

Clinical Images

Sirenomelia or mermaid syndrome

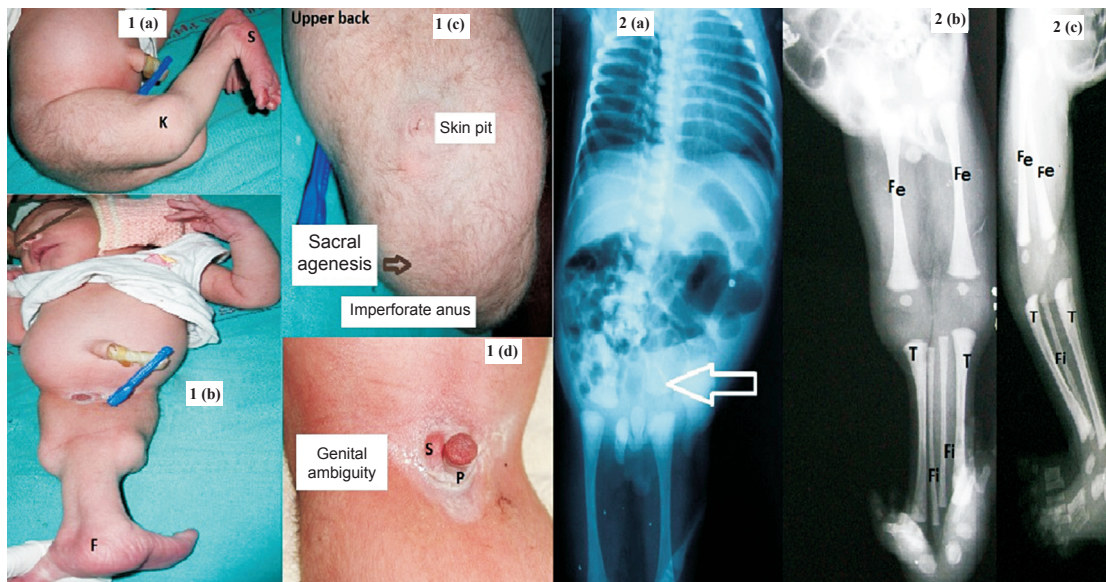


Fig.1.(a) Photograph showing abnormal flexion of knees (K) with anteriorly placed soles (S). (b) Photograph showing abnormal fusion of lower limbs from perineum to ankle with medial joining of two feet (F) (c) Posterior view showing flat perineum (black arrow) with imperforate anus and lumbosacral dermal pit. (d) Photograph showing a rudimentary phallus (P) with no urethral opening and dorsally placed hemiscrotum (S). **Fig. 2** (a). Anterioposterior (AP) radiography view of abdomen showing sacral agenesis (white arrow), kyphoscoliosis. (b), (c) AP and lateral views of lower limbs showing separate femur (Fe), tibia (T) with abnormal medial position of fibula (Fi).

A one day old infant, born of a non-consanguineous marriage, to a non-diabetic mother, presented to the department of Paediatric Surgery at Lady Hardinge Medical College, New Delhi, India, in November 2012 with complete fusion of the lower limbs from perineum to ankle, imperforate anus, sacral agenesis and rudimentary phallus with no urethral opening (Fig.1). In view of bilateral renal agenesis on imaging, poor prognosis was explained to the parents. The infant succumbed on day 4 after birth. Mermaid syndrome or sirenomelia is a rare congenital deformity in which the legs are fused and bears resemblance to mermaid's tail. It carries a grim prognosis, due to associated vertebral, urogenital and gastrointestinal abnormalities. With an early antenatal diagnosis using ultrasonography

termination of pregnancy may be considered. It is classified into symplus apus with no feet, symplus unipus if one foot is seen, and symplus dipus if two feet are present, as reported here. Embryologically it is a caudal blastemal defect, due to persistence of vitelline artery. Maternal drug abuse, diabetes and heavy metal exposure are some of the implicated risk factors.

Rahul Saxena & Archana Puri*
 Department of Paediatric Surgery,
 Lady Hardinge Medical College &
 Kalawati Saran Children's Hospital,
 New Delhi 110 001, India
**For correspondence:*
 puriararchana@hotmail.com