



Letter to the Editor

The anterolateral ligament of the knee – Visibility on magnetic resonance imaging[☆]

Ligamento anterolateral do joelho – visibilidade na ressonância nuclear magnética

Dear Editor,

With great interest I have read the article “Anatomical study on the anterolateral ligament of the knee” in your journal.¹ Meanwhile another morphological study by Claes et al.² also reported regular occurrence of the anterolateral ligament of the knee. Together with the data of Vincent et al., these three studies have examined 57 anatomical specimens and found the anterolateral ligament in 56 of them (98.2%).¹⁻³ Given the probable clinical impact on outcome after surgery of the anterior cruciate ligament preoperative judgment of its integrity would be desirable. To study the visibility on standard magnetic resonance imaging (MRI) of the knee 30 randomly selected knee MRIs from the departmental PACS were reviewed (5 women, 25 men, mean age 38.9 years). Imaging was performed on an outpatient basis using different scanners with a field strength of 1.0 or 1.5 T. According to the reported localization of the anatomic studies coronal images seemed most appropriate

for depiction. All patients received coronal proton-density weighted or fat-suppressed T2-weighted images with a slice thickness of 3–4 mm. The images were reviewed using the departmental PACS (synedra view®, Synedra, Innsbruck, Austria). The anterolateral ligament could be identified in 22 of the 30 patients (73.3%). As shown in the figure it could be found dorsal to the iliotibial tract and ventral to the lateral collateral ligament (Fig. 1). In most patients the anterolateral ligament could only be seen as a very thin ligamentous structure, in some patients only the part inserting at the lateral meniscus could be identified. Given the small number of cases no significant differences between the different scanners/sequences could be observed. Other orientations of the sequences (sagittal/axial) were found to be unreliable for the depiction of the anterolateral ligament. Until now the depiction of this ligament has not been discussed in the radiological literature. In an abstract of their work Claes et al.⁴ reported about a visibility of the anterolateral ligament in 95.7% on MRI of cases with

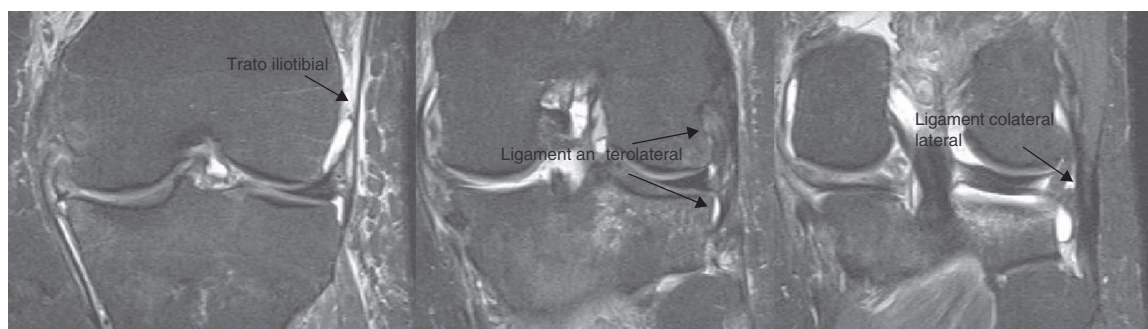


Fig. 1 – Coronal fat-suppressed T2-weighted imaging of a 38-year-old male after trauma. The anterolateral ligament is arising from the femur with two insertions, the lateral meniscus and the tibia. It is located dorsal to the iliotibial tract and ventral to the lateral collateral ligament.

[☆] Please cite this article as: Gossner J. Ligamento anterolateral do joelho – visibilidade na ressonância nuclear magnética. Rev Bras Ortop. 2014;49:98-99.

ruptured anterior cruciate ligament. The difference may be explained by the fact that the depiction of ligamentous injury is facilitated by joint effusion and edematous soft tissues separating the anatomical structures. In contrast, our approach also included exams without acute pathology, but they did not report the scanners or sequences used. In these patients a high frequency of torn anterolateral ligaments was reported.

In conclusion, the recently reported anterolateral ligament can be depicted in the majority of patients undergoing standard MRI of the knee. With a reduction of slice thickness or higher field strengths (3T) visibility will probably further increase. Orthopedic surgeons and radiologists should be aware of the importance of this structure and report about it when reviewing MRI scans of the knee.

REFERENCES

1. Helito CP, Miyahara HS, Bonadio MB, Tirico LE, Gobbi RG, Demange MK, et al. Anatomical study on the anterolateral ligament of the knee. *Rev Bras Ortop.* 2013;48(4):368-73.
2. Claes S, Vereecke E, Maes M, Victor J, Verdonk P, Bellemans J. Anatomy of the anterolateral ligament of the knee. *J Anat.* 2013;223(4):321-8.
3. Vincent JP, Magnussen RA, Gezmez F, Uguen A, Jacobi M, Weppe F, et al. The anterolateral ligament of the human knee: an anatomic and histologic study. *Knee Surg Sports Traumatol Arthrosc.* 2012;20(1):147-52.
4. Claes SA, Bartholomeeussen S, Vereecke EE, Victor JM, Verdonk P, Bellemans J. The anterolateral ligament of the knee: anatomy, radiology, biomechanics and clinical implications. Presented at the 2013 AAOS annual meeting; 2014. Available from www.abstractsonline.com

Johannes Gossner
Departamento de Radiologia Clínica, Hospital Göttingen-Weende,
Göttingen, Germany
E-mail: johannesgossner@gmx.de

14 November 2013

20 November 2013

2255-4971

© 2014 Sociedade Brasileira de Ortopedia e Traumatologia.

Published by Elsevier Editora Ltda.

Este é um artigo Open Access sob a licença de [CC BY-NC-ND](http://creativecommons.org/licenses/by-nc-nd/4.0/)

<http://dx.doi.org/10.1016/j.rboe.2014.01.004>