Clinical & Experimental Immunology
The Journal of Translational Immunology
doi:10.1111/cei.12641
IMMUNOLOGY IN THE CLINIC REVIEW SERIES
Clinical and Experimental Immunology

Immunology of IgG4-related disease

E. Della-Torre,*† M. Lanzillotta*† and C. Doglioni*‡
*Università Vita-Salute San Raffaele, †Unit of Medicine and Clinical immunology, and ‡Pathology Unit, IRCCS San Raffaele Scientific Institute, Milan, Italy

Accepted for publication 8 April 2015
Correspondence: E. Della-Torre, Unit of Medicine and Clinical Immunology, IRCCS-San Raffaele Scientific Institute, via Olgettina 60, 20132 Milan, Italy.
E-mail: dellatorre.emanuel@hsr.it

Summary

Immunoglobulin G4-related disease (IgG4-RD) is a fibroinflammatory condition that derives its name from the characteristic finding of abundant IgG4$^+$ plasma cells in affected tissues, as well as the presence of elevated serum IgG4 concentrations in many patients. In contrast to fibrotic disorders, such as systemic sclerosis or idiopathic pulmonary fibrosis in which the tissues fibrosis has remained largely intractable to treatment, many IgG4-RD patients appear to have a condition in which the collagen deposition is reversible. The mechanisms underlying this peculiar feature remain unknown, but the remarkable efficacy of B cell depletion in these patients supports an important pathogenic role of B cell/T cell collaboration. In particular, aberrant T helper type 2 (Th2)/regulatory T cells sustained by putative autoreactive B cells have been proposed to drive collagen deposition through the production of profibrotic cytokines, but definitive demonstrations of this hypothesis are lacking. Indeed, a number of unsolved questions need to be addressed in order to fully understand the pathogenesis of IgG4-RD. These include the identification of an antigenic trigger(s), the implications (if any) of IgG4 antibodies for pathophysiology and the precise immunological mechanisms leading to fibrosis. Recent investigations have also raised the possibility that innate immunity might precede adaptive immunity, thus further complicating the pathological scenario. Here, we aim to review the most recent insights on the immunology of IgG4-RD, focusing on the relative contribution of innate and adaptive immune responses to the full pathological phenotype of this fibrotic condition. Clinical, histological and therapeutic features are also addressed.

Keywords: IgG4, IgG4-related disease, immunology, pathogenesis, review

Introduction

IgG4-related disease (IgG4-RD) is a relapsing–remitting fibroinflammatory condition characterized clinically by tumefactive lesions, serum IgG4 elevation in most, but not all cases, and a prompt response to glucocorticoids (GCs). IgG4-RD was described originally in the pancreas in 2001 as 'sclerosing pancreatitis', now referred to as type I IgG4-related autoimmune pancreatitis (AIP) [1]. Shortly thereafter, however, the identification of a variety of extra-pancreatic organ involvement linked by unique histopathological features led to the recognition that AIP was part of a systemic condition [2–4]. Awareness of this new fibroinflammatory condition has expanded substantially since the first characterization of pancreatic involvement in 2001, but IgG4-RD still represents an underdiagnosed entity. Understanding of the global epidemiology of IgG4-RD remains largely incomplete [1,2]. A Japanese survey calculated that IgG4-related AIP affects 2·2 cases per 100 000 individuals and has a predilection for middle-aged to elderly men. However, the multi-organ nature of the disease, the fact that AIP represents only a minority of cases and the likelihood that even many diagnoses of AIP are missed, this figure is almost certainly an under-estimate of the true prevalence of IgG4-RD [5].

Similarly, few immunological studies have been reported to date, and the pathogenesis of IgG4-RD

remains unknown. In general theory, an antigen-driven immune response is supposed to drive both B cell commitment to IgG4 production and secretion of profibrotic cytokines by activated T lymphocytes. Indeed, rituximab (RTX), an anti-CD20 monoclonal antibody, has been proved to induce rapid clinical responses in patients with IgG4-RD, further suggesting an important pathogenic contribution of the B cell compartment [6–8]. Here, we aim to review the clinical and pathophysiological features of IgG4-RD, focusing on the most recent immunological acquisitions in the field.

Overview of clinical manifestations

IgG4-RD typically affects middle-aged to elderly men, with sporadic reports of paediatric cases [9]. The clinical presentation is usually indolent, with signs and symptoms becoming evident over months or even years. High, spiking fevers and other manifestations of systemic inflammation that mimic infections are classically absent, but weight loss can occur during the subclinical period. A longstanding history of allergies is present in 30–40% of patients at diagnosis, but symptoms that overlap with allergic conditions are also reported in some IgG4-RD patients without histories of atopy. These include bronchial asthma, chronic rhinitis and eczema [10].

IgG4-RD is characterized by pseudotumour-like lesions involving single or multiple organs. Different organs might be affected at the same time or one after the other. Clinical manifestations are largely non-specific and vary according to the spectrum of organs involved. Indeed, IgG4-RD might be asymptomatic or present with signs and symptoms related to the mechanical compression exerted by the fibrotic masses on local structures. IgG4-RD has been described in virtually every anatomical region (Table 1) [11–19], but the most common manifestations include type I AIP, chronic periaortitis, retroperitoneal fibrosis (Ormond's disease) and salivary or lacrymal gland swelling (Mikulicz's disease), conditions regarded as single independent entities for decades.

IgG4-related AIP, the most frequently recognized manifestation of IgG4-RD, presents typically with obstructive jaundice, weight loss or abdominal pain (Fig. 1a) [20–22]. Many patients are misdiagnosed initially as having adenocarcinoma of the pancreas – sometimes only after the performance of a modified pancreatectomy. Several cases of pancreatic cancer have been reported in patients with previous IgG4-related AIP, but a clear relationship between the two conditions still needs to be fully verified [23,24]. Secondary diabetes mellitus and malabsorption might complicate longstanding pancreatic disease. In 25% of cases, AIP is associated with gallbladder and bile duct involvement [25]. Gallbladder disease, known as 'IgG4-related lymphoplasmacytic cholecystitis', is generally asymptomatic and not associated with gallstones. Conversely, IgG4-related sclerosing cholangitis is likely to present with jaundice and is often difficult to differentiate from cholangiocarcinoma [22,25,26].

IgG4-related retroperitoneal fibrosis classically affects the connective tissue around the abdominal aorta ('chronic periaortitis') and the periureteral areas (Fig. 1b) [27–30]. Depending on disease localization, retroperitoneal fibrosis might be asymptomatic or present with back pain, flank pain, dysuria, haematuria, leg or scrotal oedema. Aneurysmal dilatation and hydronephrosis represent the most feared complications of retroperitoneal involvement, and might require surgical approaches to prevent aortic dissection or renal failure, respectively. Chronic periaortitis may also involve the thoracic aorta, occasionally leading to aortic dissection (Fig. 1c). Salivary and lacrymal gland involvement generally causes facial and orbital swelling (Fig. 1d). Sicca symptoms are often less severe in IgG4-RD than in Sjögren's syndrome and, when present, typically respond well to immunosuppressive therapy [31–35]. Orbital pseudotumours affect the lacrymal gland most often but can also occur in other orbital regions. Extra-ocular muscle involvement (frequently termed 'orbital myositis' in the days before the recognition of IgG4-RD) can present with exophthalmos and the restriction of ocular movements [32,33] (Fig. 1e,f).

Atypical presentations of IgG4-RD that lack pseudotumour-like lesions should be borne in mind, including tubulointerstitial nephritis, glomerulonephritis, midline destructive lesions, interstitial lung disease, pleural and pericardial effusion [11,36]. In particular, renal involvement might present with variable degrees of proteinuria, haematuria, renal failure or hypocomplementaemia [37–39]. Finally, life-threatening presentations such as rupture of inflammatory aneurysms, coronary syndromes, pachymeningitis and acute neurological events have also been described occasionally [30,40–42]. A comprehensive review of the organs involved by IgG4-RD, common clinical presentation and differential diagnoses is detailed in Table 1 [43–50].

Diagnosis

Definitive diagnosis of IgG4-RD requires both histopathological confirmation and clinicopathological correlation. Serological and radiological features lack adequate sensitivity and specificity for diagnostic purposes. Histological examination is also mandatory to exclude neoplastic or inflammatory conditions that can mimic IgG4-RD.

Serological findings

Serological findings in patients with IgG4-RD are largely non-specific. Acute phase reactants such as the erythrocyte sedimentation rate and C-reactive protein are usually (but not always) elevated to a moderate degree. Peripheral blood eosinophilia and increased serum IgE occur in

 © 2015 British Society for Immunology,

almost 30% of patients [10]. Some patients have positive low-titre anti-nuclear antibodies, but the presence of anti-Sjögren's syndrome-related antigen A (Ro/SSA), anti-La/Sjögren's syndrome-related antigen B (SSB) and anti-neutrophil cytoplasmic antibodies (ANCA) antibodies strongly implicate other immune-mediated conditions.

High serum IgG4 concentrations occur in 60–70% of patients, typically in those with multi-organ involvement [4]. Unfortunately, elevation in serum IgG4 can be associated with a host of conditions with the potential to mimic IgG4-RD, e.g. systemic vasculitides (particularly granulomatosis with polyangiitis), connective tissue disorders (e.g. the lupus spectrum of conditions), infections and malignancies [51]. Therefore, measurement of serum IgG4 should be regarded only as a useful screening tool, not as a 'stand-alone' diagnostic marker.

An analogous principle pertains to the use of serum IgG4 concentrations as a longitudinal biomarker. Although serial measurement of serum IgG4 concentrations are often useful in the assessment of disease activity, they should never be used as the sole determinant of treatment decisions. IgG4 production in the cerebrospinal fluid has also been suggested as a diagnostic biomarker for IgG4-related pachymeningitis, but histopathological evaluation, whenever possible, remains mandatory [52]. Other immunoglobulins, including IgM, IgA and other IgG subclasses, are frequently elevated in IgG4-RD, although generally not to the extent of IgG4 [2]. High concentrations of IgG subclasses other than IgG4, e.g. IgG1 and IgG3, may account for the hypocomplementaemia observed in a minority of IgG4-RD patients, because IgG4 itself typically binds complement poorly [2]. Hyperviscosity syndromes have been reported in rare cases [53].

Circulating $CD19^{+}CD20^{-}CD27^{+}CD38^{+}$ plasmablasts, the precursors of tissue resident plasma cells, have been proposed as the best available indicator of IgG4-RD disease activity, but larger studies are required in order to validate this test [54].

Radiological findings

Radiological findings are largely non-specific and are not sufficient to distinguish IgG4-RD from the neoplastic condition presenting with mass-forming lesions. IgG4-related AIP is the sole exception, because computed tomography and magnetic resonance imaging classically show a 'sausage-shaped' pancreas with a halo of oedematous tissue (Fig. 1a). These benign features are supported further by the aspect of the pancreatic gland on endoscopic ultrasonography and on histological examination through endoscopic core biopsy. ^{18}Fluoro-deoxyglucose positron emission tomography reliably identifies active inflammation in IgG4-RD and might be useful both for staging purposes and for assessing disease response to treatment [55] (Fig. 1c).

Pathology

Histopathological hallmarks of IgG4-RD are (i) a dense storiform fibrosis, (ii) obliterative pheblitis, (iii) a lymphoplasmacytic infiltrate rich in $IgG4^{+}$ plasma cells and (iv) a mild to moderate eosinophilic infiltrate (Fig. 2.a–f) [3,4]. Epithelial or endothelial damage is not typical until end-stage disease, when fibrosis subverts the parenchymal structure and impairs organ function (Fig. 2a). Neutrophils, necrosis and granulomas are classically absent, and their presence should prompt the exclusion of other potential differential diagnoses.

Storiform fibrosis. 'Storiform fibrosis' is a hallmark of IgG4-RD. The term 'storiform' refers to an irregularly whorled organization of the collagen bundles that can be observed in any organ affected by IgG4-RD (Fig. 2b,c). Storiform fibrosis is not usually prominent in lacrymal glands and lymph node involvement, although this finding has also been reported in those tissues. Storiform fibrosis is likely to be triggered by the activation of myofibroblasts following profibrotic stimuli provided by the inflammatory infiltrate. Some authors have hypothesized that the absence of a lymphoplasmacytic infiltrate in tissue biopsies marks the progression of IgG4-RD from an 'active' phase, characterized by abundant numbers of cell of the B and T cell lineages, to an 'end-stage' phase, characterized chiefly by fibrosis with few or no $IgG4^{+}$ plasma cells [8]. Even in the earliest stages of disease, however, some degree of fibrosis is typically present. These considerations should be borne in mind, because pathologists might encounter different stages of IgG4-RD due to bioptic procedures that do not always provide adequate sample sizes (e.g. needle biopsies) or areas of active disease.

Obliterative phlebitis. A unique feature of IgG4-RD is obliterative phlebitis. Obliterative phlebitis refers to the partial or complete occlusion of the lumina of small- and medium-sized veins by the lymphoplasmacytic infiltrate and by extrinsic compression (Fig. 2d). The presence of obliterative phlebitis should be sought thoroughly because of its diagnostic value, ideally through the use of elastin stains targeting the internal elastic lamina of the vessel. In contrast to systemic vasculitides such as granulomatosis with polyangiitis, microscopic polyangiitis and polyarteritis nodosa, leucytoklastic vasculitis with vessel wall necrosis and fibrin deposition is not observed in IgG4-RD. Obliterative arteritis has been reported, particularly in the lung [3].

Lymphoplasmacytic infiltrate. Lymphoplasmacytic infiltrate is composed of polyclonal/oligoclonal B and T lymphocytes. B lymphocytes tend to be organized in germinal centres (Fig. 3a), while T lymphocytes are spread throughout the fibrotic tissue (Fig. 3b). Immunohistochemistry is essential for the diagnosis of IgG4-RD because it allows the demonstration of $IgG4^{+}$ plasma cells and evaluation of the $IgG4^{+}/IgG^{+}$ ratio (Fig. 2e,f). Of note, as $IgG4^{+}$ plasma cells might be found in other

Table 1. The spectrum of IgG4-related disorders (IgG4-RD): synopsis of clinical manifestations, differential diagnoses, pathology features and therapeutic approaches. A consensus on hystopathological features diagnostic for IgG4-RD has not been reached for all possible affected organs

Organ involvment (Ref.)	Nomenclature (previous name)	Clinical presentation
Head and Neck		
Orbits and periorbital tissue [31–33]	IgG4-related orbital disease (orbital inflammatory pseudotumour)	Exophthalmos, haemianopsia, ocular movement restriction, ptosis, headache, scleritis, xerophthalmia
Salivary glands and lacrymal glands [34,35]	IgG4-related sialoadenitis (Mikulicz's disease, Kuttner's tumour)	Parotid or submandibular gland swelling, xerostomia
Thyroid gland [19]	IgG4-related thyroiditis (Riedel's rhyroiditis)	Neck pressure, neck mass, malaise, recurrent laryngeal nerve palsy, hypothyroidism
Ear, nose and throat [17,36]	IgG4-related sinusitis/midline destructive lesion/pharyngitis	Nasal crusting, nasal obstruction, rhinorrhoea, polyposis, sinusitis, nasal septum perforation, laryngeal obstruction, middle ear effusion
Thorax		
Lungs [11,12]	IgG4-related lung disease	Cough, sputum, dyspnoea, chest pain
Pleura [12]	IgG4-related pleural disease	Chest pain, dyspnoea, pleural effusion
Mediastinum [46]	IgG4-related mediastinitis (fibrosing mediastinitis)	Mediastinal mass, compression of mediastinal structures, dyspnoea, chest pain
Breast [50]	IgG4-related mastitis	Painless breast mass
Abdomen and pelvis		
Retroperitoneum [27–30]	IgG4-related retroperitoneal fibrosis (Ormond's disease)	Back/flank pain, leg oedema, hydronephrosis, deep venous thrombosis, varicocele
Pancreas [1,21,22]	IgG4-related autoimmune pancreatitis (type1 autoimmune pancreatitis)	Obstructive jaundice, diabetes mellitus, abdominal pain, pale stool, malabsorption
Biliary tree/gallbladder [23,24]	IgG4-related sclerosing cholangitis	Jaundice, weight loss, abdominal pain
Liver [24]	IgG4-related hepatitis (hepatic inflammatory pseudotumour)	Mainly asymptomatic, transaminitis, hepatic mass
Kidney [37–39]	IgG4-related tubule-interstitial nephritis/ glomerulonephritis	Elevated serum creatinine, proteinuria, haematuria, nephritic/ nephrotic syndrome
Gastrointestinal tract [49]	IgG4-related gastrointestinal disease	Epigastric pain, chronic/acute abdominal pain, intestinal obstruction or dysmotility, nausea
Mesentere [47]	IgG4-related sclerosing mesenteritis	Abdominal pain, abdominal mass, vomiting, nausea
Prostate [44]	IgG4-related prostatitis	Mass, lower urinary tract symptoms, dysuria
Testis [45]	IgG4-related epididymo-orchitis (testicular inflammatory pseudotumour)	Scrotal mass, scrotal pain
Nervous system		
Central nervous system [43]		Dementia, hemiparesis, multi-focal neurological defects
Pituitary gland [14]	IgG4-related hypophysitis	Hypopituitarism, diabetes insipidus, headache
Peripheral nerves [42]	IgG4-related neuropathy	Sensory-motor polyneuropathy, multiplex mononeuritis, perineural mass
Meninges [15,16]	IgG4-related pachymeningitis (hypertrophic pachymeninigitis)	Headache, cranial nerve palsies, vision disturbance, motor weakness, limb numbness, sensorineural hearing loss, seizures
Cardiovascular system		
Heart and pericardium [41]	IgG4-related cardiac disease	Acute chest pain (coronary syndrome), dyspnoea, pericardial rub
Aorta [30,40]	IgG4-related periaortitis (chronic periaortitis/ inflammatory aortic aneurism)	Back pain, leg oedema, bruits, acute aneurysm rupture
Lymph nodes [13]	IgG4-related lymphadenopathy	Usually asymptomatic, lymph node enlargement
Skin [18]	IgG4-related skin disease	Skin plaques, subcutaneous nodules, brown papules, dermatitis
Bone [48]	IgG4-related disease of the bone	Headache, tinnitus, skull base destructive lesion, tumefactive sinus lesion

For the organs included in the 'Consensus Statement on the pathology of IgG4-RD'[3]* a 'highly suggestive' diagnosis of IgG4-RD requires (i) specific cut-offs of $IgG4^+$ plasma cells/high-power field (HPF)*, (ii) an $IgG4^+/IgG^+$ plasma cell ratio > 40% and (iii) two or more of the following histological features: dense lymphoplasmacytic infiltrate, storiform fibrosis and obliterative phlebitis. For the organs not included in the 'Consensus Statement', 'Comprehensive diagnostic criteria'[4]† are still adopted. In this case, a 'definite' diagnosis of IgG4-RD requires (i) an infiltration of > 10 $IgG4^+$ plasma cells/HPF† and an $IgG4^+/IgG^+$ plasma cells ratio > 40%, together with (ii) diffuse/localized swelling or masses in single or multiple organs and (iii) serum IgG4 concentrations > 135 mg/dl. Abbreviations: glucocorticoids (GC: 0·5–1 mg/kg/day); methotrexate (MTX: 10–20 mg/week); cyclophosphamide (CTX: 500–1200 mg/m^2/month); rituximab (RTX: 1000 mg in two doses 15 days apart); azathioprine (2–2·5 mg/kg/day); mycophenolate mofetil (MMF: 750–1000 mg twice daily); bortezomib (BTZ: 1·5 mg/m^2/week). IgG4-RD = immunoglobulin G4-related disorders; HPF = high-power field; GERD = gastroesophageal reflux disease.

Table1. continued

Differential diagnoses	Pathology features: IgG4/HPF diagnostic for IgG4-RD*†	Therapeutic strategies
Lymphoma–granulomatosis with polyangiitis–sarcoidosis–Graves' orbitopathy, Sjögren's syndrome	>10/HPF†	GC–MTX–CTX–RTX–BTZ–surgery
Lymphoma–Sjögren's syndrome–sialodocholithiasis–sarcoidosis	>100/HPF*	GC–AZA–MTX–RTX
Thyroid lymphoma–differentiated thyroid carcinoma–other malignancies	>10/HPF†	GC–MTX–RTX
Allergic disease–Churg–Strauss syndrome–granulomatosis with polyangiitis–chronic infections–sarcoidosis	>10/HPF†	GC
Malignancy–sarcoidosis–granulomatosis with polyangiitis–infections–interstitial lung disease–inflammatory miofiroblastic tumour–Churg–Strauss syndrome	>50/HPF (surgical specimen) >20/HPF (biopsy)*	GC–AZA–CTX–RTX–BTZ
Mesothelioma–infections	>50/HPF*	GC
Lymphoma–sarcoidosis–histoplasmosis–malignancies–mycobacterial infection	>10/HPF†	GC
Malignancies–mastitis	>10/HPF†	GC–surgery
Lymphoma–sarcoma- Erdheim–Chester disease–periaortitis–idiopathic retroperitoneal fibrosis	>30/HPF*	GC–AZA–MMF–RTX
Pancreatic cancer–Type II autoimmune pancreatitis	>50/HPF (surgical specimen) >10/HPF (biopsy)*	GC–MTX–AZA–RTX
Pancreatic cancer–cholangiocarcinoma–primary sclerosing cholangitis	>50/HPF (surgical specimen) >10/HPF (biopsy)*	GC–AZA–MMF–RTX
Cholangiocarcinoma–hepatocellular carcinoma–autoimmune hepatitis	>50/HPF (surgical specimen) >10/HPF (biopsy)*	GC–RTX
Lymphoma–renal-cell carcinoma–drug-induced tubulointerstitial nephritis–vasculitis–systemic lupus erythematosus	>30/HPF (surgical specimen) >10/HPF (biopsy)*	GC–surgery
Malignancies–GERD	>10/HPF†	GC
Lymphoma–fibromatosis–peritoneal carcinosis	>10/HPF†	GC
Benign prostatic hypertrophy–malignancies–infections	>10/HPF†	GC
Seminoma–lymphoma–inflammatory miofibroblastic tumour	>10/HPF†	Surgery
Central nervous system vasculitis–infections–malignancies	>10/HPF†	GC
Neoplasms–histiocytosis–primary hypophisytis–sarcoidosis	>10/HPF†	GC
POEMS syndrome–metabolic neuropathy–vasculitis–other demyelinating neuropathies	>10/HPF†	GC
Chronic infections–lymphoma–Langherhans-cell histiocytosis–giant-cell arteritis–sarcoidosis–idiopathic hypertrophic pachymeninginitis	>10/HPF*	GC–CTX–MTX–RTX
Infections–inflammatory pericarditis–cardiac mixoma–acute coronary syndrome	>10/HPF†	GC
Takayasu arteritis–giant cell arteritis–lymphoma–infectious aortitis–sarcoidosis–histiocytosis	>50/HPF*	GC–MTX–RTX
Multi-centric Castleman disease–lymphoma–systemic lupus erythematosus–sarcoidosis–infections	>100/HPF*	GC–RTX
Cutaneous lymphoma–drug eruption–psoriasis vulgaris–multi-centric Castleman disease	>200/HPF*	GC–RTX
Malignancy–osteomielitis	>10/HPF†	GC

inflammatory, neoplastic and infectious conditions, organ specific cut-offs have been defined in order to increase the diagnostic accuracy of the immunohistochemical examination (Table 1) [3]. Indeed, a correct diagnosis should not rely on immunohistochemistry alone, but also consider the other characteristic histological features.

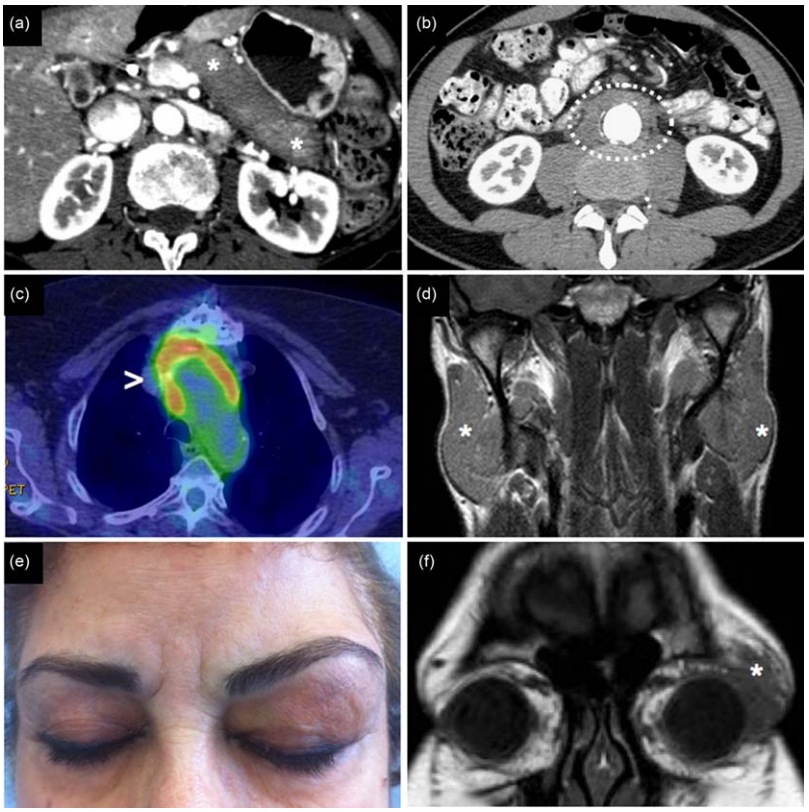

Fig. 1. Clinical and radiological presentation of IgG4-related disease (IgG4-RD). (a) IgG4-related autoimmune pancreatitis: computed tomography scan showing a 'sausage-like'-shaped pancreas with a surrounding rim of hypodense tissue (asterisks). (b) Retroperitoneal fibrosis with periaortic involvement (circle). (c) Inflammatory aneurism of the thoracic aorta showing ^{18}fluorodeoxyglucose uptake on positron emission tomography (arrowhead). (d) Magnetic resonance showing bilateral parotid enlargement due to IgG4-RD (asterisks). (e,f) Clinical and radiological appearance of IgG4-related orbital pseudotumour (asterisk).

Tissue eosinophilia and macrophages. Eosinophils are present in at least 50% of IgG4-RD lesions and might dominate the histological picture in those cases of orbital or upper respiratory tract involvement, sometimes termed 'eosinophilic angiocentric fibrosis' [56]. Macrophages are usually detectable within the fibroinflammatory infiltrate, but the presence of granulomas argues strongly against the diagnosis of IgG4-RD (Fig. 3c) [3,4].

Treatment

Treatment is not always necessary in patients with IgG4-RD, and watchful waiting is prudent in some asymptomatic cases. Conversely, when vital organs are involved or patients become symptomatic, aggressive treatment is needed because IgG4-RD can lead to serious organ dysfunction and failure. Response to treatment might be assessed by means of the IgG4-RD Responder Index, a validated tool for monitoring clinical, radiological and serological outcomes of IgG4-RD [57].

According to the recently released International Consensus Statement on the Treatment of IgG4-RD [58], GCs represent the first line therapy because they lead to dramatic clinical responses in the majority of cases with both pancreatic and extra-pancreatic disease. One typical approach is to treat with prednisolone (0·6 mg/kg per day for 2–4 weeks), followed by a gradual taper over a period of 3–6 months once remission is achieved [59]. IgG4-RD has, however, a marked tendency to relapse during or after GC tapers, especially in cases of elevated serum IgG4 at baseline, multi-organ involvement and history of disease relapse [59]. Thus, a variety of GC-sparing agents have been employed in different anatomical districts as remission-maintenance drugs (e.g. azathioprine, mycophenolate mofetil, methotrexate, cyclophosphamide and bortezomib), with alternate results [59,60] (Table 1). More recently, RTX has been proved to induce swift clinical responses and a selective decline of serum IgG4 subclass concentrations in patients with recurrent or refractory disease [6,7]. Finally, when urgent decompression is needed, as in the case of biliary duct or ureteral strictures, temporary stenting or surgical approaches remain the strategy of choice for preventing serious organ damage.

All in all, a major determinant of the responsiveness to immunosuppressive treatments is probably the degree of inflammatory cells within the affected organs. Indeed, researchers have hypothesized that mass-forming IgG4-RD lesions are more likely to shrink in the presence of a prominent lymphoplasmacytic infiltrate ('active fibroinflammation'), rather than in the presence of tightly organized collagen bundles in which both inflammatory cells and myofibroblasts are rare ('acellular end-stage fibrosis' or 'fibrotic scar') [8]. Further studies are needed to provide reliable and standardized guidelines for the long-term management of IgG4-RD.

 © 2015 British Society for Immunology,

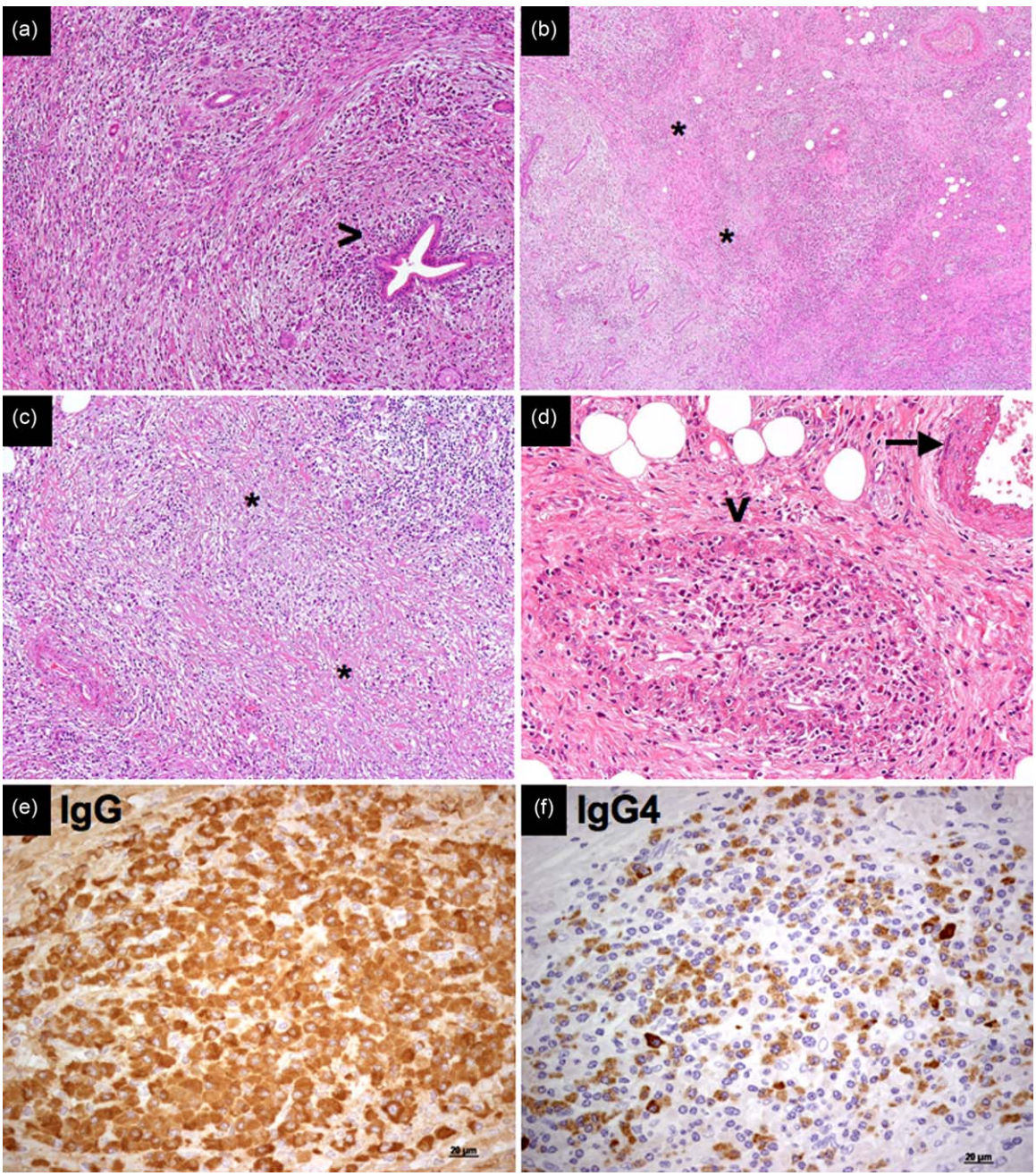

Fig. 2. Pathological features of immunoglobulin (Ig)G4-related disease. (a) Pancreatic ducts are not affected by the fibroinflammatory infiltrate in IgG4-related autoimmune pancreatitis (arrowhead; haematoxylin and eosin, magnification ×100). (b,c) Areas of storiform fibrosis in IgG4-related autoimmune pancreatitis [asterisks; haematoxylin and eosin, magnification ×40 (b) and ×100 (c)]. (d) Obliterative phlebitis: an obliterated vein surrounded by an inflammatory nodule (arrowhead), next to an intact artery (arrow) (haematoxylin and eosin, magnification ×200). (e,f) Immunohistochemistry for IgG (e) and IgG4 (e) on sequential sections shows an IgG4/IgG ratio > 40% (magnification ×40).

Immunopathology of IgG4-related disease

Little is known with certainty about the pathogenic events that initiate IgG4-RD. The evidence of common histopathological features shared by different unrelated organs suggests that IgG4-RD might be an antigen-driven inflammatory condition leading ultimately to tissue fibrosis. However, a number of unsolved questions still need to be addressed, including: (i) the pathophysiological importance of IgG4 antibodies; (ii) the characterization of the putative microbial or self-antigen; (iii) the imbalance between T helper type 1 (Th1), Th2 and regulatory T cell activation; (iv) the role of innate immunity;

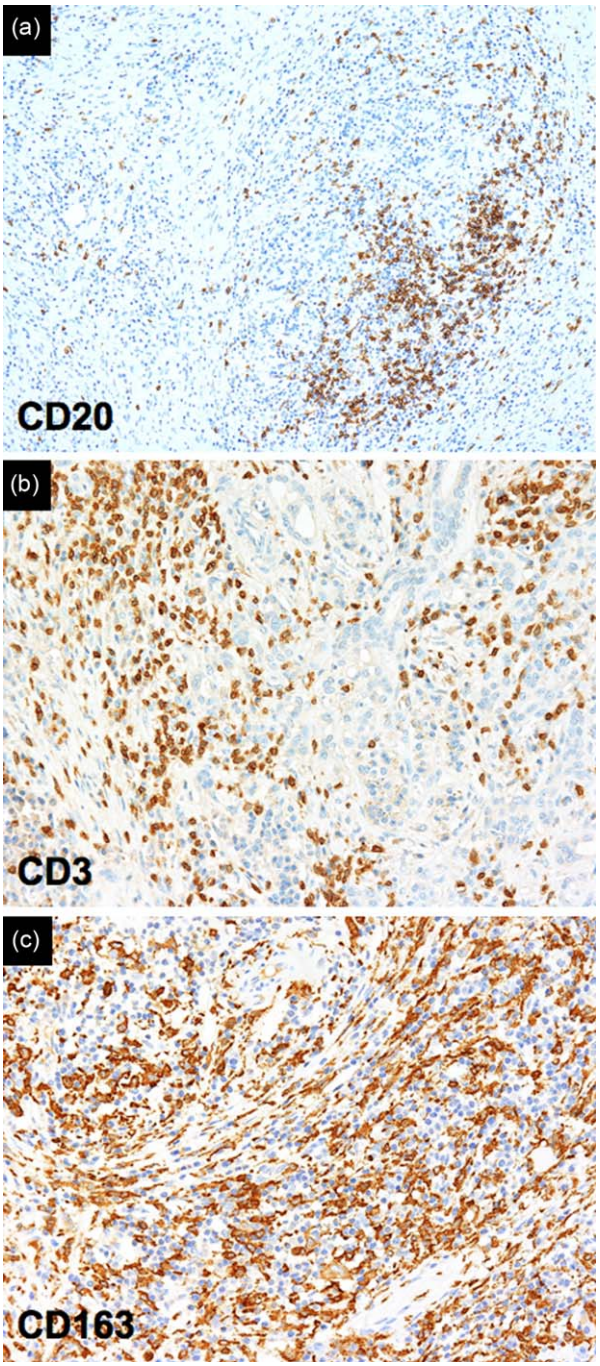

Fig. 3. Inflammatory infiltrate in IgG4-related disease. Immunohistochemistry reveals CD20$^+$ B lymphocytes organized in follicular structures (a), CD3$^+$ T lymphocytes (b), and CD163$^+$ M2 macrophages (c) spread throughout the fibrotic tissue (magnification ×100).

and (v) the immunological mechanisms leading to fibrosis.

The role of IgG4 antibodies

IgG4 antibodies represent the least abundant IgG subclass in healthy individuals (1–4% of total IgG), and their role in IgG4-RD is still controversial [2]. IgG4 antibodies are supposed to be produced after long-term antigen exposure in response to interleukin (IL)-4 and IL-10 [61], but the molecular mechanisms that drive the IgG4 class-switch are not fully understood. Indeed, part of these mechanisms (e.g. Th2 cytokines) might also increase serum IgE levels, as exhibited by many IgG4-RD patients [62].

In contrast to other IgG subclasses, heavy chains in each IgG4 molecule have non-covalent associations and inefficient disulphide bridges due to a single amino acid difference in the hinge region (a serine in lieu of a proline) (Fig. 4) [63,64]. As a result, hemi-IgG4 molecules – one heavy chain covalently associated with one light chain – have the propensity to dissociate from each other and reassociate randomly with distinct hemi-IgG4 molecules that have different antigen-binding specificities. This phenomenon is known as 'Fab arm exchange' (Fig. 4). Fab arm exchange requires a reducing environment to occur, but the precise location of the exchange *in vivo* has not been determined [64]. This half-antibody exchange, unique to the IgG4 isoclass, generates functionally 'bi-specific' antibodies that are capable of binding two different antigens but rarely associate with each other to form large immune complexes [65,66]. IgG4 antibodies also have limited ability to form immune responses because of their low affinity for both Fc receptors and the C1 complement molecule [67]. For these reasons, IgG4 has been viewed traditionally as a 'non-inflammatory' molecule, the primary function of which is to dampen rather than to incite or accelerate chronic immune activation. In short, despite the importance of IgG4 implied by the current name of this disease, the IgG4 molecule is probably not the disease driver. This is consistent with what has long been known about IgG4: that IgG4 antibodies are induced by allergy treatments designed to induce tolerance and protect allergic patients from anaphylactic reactions by competing with allergen specific IgE [68,69].

Nevertheless, several pieces of evidence suggest a pathogenic role for IgG4 antibodies, including the correlation between serum IgG4 and disease severity [2], the observation of IgG4 immune complexes in IgG4-related tubulointerstitial nephritis [69] and the possibility of complement activation through the lectin pathway [70]. ANCA of the IgG4 subclass have been demonstrated to bind Fc-gamma receptors and to contribute (at least *in vitro*) to neutrophil activation in ANCA-associated vasculitides [71,72]. IgG4 antibodies directed against desmoglein 1 and the metalloproteinase ADAMTS13 have been also implicated in the pathogenesis of pemphigus vulgaris and thrombotic thrombocytopenic purpura, respectively [73,74]. Furthermore, IgG4 as well as IgE might, theoretically, bind to Fc receptors on macrophages and eosinophils, foster internalization of extracellular antigens and

 © 2015 British Society for Immunology,

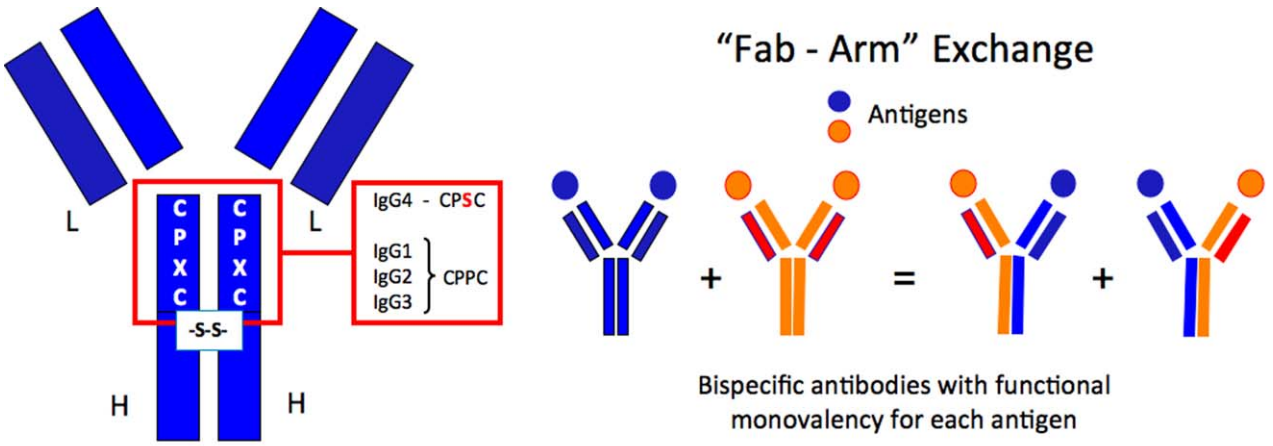

	IgG1	IgG2	IgG3	IgG4
Biological target	Protein	Carbohydrate	Protein	Protein
Functional form	Monomeric, bivalent	Dimeric, bivalent or tetravalent	Monomeric, bivalent	Bispecific, monovalent for each antigen
Serum levels (mg/dl)	5 - 11	1·5 - 6	0·2 - 1	0·08 - 1·4
Proportion of total IgG (%)	43 - 75	16 - 48	1·7 - 7	0·8 - 11·7
Complement fixation	+++	+	+++	-
Binding to FC gamma receptors				
FC gamma RI	++	+	+++	+
FC gamma RII	++	+	+++	-
FC gamma RIII	++	+	++	-

Fig. 4. Molecular basis of the 'Fab-arm' exchange and physiopathological properties of immunoglobulin (Ig)G4 antibodies.

facilitate their presentation to $CD4^+$ T lymphocytes [75]. Finally, recombinant monoclonal IgG4 antibodies cloned from circulating plasmablasts of patients with active IgG4-RD demonstrate self-reactivity in immunofluorescence and enzyme-linked immunosorbent assay (ELISA) experiments on Hep2 and HeLA cells, respectively, even though no definitive antigen specificity has been identified to date [77]. The identification of putative target antigens will improve our understanding of the pathogenic role of IgG4 antibodies in IgG4-RD.

Putative microbial and self-antigens

Putative autoantigens have been proposed as targets of an antibody response in a proportion of patients with IgG4-related AIP and sialoadenitis [76–83]. These antigens include proteins expressed in duct epithelia (carbonic anhydrase II and IV) and in acinar cells (lactoferrin, amylase-α-2A, pancreatic trypsinogens and pancreatic secretory trypsin inhibitor). However, these autoantigens are expressed only in a minority of organs potentially involved by IgG4-RD, and have been shown to induce autoantibodies in different autoimmune disorders [79], thus lacking adequate specificity for IgG4-RD. Indeed, these antigens might simply represent a preferential target during inflammatory processes in general, and their pathogenic role has yet to be proved. Molecular mimicry between *Helicobacter pylori* and pancreatic self-proteins has been also proposed as an additional pathogenic mechanism in IgG4-related AIP [84], but these results have not yet been replicated and must be interpreted cautiously.

B lymphocytes

The B cell compartment of patients with IgG4-RD has been studied extensively, because IgG4 elevation in the serum and the abundance of $IgG4^+$ plasma cells in the biopsies initially suggested an underlying lymphoproliferative condition. Moreover, B cell depletion therapy has been shown recently to induce a prompt clinical improvement in patients with IgG4-RD, supporting a central pathogenic role of B lymphocytes in this fibrotic condition [6–8].

However, although IgG4-RD has been associated with an increased risk of malignant lymphoid transformation, immunohistochemistry and *in-situ* hybridization for kappa-lambda light chains restriction failed to identify monoclonal plasma cells populations in the affected tissues [3,4,13]. On the contrary, cerebrospinal fluid analysis

of subjects with IgG4-related pachymeningitis revealed the presence of oligoclonal IgG4 bands, suggesting an antigen-driven immune response [85,86]. Indeed, next-generation sequencing analysis on biopsy samples and on peripheral blood of IgG4-RD patients demonstrated an oligoclonal expansion of somatically hypermutated IgG4$^+$ B cell clones, further supporting antigen-specific affinity maturation [76,87].

The expanded B cell clones detected on peripheral blood correspond to a population of circulating plasmablasts, identified by flow cytometry as CD19$^+$CD20$^-$ CD27$^+$CD38$^+$ cells. Circulating plasmablasts are not distinguishable from small-sized lymphocytes on blood smear, and arise classically in germinal centres after affinity maturation from CD20$^+$ naive precursors. Finally, after circulating into the bloodstream, plasmablasts home to inflammatory niches or to the bone marrow, where they differentiate into antibody-secreting short- or long-lived plasma cells [88]. Plasmablasts can circulate for prolonged periods in the setting of chronic antigenic stimulation or autoimmune diseases, but are generally observed in only low concentrations in the peripheral blood of healthy individuals [89–94]. Of note, plasmablasts expanded in IgG4-RD patients decrease sharply after RTX-induced remission and re-emerge during relapse, thus correlating tightly with disease activity. Interestingly, re-emerging plasmablasts express a distinct V–J repertoire from that of the clones that dominated at the time of initial presentation ('clonal divergence') [76], indicating repeated rounds of mutation and selection driven by a specific antigen. Recent evidence raises the possibility that plasmablasts expanded in IgG4-RD patients might belong to a subset of regulatory B cells, capable of secreting IgG4 antibodies and IL-10 in response to chronic antigen stimulation [95,96]. However, although plasmablasts share some surface markers with regulatory B cells, functional assays for IL-10 production failed to confirm this hypothesis, and expansion of regulatory B cells in the peripheral blood of patients with IgG4-RD has not been confirmed [76,95].

Activated IgG4$^+$ B cells and plasmablasts could contribute to the pathogenesis of IgG4-RD either directly through autoantibody production or indirectly through the activation of pathogenic CD4$^+$ T cells, presumably serving as effective antigen-presenting cells. Indeed, the high degree of somatic hypermutation and the 'clonal divergence' seen in IgG4$^+$ plasmablasts also suggest extensive T helper cell-dependent processes at different stages of disease. In theory, B lymphocytes might also directly sustain extracellular matrix deposition through myofibroblast activation, the production of profibrotic cytokines [e.g. IL-6 and transforming growth factor (TGF)-β] and the secretion of stimulatory autoantibodies [8,97–99], but these hypotheses have never been assessed in IgG4-RD.

T lymphocytes

IgG4-RD has been considered a Th2/T regulatory-driven condition for quite a long time. Indeed, the presence of a dense fibrotic tissue and of abundant IgG4$^+$ plasma cells are consistent with an underlying 'modified Th2 immune-response', which is associated classically with the production of both Th2 (e.g. IL-4 and IL-13) and T regulatory cytokines (e.g. TGF-β and IL-10) [100,101]. In this scenario, IL-13 and TGF-β are thought to drive the deposition of extracellular matrix by activated fibroblasts, while IL-4 and IL-10 are considered the major inducer of IgG4 class-switch in naive B lymphocytes [100,101]. The presence of allergic symptoms, peripheral blood eosinophilia, serum IgE and IgG4 elevation in many patients at diagnosis further supports this hypothesis [10].

However, accurate analysis of circulating T cells for Th1/Th2/T regulatory polarization has led to conflicting results, and showed an expansion of Th2 memory CD4$^+$ T cells only in IgG4-RD patients with a concomitant history of atopy [102,103]. Similarly, molecular and immunohistochemical analyses of IgG4-RD lesions identified variable amounts of Th1, Th2 and T regulatory cytokines, but failed to identify the exact cellular source of these molecules [100]. Therefore, direct evidence for a role of Th1/Th2/T regulatory cells in IgG4-RD pathogenesis is still lacking. Indeed, this would require the documentation of Th1/Th2/T regulatory cytokines within T cells that infiltrate affected tissues.

T cells might also contribute to IgG4-RD pathogenesis through a dysregulated follicular T helper cell activity. For instance, altered expression of IL-21 by follicular T helper cells has been associated with autoantibody production in other autoimmune diseases [104], and elevated IL-21 messenger RNA expression has been linked recently to ectopic germinal centres within lacrymal and salivary glands from patients with IgG4-RD [105]. It is conceivable that memory and follicular CD4$^+$ T helper cell-dependent processes orchestrate IgG4-RD both by secreting profibrotic cytokines and by inducing IgG4 class-switch, plasmablast expansion and production of autoantibodies. These hypotheses require further investigation.

The lesson from B cell depletion

As reported previously, treatment with anti-CD20 monoclonal antibody induces a prompt clinical response in patients with IgG4-RD and a drastic reduction in the number of circulating oligoclonally expanded plasmablasts [54,76]. Plasmablasts do not express CD20, the molecular target of RTX and, thus, they are likely to decrease in the peripheral blood because of failure to replete CD20$^+$ precursors. These data support a potential pathogenic role of IgG4$^+$ B lymphocytes (or B cells in general), and possibly IgG4 immunoglobulins, but the precise mechanisms

through which RTX could affect putative T cell-mediated profibrotic processes in IgG4-RD remain elusive. Indeed, the encouraging results obtained recently with RTX in IgG4-RD, as well as in other fibrotic conditions and T cell-driven disorders (such as systemic sclerosis, interstitial lung disease and multiple sclerosis) have expanded the overly simplistic view about B cells as simply precursors of antibody-producing plasma cells [8,106–108]. B lymphocytes might act as functional antigen-presenting cells to Th2 effector cells, maintain $CD4^+$ memory T cells by providing antigen-independent factors and promote the proliferation of pathogenic T cells [109–111]. Thus, apart from depleting $CD20^+$ B cells, RTX is likely to interfere with more important B cell/T cell cross-talk processes through the elimination of a major B-cell type required for continuous antigen presentation to T cells and for the maintenance of T cell activation. In this sense, it is tempting to speculate that B cell depletion in IgG4-RD ultimately abrogates the secretion of profibrotic cytokines (e.g. IL-4, IL-13, IL-10 and others) by pathogenic T cell populations.

Macrophages

Macrophages are tissue-resident monocytes specialized in phagocytosis and initiation of innate immunity. Two subtypes of macrophages have been identified to date: the classically activated (M1) macrophages, stimulated by Th1 responses, and the alternatively activated (M2) macrophages, induced by Th2 derived IL-4 and IL-13, as well as T regulatory-derived IL-10 [112]. Alternatively activated macrophages have been implicated in the pathogenesis of IgG4-RD because they are known to contribute to angiogenesis, immunomodulation, wound-healing and fibrosis by secreting a variety of molecules, including profibrotic factors such as TGF-β and platelet-derived growth factor (PDGFP) [113]. A direct profibrotic role has been suggested by Furukawa, who showed a correlation between $CD163^+$ M2 macrophages infiltration and the amount of tissue fibrosis in biopsies of patients with Mikulicz's disease [114]. Alternatively, Watanabe demonstrated that macrophages from patients with IgG4-related AIP induce IgG4 production by B cells upon stimulation of Toll-like receptors (TLRs) and nucleotide-binding oligomerization domain receptors (NOD)-like receptors [115]. IgG4 production was found to be dependent upon B cell-activating factor (BAFF) secretion by activated monocytes in that study [115]. Although more robust evidence is needed in order to drive definitive conclusions, these preliminary results suggest that macrophages might be important in the pathogenesis of IgG4-RD.

Basophils

Basophils, the least common of the circulating granulocytes, are known to be involved in allergic inflammatory reactions as well as in immune responses to parasitic infections. Indeed, basophils express IgE receptors on their surface, function as antigen-presenting cells in Th2 responses and release large amounts of different soluble mediators in response to allergen proteins or helminth antigens, including histamine, heparin and proteolytic enzymes [116]. Moreover, basophils are considered the most important source of IL-4 together with T cells [117,118]. The role of basophils in IgG4-RD remains largely unexplored. A single study demonstrated that activation of TLRs expressed on basophils from patients with IgG4-RD induced IgG4 production by B cells from healthy controls. As reported for monocytes in a previous study, enhanced IgG4 production was associated with BAFF and IL-13 production by activated basophils [119]. These data suggest that TLR-mediated innate immune responses may play a role in the development of IgG4-RD by inducing T cell-independent IgG4 responses.

Eosinophils

Tissue eosinophilia is a histological hallmark of IgG4-RD and peripheral blood eosinophilia has been described in approximately 30% of patients with IgG4-RD [10]. This information, together with the common findings of atopy and elevated serum IgE levels in a proportion of patients, led to the premature conclusion that allergic mechanisms drive IgG4-RD [2]. However, eosinophilia and IgE elevation have also been observed in non-atopic subjects, and are probably induced by processes inherent to IgG4-RD itself (e.g. Th2 cytokines, such as IL-4 and IL-5) rather than atopy *per se* [10,102]). Either way, activated eosinophils might contribute to IgG4-RD by promoting fibrosis through the production of TGF-β, PDGF and IL-13 [120] by sustaining $IgG4^+$ plasma cell survival in inflammatory niches [88] or by up-regulating class II major histocompatibility complex (MHC) and presenting antigens to $CD4^+$ T cells [75]. These hypotheses have never been investigated to date, and the pathogenic role of eosinophils in IgG4-RD remains controversial.

Possible pathogenic model

Experimental evidence supports a pathogenic model of IgG4-RD in which B cell/T cell collaboration orchestrates a chronic, self-perpetuating immune response against a specific antigen (whether microbial, environmental or self). In this scenario, T helper cell polarization is probably determined by signals from the innate immune system, and IgG4 class-switch is aimed to dampen chronic inflammation (Fig. 5). A crucial step in the pathogenesis of IgG4-RD might, therefore, be naive T cell activation following antigen presentation by cognate antigen-specific naive or memory B cells, eosinophils or macrophages. Once activated, putative pathogenic T helper and T regulatory cells are thought to produce an inflammatory

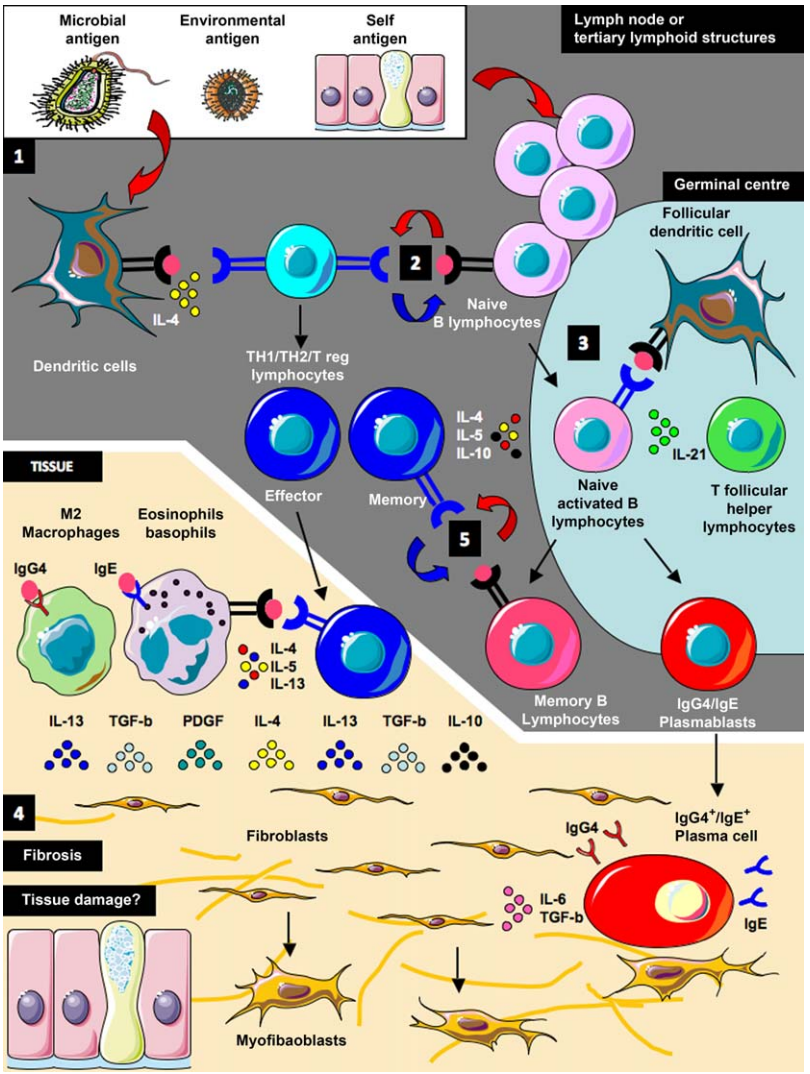

Fig. 5. Pathogenic model for immunoglobulin (Ig)G4-related disease. Antigen presentation, T cell and B cell activation presumably occur in lymph nodes or tertiary lymphoid structures originating in inflamed tissues (1). Dendritic and naive/memory B cells might present antigens to $CD4^+$ T lymphocytes triggering their activation (2). Local signals from the innate immune system might determine T helper cell polarization and differentiation into effector or memory T cells. Activated naive B cells migrate to the germinal centre where they undergo somatic hypermutation and affinity maturation, and differentiate into memory B cells or plasmablasts (3). IgG4/IgE class-switch probably occurs under the influence of cytokines produced by activated $CD4^+$ Th2 or T regulatory cells. Effector $CD4^+$ T cells migrate to inflamed tissues, where they are thought to drive the fibroinflammatory process by producing a variety of profibrotic cytokines [such as interleukin (IL)-4, IL-10, IL-13, transforming growth factor (TGF)-β], and by inducing M2 macrophages differentiation and eosinophil activation (4). IgG4 antibodies might have an antinflammatory role but, together with IgE, they might also facilitate antigen capture by innate immune cells through Fc receptor binding and presentation to T cells. In theory, $IgG4^+$ plasma cells in the tissue might also have a profibrotic role through the production of IL-6 (4). All these concomitant events lead ultimately to fibroblast activation, generation of myofibroblasts and extracellular matrix deposition. Whether the fibroinflammatory infiltrate that occurs in IgG4-RD lesions also causes tissue damage and further generation of self-antigens is not known (4). By depleting $CD20^+$ precursors, rituximab might eliminate both short-lived plasma cells and a major B cell type required for antigen presentation to T cells. This, in turn, leads to loss of activated T cells and profibrotic cytokines, and to a reduction in fibroblast activation. Disease relapse corresponds to a new plasmablast expansion, and to a renewed extracellular matrix deposition. Whether re-emerging plasmablasts observed at disease relapse differentiate *de novo* from naive B cells or from $CD20^-$ memory B cells that survive rituximab therapy is not known (5). Indeed memory B cells might *de-novo* present antigens to pathogenic naive T cells, sustaining disease recurrence (5).

cytokine milieu that includes IFN-γ, IL-4, IL-10, IL-5, IL-13 and TGF-β. IL-4 and IL-10 may drive preferential class-switch of antigen-specific B cells to IgG4 and IgE, and induce their expansion. IL-5, IL-13 and TGF-β could lead to the activation of eosinophils, fibroblasts, and alternatively activated macrophages. Activated antigen-

specific T cells may, in turn, facilitate germinal centre formation and recruitment of increasing numbers of somatically hypermutated B cell clones, thereby setting up a vicious cycle of mutual activation between B and T lymphocytes. In this sense, B cell depletion might eliminate a major cell type required for antigen presentation to T cells, leading to loss of activated T cells, reduced production of profibrotic cytokines and (ultimately) abrogation of collagen secretion by myofibroblasts. RTX might also target the precursors of short-lived plasma cells, thus leading to a rapid decline of serum IgG4 levels. In turn, disease relapse might be due to $CD20^{-}$ memory B cells that survive RTX therapy, re-present antigens to pathogenic T cells and generate re-emerging plasmablasts. Disease relapse ultimately corresponds to a renewed extracellular matrix deposition by activated fibroblasts [8].

Conclusion

IgG4-RD remains an often-overlooked clinical entity, but awareness of this new fibroinflammatory condition is increasing. In the present work we have reviewed the most recent advances pertaining to the immunopathology of IgG4-RD, and describe how the innate and the adaptive immune system might synergize to ultimately drive the characteristic fibrotic alterations observed in the affected tissues. In the last decade, substantial work has begun to dissect the mechanisms of B cell/T cell collaboration leading to aberrant IgG4 production and to tissue fibrosis. More recently, seminal work has highlighted a possible pathogenic role of macrophages and basophils, thus further complicating the oversimplified view about IgG4-RD as a B cell-/T cell-mediated disorder. Understanding the immune dysregulation that occurs in IgG4-RD will foster our knowledge about the human immune system in general and about potential therapeutic approaches for other fibrotic conditions.

Acknowledgements

The authors thank Prof. John Stone (Rheumatology Unit - Massachusetts General Hospital) for helpful input and review of the manuscript. This work was supported in part by a grant from the "Fondazione Italiana per la Ricerca sull' Artrite" (FIRA Onlus 2014).

Disclosure

The authors declare no conflicts of interest.

References

1 Hamano H, Kawa S, Horiuchi A *et al.* High serum IgG4 concentrations in patients with sclerosing pancreatitis. N Engl J Med 2011; **344**:732–8.

2 Stone JH, Zen Y, Deshpande V. IgG4-related disease. N Engl J Med 2012; **366**:539–51.

3 Deshpande V, Zen Y, Chan JK *et al.* Consensus statement on the pathology of IgG4-related disease. Mod Pathol 2012; **25**: 1181–92.

4 Umehara H, Okazaki K, Masaki Y *et al.* Comprehensive diagnostic criteria for IgG4-related disease (IgG4-RD), 2011. Mod Rheumatol 2012; **22**:21–30.

5 Kanno A, Nishimori I, Masamune A *et al.* Nationwide epidemiological survey of autoimmune pancreatitis in Japan. Pancreas 2012; **41**:835–9.

6 Carruthers MN, Topazian MD, Khosroshahi A *et al.* Rituximab for IgG4-related disease: a prospective, open-label trial. Ann Rheum Dis 2015; 74:1171–7.

7 Khosroshahi A, Bloch DB, Deshpande V, Stone JH. Rituximab therapy leads to rapid decline of serum IgG4 levels and prompt clinical improvement in IgG4-related systemic disease. Arthritis Rheum 2010; **62**:1755–62.

8 Della-Torre E, Feeney E, Deshpande V *et al.* B-cell depletion attenuates serological biomarkers of fibrosis and myofibroblast activation in IgG4-related disease. Ann Rheum Dis 2014; doi: 10.1136/annrheumdis-2014-205799.

9 Griepentrog GJ, Vickers RW, Karesh JW, Azari AA, Albert DM, Bukat CN. A clinicopathologic case study of two patients with pediatric orbital IgG4-related disease. Orbit 2013; **32**:389–91.

10 Della-Torre E, Mattoo H, Mahajan VS, Carruthers M, Pillai S, Stone JH. Prevalence of atopy, eosinophilia, and IgE elevation in IgG4-related disease. Allergy 2014; **69**:269–72.

11 Inoue D, Zen Y, Abo H *et al.* Immunoglobulin G4-related lung disease: CT findings with pathologic correlations. Radiology 2009; **251**:260–70.

12 Khan ML, Colby TV, Viggiano RW, Fonseca R. Treatment with bortezomib of a patient having hyper IgG4 disease. Clin Lymphoma Myeloma Leuk 2010; **10**:217–9.

13 Cheuk W, Chan JK. Lymphadenopathy of IgG4-related disease: an underdiagnosed and overdiagnosed entity. Semin Diagn Pathol 2012; **29**:226–34.

14 Leporati P, Landek-Salgado MA, Lupi I, Chiovato L, Caturegli P. IgG4-related hypophysitis: a new addition to the hypophysitis spectrum. J Clin Endocrinol Metab 2011; **96**:1971–80.

15 Lu LX, Della-Torre E, Stone JH, Clark SW. IgG4-related hypertrophic pachymeningitis: clinical features, diagnostic criteria, and treatment. JAMA Neurol 2014; **71**:785–93.

16 Carruthers R, Carruthers M, Della-Torre E. IgG4-related disease and other causes of inflammatory meningeal disease. Semin Neurol. 2014; **34**:395–404.

17 Reder L, Della-Torre E, Stone JH, Mori M, Song P. Clinical manifestations of IgG4-related disease in the pharynx: case series and review of the literature. Ann Otol Rhinol Laryngol 2014; **124**:173–8.

18 Tokura Y, Yagi H, Yanaguchi H *et al.* IgG4-related skin disease. Br J Dermatol 2014; **171**:959–67.

19 Dahlgren M, Khosroshahi A, Nielsen GP, Deshpande V, Stone JH. Riedel's thyroiditis and multifocal fibrosclerosis are part of the IgG4-related systemic disease spectrum. Arthritis Care Res (Hoboken) 2010; **62**:1312−18.

20 Stone JH, Khosroshahi A, Deshpande V *et al.* Recommendations for the nomenclature of IgG4-related disease and its individual organ system manifestations. Arthritis Rheum 2012; **64**: 3061–7.

21 Shimosegawa T, Chari ST, Frulloni L *et al.* International consensus diagnostic criteria for autoimmune pancreatitis: guidelines of the International Association of Pancreatology. Pancreas 2011; **40**:352–8.

22 Kamisawa T, Takuma K, Egawa N, Tsuruta K, Sasaki T. Autoimmune pancreatitis and IgG4-related sclerosing disease. Nat Rev Gastroenterol Hepatol 2010; **7**:401–9.

23 Pezzilli R, Vecchiarelli S, Di Marco MC *et al.* Pancreatic ductal adenocarcinoma associated with autoimmune pancreatitis. Case Rep Gastroenterol 2011; **5**:378–85.

24 Gupta R, Khosroshahi A, Shinagare S *et al.* Does autoimmune pancreatitis increase the risk of pancreatic carcinoma?: a retrospective analysis of pancreatic resections. Pancreas 2013; **42**:506–10.

25 Ghazale A, Chari ST, Zhang L *et al.* Immunoglobulin G4-associated cholangitis: clinical profile and response to therapy. Gastroenterology 2008; **134**:706–15.

26 Joshi D, Webster GJ. Biliary and hepatic involvement in IgG4-related disease. Aliment Pharmacol Ther 2014; **40**:1251–61.

27 Khosroshahi A, Carruthers MN, Stone JH *et al.* Rethinking Ormond's disease: 'idiopathic' retroperitoneal fi brosis in the era of IgG4-related disease. Medicine (Balt) 2013; **92**:82–91.

28 Zen Y, Onodera M, Inoue D *et al.* Retroperitoneal fibrosis: a clinicopathologic study with respect to immunoglobulin G4. Am J Surg Pathol 2009; **33**:1833–9.

29 Zen Y, Kasashima S, Inoue D. Retroperitoneal and aortic manifestations of immunoglobulin G4-related disease. Semin Diagn Pathol 2012; **29**:212–18.

30 Stone JR. Aortitis, periaortitis, and retroperitoneal fibrosis, as manifestations of IgG4-related systemic disease. Curr Opin Rheumatol 2011; **23**:88–94.

31 Wallace ZS, Deshpande V, Stone JH. Ophthalmic manifestations of IgG4-related disease: single-center experience and literature review. Semin Arthritis Rheum 2013; **43**:806–17.

32 McNab AA, McKelvie P. IgG4-related ophthalmic disease. Part I: background and pathology. Ophthal Plast Reconstr Surg 2015; **31**:83–8.

33 McNab AA, McKelvie P. IgG4-related ophthalmic disease. Part II: clinical aspects. Ophthal Plast Reconstr Surg 2015; **31**: 167–78.

34 Geyer JT, Ferry JA, Harris NL *et al.* Chronic sclerosing sialadenitis (Kuttner tumor) is an IgG4-associated disease. Am J Surg Pathol 2010; **34**:202–10.

35 Himi T, Takano K, Yamamoto M, Naishiro Y, Takahashi H. A novel concept of Mikulicz's disease as IgG4-related disease. Auris Nasus Larynx 2012; **39**:9–17.

36 Della-Torre E, Mattoo H, Mahajan VS *et al.*IgG4-related midline destructive lesion. Ann Rheum Dis 2014; **73**:1434–6.

37 Cornell LD. IgG4-related kidney disease. Semin Diagn Pathol 2012; **29**:245–50.

38 Kawano M, Mizushima I, Yamaguchi Y *et al.* Immunohistochemical characteristics of IgG4-related tubulointerstitial nephritis: detailed analysis of 20 Japanese cases. Int J Rheumatol 2012; **2012**:609795.

39 Kawano M, Saeki T, Nakashima H *et al.* Proposal for diagnostic criteria for IgG4-related kidney disease. Clin Exp Nephrol 2011; **15**:615–26.

40 Kajander H, Paavonen T, Valo T, Tarkka M, Mennander AA. Immunoglobulin G4-positive ascending thoracic aortitis may be prone to dissection. J Thorac Cardiovasc Surg 2012; **146**: 1449–55.

41 Holmes BJ, Delev ND, Pasternack GR, Halushka MK. Novel cause of sudden cardiac death: IgG4-related disease. Circulation 2012; **125**:2956–7.

42 Inoue D, Zen Y, Sato Y *et al.* IgG4-related perineural disease. Int J Rheumatol 2012; **2012**:401890.

43 Regev K, Nussbaum T, Cagnano E, Giladi N, Karni A. Central nervous system manifestation of IgG4-related disease. JAMA Neurol 2014; **71**:767–70.

44 Buijs J, Maillette de Buy Wenniger L, van Leenders G *et al.* Immunoglobulin G4-related prostatitis: a case–control study focusing on clinical and pathologic characteristics. Urology 2014; **83**:521–6.

45 Bösmüller H, von Weyhern CH, Adam P, Alibegovic V, Mikuz G, Fend F. Paratesticular fibrous pseudotumor–an IgG4-related disorder? Virchows Arch 2011; **458**:109–13.

46 Peikert T, Shrestha B, Aubry MC *et al.* Histopathologic overlap between fibrosing mediastinitis and IgG4-related disease. Int J Rheumatol 2012**;2012**:207056.

47 Salvarani C, Valli R, Boiardi L, Pipitone N, Nicoli F, Muratore F. IgG4-associated sclerosing mesenteritis. Clin Exp Rheumatol 2011; **29**:S79–80.

48 Bittencourt AG1, Pereira LV, Cabral F Jr, Halang Fde S, Gonçalves Mde C, Bento RF. IgG4-related sclerosing disease of the temporal bone. Otol Neurotol 2013; **34**:e20–1.

49 Koizumi S, Kamisawa T, Kuruma S *et al.* Immunoglobulin G4-related gastrointestinal diseases, are they immunoglobulin G4-related diseases? World J Gastroenterol 2013; **19**: 5769–74.

50 Chougule A, Bal A, Das A, Singh G. IgG4 related sclerosing mastitis: expanding the morphological spectrum of IgG4 related diseases. Pathology 2015; **47**:27–33.

51 Carruthers MN, Khosroshahi A, Augustin T, Deshpande V, Stone JH. The diagnostic utility of serum IgG4 concentrations in IgG4-related disease. Ann Rheum Dis 2014; **74**:14–8.

52 Della-Torre E, Galli L, Franciotta D *et al.* Diagnostic value of IgG4 indices in IgG4-related hypertrophic pachymeningitis. J Neuroimmunol 2013; **266**:82–6.

53 Wong PC, Fung AT, Gerrie AS *et al.* IgG4-related disease with hypergammaglobulinemic hyperviscosity and retinopathy. Eur J Haematol 2013; **90**:250–6.

54 Wallace ZS, Mattoo H, Carruthers M *et al.* Plasmablasts as a biomarker for IgG4-related disease, independent of serum IgG4 concentrations Ann Rheum Dis 2015; **74**:190–5.

55 Ebbo M, Grados A, Guedj E *et al.* Usefulness of 2-[18F]-fluoro-2-deoxy-D-glucose-positron emission tomography/computed tomography for staging and evaluation of treatment response in IgG4-related disease: a retrospective multicenter study. Arthritis Care Res (Hoboken) 2014; **66**:86–96.

56 Deshpande V, Khosroshahi A, Nielsen GP, Hamilos DL, Stone JH. Eosinophilic angiocentric fibrosis is a form of IgG4-related systemic disease. Am J Surg Pathol 2011; **35**:701–6.

57 Carruthers MN, Stone JH, Deshpande V, Khosroshahi A. Development of an IgG4-RD responder index. Int J Rheumatol 2012**;2012**:259408.

58 Khosroshahi A, Wallace ZS, Crowe J *et al.* International consensus guidance statement on the treatment of IgG4-related disease. Arthritis Rheumatol 2015; doi: 10.1002/art.39132.

59 Khosroshahi A, Stone JH. Treatment approaches to IgG4-related systemic disease. Curr Opin Rheumatol 2011; **23**:67–71.

60 Della-Torre E, Campochiaro C, Bozzolo EP *et al.* Methotrexate for maintenance of remission in IgG4-related disease. Rheumatology 2015; in press.
61 Tsuboi H, Matsuo N, Iizuka M *et al.* Analysis of IgG4 class switch-related molecules in IgG4-related disease. Arthritis Res Ther 2012; **14**:R171.
62 King C, Tangye SG, Mackay CR. T follicular helper (TFH) cells in normal and dysregulated immune responses. Annu Rev Immunol 2008; **26**:741–66.
63 Aalberse RC, Stapel SO, Schuurman J, Rispens T. Immunoglobulin G4: an odd antibody. Clin Exp Allergy 2009; **39**:469–77.
64 Rispens T, Ooijevaar–de Heer P, Bende O, Aalberse RC. Mechanism of immunoglobulin G4 Fab-arm exchange. J Am Chem Soc 2011; **133**:10302–11.
65 van der Neut Kolfschoten M, Schuurman J, Losen M *et al.* Anti-inflammatory activity of human IgG4 antibodies by dynamic Fab arm exchange. Science 2007; **317**:1554–57.
66 Aalberse RC, Schuurman J. IgG4 breaking the rules. Immunology 2002; **105**:9–19.
67 Bindon CI, Hale G, Bruggemann M, Waldmann H. Human monoclonal IgG isotypes differ in complement activating function at the level of C4 as well as C1q. J Exp Med 1988; **168**: 127–42.
68 Aalberse RC, Van Milligen F, Tan KY, Stapel SO. Allergen-specific IgG4 in atopic disease. Allergy 1993; **48**: 559–69.
69 Durham SR, Emminger W, Kapp A *et al.* Long-term clinical efficacy in grass pollen–induced rhinoconjunctivitis after treatment with SQ-standardized grass allergy immunotherapy tablet. J Allergy Clin Immunol 2010; **125**:131–8.
70 Muraki T, Hamano H, Ochi Y *et al.* Autoimmune pancreatitis and complement activation system. Pancreas 2006; **32**:16–21.
71 Holland M, Hewins P, Goodall M, Adu D, Jefferis R, Savage CO. Anti-neutrophil cytoplasm antibody IgG subclasses inWegener's granulomatosis: a possible pathogenic role for the IgG4 subclass. Clin Exp Immunol 2004; **138**:183–92.
72 Hussain A, Pankhurst T, Goodall M *et al.* Chimeric IgG4 PR3-ANCA induces selective inflammatory responses from neutrophils through engagement of Fcγ receptors. Immunology 2009; **128**:236–44.
73 Ferrari S, Mudde GC, Rieger M *et al.* IgG subclass distribution of anti-ADAMTS13 antibodies in patients with acquired thrombotic thrombocytopenic purpura. J Thromb Haemost 2009; **7**:1703–10.
74 Rock B, Martins CR, Theofilopoulos AN *et al.* The pathogenic effect of IgG4 autoantibodies in endemic pemphigus foliaceus (fogo selvagem). N Engl J Med 1989; **320**:1463–9.
75 Padigel UM, Hess JA, Lee JJ *et al.* Eosinophils act as antigen-presenting cells to induce immunity to *Strongyloides stercoralis* in mice. J Infect Dis 2007; **196**:1844–51.
76 Mattoo H, Mahajan VS, Della-Torre E *et al.* De novo oligoclonal expansions of circulating plasmablasts in active and relapsing IgG4-related disease. J Allergy Clin Immunol 2014; **134**: 679–87.
77 Okazaki K, Uchida K, Ohana M *et al.* Autoimmune-related pancreatitis is associated with autoantibodies and a Th1/Th2-type cellular immune response. Gastroenterology 2000; **118**: 573–81.
78 Aoki S, Nakazawa T, Ohara H *et al.* Immunohistochemical study of autoimmune pancreatitis using anti-IgG4 antibody and patients' sera. Histopathology 2005; **47**:147–58.
79 Nishimori I, Miyaji E, Morimoto K, Nagao K, Kamada M, Onishi S. Serum antibodies to carbonic anhydrase IV in patients with autoimmune pancreatitis. Gut 2005; **54**:274–81.
80 Aparisi L, Farre A, Gomez-Cambronero L *et al.* Antibodies to carbonic anhydrase and IgG4 levels in idiopathic chronic pancreatitis: relevance for diagnosis of autoimmune pancreatitis. Gut 2005; **54**:703–9.
81 Lohr JM, Faissner R, Koczan D *et al.* Autoantibodies against the exocrine pancreas in autoimmune pancreatitis: gene and protein expression profiling and immunoassays identify pancreatic enzymes as a major target of the inflammatory process. Am J Gastroenterol 2010; **105**:2060–71.
82 Endo T, Takizawa S, Tanaka S *et al.* Amylase α-2A autoantibodies: novel marker of autoimmune pancreatitis and fulminant type 1 diabetes. Diabetes 2009; **58**:732–7.
83 Asada M, Nishio A, Uchida K *et al.* Identification of a novel autoantibody against pancreatic secretory trypsin inhibitor in patients with autoimmune pancreatitis. Pancreas 2006; **33**: 20–6.
84 Frulloni L, Lunardi C, Simone R *et al.* Identification of a novel antibody associated with autoimmune pancreatitis. N Engl J Med 2009; **361**:2135–42.]
85 Della-Torre E, Passerini G, Furlan R *et al.* Cerebrospinal fluid analysis in immunoglobulin G4-related hypertrophic pachymeningitis. J Rheumatol 2013; **40**:1927–9.
86 Della-Torre E, Bozzolo EP, Passerini G *et al.* IgG4-related pachymeningitis: evidence of intrathecal IgG4 on cerebrospinal fluid analysis. Ann Intern Med 2012; **156**:401–3.
87 Maillette de Buy Wenniger LJ, Doorenspleet ME, Klarenbeek PL *et al.* Immunoglobulin G4+ clones identified by next-generation sequencing dominate the B cell receptor repertoire in immunoglobulin G4 associated cholangitis. Hepatology 2013; **57**:2390–8.
88 Hiepe F, Dörner T, Hauser AE, Hoyer BF, Mei H, Radbruch A. Long-lived autoreactive plasma cells drive persistent autoimmune inflammation. Nat Rev Rheumatol 2011; **7**: 170–8.
89 Harada Y, Kawano MM, Huang N *et al.* Identification of early plasma cells in peripheral blood and their clinical significance. Br J Haematol 1996; **92**:184–91.
90 Odendahl M, Jacobi A, Hansen A *et al.* Disturbed peripheral B lymphocyte homeostasis in systemic lupus erythematosus. J Immunol 2000; **165**:5970–9.
91 Fink K. Origin and function of circulating plasmablasts during acute viral infections. Front Immunol 2012; **3**:1.
92 Jacobi AM, Odendahl M, Reiter K *et al.* Correlation between circulating CD27high plasma cells and disease activity in patients with systemic lupus erythematosus. Arthritis Rheum 2003; **48**:1332–42.
93 Odendahl M, Keitzer R, Wahn U *et al.* Perturbations of peripheral B lymphocyte homoeostasis in children with systemic lupus erythematosus. Ann Rheum Dis 2003; **62**: 851–8.
94 Kerkman PF, Rombouts Y, van der Voort EI *et al.* Circulating plasmablasts/plasmacells as a source of anticitrullinated protein antibodies in patients with rheumatoid arthritis. Ann Rheum Dis 2013; **72**:1259–63.

95 van de Veen W, Stanic B, Yaman G *et al.* IgG4 production is confined to human IL-10-producing regulatory B cells that suppress antigen-specific immune responses. J Allergy Clin Immunol 2013; **131**:1204–12.
96 Sumimoto K, Uchida K, Kusuda T *et al.* The role of CD19+ CD24high CD38high and CD19+ CD24high CD27+ regulatory B cells in patients with type 1 autoimmune pancreatitis. Pancreatology 2014; **14**:193–200.
97 François A, Chatelus E, Wachsmann D *et al.* B lymphocytes and B-cell activating factor promote collagen and profibrotic markers expression by dermal fibroblasts in systemic sclerosis. Arthritis Res Ther 2013; **15**:R168.
98 Lighaam LC, Aalberse RC, Rispens T. IgG4-related fibrotic diseases from an immunological perspective: regulators out of control? Int J Rheumatol 2012**;2012**:789164.
99 Sato S, Hayakawa I, Hasegawa M, Fujimoto M, Takehara K. Function blocking autoantibodies against matrix metalloproteinase-1 in patients with systemic sclerosis. J Invest Dermatol 2003; **120**:542–7.
100 Mahajan VS, Mattoo H, Deshpande V *et al.* IgG4-related disease. Annu Rev Pathol 2014; **9**:315–47.
101 Wynn TA. Fibrotic disease and the TH1/TH2 paradigm. Nat Rev Immunol 2004; **4**:583–94.
102 Mattoo H, Della-Torre E, Mahajan VS, Stone JH, Pillai S. Circulating Th2 memory cells in IgG4-related disease are restricted to a defined subset of subjects with atopy. Allergy 2014; **69**:399–402.
103 Miyoshi H, Uchida K, Taniguchi T *et al.* Circulating naïve and CD4+CD25high regulatory T cells in patients with autoimmune pancreatitis. Pancreas 2008; **36**:133–40.
104 King C, Tangye SG, Mackay CR. T follicular helper (TFH) cells in normal and dysregulated immune responses. Annu Rev Immunol 2008; **26**:741–66.
105 Maehara T, Moriyama M, Nakashima H *et al.* Interleukin-21 contributes to germinal centre formation and immunoglobulin G4 production in IgG4-related dacryoadenitis and sialoadenitis, so-called Mikulicz's disease. Ann Rheum Dis 2012; **71**: 2011–9.
106 Jordan S, Distler JH, Maurer B *et al.* Effects and safety of rituximab in systemic sclerosis: an analysis from the European Scleroderma Trial and Research (EUSTAR) group. Ann Rheum Dis 2014; **74**:1188–94.
107 Keir GJ, Maher TM, Ming D *et al.* Rituximab in severe, treatment-refractory interstitial lung disease. Respirology 2014; **19**:353–9.
108 Castillo-Trivino T, Braithwaite D, Bacchetti P, Waubant E. Rituximab in relapsing and progressive forms of multiple sclerosis: a systematic review. PLOS ONE 2013; **8**:e66308.
109 Crawford A, Macleod M, Schumacher T, Corlett L, Gray D. Primary T cell expansion and differentiation *in vivo* requires antigen presentation by B cells. J Immunol 2006; **176**:3498–506.
110 Pillai S, Mattoo H, Cariappa A. B cells and autoimmunity. Curr Opin Immunol 2011; **23**:721–31.
111 Barr TA, Shen P, Brown S *et al.* B cell depletion therapy ameliorates autoimmune disease through ablation of IL-6-producing B cells. J Exp Med 2012; **209**:1001–10.
112 Gordon S. Alternative activation of macrophages. Nat Rev Immunol 2003; **3**:23–35.
113 Wynn TA, Barron L. Macrophages: master regulators of inflammation and fibrosis. Semin Liver Dis 2010; **30**:245–57.
114 Furukawa S, Moriyama M, Tanakaa A *et al.* Preferential M2 macrophages contribute to fibrosis in IgG4-related dacryoadenitis and sialoadenitis, so-called Mikulicz's disease. Clin Immunol 2015; **156**:9–18.
115 Watanabe T, Yamashita K, Fujikawa S *et al.* Activation of toll-like receptors and NOD-like receptors is involved in enhanced IgG4 responses in autoimmune pancreatitis. Arthritis Rheum 2012; **64**:914–24.
116 Sokol CL, Medzhitov R. Role of basophils in the initiation of Th2 responses. Curr Opin Immunol 2010; **22**:73–7.
117 Paul WE, Zhu J. How are T(H)2-type immune responses initiated and amplified? Nat Rev Immunol 2010; **10**:225–35.
118 Chen K, Xu W, Wilson M *et al.* Immunoglobulin D enhances immune surveillance by activating antimicrobial, proinflammatory and B cell-stimulating programs in basophils. Nat Immunol 2009; **10**:889–98.
119 Watanabe T, Yamashita K, Sakurai T *et al.* Toll-like receptor activation in basophils contributes to the development of IgG4-related disease. J Gastroenterol 2013; **48**:247–53.
120 Huaux F, Liu T, McGarry B, Ullenbruch M, Xing Z, Phan SH. Eosinophils and T lymphocytes possess distinct roles in bleomycin-induced lung injury and fibrosis. J Immunol 2003; **171**: 5470–81.