

Management of Intraosseous Vascular Malformations of the Jaws in Children and Adolescents: Report of 6 Cases and Literature Review

Nadia Theologie-Lygidakis¹, Ourania Schoinohoriti¹, Fotios Tzermpos¹, Panos Christopoulos¹, Ioannis Iatrou¹

¹Department of Oral and Maxillofacial Surgery, "P. & A. Kyriakou" Children's Hospital, University of Athens, Greece.

Corresponding Author:

Ourania Schoinohoriti
21 Panourgia street, 15343, Agia Paraskevi, Athens
Greece
Phone: +30 210 6049977 / +30 6944676630
Fax: +30 210 6613703
E-mail: our_schoinohoriti@yahoo.com

ABSTRACT

Background: Intraosseous vascular malformations represent a rare clinical entity of the facial skeleton. The purpose of the current study was to present our experience in a Greek paediatric population and propose guidelines for the treatment of these jaws anomalies in children and adolescents.

Methods: A retrospective study (from 2009 to 2014) was performed to investigate the features and management of the intraosseous vascular anomalies in a Greek paediatric population.

Results: Six patients aged between 6 and 14 years were treated for intraosseous vascular malformations (4 venous and 2 arteriovenous) of the jaws. Five lesions were located in the mandible and one in the maxilla. In four lesions with pronounced vascularity superselective angiography, followed by embolization was performed. Individualized surgical treatment, depending on the size and vascularity of the lesions was applied in 4 patients.

Conclusions: The intraosseous vascular malformations of the jaws may escape diagnosis in paediatric patients. A multidisciplinary approach is important for their safe and efficient treatment. Embolization is recommended for extended high-flow lesions, either preoperatively or as a first-line treatment, when surgery is not feasible without significant morbidity.

Keywords: adolescent; bones and bone; children; embolization therapeutic; humans; vascular malformations.

Accepted for publication: 6 February 2015

To cite this article:

Theologie-Lygidakis N, Schoinohoriti O, Tzermpos F, Christopoulos P, Iatrou I. Management of Intraosseous Vascular Malformations of the Jaws in Children and Adolescents: Report of 6 Cases and Literature Review

J Oral Maxillofac Res 2015;6(2):e5

URL: <http://www.ejomr.org/JOMR/archives/2015/2/e5/v6n2e5.pdf>

doi: [10.5037/jomr.2015.6205](https://doi.org/10.5037/jomr.2015.6205)

INTRODUCTION

The International Society for the Study of Vascular Anomalies (ISSVA) classification system divides vascular anomalies into vascular neoplasms and vascular malformations. The major distinction between them is the existence of an increased endothelial cell turnover (vascular neoplasms), which is ultimately determined by identifying mitoses on histopathology. Vascular malformations do not increase the endothelial cell turnover, since they represent structural abnormalities of the capillary, venous, lymphatic and arterial system and are subdivided into slow- or low- and fast- or high- flow malformations. Low-flow malformations contain combinations of capillary, venous and lymphatic components [1].

The intraosseous vascular anomalies (IVAs) are rare conditions that account only 0.5 - 1% of all intraosseous lesions [2-6]. Their identification and treatment has been hindered by a confusing and largely descriptive nomenclature [1,6,7]. The term “intraosseous hemangioma” has been used indiscriminately for intraosseous lesions, including both hemangiomas and vascular malformations [6-9]. No well-documented cases of intraosseous hemangiomas involving the facial skeleton have been reported, but lesions described as such are predominantly venous (low-flow) and less commonly arteriovenous (high-flow) malformations [8,10-15]. Recently, the immunohistochemical marker GLUT-1 has been used to objectively differentiate hemangiomas (GLUT-1 positive) from vascular malformations (GLUT-1 negative) [15-17].

Further confusion occurs from the need to differentiate vascular anomalies “primarily” involving bones from those, located in soft tissues but inducing secondary skeletal changes [7]. The former,

originating into the medullar bone and growing towards the cortex, have been described as “central” or “intraosseous”; the latter, originating within the periosteal vessels and growing into the medullar bone, have been described as “peripheral” [4]. The aim of this study was to report our 5-year experience in the management of intraosseous vascular malformations of the jaws in children and adolescents, highlighting the diagnostical difficulties, as well as the challenge of their conclusive treatment in this particular age group.

CASES DESCRIPTIONS AND RESULTS

The files of all patients, treated for intraosseous vascular anomalies of the jaws at the Department of Oral and Maxillofacial Surgery, “P. & A. Kyriakou” Children’s Hospital, University of Athens, Greece, between January 2009 and January 2014, were retrospectively reviewed.

The term intraosseous vascular malformations (IVMs) was preferred to describe all vascular malformations in the mandible or the maxilla, centrally or peripherally located.

Six (1 male and 5 female) patients (age range 6 - 14 years, mean age 11.33) were included in the current study (this study has been reviewed and approved by the local Research Ethics Committee). Of our sample, patient number 3 was operated upon twice before referral to our Department. Patient number 2 was submitted to surgical excision of a pyogenic granuloma at the anterior mandible, three years before being referred to us, for an IVM, located at the same site. Data of patients are summarized in Table 1. Five lesions were located at the mandible and a single one at the maxilla. Among these lesions, four were centrally located within the medullar bone (patients number 1, 3, 4 and 6) and two periosteal lesions had a cortex infiltration and expansion towards

Table 1. Summarized data of the paediatric patients

Patient number	Age (years)	Gender	Location	Max diameter (cm)	Treatment	Histology	Follow-up
1	13	Male	Left mandible	3.2	Coil embolization + peripheral mandibulectomy	Venous malformation	5 years
2	13	Female	Anterior mandible	2.4	Resection-extractions + reconstruction with graft + PDGF + membrane	Venous malformation	3 years
3	14	Female	Right mandible	8.2	PVA embolization + hemi-mandibulectomy + reconstruction plate	Venous malformation	2 years
4	13	Female	Right mandible	3.1	Onyx® embolization (twice)	Arteriovenous malformation	2 years
5	6	Female	Right maxilla	2	Resection	Venous malformation	1 year
6	9	Female	Right mandible	6.8	1) PVA embolization 2) Onyx® embolization (twice)	Arteriovenous malformation	6 months

the medullar bone (patients number 2 and 5). All patients presented minor to considerable cortex expansion and particularly in two patients (number 3 and 6) this expansion caused facial deformity. Teeth mobility was noted in all patients, apart from patient number 3, who had already been submitted to multiple extractions and patient number 5, who suffered from a localized peripheral lesion. Gingival swelling and spontaneous bleeding was registered in five patients, except one case (patient number 3). In patient number 6, the lesion had also infiltrated the buccal and submandibular soft tissues.

All patients had been submitted to orthopantomograms (OPGs) and in 4 patients (number 1, 2, 3 and 6) computed tomography (CT) scans were performed and not well delineated lesions, involving the medullar and cortical bone of the jaws, compatible with IVMs, were revealed. The diameter of the lesions, measured from OPGs and/or CT scans, ranged from 2 to 8.2 cm (Table 1). In lesions with pronounced vascularity (patient number 1, 3, 4 and 6) biopsies were attempted unsuccessfully due to profuse intraoperative haemorrhage. Superselective angiography, followed by embolization was performed in 4 patients. Specifically, calibrated poly-vinyl alcohol (PVA) microspheres (255 - 350 µm in diameter), coil and Onyx® embolization was performed. The treatment included:

- Peripheral mandibulectomy or maxillectomy through intraoral approach, i.e. removing the alveolar process along with the related teeth (small lesions, 2 - 2.4 cm in diameter) (patients number 2 and 5);
- Embolization following selective angiography and peripheral mandibulectomy or maxillectomy through intraoral approach (moderate lesions, 3.2 - 3.3 cm) (patient number 1);
- Embolization and hemimandibulectomy through extraoral approach, followed by immediate reconstruction with a 2.5 mm plate (extended lesion, 8.2 cm) (patient number 3);
- Repeated courses of embolization without surgical treatment followed in patients suffering from arteriovenous malformations, the resection of which was not feasible without significant morbidity (patients number 4 and 6).

Simple closure of the adjoining soft tissues was performed in patients number 1 and 5. The patient number 3 was treated with soft tissue advancement to cover the inserted reconstruction plate and patient number 2 was submitted to guided bone regeneration with a bone heterograft lined with a membrane. A summarized presentation of patients number 1, 3 and 4, demonstrating the different treatment approach, appears in Figures 1 - 3.

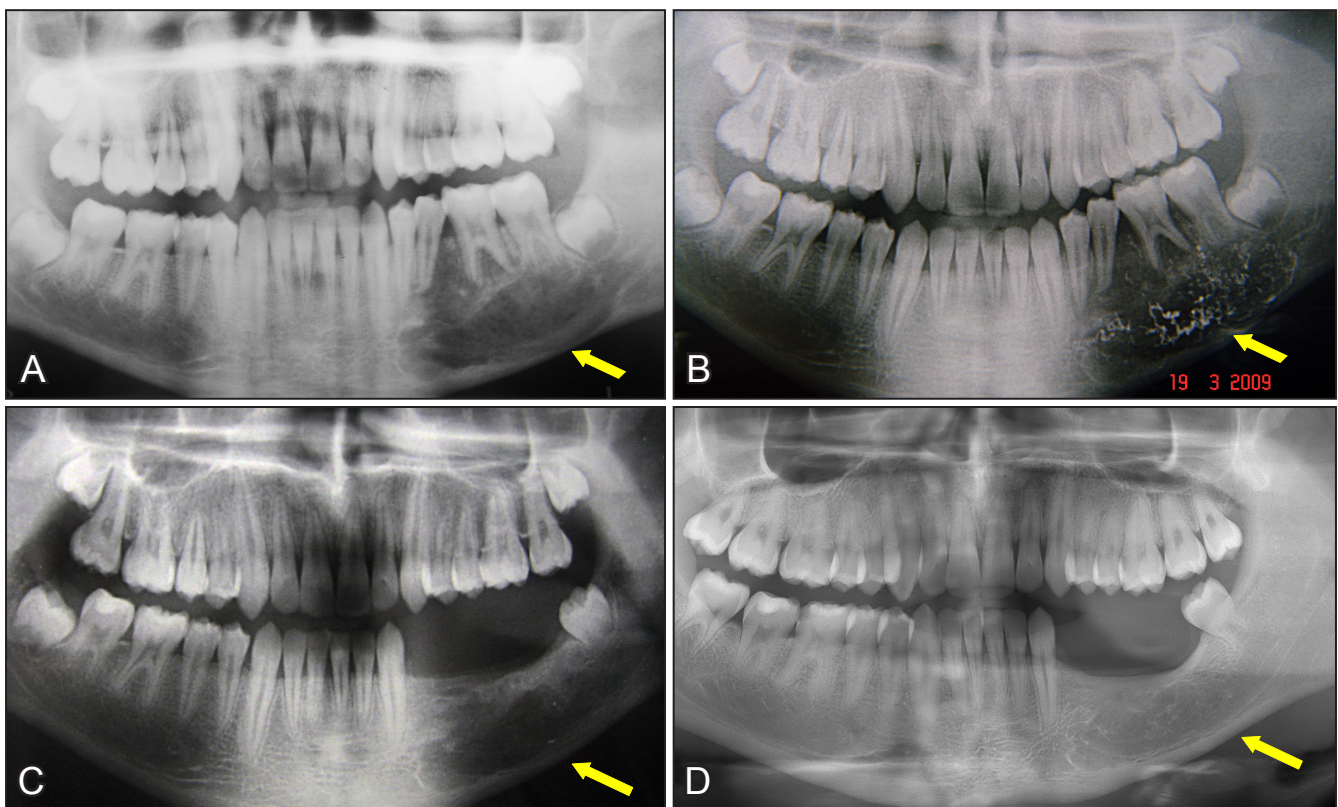


Figure 1. A = initial orthopantomogram of the patient number 1, showing an ill-defined IVA located at the left side of the mandibular body; B = orthopantomogram, directly after embolization with coils; C = 2 months after peripheral mandibulectomy; D = 5-years postoperatively, showing complete rehabilitation of the osseous defect.

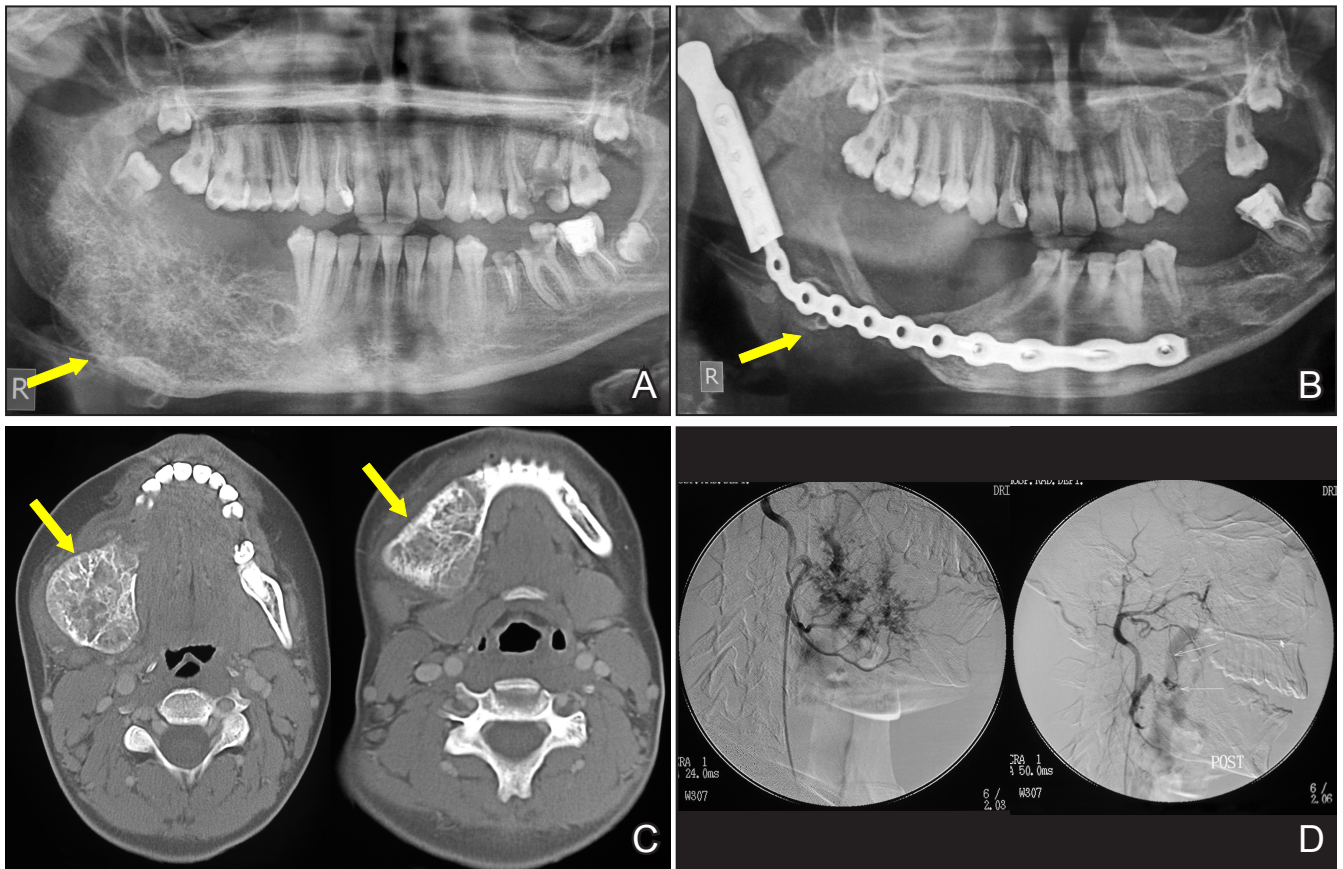


Figure 2. A = initial orthopantomogram of the patient number 3, showing an ill-defined extended IVA at the right side of the mandible; B = orthopantomogram, 20 months after hemimandibulectomy and reconstruction with a 2.5 mm plate (notice the bone growth along the plate); C = initial computed tomography scans of the same patient; D = lateral view with digital subtraction arteriography of the right common carotid artery: left - before embolization, right - after embolization with PVA particles.

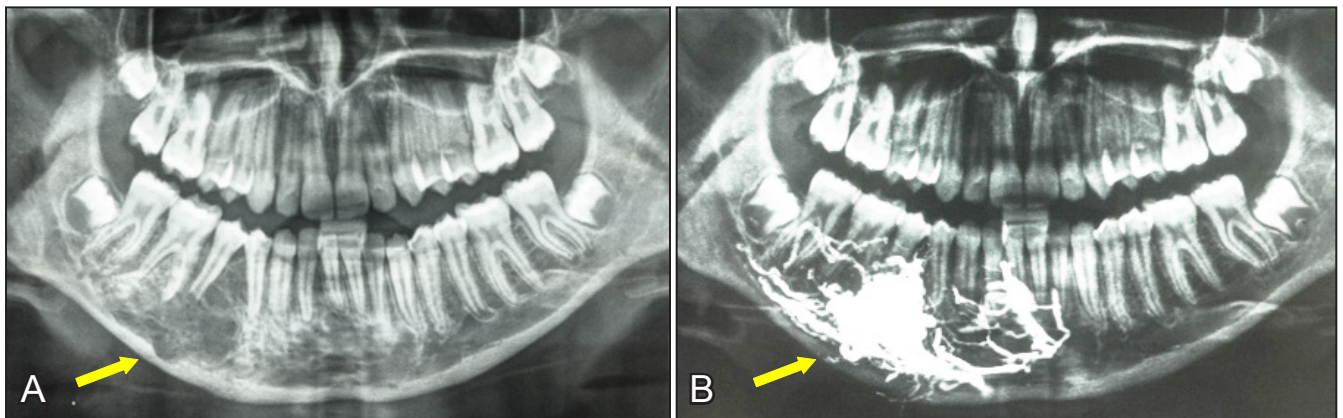


Figure 3. A = initial orthopantomogram of the patient number 4, showing an extended, ill-defined IVA at the right mandibular body; B = orthopantomogram of the same patient, directly after embolization with Onyx®, showing compact lodgement of the embolic agent in the varix.

No postoperative complications were encountered and the healing was uneventful; the functional and aesthetic outcome was satisfactory in all cases. The histopathological examination of the resected specimens revealed 4 IVMs (patients number 1, 2, 3 and 5) and 2 AVMs (patients number 4 and 6) (Table 1). Prosthetic devices to restore missing teeth were placed in cases 1 and 2. All patients remain under follow-up without significant findings to the day.

DISCUSSION

Vascular anomalies represent a heterogenous group of clinicopathologically distinct entities, the understanding of which is of immense significance for their accurate diagnosis and subsequent appropriate treatment [1,18]. The nomenclature proposed by Mulliken and Glowacki [19] in 1982 was later

modified by the ISSVA and subsequently widely adopted [1,18]. According to this classification, vascular anomalies comprise tumours (lesions with proliferative endothelium) and malformations (lesions with structural anomalies); the latter are subdivided to simple (venous, lymphatic, capillary and arterial) and combined (arteriovenous) malformations. However, the ISSVA classification has not been applied for the categorization of IVAs [20].

The IVAs mostly occur in the vertebral column and may be diagnosed during the 4th - 5th decade of life, with a female to male ratio of 2-3:1 [5,8,21,22]. Although vascular anomalies often affect the soft tissues of the maxillofacial region, they are rarely encountered within the facial bones; only few cases, afflicting the mandible, maxilla, zygomatic, nasal or frontal bones have been described [2,3,6,12,21,23-25]. These have been predominantly venous malformations (VMs) and rarely arteriovenous malformations (AVMs) [18]. The VMs are the most common type of intraosseous lesions, composed of atypical venous vessels of various size and wall thickness, potentially involuting into adipose tissue or degenerative smooth muscle after local thrombosis [6,18]. Intraosseous AVMs, approximately 50% of which are encountered in the head and neck region, represent abnormal shunts between arteries and veins, with the blood flow bypassing the capillary bed and thus downregulating local blood pressure; enlarged venous channels downstream are referred to as the nidus of the malformation [26,27]. Among our patients VMs (4 cases) represented the most common histological diagnosis, followed by AVMs (2 cases).

Despite their hamartomatous origin (congenital background), the IVMs may escape diagnosis over long periods of time due to their clinical course and deep location within the bones or may be misdiagnosed because of their non-specific clinical and imaging findings [2,4,18,21]. Although VMs and AVMs have common pathophysiology, their clinical manifestations and imaging features are significantly different, thus warranting a distinct diagnostic and therapeutic approach for each type of lesions [18].

The IVMs usually appear as slowly growing painless masses but may produce various functional and aesthetic signs and symptoms, depending on their location and extension. For instance, hemifacial pain has been reported particularly in zygomatic lesions [9]. Discomfort and expansion due to venous engorgement, local thrombosis or thrombophlebitis, limited haemorrhage and a mass effect have also been observed [18]. The VMs of the jaws typically appear as indolent bulging masses that rarely cause tooth displacement and mobility, root and bone resorption,

asymmetry of dental arches, or severe haemorrhage after dental treatment (scaling, root planning, extractions etc.) or biopsy [6]. Swelling as a response to stimuli (trauma, thrombosis, infection) or related to estrogens throughout puberty and pregnancy has been reported [28].

On the other hand, high-flow AVMs represent the most aggressive vascular malformation because of their ability to produce life-threatening massive haemorrhage after minimal oral or dental trauma and their extremely high recurrence rate [6,18,29,30]. Lesions stable for a long period of time may exhibit an explosive growth potential during pregnancy and puberty or after hormonal change, trauma or surgery [18,28-30]. Facial asymmetry with excess growth of the involved bone, gingival discoloration and tooth mobility constitute the typical triad of signs of intraosseous AVMs of the jaws. Pain and lower lip hypoesthesia are commonly encountered, whereas bruits or pulsation are evident when sufficiently sized IVMs have eroded the alveolar cortex [6,18].

In the current series, cortical expansion was mostly minor (1 patient) to moderate (3 patients), but in 2 patients it was so conspicuous that it produced facial asymmetry. Mild to moderate teeth mobility and occlusal changes were recorded in all patients, with the exception of one, who had already undergone multiple extractions and another patient, suffering from a localized VM. Minor and recurrent spontaneous gingival bleeding was noted in all patients, except a patient that had been submitted to extractions. Profuse haemorrhage during biopsy was encountered in 4 patients, compelling us to abort the procedure.

The initial diagnosis of IVMs is often complicated because of their non-specific imaging findings [2,4,21,29]. Orthopantomograms present non-specific uni- or multi-locular radiolucent areas resembling cysts or exhibit honeycombed, reticular or sunburst patterns; roots of the adjacent teeth can be absorbed [22,31]. CT scan was the preferred imaging modality for IVMs, as it allows assessing and staging of AVMs and helps the visualization of the cortical involvement and the depiction of relationship with surrounding soft tissues of both VMs and AVMs [18,21]: VMs may show “sunburst”, reticular or multilocular “soap bubble” patterns with relatively intact cortices and usually enhance homogeneously with a contrast medium; AVMs appear as radiolucent masses, lacking clear borders and showing intense capitation, within the lesion and adjacent blood vessels with contrast, with or without visible nidus depending on the size of the channels [18]. Angiography may reveal normal flow in VMs and is considered of limited value [18].

On the contrary, it yields valuable haemodynamic information for AVMs, indicating the extent of vascular involvement, showing the feeding and draining vessels and occasionally revealing a nidus or fistula that represents the hallmark of AVMs; therefore, a careful angiographic investigation of AVMs is useful for the treatment planning [2,5,8,10,18,31,32]. In the present series, superselective angiography was performed in 4 patients with moderate or large lesions (2 AVMs and 2 VMs), to clarify their extension, vascular architecture and flow characteristics. Although the histopathological examination identified 2 VMs among these lesions, their pronounced vascularity that led to profuse bleeding during biopsy, induced angiographic investigation mainly with the prospect of performing embolization, to avoid massive haemorrhage during resection.

The management of IVMs of the jaws is complex, depending on the size, location and flow characteristics of the lesion and the patient's functional compromise and age. In addition, an integrated team approach involving maxillofacial surgeons, interventional radiologists and critical care intensivists may be required [6,33-36]. In our patients, size and vascularity of the lesions were the determining factors for the treatment: surgery was considered safe and efficient for small lesions without pronounced vascularity; for larger lesions with increased vascularity, the preoperative embolization was considered mandatory, before removing the affected bone. Finally, for two extended AVMs with extremely pronounced vascularity, the embolization was performed as a first-line therapeutic intervention to limit the symptoms and avoid major and potentially threatening haemorrhage; however, the young patients remain under follow-up and the conclusive treatment (resection and reconstruction) will be scheduled in due time in the future, depending on the evolution of the lesions and the patients' needs.

Endovascular embolization of IVMs is effective to either cure or reduce the size and minimize the risk of intraoperative haemorrhage, especially in larger or high-flow lesions, such as AVMs [2,9,10,14,18,22,37]. Numerous embolic agents (PVA particles, acrylic glue, Onyx[®], coils and various combinations) have been used with varying efficiency [33-35,38,39]. The PVA particles injected directly into the arterial flow are arrested within the lesion, creating a transitory focal devascularisation [38]. Acrylic glue is a liquid embolic agent with long-lasting results after its injection into the lesion [34,38]. Onyx[®] (ethylene vinyl alcohol copolymer with dimethyl sulfoxide and tantalum) is a liquid hydrophilic and non-

adhesive embolic agent that is used in the treatment of extracranial AVMs [39,40]. Transosseous direct puncture embolization of AVMs with various agents has been attempted alternatively or adjunctively with encouraging results [30].

In the present case series, the embolic agent type was decided by the interventional radiologist, based on his experience and on the findings of superselective angiography (lesion type, vascular architecture, flow velocity and microcatheter position). Coils, PVA and Onyx[®] were the selected embolic agents. In two lesions with moderate size, the embolization was performed adjunctively 36 - 48 hours before surgery, to control the intraoperative haemorrhage.

The surgical treatment of both intraosseous VMs and AVMs consists ideally in *en bloc* surgical removal including healthy surrounding bone, with ligation of the nutritional vessels, if recognizable [2,4,5,10,18,21-23,32]. Aggressive curettage has been proposed as a conservative first-line approach for the treatment of VMs of the jaws in young patients but for AVMs it is warranted only when resection cannot be performed without significant morbidity and the lesion has not infiltrated the bony cortices [18]. However, radical surgery of high-flow lesions has been associated with significant morbidity and mortality due to massive blood loss; especially in paediatric patients wide resection of IVMs of the jaws may be associated with growth disturbance, functional compromise (due to teeth extractions and neurosensory disturbances) and cosmetic deformity [18,33,38]. Therefore, it has been advocated that wide *en bloc* resection, leading to facial mutilation and necessitating massive reconstruction should be avoided, at least as first-line therapy [34]. In this series wide *en bloc* resection requiring hemimandibulectomy, was considered mandatory only in one patient, who exhibited recurrent symptoms and signs after having been operated twice before referral to our Department. A more conservative surgical approach (partial removal of the alveolar process with the related teeth) was applied in 3 cases, either with (1 case) or without (2 cases) preoperative embolization; this was considered preferable to avoid mutilation and preserve the growth potential of the maxillofacial skeleton, while successfully stabilizing the lesion and controlling symptoms. The immediate reconstruction after wide resection is indicated to regain or preserve facial symmetry and contour [2,5,22-25,30,32,36]. Many reconstructive modalities, including autogenous bone and numerous alloplastic materials, have been used with varying efficiency [2,5,7,22,23,30,34,41]. In the current series, immediate reconstruction was selected in two cases: in the first patient a reconstruction

plate was placed as initial treatment, followed by autogenous bone grafting, whereas in the second patient a bone heterograft lined with a membrane was placed.

CONCLUSIONS

Given their rarity and non-specific clinical and radiographic characteristics, the intraosseous vascular malformations of the jaws may escape diagnosis in the paediatric population, thus enhancing the risk of spontaneous or intraoperative severe bleeding. Multidisciplinary approach is important for their treatment. Endovascular embolization

is recommended in extended high-flow lesions, either preoperatively or as a first-line therapeutic strategy, when surgery cannot be applied without significant morbidity. Wide *en bloc* resection necessitating extensive reconstruction should only be considered following preparation in selected paediatric cases.

ACKNOWLEDGMENTS AND DISCLOSURE STATEMENTS

The authors have no conflicts of interest related to this study to report. No external funding, apart from the support of the authors' institution, was available for this study.

REFERENCES

1. North PE. Pediatric Vascular Tumors and Malformations. *Surg Pathol Clin*. 2010 Sept; 3(3):455-94. [doi: [10.1016/j.path.2010.07.002](https://doi.org/10.1016/j.path.2010.07.002)]
2. Perugini M, Renzi G, Gasparini G, Cerulli G, Becelli R. Intraosseous hemangioma of the maxillofacial district: Clinical analysis and surgical treatment in 10 consecutive patients. *J Craniofac Surg*. 2004 Nov; 15(6):980-5. [Medline: [15547387](https://pubmed.ncbi.nlm.nih.gov/15547387/)]
3. Alves S, Junqueira JL, de Oliveira EM, Pieri SS, de Magalhães MH, Dos Santos Pinto D Jr., Mantesso A. Condylar hemangioma: report of a case and review of the literature. *Oral Surg Oral Med Oral Pathol Oral Radiol Endod*. 2006 Nov;102(5):e23-7. Epub 2006 Sep 7. [Medline: [17052619](https://pubmed.ncbi.nlm.nih.gov/17052619/)] [doi: [10.1016/j.tripleo.2006.04.004](https://doi.org/10.1016/j.tripleo.2006.04.004)]
4. Cheng NC, Lai DM, Hsie MH, Liao SL, Chen YB. Intraosseous hemangiomas of the facial bone. *Plast Reconstr Surg*. 2006 Jun;117(7):2366-72. [Medline: [16772943](https://pubmed.ncbi.nlm.nih.gov/16772943/)]
5. Arribas-Garcia I, Alcalá-Galiano A, Garcia AF, Montalvo JJ. Zygomatic intraosseous haemangioma: Reconstruction with an alloplastic prosthesis based on a 3-D model. *J Plast Reconstr Aesthet Surg*. 2010 May;63(5):e451-3. [Medline: [19700378](https://pubmed.ncbi.nlm.nih.gov/19700378/)] [doi: [10.1016/j.bjps.2009.07.033](https://doi.org/10.1016/j.bjps.2009.07.033)]
6. Aldridge E, Cunningham LL Jr., Gal TJ, Yepes JF, Abadi BJ. Intraosseous venous malformation of the mandible: a review on interdisciplinary differences in diagnostic nomenclature for vascular anomalies in bone and report of a case. *J Oral Maxillofac Surg*. 2012 Feb;70(2):331-9. [Medline: [21798650](https://pubmed.ncbi.nlm.nih.gov/21798650/)] [doi: [10.1016/j.joms.2011.03.013](https://doi.org/10.1016/j.joms.2011.03.013)]
7. Kaban LB, Mulliken JB. Maxillofacial vascular anomalies. In: Kaban LB, Troulis MJ. *Pediatric Oral and Maxillofacial Surgery*. Philadelphia: Saunders, Elsevier,; 2004. p. 259-85.
8. Ramchandani PL, Sabesan T, Mellor TK. Intraosseous vascular anomaly (haemangioma) of the zygoma. *Br J Oral Maxillofac Surg*. 2004 Dec;42(6):583-6. [Medline: [15544895](https://pubmed.ncbi.nlm.nih.gov/15544895/)] [doi: [10.1016/j.bjoms.2004.06.016](https://doi.org/10.1016/j.bjoms.2004.06.016)]
9. Srinivasan B, Ethunandan M, Van der Horst C, Markus AF. Intraosseous 'haemangioma' of the zygoma: More appropriately termed a venous malformation. *Int J Oral Maxillofac Surg*. 2009 Oct;38(10):1066-70. [Medline: [19574025](https://pubmed.ncbi.nlm.nih.gov/19574025/)] [doi: [10.1016/j.ijom.2009.05.010](https://doi.org/10.1016/j.ijom.2009.05.010)]
10. Siniscalchi EN, Minutoli F, Catalfamo L, Romano F, Longo M, De Ponte FS. Intraosseous mandibular arteriovenous malformations: Case report. *J Craniofac Surg*. 2009 Mar;37(2):106-9. [Medline: [19027310](https://pubmed.ncbi.nlm.nih.gov/19027310/)] [doi: [10.1016/j.jcms.2008.10.004](https://doi.org/10.1016/j.jcms.2008.10.004)]
11. Vargel I, Cil BE, Er N, Ruacan S, Akarsu AN, Erk Y. Hereditary intraosseous vascular malformation of the craniofacial region: an apparently novel disorder. *Am J Med Genet*. 2002 Apr 15;109(1):22-35. [Medline: [11932989](https://pubmed.ncbi.nlm.nih.gov/11932989/)] [doi: [10.1002/ajmg.10282](https://doi.org/10.1002/ajmg.10282)]
12. Kaban LB, Mulliken JB. Vascular anomalies of the maxillofacial region. *J Oral Maxillofac Surg*. 1986 Mar;44(3):203-13. [Medline: [3456442](https://pubmed.ncbi.nlm.nih.gov/3456442/)] [doi: [10.1016/0278-2391\(86\)90109-6](https://doi.org/10.1016/0278-2391(86)90109-6)]
13. Greene AK, Rogers GF, Mulliken B. Intraosseous "Haemangiomas" are malformations and not tumors. *Plast Reconstr Surg*. 2007 May;119(6):1949-50; author reply 1950. [Medline: [17440384](https://pubmed.ncbi.nlm.nih.gov/17440384/)] [doi: [10.1097/01.prs.0000259768.59590.5a](https://doi.org/10.1097/01.prs.0000259768.59590.5a)]
14. Brusati R, Galioto S, Biglioli F, Goisis M. Conservative treatment of arteriovenous malformations of the mandible. *Int J Oral Maxillofac Surg*. 2001 Oct;30(5):397-401. [Medline: [11720041](https://pubmed.ncbi.nlm.nih.gov/11720041/)] [doi: [10.1054/ijom.2001.0120](https://doi.org/10.1054/ijom.2001.0120)]
15. Boye E, Jinnin M, Olsen BR. Infantile hemangioma: Challenges, new insights and therapeutic promise. *J Craniofac Surg*. 2009 Mar;20 Suppl 1:678-84. [Medline: [19190505](https://pubmed.ncbi.nlm.nih.gov/19190505/)] [doi: [10.1097/SCS.0b013e318193d6c1](https://doi.org/10.1097/SCS.0b013e318193d6c1)]
16. Leon-Villalpalos J, Wolfe K, Kangesu L. GLUT1: an extra diagnostic tool to differentiate between haemangiomas and vascular malformations. *Br J Plast Surg*. 2005 Apr;58(3):348-52. [Medline: [15780229](https://pubmed.ncbi.nlm.nih.gov/15780229/)] [doi: [10.1016/j.bjps.2004.05.029](https://doi.org/10.1016/j.bjps.2004.05.029)]
17. Enjolras O, Soupre V, Picard A. Classification des anomalies vasculaires superficielles. *Presse Med*. 2010 Apr;39(4): 457-64. [doi: [10.1016/j.lpm.2009.07.029](https://doi.org/10.1016/j.lpm.2009.07.029)]

18. Colletti G, Frigerio A, Giovanditto F, Biglioli F, Chiapasco M, Grimmer JF. Surgical treatment of vascular malformations of the facial bones. *J Oral Maxillofac Surg.* 2014 Jul;72(7):1326.e1-18. [Medline: [24768420](#)] [doi: [10.1016/j.joms.2014.02.012](#)]
19. Mulliken JB, Glowacki J. Hemangiomas and vascular malformations in infants and children: a classification based on endothelial characteristics. *Plast Reconstr Surg.* 1982 Mar;69(3):412-22. [Medline: [7063565](#)] [doi: [10.1097/00006534-198203000-00002](#)]
20. Bruder E, Perez-Atayde AR, Jundt G, Alomari AI, Rischewski J, Fishman SJ, Mulliken JB, Kozakewich HP. Vascular lesions of bone in children, adolescents, and young adults. A clinicopathologic reappraisal and application of the ISSVA classification. *Virchows Arch.* 2009 Feb;454(2):161-79. [Medline: [19107514](#)] [doi: [10.1007/s00428-008-0709-3](#)]
21. Oliveira GG, García-Rozado A, Rey RL. Intraosseous mandibular hemangioma. A case report and review of the literature. *Med Oral Patol Oral Cir Bucal.* 2008 Aug 1;13(8):E496-8. [Medline: [18667983](#)]
22. Valentini V, Nicolai G, Lorè B, Aboh IV. Intraosseous hemangiomas. *J Craniofac Surg.* 2008 Nov; 19(6):1459-64. [Medline: [19098533](#)] [doi: [10.1097/SCS.0b013e318188a030](#)]
23. Zins JE, Türegün MC, Hosn W, Bauer TW. Reconstruction of intraosseous hemangiomas of the midface using split calvarial bone grafts. *Plast Reconstr Surg.* 2006 Mar;117(3):948-53; discussion 954. [Medline: [16525289](#)] [doi: [10.1097/01.prs.0000204768.82643.0c](#)]
24. Persky MS, Yoo HJ, Berenstein A. Management of vascular malformations of the mandible and maxilla. *Laryngoscope.* 2003 Nov; 113(11):1885-92. [Medline: [14603041](#)] [doi: [10.1097/00005537-200311000-00005](#)]
25. Theologie-Lygidakis N, Schoinohoriti OK, Tzerbos F, Iatrou I. Surgical management of head and neck vascular anomalies in children: a retrospective analysis of 42 patients. *Oral Surg Oral Med Oral Pathol Oral Radiol.* 2014 Jan;117(1):e22-31. Epub 2012 Aug 24. [Medline: [22921448](#)] [doi: [10.1016/j.oooo.2012.02.039](#)]
26. Churojana A, Khumtong R, Songsaeng D, Chongkolwatana C, Suthipongchai S. Life-threatening arteriovenous malformation of the maxillomandibular region and treatment outcomes. *Interv Neuroradiol.* 2012 Mar;18(1):49-59. [Medline: [22440601](#)] [PMC free article: [3312089](#)] [doi: [10.1177/159101991201800107](#)]
27. McCafferty IJ, Jones RG. Imaging and management of vascular malformations. *Clin Radiol.* 2011 Dec;66(12):1208-18. [Medline: [21944775](#)] [doi: [10.1016/j.crad.2011.06.014](#)]
28. Burns AJ, Navarro JA, Cooner RD. Classification of vascular anomalies and the comprehensive treatment of hemangiomas. *Plast Reconstr Surg.* 2009 Jul;124(1 Suppl):69e-81e. [Medline: [19568141](#)] [doi: [10.1097/PRS.0b013e3181aa1015](#)]
29. Oueis H, Geist JR, Tran MU, Stenger J. High-flow arteriovenous malformations of the mandible and the maxilla: report of 2 cases. *Pediatr Dent.* 2010 Sep-Oct;32(5):451-6. [Medline: [21070715](#)]
30. Lemound J, Brachvogel P, Götz F, Rücker M, Gellrich NC, Eckardt A. Treatment of mandibular high-flow vascular malformations: report of 2 cases. *J Oral Maxillofac Surg.* 2011 Jul;69(7):1956-66. Epub 2011 Jan 8. [Medline: [21216076](#)] [doi: [10.1016/j.joms.2010.09.013](#)]
31. Fernández LR, Luberti RF, Domínguez FV. Radiographic features of osseous hemangioma in the maxillofacial region. Bibliographic review and case report. *Med Oral.* 2003 May-Jul;8(3):166-77. [Medline: [12730651](#)]
32. Drage NA, Whaites EJ, Hussain K. Hemangioma of the body of the mandible: a case report. *Br J Oral Maxillofac Surg.* 2003 Apr;41(2):112-4. [Medline: [12694704](#)] [doi: [10.1016/S0266-4356\(03\)00002-0](#)]
33. Kademani D, Costello BJ, Ditty D, Quinn P. An alternative approach to maxillofacial arteriovenous malformations with transosseous direct puncture embolization. *Oral Surg Oral Med Oral Pathol Oral Radiol Endod.* 2004 Jun;97(6):701-6. [Medline: [15184851](#)] [doi: [10.1016/j.tripleo.2003.12.031](#)]
34. Liu D, Ma X, Zhao F, Zhang J. Intraosseous embolotherapy of central arteriovenous malformations in the jaw: long-term experience with 8 cases. *J Oral Maxillofac Surg.* 2009 Nov;67(11):2380-7. [Medline: [19837306](#)] [doi: [10.1016/j.joms.2009.04.088](#)]
35. Kawano K, Mizuki H, Mori H, Yanagisawa S. Mandibular arteriovenous malformation treated by transvenous coil embolization: a long-term follow-up with special reference to bone regeneration. *J Oral Maxillofac Surg.* 2001 Mar;59(3):326-30. [Medline: [11243618](#)] [doi: [10.1053/joms.2001.21005](#)]
36. Wu JH, Du JK, Lu PC, Chen CM. Interdisciplinary management of mandibular intraosseous haemangioma. *Br J Oral Maxillofac Surg.* 2011 Oct;49(7):e55-7. [Medline: [21398000](#)] [doi: [10.1016/j.bjoms.2011.01.014](#)]
37. Giaoui L, Princ G, Chiras J, Guilbert F, Bertrand JC. Treatment of vascular malformations of the mandible: a description of 12 cases. *Int J Oral Maxillofac Surg.* 2003 Apr;32(2):132-6. [Medline: [12729771](#)] [doi: [10.1054/ijom.2002.0268](#)]
38. Rodesch G, Soupre V, Vazquez MP, Alvarez H, Lasjaunias P. Arteriovenous malformations of the dental arcades. The place of endovascular therapy: results in 12 cases are presented. *J Craniofac Surg.* 1998 Oct;26(5):306-13. [Medline: [9819681](#)]
39. Eivazi B, Werner JA. Management of vascular malformations and hemangiomas of the head and neck—an update. *Curr Opin Otolaryngol Head Neck Surg.* 2013 Apr;21(2):157-63. [Medline: [23486379](#)] [doi: [10.1097/MOO.0b013e3182835e15a9](#)]
40. Jahan R, Murayama V, Gobin YP, Duckwiler GR, Vinters HV, Vi-uela F. Embolization of arteriovenous malformations with Onyx: clinicopathological experience in 23 patients. *Neurosurgery.* 2001 May;48(5):984-95; discussion 995-7. [Medline: [11334300](#)]

41. Lee J, Sung HM, Jang JD, Park YW, Min SK, Kim EC. Successful reconstruction of 15-cm segmental defects by bone marrow stem cells and resected autogenous bone graft in central hemangioma. *J Oral Maxillofac Surg.* 2010 Jan;68(1):188-94. [Medline: [20006176](#)] [doi: [10.1016/j.joms.2009.08.031](#)]
-

To cite this article:

Theologie-Lygidakis N, Schoinohoriti O, Tzermpos F, Christopoulos P, Iatrou I. Management of Intraosseous Vascular Malformations of the Jaws in Children and Adolescents: Report of 6 Cases and Literature Review.

J Oral Maxillofac Res 2015;6(2):e5

URL: <http://www.ejomr.org/JOMR/archives/2015/2/e5/v6n2e5.pdf>

doi: [10.5037/jomr.2015.6205](#)

Copyright © Theologie-Lygidakis N, Schoinohoriti O, Tzermpos F, Christopoulos P, Iatrou I. Published in the JOURNAL OF ORAL & MAXILLOFACIAL RESEARCH (<http://www.ejomr.org>), 30 June 2015.

This is an open-access article, first published in the JOURNAL OF ORAL & MAXILLOFACIAL RESEARCH, distributed under the terms of the [Creative Commons Attribution-Noncommercial-No Derivative Works 3.0 Unported License](#), which permits unrestricted non-commercial use, distribution, and reproduction in any medium, provided the original work and is properly cited. The copyright, license information and link to the original publication on (<http://www.ejomr.org>) must be included.