

Flow-through anastomosis using a T-shaped vascular pedicle for gracilis functioning free muscle transplantation in brachial plexus injury

Yi Hou, Jiantao Yang, Yi Yang, Bengang Qin, Guo Fu, Xiangming Li, Liqiang Gu*, Xiaolin Liu, Qingtang Zhu, Jian Qi

The First Affiliated Hospital of Sun Yat-sen University, Department of Microsurgery, Orthopedic Trauma, and Hand Surgery, Guangzhou, China

OBJECTIVE: In gracilis functioning free muscle transplantation, the limited caliber of the dominant vascular pedicle increases the complexity of the anastomosis and the risk of vascular compromise. The purpose of this study was to characterize the results of using a T-shaped vascular pedicle for flow-through anastomosis in gracilis functioning free muscle transplantation for brachial plexus injury.

METHODS: The outcomes of patients with brachial plexus injury who received gracilis functioning free muscle transplantation with either conventional end-to-end anastomosis or flow-through anastomosis from 2005 to 2013 were retrospectively compared. In the flow-through group, the pedicle comprised a segment of the profunda femoris and the nutrient artery of the gracilis. The recipient artery was interposed by the T-shaped pedicle.

RESULTS: A total of 46 patients received flow-through anastomosis, and 25 patients received conventional end-to-end anastomosis. The surgical time was similar between the groups. The diameter of the arterial anastomosis in the flow-through group was significantly larger than that in the end-to-end group (3.87 mm vs. 2.06 mm, respectively, $p < 0.001$), and there were significantly fewer cases of vascular compromise in the flow-through group (2 [4.35%] vs. 6 [24%], respectively, $p = 0.019$). All flaps in the flow-through group survived, whereas 2 in the end-to-end group failed. Minimal donor-site morbidity was noted in both groups.

CONCLUSIONS: Flow-through anastomosis in gracilis functioning free muscle transplantation for brachial plexus injury can decrease the complexity of anastomosis, reduce the risk of flap loss, and allow for more variation in muscle placement.

KEYWORDS: Brachial plexus injury; Functioning free muscle transplantation; Flow-through anastomosis; Gracilis muscle; T-shaped pedicle.

Hou Y, Yang J, Yang Y, Qin B, Fu G, Li X, et al. Flow-through anastomosis using a T-shaped vascular pedicle for gracilis functioning free muscle transplantation in brachial plexus injury. *Clinics*. 2015;70(8):544-549

Received for publication on February 10, 2015; First review completed on March 30, 2015; Accepted for publication on May 12, 2015

E-mail: guliqiang1963@aliyun.com

*Corresponding author

INTRODUCTION

Traumatic brachial plexus injury (BPI) is a severe and devastating condition observed in up to 4.2% of multitrauma victims (1). Although transfer of multiple nerves has shown satisfactory results for traumatic BPI (2-5), the management of total BPI, or brachial plexus avulsion, is challenging. Functioning free muscle transplantation (FFMT) with or without transfer of multiple nerves has been increasingly accepted as an important option for achieving functional reconstruction (6-11).

FFMT consists of the surgical transplantation of normal muscle with neurovascular anastomosis to replace a destroyed or denervated muscle. FFMT has been used to restore upper limb function following traumatic BPI (12), muscle loss or denervation (13), Volkmann's ischemic contracture (14), and tumor resection (15). In contrast to common free cutaneous or musculocutaneous flap transfer, FFMT aims to restore function rather than to provide simple wound coverage and soft tissue repair. In essence, FFMT is a vascularized free tissue transfer, and many factors can adversely affect the outcomes of flaps, especially including failure of the vascular anastomosis (16). Therefore, reliable anastomosis of blood vessels is one of the most important prerequisites for successful FFMT.

The gracilis muscle is the donor muscle most widely used in FFMT, and the limited caliber of the vascular pedicle is problematic. In particular, the diameter of the gracilis artery is only 1.0 mm to 2.5 mm (17-19), which

Copyright © 2015 CLINICS – This is an Open Access article distributed under the terms of the Creative Commons License (<http://creativecommons.org/licenses/by/4.0/>) which permits unrestricted use, distribution, and reproduction in any medium or format, provided the original work is properly cited.

No potential conflict of interest was reported.

DOI: 10.6061/clinics/2015(08)03



causes difficulty in finding matched-size recipient vessels and which also limits blood flow at the site of anastomosis. Thus, FFMT using the gracilis muscle is susceptible to vascular compromise. Moreover, BPI associated with vascular injury is not uncommon. The concomitant vascular damage, although insidious, often involves the commonly used arterial branches in the recipient limb, leading to less-than-optimal vascular anastomosis and an increased failure risk in FFMT. An anastomosis method other than the conventional end-to-end or side-to-side method is thus needed to decrease the risk of gracilis flap failure in FFMT.

Flow-through anastomosis uses a T-shaped vascular pedicle to bridge the recipient blood vessels. Flaps with a flow-through design were originally used in complex trauma surgery and malignant tumor resection, which require simultaneous wound coverage and blood vessel repair. By using a T-shaped vascular pedicle, injured or deficient vessels at the recipient site can be repaired via circulation through the flap while the flap is simultaneously revascularized by the recipient blood vessels. Foucher et al. (20) first reported a flow-through flap in 1984, and Costa et al. (21) reported 1-stage coverage and revascularization of traumatized limbs using a flow-through flap in 1991. Since that time, the technique has been widely applied in trauma surgery to achieve wound coverage and vascular repair in one stage (22-24). In addition, due to its versatility, the flow-through technique has been used in various free flap transfers to increase blood inflow, decrease overall resistance, and capture more variant perforators (25-30). However, there are few reports of this technique's use with FFMT.

Thus, the purpose of this study was to compare the results of flow-through anastomosis with those of traditional end-to-end anastomosis in gracilis FFMT used for the repair of traumatic BPI.

METHODS

Patients

The cases of consecutive patients with traumatic BPI treated with gracilis FFMT at our center from 2005 to 2013 were retrospectively reviewed. The criteria for inclusion in this study were patients with traumatic BPI who received FFMT using the gracilis muscle as the donor muscle. Patients with traumatic muscle loss and those who received FFMT using muscles other than the gracilis as the donor muscle were excluded. At the beginning of the study period, we used traditional end-to-end vascular anastomosis when performing FFMT, whereas in the later part of the study period, we used the flow-through technique; thus, patients were divided into a traditional anastomosis group and a flow-through anastomosis group.

Data regarding patient age and gender, the etiology of the injury, the harvest time, the total operation time, vascular compromise and other postoperative complications, and donor-site complications were collected from the medical records. The data were specifically collected from the medical records by a physician who was not involved in the study and who was not aware of which type of anastomosis was performed. As is routine in our department, two groups of surgeons began preparation of the donor site and recipient site simultaneously. The operation time was defined as the time from incision to wound closure, and the

harvest time was defined as the time from incision to complete isolation of the muscle. The study was approved by the Institutional Review Board of the hospital, and all patients provided written informed consent for the surgical procedure performed and for their images and data to be used for research purposes.

Surgical technique

All of the FFMTs were performed by a single senior professor and his team, including a resident and an attending physician. Each patient was placed in the supine position with hip joint flexion, abduction, and external rotation and knee joint flexion. In this position, the adductor longus could be palpated in the medial thigh. Additionally, a line was drawn along the prominence from the pubic tubercle to the medial knee to indicate the anterior boarder of the gracilis muscle, and the skin flap overlying the gracilis muscle was marked (Figure 1).

An incision was made along the anterior boarder of the skin flap, and dissection between the adductor longus and the gracilis was performed, preserving the fascia surrounding the gracilis. The dominant pedicle and motor nerve were identified beneath the adductor longus (Figure 2A); however, the neurovascular pedicle was not dissected at this time. Next, the incision was extended to the insertion of the gracilis, and the posterior border of the skin flap was incised. The gracilis was then isolated from adductor longus anterolaterally and from the adductor magus posterolaterally.

With the adductor longus retracted anteriorly, the vascular pedicle of the gracilis was exposed and dissected, and the branches to the adductor longus, brevis, and magnus were ligated. The nerve branches of the muscle were also identified (Figure 2B). The adductor longus was also retracted posteromedially so that the artery pedicle could be traced to its origin at the profunda femoris. A 2 cm to 3 cm segment of the profunda femoris was then isolated and cut (Figure 2C). A T-shaped artery pedicle comprising the profunda femoris and the nutrient artery of the gracilis was harvested, and the venae comitantes of the nutrient artery were also harvested from their origin. The profunda femoris arterial segment had an obviously larger caliber (Figure 2D). After dividing the motor nerve, the gracilis was harvested.

Incisions in the upper limb were performed based on the aim of reconstruction. The recipient artery, which was usually the brachial artery, axillary artery, or radial artery, was divided and interposed with the T-shaped pedicle, with both ends anastomosed (Figure 3). The venae comitantes of the gracilis were also anastomosed with the matched recipient veins in an end-to-end fashion. If there were 2 venae comitantes, they were anastomosed with the superficial and deep venous systems, respectively (Figure 3C). When only a single vena comitans was present, only one anastomosis was performed. In the end-to-end anastomosis group, a single arterial end-to-end anastomosis was performed. The spinal accessory nerve was the first choice for nerve innervation in both groups. For patients whose spinal accessory nerves were unavailable, intercostal nerves, the medial brachial cutaneous nerve, and a bundle of ulnar nerves reinnervated by CC7 were utilized.

Postoperative care and follow-up

Postoperatively, the patients were administered antibiotics to prevent infection and were also given anticoagulation and anticonvulsant treatments. Plaster splints were applied for

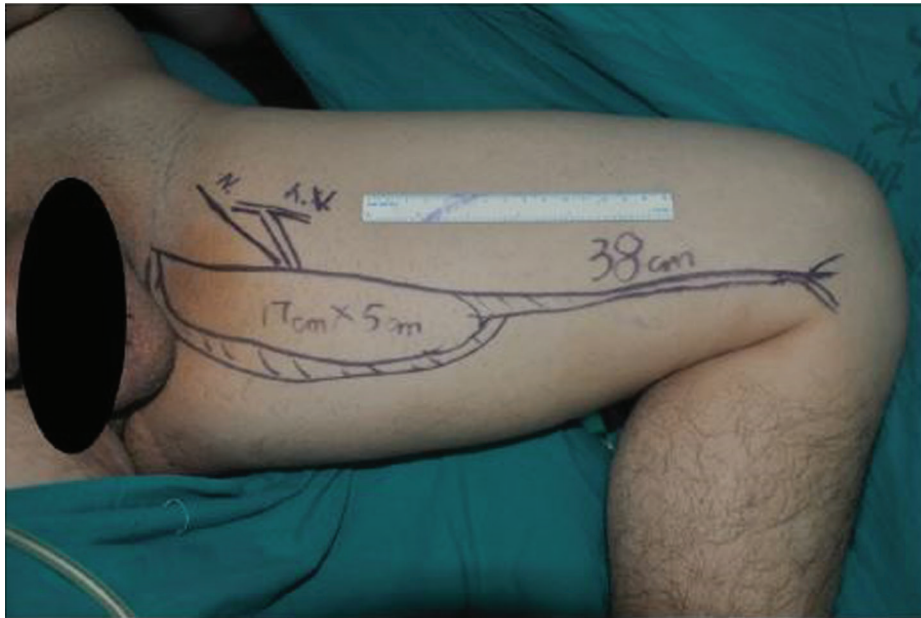

Figure 1 - Design of the gracilis musculocutaneous flap

6 weeks after surgery, and passive functional exercises were begun immediately after surgery. The rehabilitation protocol comprised acupuncture, moxibustion, and electrical stimulation.

Donor-site discomfort and dysfunction were evaluated 1 year after the FFMT. Subjective donor-site discomfort was specifically evaluated using a questionnaire adapted from

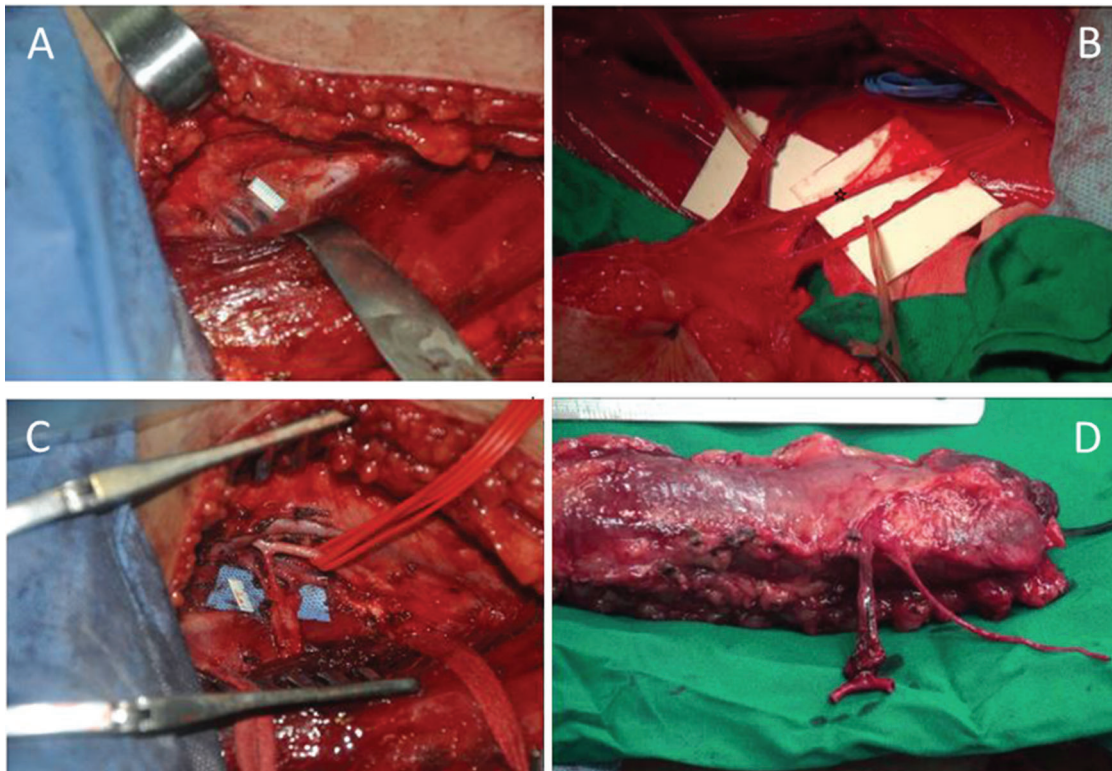

Figure 2 - Intraoperative images - A) Exposure of the dominant vascular pedicle. To avoid injury during the operation, the pedicle was not dissected at first. **B)** The neurovascular pedicle of the gracilis. Note that the sensory nerve branch (☆) must be resected to ensure enough motor nerve fiber regeneration (a, b). **C)** Exposure of the profunda femoris. A segment of the profunda femoris was prepared. It is unnecessary to perform a long dissection. **D)** The T-shaped arterial pedicle of the gracilis musculocutaneous flap (flap placed with the skin paddle downward).

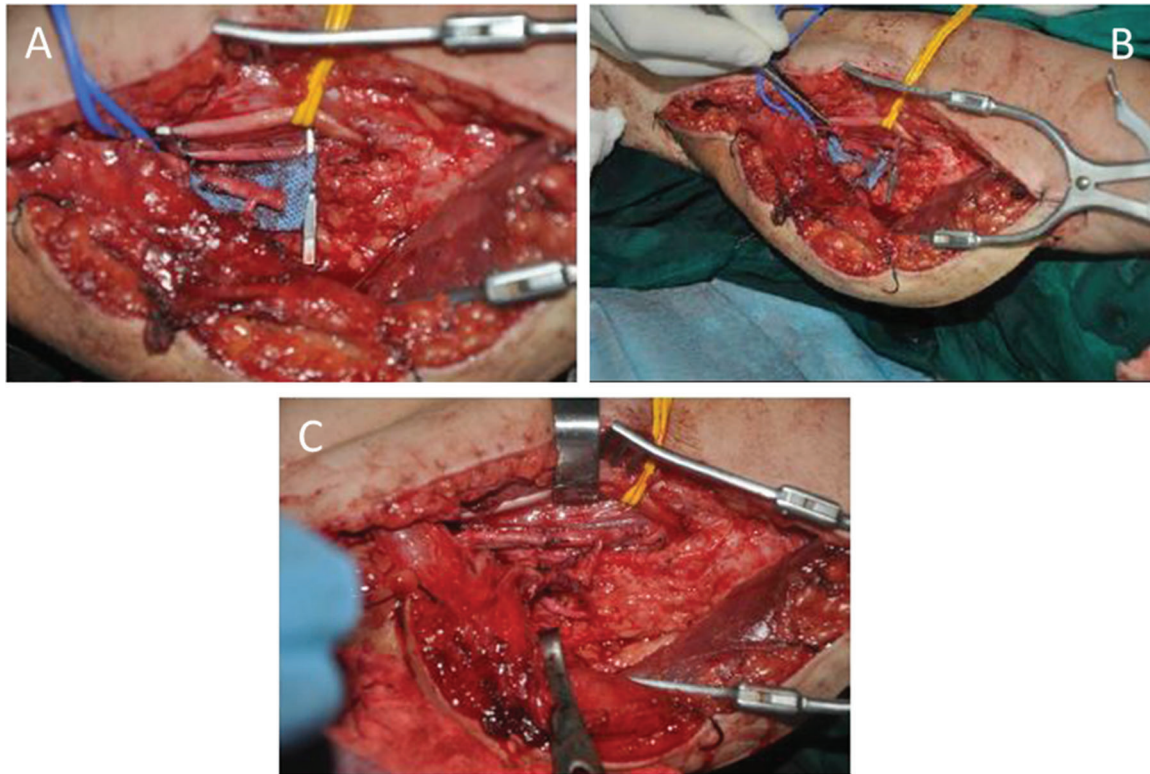


Figure 3 - Flow-through anastomosis of the T-shaped pedicle - A) The diameter of the profunda femoris segment is obviously larger than that of the nutrient artery of the gracilis. **B)** The brachial artery was resected, and the diameters of the segment profunda femoris and brachial artery were well matched. **C)** Interposed anastomosis to bridge the brachial artery. Two veins were anastomosed in direct end-to-end fashion.

that of Carr et al. (31). Briefly, donor-site symptoms were classified into 11 grades, with 0 defined as no discomfort; 1 to 9, as increasing degrees of discomfort; and 10, as unbearable discomfort.

Statistical analysis

Continuous variables are presented as the mean \pm standard deviation (SD) and were compared using independent-sample t-tests. Categorical variables are expressed as a number and percentage and were compared using Fisher's exact test. A two-tailed $p < 0.05$ was considered statistically significant. All analyses were performed using SPSS Version 20 (SPSS Statistics V20, IBM Corporation, Somers, New York).

RESULTS

A total of 71 patients treated with FFMT for traumatic BPI due to a motorcycle accident, a machine injury, or a crush injury were included in the analysis. A total of 46 patients received flow-through anastomosis, and 25 patients received conventional end-to-end anastomosis; these 2 groups were comparable with respect to age and sex (both $p > 0.05$; Table 1). The purpose of reconstruction for the patients in the flow-through group was to restore elbow flexion and finger extension ($n=33$), to restore elbow flexion and finger flexion ($n=12$), or to restore elbow extension ($n=1$). In the end-to-end group, the goal of reconstruction was to restore elbow flexion and finger extension ($n=21$) or to restore elbow flexion ($n=4$). In the flow-through group, the recipient vessels included

32 brachial arteries, five axillary arteries, and nine radial arteries. In the end-to-end group, the recipient vessels included four circumflex humeral arteries, six brachial artery branches, six axillary artery branches, three deep brachial artery branches, and two thoracoacromial arteries.

As shown in Table 1, the harvest time ($p=0.167$), total operation time ($p=0.721$), and donor-site score ($p=0.288$) were similar between the two groups. The diameter of the arterial anastomosis in the flow-through group was significantly larger than that in the end-to-end group (3.87 ± 0.42 mm vs. 2.06 ± 0.44 mm, respectively, $p < 0.001$), and there were significantly fewer cases of vascular compromise in the flow-through group (2 [4.35%] vs. 6 [24%], respectively, $p=0.019$). Moreover, in the flow-through group, there were two cases of reversible venous spasms, and the flaps were salvaged after re-exploration. In contrast, in the end-to-end group, there were six cases of vascular compromise, including one case of venous spasm, four of venous thrombosis, and one of arterial thrombosis; four flaps were salvaged, whereas two failed.

In addition, one patient in the flow-through group and two in the end-to-end group developed donor-site hematomas that resolved with local care. However, no adduction muscle strength loss was noted at 1 year after surgery in either group, as determined by a manual muscle strength test. The donor-site scores were similar between the two groups (Table 1), and no scores of 3 or more were noted in either group. Discomfort included itching, numbness, and hyperesthesia around the scar. However, all discomfort was easily bearable and did not affect the activities of daily life.



Table 1 - Patient characteristics and outcomes

	Flow-through group (n=46)	End-to-end anastomosis group (n=25)	p-value
Age (y)	27.85 ± 8.80	26.44 ± 7.94	0.508
Gender, male	44 (95.6)	24 (96)	0.718
Harvest time (min)	98.67 ± 9.16	101.52 ± 6.02	0.167
Total operation time (min)	400.11 ± 73.14	408.20 ± 98.74	0.721
Diameter of arterial anastomosis* (mm)	3.87 ± 0.42	2.06 ± 0.44	<0.001
Vascular compromise	2 (4.35)	6 (24)	0.019
Donor-site score	1.09 ± 0.69	0.88 ± 0.67	0.228

*The diameter was measured once the vessels were mobilized during surgery. The data are expressed as a number (percentage) or the mean ± standard deviation.

DISCUSSION

We have performed FFMT for brachial plexus avulsion since 2005, and end-to-end vascular anastomosis was initially used. As the technique evolved, we adopted flow-through vascular anastomosis for the procedure. In the present study, we compared the results of gracilis FFMT for traumatic BPI using flow-through or end-to-end anastomosis. The results showed that the diameter of the arterial anastomosis in the flow-through group was significantly larger than that in the end-to-end group. Additionally, there were significantly fewer cases of vascular compromise and less flap failure in the flow-through anastomosis group, whereas the operation time and donor-site morbidity were similar between the groups.

The treatment of BPI is challenging, especially if there is complete avulsion of the brachial plexus. Limited donor nerve for nerve transfer and long distances to the target muscle are the main obstacles. For certain patients, FFMT is the only choice for the restoration of limb function. In these cases, FFMT failure would be catastrophic. The reported success rate of free tissue transplantation ranges from 91% to 99%, with the majority of failures being due to technical errors with vessel anastomosis, such as a mismatch of vessels (16). Generally, small vessels are more vulnerable to thrombosis than large-diameter vessels are, and a T-shaped vascular pedicle can afford a larger vessel for anastomosis.

Although primarily used in trauma with main artery injury, application of the flow-through technique has been extended to various situations without vascular injury. For example, Haffey et al. (25) reported a flow-through anterolateral thigh free flap that could capture vascular perforators from separate sources, regardless of the vascular branching pattern of the pedicle. Moreover, Kawamura et al. (27) reported the feasibility of harvesting a flow-through flap from the scapular region, and Koshima et al. (28) reported a flow-through free anterolateral or anteromedial thigh flap with a wide but short vascular pedicle to avoid problems associated with variation and to shorten the operation time, with good results. Thus, the versatility of the technique has been clearly shown, laying the foundation for its application in FFMT.

The gracilis muscle has a type II blood supply system (32). The dominant pedicle enters the muscle 6 to 10 cm inferior to the pubic tubercle, with one or two minor pedicles entering the muscle approximately 20 cm inferior to the pubis. The muscle can survive by relying only on the dominant vascular pedicle, and the caliber of the dominant pedicle is 1 to 2.5 mm (17). The dominant artery generally originates from the profunda femoris (33), although certain authors have reported that it originates from the medial circumflex femoral artery (34). Regardless of the origin, both the profunda

femoris and the medial circumflex femoral artery can be easily identified and well matched with a recipient artery.

The most important advantage of a T-shaped vascular pedicle is the large caliber, and there are unique advantages to using this technique in FFMT. Miyamoto et al. (35) revealed that a flow-through flap allowed greater blood flow into the flap through the anastomotic site than end-to-end and end-to-side anastomoses did. For FFMT, increased blood flow is particularly advantageous for intramuscular blood circulation during the early stage after surgery. Extra dissection to identify an anonymous recipient artery is unnecessary because of matching with the brachial, axillary, or radial artery. This approach successfully avoids problems due to previous vascular injury and also allows for variation of the insertion point of the transplanted muscle, without restriction due to inconvenient recipient vessel positioning. Additionally, the vascular system of the recipient site can be kept intact, which reduces the risk of additional ischemia if recipient vessels must be sacrificed.

There are, however, several unresolved issues with the application of a T-shaped venous pedicle. Ichinose et al. (36) noted that dual venous anastomosis of separate venous systems is conducive to reducing the risk of flap failure and affords protection against venous catastrophe through a self-compensating mechanism. There are one or two venae comitantes in the gracilis vascular pedicle, and with flow-through venous anastomosis, drainage occurs through a single venous system. Therefore, when there are two venae comitantes, it is recommended that they be respectively anastomosed with branches from the deep and superficial venous systems. Conversely, if only one vena comitans is present, flow-through venous anastomosis is recommended due to the advantages of the large caliber.

In the present study, less vascular compromise was observed with flow-through anastomosis; the increased inflow not only supplies oxygen-rich blood but also improves the outflow of venous blood (35). This is likely the reason that significantly less vascular crisis occurred in the flow-through group, even though only the artery underwent flow-through anastomosis. Due to abundant communication in the femoral arterial system in the thigh, ischemia of the lower limb after sacrifice of the profunda femoris is rare. In our study, no ischemic necrosis or contracture of the muscles at the donor site occurred, and no obvious decrease in muscle strength was observed.

There are no specific contraindications for the use of flow-through anastomosis with a T-shaped arterial pedicle in FFMT. However, caution must be exercised in patients with a history of vascular injury to the femoral artery. Computed tomography angiography (CTA) may be useful for assessing



blood flow in the femoral artery system preoperatively. In addition, the method is not recommended if the ipsilateral gracilis is chosen as the donor muscle; due to the relative locations of the donor and recipient vessels, folding and twisting of the vascular pedicle is likely to occur.

The primary limitations of this report are the relatively small number of patients and the retrospective nature of the study. Traumatic muscle loss is also an important indication for FFMT; however, we limited this study to patients without muscle loss to reduce the influence of this variable on the results. Lastly, we did not include data on the long-term outcomes of the surgery because the purpose of this report was to examine the effect of the flow-through technique on flap survival.

The use of flow-through anastomosis in gracilis FFMT for BPI can decrease the complexity of anastomosis and reduce the risk of flap loss. The technique allows for a recipient artery to be chosen such that muscle placement can be performed in accordance with the aims of reconstruction and also allows for preservation of the original vessels in the recipient limb. Thus, we believe that flow-through anastomosis should be considered when performing FFMT.

ACKNOWLEDGMENTS

This study was supported by the NHFPC Special Fund for Health Scientific Research in the Public Welfare (Number 201402016).

AUTHOR CONTRIBUTIONS

We declare that all of the listed authors have participated actively in the study and meet the requirements for authorship. Hou Y and Gu L designed the study and wrote the protocol. Hou Y and Yang J performed the research/study. Liu X and Zhu Q contributed constructive suggestions about writing the article. Yang Y and Qin B managed the literature searches and analyses. Fu G and Li X performed the statistical analysis. Hou Y wrote the first draft of the manuscript.

REFERENCES

- Midha R. Epidemiology of brachial plexus injuries in a multitrauma population. *Neurosurgery*. 1997;40(6):1182-9, <http://dx.doi.org/10.1097/00006123-199706000-00014>
- Gu YD, WU MM, Zhen YL, Zhao JA, Zhang GM, Chen DS, et al. Phrenic nerve transfer for treatment of root avulsion of the brachial plexus. *Chin Med J (Engl)*. 1990;103(4):267-70.
- McGuiness CN, Kay SP. The pre-spinal route in contralateral C7 nerve root transfer for brachial plexus avulsion injuries. *J Hand Surg Br*. 2002;27(2):159-60, <http://dx.doi.org/10.1054/jhsb.2001.0665>
- Lee SK, Wolfe SW. Nerve transfers for the upper extremity: new horizons in nerve reconstruction. *J Am Acad Orthop Surg*. 2012;20(8):506-17, <http://dx.doi.org/10.5435/JAAOS-20-08-506>
- Terzis JK, Kostopoulos VK. The surgical treatment of brachial plexus injuries in adults. *Plast Reconstr Surg*. 2007;119(4):73e-92e, <http://dx.doi.org/10.1097/01.prs.0000254859.51903.97>
- Terzis JK, Kostopoulos VK. Free muscle transfer in posttraumatic plexopathies: part I: the shoulder. *Ann Plast Surg*. 2010;65(3):12-7, <http://dx.doi.org/10.1097/SAP.0b013e3181cbfe9d>
- Terzis JK, Kostopoulos VK. Free muscle transfer in posttraumatic plexopathies part II: the elbow. *Hand (N Y)*. 2010;5(2):160-70.
- Terzis JK, Kostopoulos VK. Free muscle transfer in posttraumatic plexopathies: part III. The hand. *Plast Reconstr Surg*. 2009;124(4):1225-36, <http://dx.doi.org/10.1097/PRS.0b013e3181b5a322>
- Chuang DC. Brachial plexus injury: nerve reconstruction and functioning muscle transplantation. *Semin Plast Surg*. 2010;24(1):57-66, <http://dx.doi.org/10.1055/s-0030-1253242>
- Songcharoen P. Management of brachial plexus injury in adults. *Scand J Surg*. 2008;97(4):317-23.
- Chuang DC. Nerve transfer with functioning free muscle transplantation. *Hand Clin*. 2008;24(4):377-88, <http://dx.doi.org/10.1016/j.hcl.2008.03.012>
- Doi K, Kuwata N, Muramatsu K, Hattori Y, Kawai S. Double muscle transfer for upper extremity reconstruction following complete avulsion of the brachial plexus. *Hand Clin*. 1999;15(4):757-67.
- Lin SH, Chuang DC, Hattori Y, Chen HC. Traumatic major muscle loss in the upper extremity: reconstruction using functioning free muscle transplantation. *J Reconstr Microsurg*. 2004;20(3):227-35, <http://dx.doi.org/10.1055/s-2004-823110>
- Chuang DC, Carver N, Wei FC. A new strategy to prevent the sequelae of severe Volkmann's ischemia. *Plast Reconstr Surg*. 1996;98(6):1023-31, <http://dx.doi.org/10.1097/0006534-199611000-00015>
- Ihara K, Shigetomi M, Kawai S, Doi K, Yamamoto M. Functioning muscle transplantation after wide excision of sarcomas in the extremity. *Clin Orthop Relat Res*. 1999;(358):140-8.
- Gardiner MD, Nanchahal J. Strategies to ensure success of microvascular free tissue transfer. *J Plast Reconstr Aesthet Surg*. 2010;63(9):e665-73, <http://dx.doi.org/10.1016/j.bjps.2010.06.011>
- Macchi V, Vigato E, Porzionato A, Tiengo C, Stecco C, Parenti A, et al. The gracilis muscle and its use in clinical reconstruction: an anatomical, embryological, and radiological study. *Clin Anat*. 2008;21(7):696-704, <http://dx.doi.org/10.1002/ca.v21.7>
- Juricic M, Vaysse P, Guitard J, Moscovici J, Becue J, Juskiwenski S. Anatomic basis for use of a gracilis muscle flap. *Surg Radiol Anat*. 1993;15(3):163-8, <http://dx.doi.org/10.1007/BF01627695>
- Giordano PA, Abbes M, Pequignot JP. Gracilis blood supply: anatomical and clinical re-evaluation. *Br J Plast Surg*. 1990;43(3):266-72, [http://dx.doi.org/10.1016/0007-1226\(90\)90071-7](http://dx.doi.org/10.1016/0007-1226(90)90071-7)
- Foucher G, van Genechten F, Merle N, Michon J. A compound radial artery forearm flap in hand surgery: an original modification of the Chinese forearm flap. *Br J Plast Surg*. 1984;37(2):139-48, [http://dx.doi.org/10.1016/0007-1226\(84\)90001-8](http://dx.doi.org/10.1016/0007-1226(84)90001-8)
- Costa H, Guimarães I, Cardoso A, Malta A, Amarante J, Guimarães F. One-staged coverage and revascularisation of traumatised limbs by a flow-through radial mid-forearm free flap. *Br J Plast Surg*. 1991;44(7):533-7, [http://dx.doi.org/10.1016/0007-1226\(91\)90012-9](http://dx.doi.org/10.1016/0007-1226(91)90012-9)
- Kells AF, Broyles JM, Simoa AF, Lewis VO, Sacks JM. Anterolateral thigh flow-through flap in hand salvage. *Eplasty*. 2013;13:e19.
- Yokota K, Sunagawa T, Suzuki O, Nakanishi M, Ochi M. Short interposed pedicle of flow-through anterolateral thigh flap for reliable reconstruction of damaged upper extremity. *J Reconstr Microsurg*. 2011;27(2):109-14, <http://dx.doi.org/10.1055/s-0030-1268209>
- Kasten SJ, Chung KC, Tong L. Simultaneous revascularization and soft tissue coverage in the traumatized upper extremity with a flow-through radial forearm free flap. *J Trauma*. 1999;47(2):416-9, <http://dx.doi.org/10.1097/00005373-199908000-00042>
- Haffey TM, Lamarre ED, Fritz MA. Auto flow-through technique for anterolateral thigh flaps. *JAMA Facial Plast Surg*. 2014;16(2):147-50, <http://dx.doi.org/10.1001/jamafacial.2013.2263>
- Parr JM, Adams BM, Wagels M. Flow-through flap for salvage of fibula osseocutaneous vascular variations: a surgical approach and proposed modification of its classification. *J Oral Maxillofac Surg*. 2014;72(6):1197-202, <http://dx.doi.org/10.1016/j.joms.2013.12.011>
- Kawamura K, Yajima H, Kobata Y, Shigematsu K, Takakura Y. Anatomy of Y-shaped configurations in the subscapular arterial system and clinical application to harvesting flow-through flaps. *Plast Reconstr Surg*. 2005;116(4):1082-9, <http://dx.doi.org/10.1097/01.prs.0000178791.85118.ca>
- Koshima I, Fujitsu M, Ushio S, Sugiyama N, Yamashita S. Flow-through anterior thigh flaps with a short pedicle for reconstruction of lower leg and foot defects. *Plast Reconstr Surg*. 2005;115(1):155-62.
- Brooks D, Buntic RF, Nguyen N. Salvage of a radial forearm flap transferred onto a by-pass graft with conversion from a high-to-low-resistance circulatory pattern: case report. *J Reconstr Microsurg*. 2005;21(6):355-7, <http://dx.doi.org/10.1055/s-2005-915201>
- Rozen WM, Leong J. Arterialized venous flow-through flaps with dual discontinuous venous drainage: a new modification to improve flap survival. *Plast Reconstr Surg*. 2012;130(1):229e-31e, <http://dx.doi.org/10.1097/PRS.0b013e3182550260>
- Carr MM, Manktelow RT, Zuker RM. Gracilis donor site morbidity. *Microsurgery*. 1995;16(9):598-600, [http://dx.doi.org/10.1002/\(ISSN\)1098-2752](http://dx.doi.org/10.1002/(ISSN)1098-2752)
- Mathes SJ, Nahai F. Classification of the vascular anatomy of muscles: experimental and clinical correlation. *Plast Reconstr Surg*. 1981;67(2):177-87, <http://dx.doi.org/10.1097/00006534-198167020-00007>
- Morris SF, Yang D. Gracilis muscle: arterial and neural basis for subdivision. *Ann Plast Surg*. 1999;42(6):630-3, <http://dx.doi.org/10.1097/0000637-199906000-00008>
- Kappler UA, Constantinescu MA, Buchler U, Vogelien E. Anatomy of the proximal cutaneous perforator vessels of the gracilis muscle. *Br J Plast Surg*. 2005;58(4):445-8, <http://dx.doi.org/10.1016/j.bjps.2004.11.021>
- Miyamoto S, Okazaki M, Ohura N, Shiraiishi T, Takushima A, Harii K. Comparative study of different combinations of microvascular anastomoses in a rat model: end-to-end, end-to-side, and flow-through anastomosis. *Plast Reconstr Surg*. 2008;122(2):449-55, <http://dx.doi.org/10.1097/PRS.0b013e31817d62c5>
- Ichinose A, Terashi H, Nakahara M, Sugimoto I, Hashikawa K, Nomura T, et al. Do multiple venous anastomoses reduce risk of thrombosis in free-flap transfer? Efficacy of dual anastomoses of separate venous systems. *Ann Plast Surg*. 2004;52(1):61-3, <http://dx.doi.org/10.1097/01.sap.0000096425.18223.60>