



## Original Article

# Radiographic study on the tibial insertion of the posterior cruciate ligament<sup>☆</sup>



Julio Cesar Gali\*, Paulo Esquerdo, Marco Antonio Pires Almagro, Phelipe Augusto Cintra da Silva

Faculdade de Ciências Médicas e da Saúde de Sorocaba, Pontifícia Universidade Católica de São Paulo, Sorocaba, SP, Brazil

## ARTICLE INFO

## Article history:

Received 5 February 2014

Accepted 11 June 2014

Available online 17 April 2015

## Keywords:

Tibia

Posterior cruciate

ligament/radiography

Cadaver

## ABSTRACT

**Objective:** To establish the radiographic distances from posterior cruciate ligament (PCL) tibial insertions centers to the lateral and medial tibial cortex in the anteroposterior view, and from these centers to the PCL facet most proximal point on the lateral view, in order to guide anatomical tunnels drilling in PCL reconstruction and for tunnel positioning postoperative analysis.

**Study design:** Controlled laboratory study.

**Methods:** Twenty cadaver knees were evaluated. The PCL's bundles tibial insertions were identified and marked out using metal tags, and the knees were radiographed. On these radiographs, the bundles insertion sites center location relative to the tibial mediolateral measure, and the distances from the most proximal PCL facet point to the bundle's insertion were determined. All measures were calculated using the ImageJ software.

**Results:** On the anteroposterior radiographs, the mean distance from the anterolateral (AL) bundle insertion center to the medial tibial edge was  $40.68 \pm 4.10$  mm; the mean distance from the posteromedial (PM) bundle insertion center to the medial tibial edge was  $38.74 \pm 4.40$  mm. On the lateral radiographs, the mean distances from the PCL facet most proximal point to AL and PM bundles insertion centers were  $5.49 \pm 1.29$  mm and  $10.53 \pm 2.17$  mm respectively.

**Conclusions:** It was possible to establish a radiographic pattern for PCL tibial bundles insertions, which may be useful for intraoperative tunnels locations control and for postoperative tunnels positions analysis.

© 2014 Sociedade Brasileira de Ortopedia e Traumatologia. Published by Elsevier Editora Ltda. All rights reserved.

<sup>☆</sup> Work developed in the Faculdade de Ciências Médicas e da Saúde de Sorocaba, Pontifícia Universidade Católica de São Paulo, Sorocaba, SP, Brazil.

\* Corresponding author.

E-mail: [juliogali@globo.com](mailto:juliogali@globo.com) (J.C. Gali).

<http://dx.doi.org/10.1016/j.rboe.2015.04.003>

2255-4971/© 2014 Sociedade Brasileira de Ortopedia e Traumatologia. Published by Elsevier Editora Ltda. All rights reserved.

**Estudo radiográfico da inserção tibial do ligamento cruzado posterior**

## R E S U M O

**Palavras-chave:**

Tíbia  
Ligamento cruzado posterior/radiografia  
Cadáver

**Objetivo:** Estabelecer as distâncias radiográficas dos centros das inserções tibiais do ligamento cruzado posterior (LCP) até as corticais medial e lateral da tíbia, nas radiografias em anteroposterior, e desses centros até o ponto mais proximal da faceta do LCP, nas radiografias em perfil, para que possam orientar a criação de túneis anatômicos na reconstrução do LCP e para análise pós-operatória do posicionamento dos túneis.

**Desenho:** Estudo laboratorial controlado.

**Métodos:** Vinte joelhos de cadáveres foram avaliados. As inserções tibiais das bandas do LCP foram identificadas e demarcadas com marcadores metálicos e os joelhos foram radiografados. Nas radiografias determinamos a localização do centro de inserção das bandas relativa à medida mediolateral da tíbia e as distâncias do ponto mais proximal da faceta do LCP até o centro de inserção das bandas. Todas as medidas foram calculadas com o software ImageJ.

**Resultados:** Nas radiografias em anteroposterior a distância média entre o centro da inserção da banda anterolateral (AL) até a borda medial da tíbia foi de  $40,68 \pm 4,10$  mm; a distância entre o centro de inserção da banda posteromedial (PM) até a borda medial da tíbia foi, em média, de  $38,74 \pm 4,40$  mm. Nas radiografias em perfil as distâncias médias entre o ponto mais proximal da faceta do LCP e os centros de inserção das bandas AL e PM foram de  $5,49 \pm 1,29$  mm e  $10,53 \pm 2,17$  mm, respectivamente.

**Conclusões:** Foi possível estabelecer um padrão radiográfico das inserções tibiais das bandas do LCP que pode ser útil para o controle intraoperatório da localização dos túneis e para análise pós-operatória da posição dos túneis.

© 2014 Sociedade Brasileira de Ortopedia e Traumatologia. Publicado por Elsevier Editora Ltda. Todos os direitos reservados.

**Introduction**

Anatomical positioning of the graft is a requisite for achieving a good result from posterior cruciate ligament (PCL) reconstructions.<sup>1-3</sup> Success in surgical treatments for PCL injuries is related to precise restoration of PCL anatomy.<sup>4</sup> In a recent published paper, the anatomical location and measurements of the tibial insertions of the PCL were described.<sup>5</sup>

Improper positioning of the tunnels in PCL reconstruction may cause shortening or lengthening of the graft during knee flexion and, ultimately, failure.<sup>6</sup>

For the function of the reconstructed ligament to be normal, anatomical reconstruction of its anterolateral (AL) and posteromedial (PM) bands should be envisaged, given that biomechanical studies have shown that PCL reconstruction with a double band is superior to reconstruction with a single band.<sup>7-9</sup>

Correct demarcation of the insertion sites of the AL and PM bands of the PCL and the correlated radiographic images might assist in providing greater precision for surgical reconstruction of this ligament.<sup>10-12</sup>

Computed tomography is a potentially useful tool for evaluating the locations of bone tunnels, which even has the possibility of generating three-dimensional reconstructions,<sup>13</sup> although their use in the operating theater is not possible.

Magnetic resonance is less effective for evaluating the positioning of the tunnels in cruciate ligament reconstructions, because interference screws or other metal artifacts used in graft fixation may interfere with image quality.<sup>11</sup>

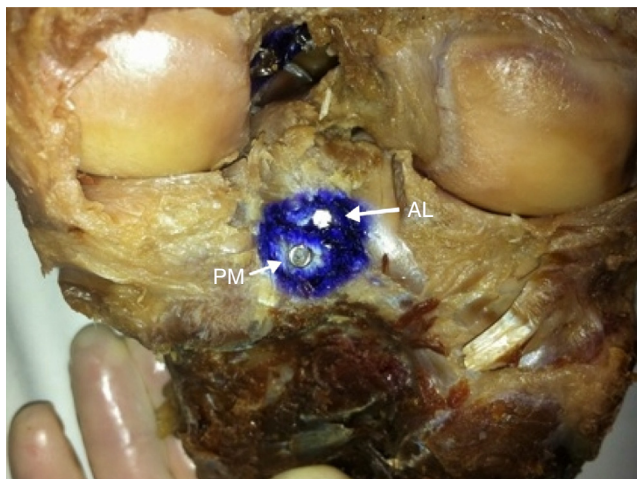The aim of our study was to define the radiographic distances from the centers of the tibial insertions of the bands of the posterior cruciate ligament to the medial and lateral cortical bone of the tibia, on radiographs in anteroposterior view, and from these centers to the most proximal point of the facet of the PCL, on radiographs in lateral view, so that these might guide the creation of anatomical tunnels during operations and so that these might serve as analytical parameters for positioning bone tunnels after these operations.

**Methods**

The insertions of the AL and PM bands of the PCL were evaluated in 20 anatomical specimens from the knees of adult cadavers (11 right and 9 left knees). The specimens were not paired and their sex and age data were unknown. All the knees presented intact anterior and posterior cruciate ligaments and none of them showed any macroscopic signs of arthrosis.

Before the dissection, the specimens were fixed in 10% formalin and were conserved in a mixture of 2.5% phenol, 2.5% formalin and 1% sodium chloride. Following this, they were kept in liquid glycerin for 60 days.

We identified and isolated the tibial insertions of the AL and PM bands of the PCL and then resected them. The centers of the bands were determined from the intersection of the diameters of the height and width and were indicated by means of metal markers that were glued directly onto the bone, using special glue. Markers of different format were used for each band (Fig. 1).



**Fig. 1 – Photograph of the dissected specimen showing the insertions of the anterolateral (AL) and posteromedial (PM) bands.**

Digital radiographs were produced in anteroposterior (AP) view, with the knee extended, and in absolute lateral view, with the knee flexed at 30°. The radiographs were produced using the following technical standardization: distance from the tube to the specimens of 120 cm; voltage of 48 kV and dosage of 5 mAs.

On the AP radiographs, the locations of the insertion sites of the AL and PM bands were established, in percentages, from

the ratio of the distance from the insertion point of each band to the medial border of the tibia, divided by the largest mediolateral measurement of the superior tibial joint face (Fig. 2).

On the lateral radiographic images, we traced a line above the inclined region of the most proximal portion of the tibia, i.e. the insertion site of the PCL, defined by Moorman et al. as the “facet of the PCL”.<sup>14</sup> We measured the size of the facet of the PCL and the distances from the most proximal point of this line to the insertions of the AL and PM bands (Fig. 3). The ImageJ software was used to measure all of the distances described above.

## Results

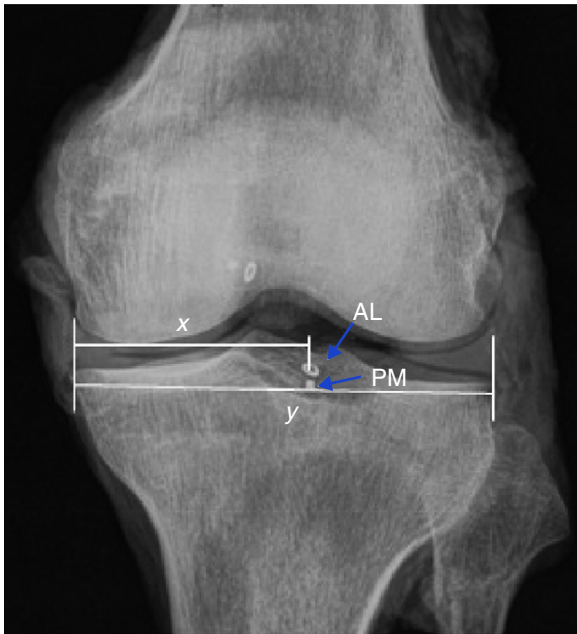
On all the radiographic images analyzed, the center of the insertion of the PM band was distal and medial to the center of the insertion of the AL band.

The mean distance from the center of the insertion of the AL band to the medial border of the tibia was  $40.68 \pm 4.10$  mm, which corresponded to  $52.32 \pm 4.55\%$  of the mediolateral measurement of the superior tibial joint face.

In relation to the PM band, the mean distance between the center of its insertion and the medial border of the tibia was  $38.74 \pm 4.40$  mm, equivalent to  $49.85 \pm 4.92\%$  of the measurement of the distance between the medial and lateral borders of the superior tibial joint face. The data relating to the tibial insertions of the PCL on AP radiographs are presented in Table 1.

**Table 1 – Distance in mm from the centers of the insertions of the AL and PM bands to the medial border of the tibia and this distance as a percentage of the greatest mediolateral distance from the superior tibial joint face, on radiographs in AP view.**

Anatomical specimen	Side	Facet of the PCL (mm)	Distance from the most proximal point of the facet of the PCL to the insertion of the band	
			AL (mm)	PM (mm)
1	R	15.87	5.34	9.58
2	L	15.77	6.62	11.99
3	R	12.29	4.16	7.9
4	L	13.47	4.33	9.61
5	L	13.46	3.99	9.75
6	R	13.2	4.27	8.7
7	R	13.13	5.18	9.29
8	R	14.32	4.15	9.51
9	L	12.66	5.47	7.75
10	R	18.42	6.07	12.24
11	L	22.03	8.74	15.29
12	L	15.04	5.79	11.82
13	R	15.77	6.1	11.33
14	R	17.8	5.81	9.43
15	L	15.72	6.26	8.92
16	R	19.2	7.85	15.03
17	R	14.67	4.15	8.12
18	R	17.08	6.32	12.68
19	L	13.71	4.66	9.76
20	L	15.1	4.59	11.91
Mean		15.436	5.493	10.531
SD		2.472	1.291	2.176
Maximum		22.030	8.740	15.290
Minimum		12.290	3.990	7.750



**Fig. 2 – Radiograph in AP view showing the insertions of the anterolateral (AL) and posteromedial (PM) bands;  $x$  = distance from the insertion point of the band to the medial border of the tibia;  $y$  = greatest mediolateral distance from the superior tibial joint face.**

In evaluating the lateral-view radiographs, the mean length of the facet of the PCL was  $15.43 \pm 2.47$  mm. The mean distances between the most proximal point of the facet of the PCL and the centers of insertion of the AL and PM bands were  $5.49 \pm 1.29$  mm and  $10.53 \pm 2.17$  mm, respectively (Table 2).

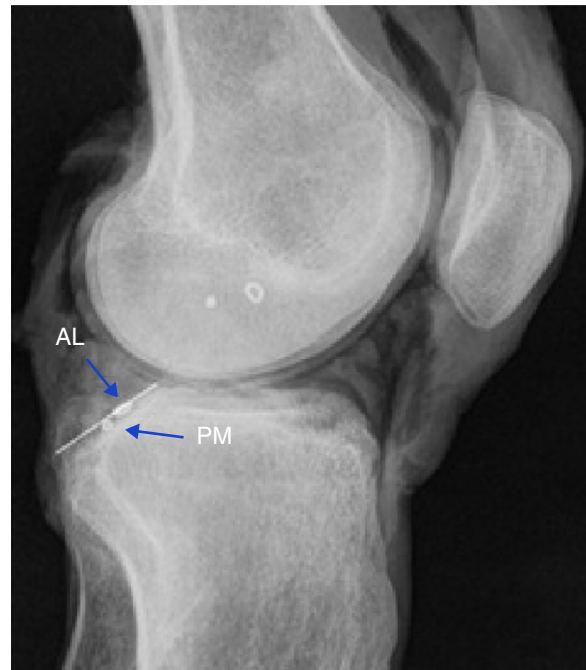## Discussion

The general orthopedic precept that surgery should reproduce anatomy suggests that grafts placed far from their true anatomical insertion may present impaired function.<sup>14</sup> Thus, radiographic guidelines for placing tunnels in surgical treatments for PCL injuries are essential for accomplishing anatomical reconstructions.<sup>15</sup>

The radiographic locations of the bands of the PCL are reference points that are independent of the size of the knee. Intraoperative fluoroscopy may therefore be a helpful tool for correct placement of the tunnels.<sup>12</sup>

Biomechanical studies have shown that reconstruction of the PCL using a double band is superior to reconstruction with a single band.<sup>7-9</sup> However, the most important factor for good results is perfect anatomical placement of the bands.<sup>9</sup> Some studies on the PCL have not described the locations of the AL and PM bands separately.<sup>10,12,16</sup>

We observed that the center of insertion of the PM band was always medial and distal to the center of insertion of the AL band. On AP radiographs, the mean distances from the centers of insertion of the AL and PM bands to the medial border of the tibia were  $40.68 \pm 4.10$  mm and  $38.74 \pm 4.40$  mm, respectively. The center of insertion of the AL band was at a location that corresponded to  $52.32 \pm 4.55\%$  of the mediolateral measure-



**Fig. 3 – Radiograph in lateral view showing the line above the “facet of the PCL” and the insertions of the anterolateral (AL) and posteromedial (PM) bands.**

ment of the superior tibial joint face. For the center of insertion of the PM band, this location represented  $49.85 \pm 4.92\%$  of the measurement of the superior tibial joint face.

Lorenz et al.<sup>12</sup> studied the insertion of the PCL in 16 knees from cadavers. They found that the common point of the insertion of the PCL was located at  $49 \pm 2\%$  of the mediolateral diameter of the tibia, in relation to the medial border. In a study on 10 knees from cadavers using computed tomography, Greiner et al.<sup>13</sup> found that the mean distance between the tibial insertion of the PCL and the medial border of the tibial plateau was 36.6 mm, equivalent to 49% of the total width of the tibial plateau.

In a study on 39 knees from cadavers, Edwards et al.<sup>17</sup> found that there was a strong correlation between the positions of the centers of the AL and PM bands and the width of the tibial plateau, which was  $48 \pm 4\%$  for the AL band ( $p < 0.001$ ) and  $48 \pm 5\%$  for the PM band ( $p < 0.002$ ).

According to Osti et al.,<sup>18</sup> who evaluated 15 knees from human cadavers, the centers of insertion of the AL and PM bands were found at 47.88% and 50.93% of the total mediolateral tibial diameter, respectively. Takahashi et al.<sup>19</sup> studied 33 tibias from cadavers and found that the distances from the medial border of the joint cartilage of the tibial plateau to the centers of the tibial insertions of the AL and PM bands, in relation to the width of the tibial plateau, were 51.0% and 50.0%, respectively.

In our sample, the distance from the most proximal point of the line traced above the facet of the PCL to the insertion of the AL band was  $5.49 \pm 1.29$  mm and it was  $10.53 \pm 2.17$  mm for the PM band. According to Osti et al.,<sup>18</sup> the measurements from the insertions of the AL and PM bands of the PCL to the joint surface were 5.3 mm and 12.8 mm, respectively. On the

**Table 2 – Length of the facet of the PCL and distance from the most proximal point of the facet to the centers of the insertions of the AL and PM bands of the PCL, on radiographs in lateral view.**

Anatomical specimen	Side	Center of AL band to medial border of tibia (mm)	Center of PM band to medial border of tibia (mm)	Percentage of distance from insertion of AL band	Percentage of distance from insertion of PM band
1	R	42.50	39.30	48.82	46.07
2	R	38.60	37.80	46.73	45.76
3	R	41.10	37.70	52.29	47.96
4	L	44.70	42.50	54.37	51.70
5	L	42.00	39.10	53.77	50.06
6	R	38.20	37.60	47.33	46.59
7	L	42.40	40.20	57.06	54.10
8	R	38.00	35.10	54.20	50.07
9	R	29.30	26.40	42.83	38.57
10	R	37.90	35.60	47.79	44.89
11	R	43.70	42.60	55.17	53.78
12	L	44.20	41.50	53.70	50.42
13	L	42.50	40.50	55.26	52.66
14	L	42.70	41.80	57.31	56.10
15	L	38.00	36.40	49.41	47.33
16	R	42.60	41.30	51.26	49.69
17	R	37.50	35.70	50.74	48.30
18	L	49.40	48.80	63.09	62.32
19	R	36.90	35.00	50.34	47.74
20	L	41.30	39.80	54.84	52.85
Mean		40.68	38.74	52.32	49.85
SD		4.10	4.40	4.55	4.92
Maximum		49.40	48.80	63.09	62.32
Minimum		29.30	26.40	42.83	38.57

other hand, according to Racanelli and Drez,<sup>10</sup> in a study on 12 knees from human cadavers, the distance from the common insertion of the PCL to the tibial joint face was 8 mm.

We fully agree with the statement by Johannsen et al.<sup>15</sup> that the most important findings relate to the lateral radiographic view, which is more frequently used during operations.

The different evaluation measurements that we used here can be applied to surgical reconstructions of the PCL, both as an aid for creating anatomical tunnels and for postoperative verification.

## Conclusions

Our study established a radiographic model for identifying the sites of the tibial insertions of the bands of the PCL based on the distances from the centers of their insertions to the medial and lateral cortical bones of the tibia and from these centers to the most proximal point of the facet of the PCL. The results from our investigation may contribute toward anatomical reconstruction of the PCL, since correct positioning of the tunnels can be checked using fluoroscopy, before they are drilled. The data obtained may also aid in analyzing the locations of the tunnels, after the operation.

## Conflicts of interest

The authors declare no conflicts of interest.

## REFERENCES

- Petersen W, Lenschow S, Weimann A, Strobel MJ, Raschke MJ, Zantop T. Importance of femoral tunnel placement in double-bundle posterior cruciate ligament reconstruction: biomechanical analysis using a robotic/universal force-moment sensor testing system. *Am J Sports Med.* 2006;34(3):456–63.
- Yasuda K, Kitamura N, Kondo E, Hayashi R, Inoue M. One-stage anatomic double-bundle anterior and posterior cruciate ligament reconstruction using the autogenous hamstring tendons. *Knee Surg Sports Traumatol Arthrosc.* 2009;17(7):800–5.
- McGuire DA, Hendricks SD. Comparison of anatomic versus non-anatomic placement of femoral tunnels in Achilles double-bundle posterior cruciate ligament reconstruction. *Arthroscopy.* 2010;26(5):658–66.
- Harner CD, Xerogeanes JW, Livesay GA, Carlin GJ, Smith BA, Kusayama T, et al. The human posterior cruciate ligament complex: an interdisciplinary study. Ligament morphology and biomechanical evaluation. *Am J Sports Med.* 1995;23(6):736–45.
- Gali JC, Oliveira HC, Lisboa BCB, Dias BD, Casimiro FG, Caetano EB. Inserções tibiais do ligamento cruzado posterior: anatomia topográfica e estudo morfométrico. *Rev Bras Ortop.* 2013;48(3):263–7.
- Saddler SC, Noyes FR, Grood ES, Knochenmuss DR, Hefzy MS. Posterior cruciate ligament anatomy and length-tension behavior of PCL surface fibers. *Am J Knee Surg.* 1996;9(4):194–9.
- Race A, Amis AA. PCL reconstruction. In vitro biomechanical comparison of “isometric” versus single and double-bundled “anatomic” grafts. *J Bone Joint Surg Br.* 1998;80(1):173–9.



8. Harner CD, Janaushek MA, Kanamori A, Yagi M, Vogrin TM, Woo SL. Biomechanical analysis of a double-bundle posterior cruciate ligament reconstruction. *Am J Sports Med.* 2000;28(2):144-51.
9. Mannor DA, Shearn JT, Grood ES, Noyes FR, Levy MS. Two-bundle posterior cruciate ligament reconstruction. An in vitro analysis of graft placement and tension. *Am J Sports Med.* 2000;28(6):833-45.
10. Racanelli JA, Drez D Jr. Posterior cruciate ligament tibial attachment anatomy and radiographic landmarks for tibial tunnel placement in PCL reconstruction. *Arthroscopy.* 1994;10(5):546-9.
11. Brand JC Jr, Cole J, Sumida K, Caborn DN, Johnson DL. Radiographic analysis of femoral tunnel position in postoperative posterior cruciate ligament reconstruction. *Arthroscopy.* 2002;18(7):688-94.
12. Lorenz S, Elser F, Brucker PU, Obst T, Imhoff AB. Radiological evaluation of the anterolateral and posteromedial bundle insertion sites of the posterior cruciate ligament. *Knee Surg Sports Traumatol Arthrosc.* 2009;17(6):683-90.
13. Greiner P, Magnussen RA, Lustig S, Demey G, Neyret P, Servien E. Computed tomography evaluation of the femoral and tibial attachments of the posterior cruciate ligament in vitro. *Knee Surg Sports Traumatol Arthrosc.* 2011;19(11):1876-83.
14. Moorman CT 3rd, Zane MS, Bansai S, Cina SJ, Wickiewicz TL, Warren RF, Kaseta MK. Tibial insertion of the posterior cruciate ligament: a sagittal plane analysis using gross, histologic, and radiographic methods. *Arthroscopy.* 2008;24(3):269-75.
15. Johannsen AM, Anderson CJ, Wijdicks CA, Engebretsen L, LaPrade RF. Radiographic landmarks for tunnel positioning in posterior cruciate ligament reconstructions. *Am J Sports Med.* 2013;41(1):35-42.
16. Lee YS, Ra HJ, Ahn JH, Ha JK, Kim JG. Posterior cruciate ligament tibial insertion anatomy and implications for tibial tunnel placement. *Arthroscopy.* 2011;27(2):182-7.
17. Edwards A, Bull AM, Amis AA. The attachments of the fiber bundles of the posterior cruciate ligament: an anatomic study. *Arthroscopy.* 2007;23(3):284-90.
18. Osti M, Tschann P, Künzel KH, Benedetto KP. Anatomic characteristics and radiographic references of the anterolateral and posteromedial bundles of the posterior cruciate ligament. *Am J Sports Med.* 2012;40(7):1558-63.
19. Takahashi M, Matsubara T, Doi M, Suzuki D, Nagano A. Anatomical study of the femoral and tibial insertions of the anterolateral and posteromedial bundles of human posterior cruciate ligament. *Knee Surg Sports Traumatol Arthrosc.* 2006;14(11):1055-9.