

From open to single port video-assisted thoracoscopic lobectomy: a stepwise and return progression of the experience from Department of Thoracic Surgery, General Hospital of Guangzhou Military Command of P.L.A

Qihang Zhu*, Haiping Xiao*, Enwu Xu, Ming Liao, Yong Tang, Yiwen Xuan, Kai Su, Zhe He, Xiufan Peng, Zhuohua Zhang, Yan Liu, Guibin Qiao

Department of Thoracic Surgery, General Hospital of Guangzhou Military Command of P.L.A, Guangzhou 510010, China

*These authors contributed equally to this work.

Correspondence to: Guibin Qiao, MD, PhD, Director and Professor. Department of Thoracic Surgery, General Hospital of Guangzhou Military Command of P.L.A, Guangzhou 510010, China. Email: guibinqiao@126.com.

Submitted May 10, 2015. Accepted for publication Jun 23, 2015.

doi: 10.3978/j.issn.2072-1439.2015.06.12

View this article at: <http://dx.doi.org/10.3978/j.issn.2072-1439.2015.06.12>

Introduction

Department of Thoracic Surgery, General Hospital of Guangzhou Military Command of P.L.A was founded in 1954, and the first lobectomy using standard posterolateral thoracotomy was performed in the same year. For about half a century, more than 5,000 open lobectomy have been performed at the department. With the wide acceptance of video-assisted thoracoscopic surgery (VATS) lobectomy all over the world, more than a thousand cases of multiport VATS lobectomy have been performed at our department. Since 2013, without any training and operation observation, single port VATS lobectomy has been successfully developed after the reading of a series of papers by Dr. Gonzalez-Rivas, and nearly 200 single port VATS lobectomy have been performed at our department up to now. Moreover, we have developed our own unique surgical skills and process without any major intra-/and post-operative complications. In order to verify the advantages of single port, we launched a prospective study to compare the short and long term outcomes between multiple and single port VATS lobectomy recently. Here, we firstly introduce the evolution of lobectomy approach at our department, and give the story how we develop surgical approach from open to single port VATS step by step. Then, the characteristic of single port lobectomy and our unique experience will be described. We think single port VATS lobectomy is a kind of return

progression from open lobectomy with the same surgical vision and technique maneuver. At last, we will discuss a few potential improvements of single port lobectomy and give a glimpse into the future.

Single port VATS approach was firstly elaborated by Dr. Rocco from Division of Surgery, the National Cancer Institute, Naples, Italy. Since 2004, Rocco and colleagues (1-3) described their technology and initial experience of single port VATS in pulmonary wedge resection and mediastinal nodal biopsy in a series of papers. It has been a prevalent trend around the world after 2012, when Dr. Gonzalez-Rivas firstly reported his wonderful endeavor in single port VATS lobectomy with radical lymphadenectomy for non-small cell lung cancer (NSCLC). Nowadays, more and more surgeons are interesting in how to develop this relative complicated technique. In this paper, we introduce our experience and some tips and tricks in single port VATS lobectomy.

The evolution of surgical approach for lobectomy at our department

Traditional open surgical approach [1954-2000]

In 1954, Department of Thoracic Surgery was founded in General Hospital of Guangzhou Military Command of P.L.A by a prominent surgeon Dr. Weijie Ou (*Figure 1A*).

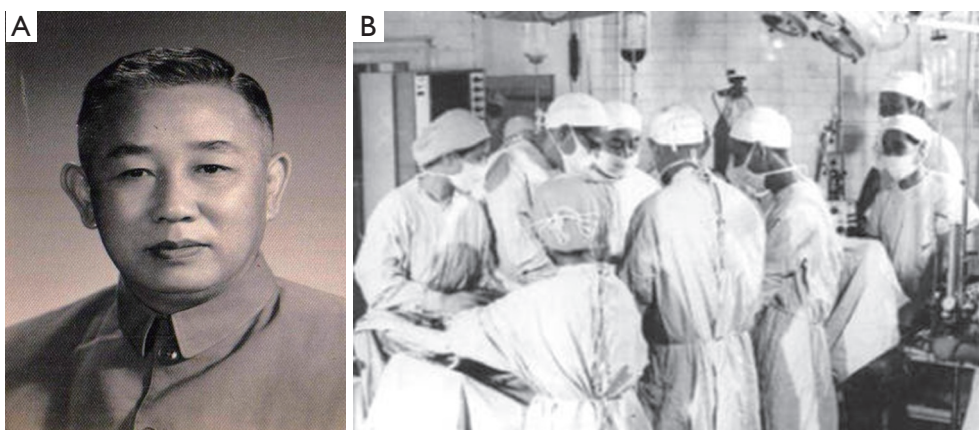


Figure 1 (A) Dr. Weijie Ou [1920-1997], founder and first director of our department; (B) lobectomy in our department in the early time.

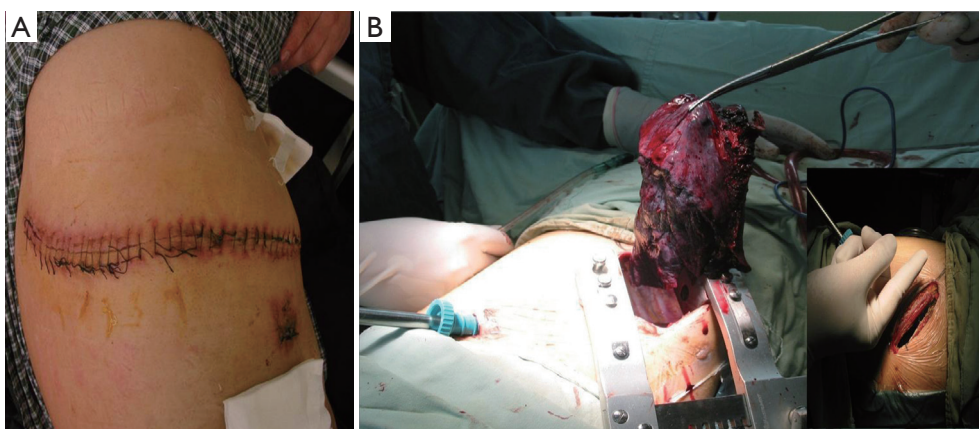


Figure 2 (A) Appearance of chest wall after standard posterolateral thoracotomy, we can see the almost 35 cm long incision and the drainage port below; (B) lobectomy through video-assisted thoracoscopic subaxillary minithoracotomy. The incision is longer than 10 cm.

At almost the same time, the first lobectomy through standard posterolateral thoracotomy was performed at our department (*Figure 1B*). At that time, it was one of the several centers that could be qualified for major pulmonary surgery in southern China. Since then, thousands of patients with lung diseases have regained their health in our department. During half a century, the main surgical approach for lobectomy was the standard posterolateral thoracotomy at our department (*Figure 2A*).

Muscle sparing thoracotomy [2000-2003]

Based on the abundant experience on lobectomy using traditional thoracotomy, we were adapted to muscle sparing thoracotomy fast and well around 2000. In general, muscle sparing thoracotomy includes subaxillary minithoracotomy (*Figure 2B*, the common way we did) and auscultatory

triangle thoracotomy. Though the assumption that muscle sparing thoracotomy resulting in less pain than conventional open surgery was debated (4,5), the smaller incision leading to a better cosmetic result is obvious. The approach was still attractive before VATS become widespread. It should be pointed out that conventional open operation and muscle sparing thoracotomy coexist at our department during this period.

Video-assisted thoracoscopic surgery (VATS) [2003-]

If muscle sparing thoracotomy was the eve of minimally invasive thoracic surgery, the use of thoracoscopy truly opened the era of minimally invasive thoracic surgery. With the experience of VATS in pneumothorax, mediastinal diseases and pulmonary wedge resection for nearly 10 years, we applied VATS in lobectomy from 2003. Since then,

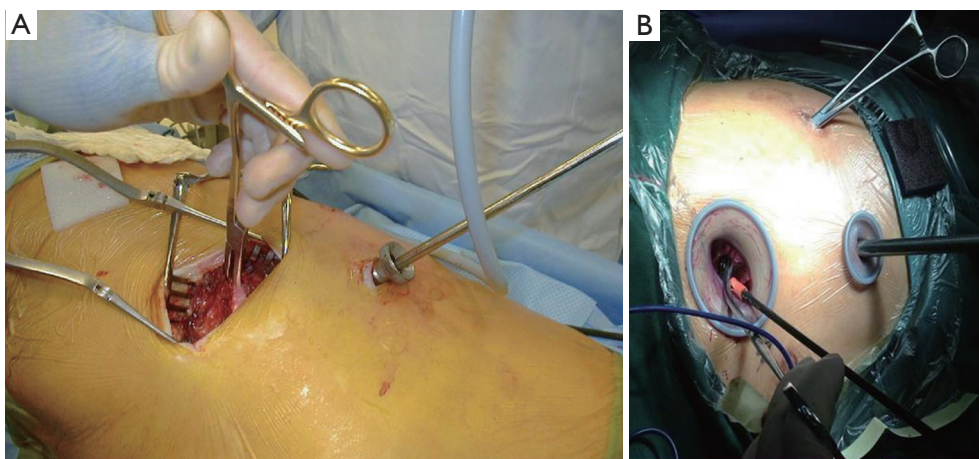


Figure 3 (A) Hybrid VATS lobectomy: the length of incision is shorter than *Figure 2B*. Meanwhile, a minimal invasive rib retractor is still used to expose thoracic cavity; (B) complete VATS lobectomy through the typical 3-port. The length of utility incision is about 3-6 cm without rib retractor, but a wound protector. A 1-cm auxiliary is used to help expose the tissue. Another 1-cm incision is used to insert thoracoscope, here we use a small wound protector instead of trocar. VATS, video-assisted thoracoscopic surgery.

VATS lobectomy has been applied in our unit more and more widely, and the development of VATS lobectomy at our department can be broadly divided into three phases: hybrid VATS, complete VATS and single port VATS.

Hybrid VATS lobectomy (after 2003)

Before 2005, the main approach for lobectomy at our department is hybrid VATS. In our view, hybrid VATS contains muscle-sparing minithoracotomy using rib retractor to spread intercostal (incision, 8 to 10 cm) and a 10-mm incision to insert thoracoscopy (*Figure 3A*). The perspective of a surgeon comes from the combination of genuine direct vision and visualization of video screen. It is the primary development stage of VATS lobectomy at our unit. In this stage, this hybrid method made the surgeons adapt to the perspective and operation under thoracoscope. In addition, almost every complicated procedure including double sleeve pulmonary resection could be performed using this hybrid method. Most important, we completed almost all lobectomy by handmade maneuver (including the suture and ligation of vessels) instead of surgical instruments like stapler. This hybrid VATS lobectomy not only reduces medical cost but also improve our surgical skills which facilitate the transition of single port lobectomy from multiple ports.

Complete VATS lobectomy (after 2006)

In 2005, Dr. McKenna and colleagues (6) reported their experience of VATS lobectomy with 1,100 cases and

published in *Annals of Thoracic Surgery* in 2006. Based on their description, the typical design includes (*Figure 3B*): a 10-mm incision placing trocar through the 7th or 8th intercostal space in the midaxillary line, a 1-cm auxiliary incision in the 7th intercostal space in the posterior axillary line, and a 3 to 6 cm utility incision (without using rib retractor, but wound protector) directing lateral from the vein for upper lobectomies or one intercostal space lower for middle or lower lobectomies. Strictly speaking, all procedures should be seen only through the visualization of video. The method they used became known as complete VATS (c-VATS).

Almost at the same time, we successfully performed c-VATS lobectomy, too. The first case we performed was right middle lobectomy (*Figure 4*) in October, 2005. Notably, the case involved in a very complex procedure: to manage the severely adhesive pulmonary vein safely, partial resection of pericardium was performed under c-VATS. It was inseparable from the long history of open surgery and experience accumulated in hybrid VATS for us to be able to handle such a difficult procedure. Besides, one of the unique features of our VATS lobectomies could be seen from the video, thanks to the experience accumulated by conventional thoracotomy as mentioned before, we had been used to the handmade surgical maneuver without any instruments.

Since 2006, endoscopic instruments, including instrumentation with both proximal and distal articulation, modern articulated staplers have been brought in our

department. With the development of our technology, the majority of pulmonary lobectomies can be done under complete VATS. In this process, we tried consciously to transform the typical three or four ports to two ports (single utility port). That's one small step, one giant leap for techniques and concepts. For 3-port approach, not only the optical plane that requires a torsional angle, but also the cooperation and hands operation both are separated. With aspect to 2-port approach, however, both hands operation and cooperation are performed through the same one port. Through this approach, operators could practice the single port operation. One can suppose that it's the run-up for single port VATS.

Single port VATS lobectomy (after 2009)

We performed the first single port VATS in 2009. Initially, it was used for minor operations, such as pneumothorax,

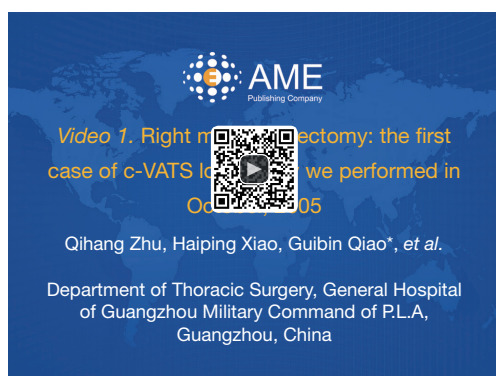

Figure 4 Right middle lobectomy: the first case of c-VATS lobectomy we performed in October, 2005 (7). C-VATS, complete video-assisted thoracoscopic surgery.

Available online: <http://www.asvide.com/articles/551>

thymusectomy or sympathectomy. At that moment, special instruments (*Figure 5A,B*) for single port surgery designed by a Chinese company (Liuyedao, Inc., Yuyao, China) were used. However, the instruments were firstly designed for single port laparoscopic surgical procedures. Thus, it should be pointed out now that the instrument has limitations for single port pulmonary lobectomy. Because the instrument is overlong and wrist-controlled, it is not convenient for complex pulmonary surgery. Nevertheless, this process provided us valuable practice to experience single port operation.

Since 2013, without any training and operation observation, single port VATS lobectomy has been successfully developed after the reading of a series of papers by Dr. Gonzalez-Rivas, and nearly 200 single port VATS lobectomies have been performed at our department up to now. Moreover, we have developed our own unique surgical skills and process without any major intra- and post-operative complications. Nowadays, more than 40% lobectomies at our department can be performed using single port VATS. All types of lobectomies can be performed by us expertly, including lobectomy, bilobectomy and sleeve lobectomy. And here, we would like to present a complete single port VATS right upper lobectomy we performed (*Figure 6*). It is a complicated large tumor with diameter of 9 cm.

Just like the evolutionary process from the ape to the modern man, the progression of the approach for pulmonary lobectomy at our department is step by step from long incision to multiple small ports and eventually to the single port (*Figure 7A,B*). In our opinion, single port or uniportal technique is the final evolution stage in these minimally invasive surgical techniques. It is the theory of evolution that is reflected in minimally invasive thoracic surgery, which is bound to happen as time progressed.

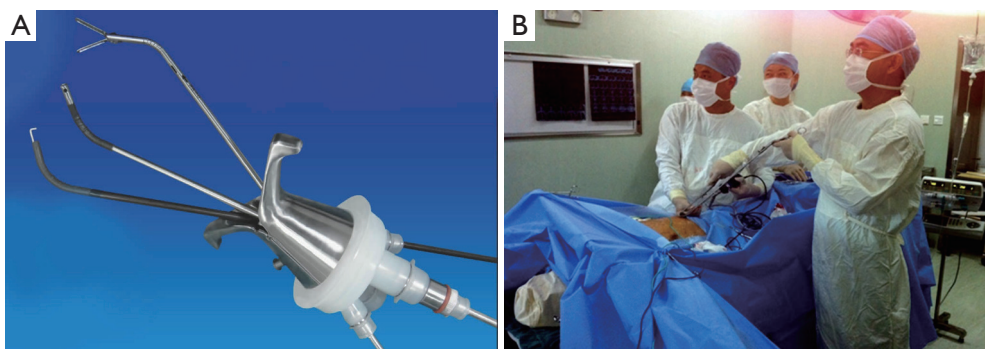


Figure 5 (A) Special instruments for single port surgery (Liuyedao, Inc., Yuyao, China), including a single hole puncture device, non-invasive grasping forceps, separating pliers and electric hook; (B) intraoperative image using the special instruments (Liuyedao, Inc., Yuyao, China).

Because the visual perspective and surgical maneuver of single port lobectomy are same with the open or hybrid VATS lobectomy, we call this evolution from open to single port as “return progression”.

Our experience of single port VATS lobectomy

Theoretically, single port VATS lobectomy has its potential advantages. Firstly, instruments are parallel to thoracoscope, providing a similar angle of view as for open surgery, i.e., a sagittal, caudocranial perspective. Obviously, it contributes to flat one’s learning curve from open surgery to single port VATS. Then, trocar is not needed to introduce the lens. It may reduce the postoperative pain and paresthesias mainly because of the squeezing between trocar and ribs. Recently, a study found that the pain and recovery are comparable after either uniportal or multiport video-assisted thoracoscopic lobectomy. Though the study indicated that

single port VATS lobectomy is non-inferior to multiport lobectomy in the first 24 postoperative hours, it was a non-randomized and retrospective clinical trial based on only one centre. In the future, larger prospective trials are needed to address whether there is difference in the outcome of pain scores of a longer period in the postoperative course. On the other hand, however, disadvantages exist inevitably. Firstly, because of the narrow space from single port, the view of operators is obstructed, as well as their operation is restricted. These lead to bad exposure and difficulty in node dissection or stopping bleeding. Secondly, it is hard to coordinate among instruments, as well as the cooperation with thoracoscope assistant, which leading to unavoidable interference of the thoracoscope and the instrumentation. Thirdly, to some extent, single port VATS lobectomy challenges the personal habits and skills of who has already been adapted in multiport surgery.

Currently, single port lobectomy has been reported as safe and effective, with low postoperative morbidity and mortality (9,10). Is it ready to declare that single port VATS can replace the status of multiport surgery? In our opinion, one should consider that single port VATS is not a denial of conventional VATS surgery, but a beneficial supplement. For selected cases, those with severe adhesions for an example, multiport VATS or conventional open surgery may be more effective and safe than single port surgery.

It must be pointed out again that available studies were non-randomized and retrospective because of the late arrival of single port VATS. The previous results were obtained based on weak evidence. Furthermore, with the development of single port technology and instruments, the disadvantages mentioned above should be overcome, which could be deduced from the process history of multiport

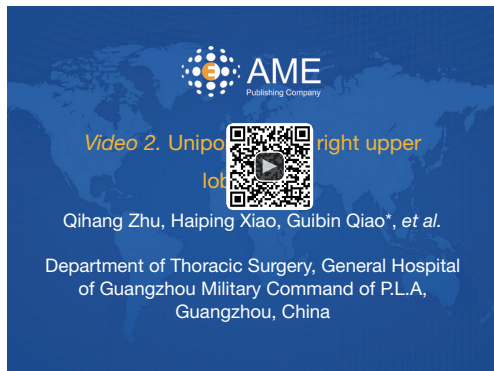

Figure 6 Uniportal VATS right upper lobectomy (8). VATS, video-assisted thoracoscopic surgery.

Available online: <http://www.asvide.com/articles/552>

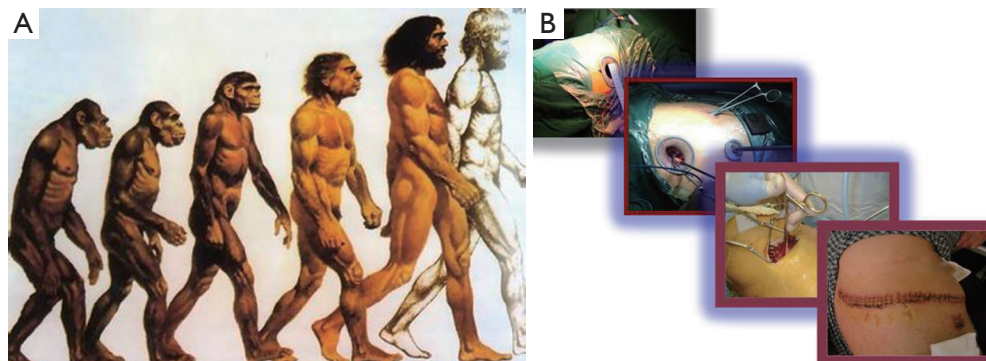


Figure 7 (A) History of human evolution; (B) evolution history of the approach for pulmonary lobectomy at our department.

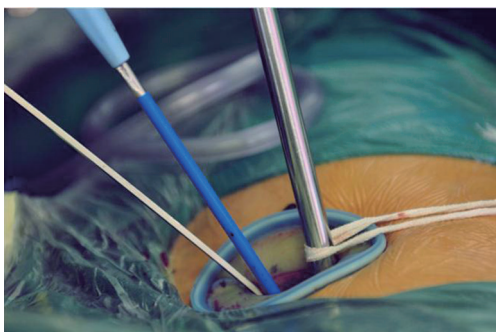


Figure 8 The general position of camera and stabilization. The lens is stuck to the upper side of incision. A string is used to eliminate camera shake.

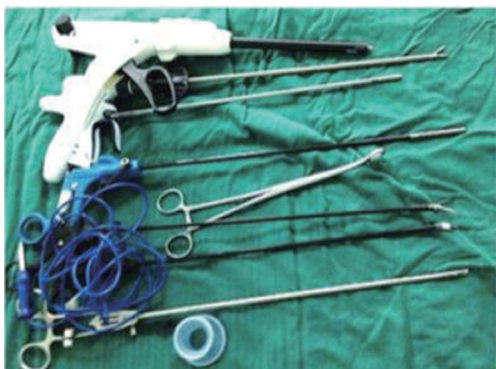

Figure 9 The common instruments we used in single port VATS lobectomy, including ultrasound scalpel, articulated stapler, non-invasive grasping forceps, oval forceps, separating pliers, electric hook, and vascular clamp. VATS, video assisted thoracoscopic surgery.

VATS lobectomy. To explore the potential advantages of single port VATS lobectomy, a retrospective and prospective clinical study to explore the short-term effects (e.g., pain, lung function, chest tube duration, hospital stay and complications, etc.) among hybrid VATS lobectomy, complete VATS lobectomy and single port VATS lobectomy is conducted in our department now. Early results indicate that paresthesias in single port arm seem to be lower than the others, with no difference of pain and complications. We believe that similar clinical trials are ongoing around the world. However, it is more time that is needed to get results. Currently, an effective way to encourage progress is the exchange of experiences among units, which can help find our problems and promote solutions. Therefore, in this stage, summary of individual experience becomes very important. The experiences of our department in single port VATS lobectomy will be summarized as follows.

Position of camera and stabilization

Unlike traditional multiport VATS, it is unnecessary to use a trocar for the thoracoscope, which is one of the potential principles of single port VATS lobectomy to relieve pain. To ensure enough space for operation, we think, assistant should stick the lens to the upper side (the posterior part) of incision most of the time. Operator will have enough room to complete the surgical procedure in this situation. In addition, a string is used to eliminate camera shake, as well as lighten assistant's load. The classical appearance is presented in *Figure 8*.

Instruments

Nowadays, there is a set of specific adapted instruments for single port lobectomy, including the common high definition 30° thoracoscope, articulated staplers, and instruments with proximal and distal articulation. However, based on a range of practices we get from the long history of our conventional lobectomy, we are very skilled at using conventional instruments (*Figure 9*). For example, vascular clips or sutures and ligations are commonly used when handling the vessels, just like in open or hybrid VATS lobectomy. For small pulmonary lacerations, we are accustomed to choose sutures, but not staplers. For patients, more medical costs will be saved by using conventional instruments. In addition, a unique experience of us is that we use short-handled instruments widely. We think that may contribute to providing a stable triangular space, as well as avoiding inadvertent collisions.

Incision

To our knowledge, the common location of the incision for single port VATS lobectomy is 4th or 5th intercostal space in the anterior position. Gonzalez-Rivas *et al.* (11) tended to recommend the 5th intercostal space. Indeed, that provided better angles for hilar dissection and appropriate length for the insertion of staplers. Nevertheless, we use 4th intercostal space more than 5th intercostal space. The incision is about 3-5 cm long, the same size as the utility incision we use in multiport VATS technique (*Figure 10*). Though it is a little harder to insert staplers than 5th intercostal space, it is closer to the hilar. Because of the unique development history of our department as mentioned above, we are used to sutures or insert vascular clips (traditional open surgery procedures), not articulated

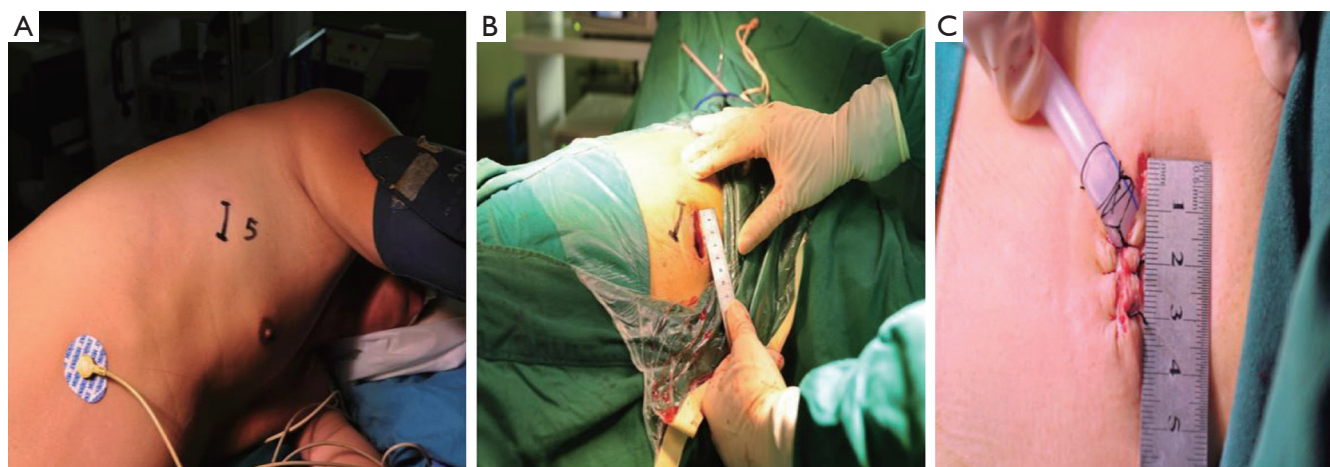


Figure 10 Location and length of the incision for single port lobectomy at our department. 4th intercostal space in the anterior position is common used, and the length is about 3-5 cm.

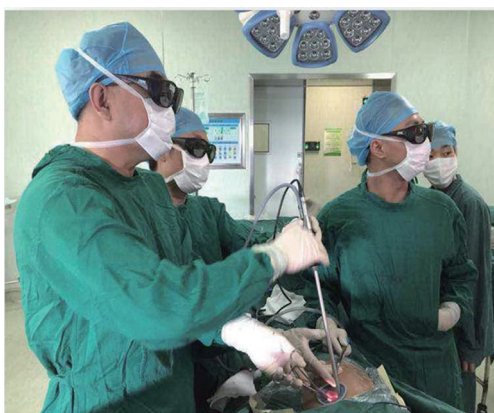

Figure 11 General position of operating personnel in our department for single port lung resection. Operator and the assistant who handle the thoracoscope are positioned in front of the patient. The other assistant who helps exposure the target tissue and instrument nurse are at the posterior of patient.

staplers. Moreover, in severe circumstances, operator is able to handle the accidental bleeding during surgery as soon as possible.

Position of operating personnel

In view of narrow operation space of single port surgery, a coordinated, effective positional programme is urgently needed. In general, surgical team members include three surgeons and one instrument nurse, as we can see from *Figure 11*. The operator and the assistant who handle

the thoracoscope must to be positioned in front of the patient in order to have the same thoracoscopic vision and movements. And the assistant is better to stand below the operator. The other assistant who helps exposure the target tissue should be at the posterior of patient. The instrument nurse is also located at the posterior side of patient. It must be explained that the position we described above is general aspect. A competent operator will be able to make a change flexibly based on the actual situation.

Management of accidents

Operative accidents, including severe adhesion, bleeding, pulmonary laceration, etc., happened occasionally. Among them, bleeding is a common but sometimes life-threatening complication during surgery. When facing such situation, we recommend that operator should make a prompt decision to transform single port to multiport (*Figure 12*). Especially when the single port VATS lobectomy is still in developing stage around the world now, don't do something for the sake of doing it. The safety of patients is the first, technical exercises the second. The practice also applies to some other accidents. In our opinion, management of accidents represents the ability of operator. A good operator can make an appropriate decision quickly and decisively.

Single port VATS lobectomy is another innovation in the minimally invasive thoracic surgery. Different methods of painting is a good analogy for single port VATS and open lobectomy (*Figure 13A,B*). Imaging that the traditional Chinese landscape painting is the open lobectomy, while the

single port VATS lobectomy be the inside-bottle painting. The process of traditional Chinese landscape painting is painting the background before details. Instead, the inside-bottle painting is painted by the accumulation of details. The two methods are mostly opposite. For this reason, single port VATS lobectomy is the new challenges of thoracic surgery. In order to deal with the single port VATS lobectomy better, operators should renew their concepts, operating skills and surgical process.

Future prospects of single port VATS lobectomy

Currently, single port VATS lobectomy has shown as an irresistible trend in the minimally invasive thoracic surgery. However, there are still many imperfect fields which need further improvement. Hence, here we will discuss a few notable future prospects based on the development situation among units and the practical experiences of ourselves.

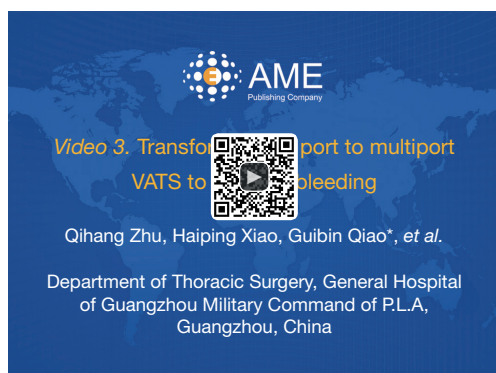

Figure 12 Transform single port to multiport VATS to manage bleeding. VATS, video-assisted thoroscopic surgery (12). Available online: <http://www.asvide.com/articles/553>

Improvement of instruments

Nowadays, though the modern instruments can be competent with single port VATS lobectomy basically, the further improvements are needed.

The first one is the articulated stapler. Recently, the use of 360° rotation of the shaft is an encouraging progress. However, the existing problem is that the stem is too thick to move flexible in single port's narrow surgery space, leading to more instrument interference and obstruction of view. Given this, a thinner stem is urgently needed with reservation of available features. According to the development of modern materials science, we believe that it is not a dream to deliver such the technology.

Another one is the high definition 30° thoracoscope. The same existing problem is the thick stem, too. Certainly, one could also design a thinner stem thoracoscope as a solution. However, some authors (13) have described a remote wireless cameras which can be 'hung' onto the inside of the chest wall or held against the inner chest cavity by a magnetic anchoring and guidance system (MAGS, *Figure 14A,B*), a way they used to facilitate laparoscopic single port surgery. To our knowledge, the main limitations now are the battery life issues (insufficient power reserve capacity for surgery) and deficiency of wireless data transmission (leading to image instability). In the near future, the development of energy science and radio science may address the problems.

Indeed, improvement of instruments will facilitate the single port VATS lobectomy well. Nevertheless, more frequently use of modern specific adapted instruments, disposable medical instruments in particular, leads to the increase of cost inevitably. As a well-established thoracic department, in most cases, we are good at using traditional instruments to complete most of the single port lobectomy procedures. Thus,




Figure 13 (A) Painting process of traditional Chinese landscape painting is painting the background before details (Available online: <http://www.dfmsj.com/Sj/ShowProducts-47-121.html>); (B) painting process of the inside-bottle painting (Available online: <http://www.duitang.com/people/mblog/222929285/detail/>).

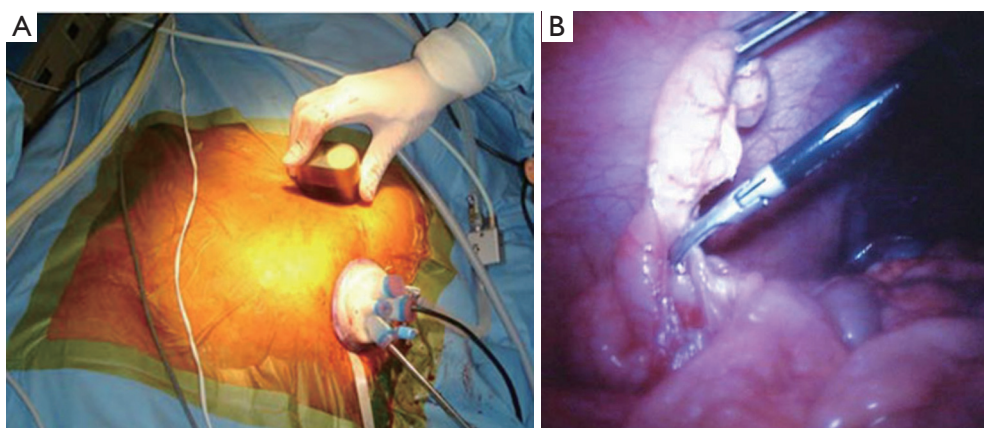


Figure 14 (A) Deployment of magnet on anterior abdominal wall during nephrectomy (13); (B) internal MAGS camera view of appendix with internal LED illumination and ultrasonic shears dividing the appendiceal mesentery (13). MAGS, magnetic anchoring and guidance system; LED, light emitting diode.

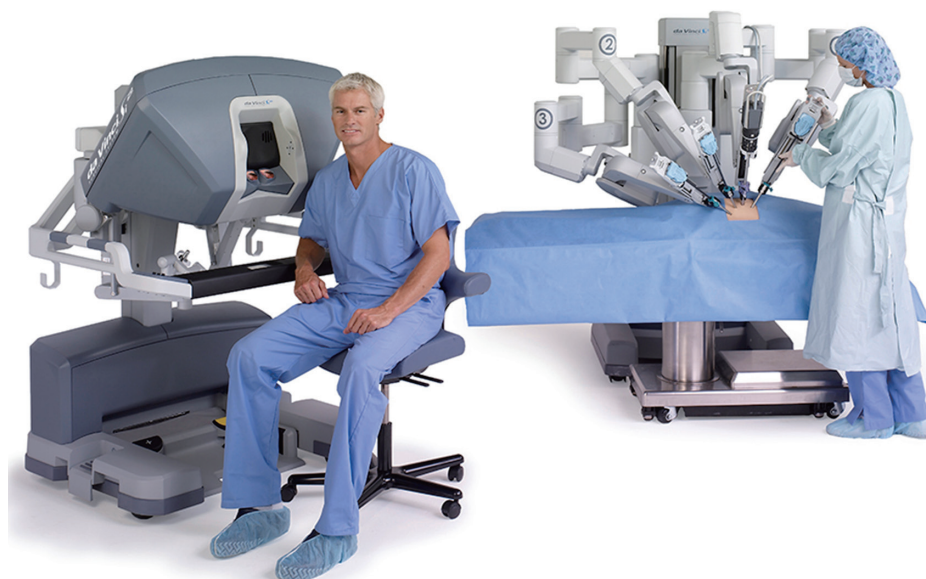

Figure 15 The robot is “outside” of the patient (Available online: <http://www.mountainside-medical.com/blog/da-vinci-latest-robotic-surgery/>).

our technical ability to use traditional instruments expertly in VATS lobectomy will be a beneficial complement.

Robotic single port VATS

After the advancement of VATS, the development of the surgical robot (Intuitive, Da Vinci, Inc, Sunnyvale, CA, USA) has been in the ascendant for a decade. Initially, the major applications have been for pelvic surgeries. It was not until 2006 that Park *et al.* reported their initial practice of robotic lobectomy (14). After that, previous reports (15,16)

demonstrate the safety of robotic lobectomy. Nowadays, more and more thoracic units in China have introduced the robotic device and technology.

Actually, the main advantage of robotic operation is that the robotic arms cover seven degrees of freedom enabling wristed movement for surgery. However, as we can notice from *Figure 15*, the robot is ‘outside’ of the patient, which is similar to the operating principle of human beings. Due to the feature of current system design, it is certain that multiple ports are required. But actually, the robotic platform is designed to mimic open surgery, matching the



Figure 16 A new insertable robotic end-effectors platform (IREP, Columbia University, USA) (17). (A) The cylindrical profile with the diameter of only 15 mm before opened up; (B) the robot opens up with camera and arms when it is inserted into the thoracic cavity.

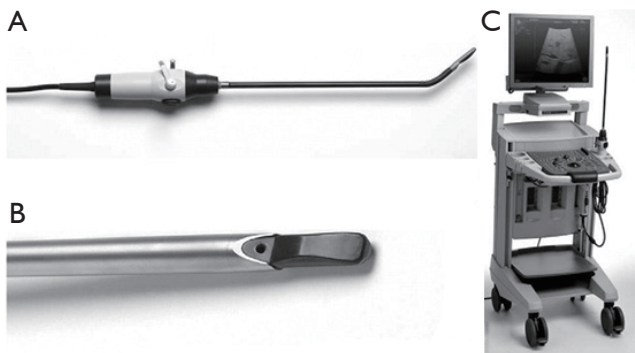


Figure 17 (A) Ultrasonography device with detail of characteristics that make the probe useful for single-access video-assisted thoracic surgery (VATS); (B,C) in particular, the articulating end contributes to refinement of lung scanning (19).

original intention of single port VATS. To perform robotic lobectomy through single port approach, a good solution is to design an inserted robotic system. The operation body, including camera, robot arms, should be inserted into the thoracic cavity through a single small incision. Fortunately, a new insertable robotic end-effectors platform (IREP, Columbia University, USA) (17) has been designed and constructed for single-port access surgery. The IREP is designed as a cylindrical profile which has the diameter of only 15 mm (*Figure 16A*). After being inserted into the thoracic cavity, the robot opens up with camera and arms (*Figure 16B*). One could realize that it is the duplicate for existing single port VATS.

Still, several problems remain in robotic lung resection (18), including: (I) the learning curve is often unclear at this stage of adoption, resulting in potential harm; (II) the robotic platform does not provide tactile feedback, leading to possible off-screen damage; (III) robotic-assisted lobectomies cost seems to be higher than thoracoscopic procedures. Due to the sustaining innovations of products and concepts, however, the robotic single port lobectomy is feasible now in theory.

Localization of small lung nodules

Currently, the precise resection for small lung nodules, especially small nodules and those with low solid component, mainly depends on the accurate preoperative localization, including CT-guide hookwire localization, methylene blue staining etc. Actually, operator could assess the accuracy of preoperative localization by touching the target tissue in multiport VATS. Though operators could apply traditional preoperative computed tomography-guided hookwire localization to single port VATS lobectomy, there is an issue that the inability to palpate the lung to identify invisible lesion because of the narrow space of single port. Thus, it is more difficulty than multiport VATS in assessing tumors though a single port.

To solve the problem above, scholars carried out various attempts. Rocco and colleagues (19) reported the use of intraoperative articulating ultrasound probe in single port VATS lung resection (*Figure 17*). It is a laparoscopic 10-mm ultrasound probe (B-K Medical, Herlev, Denmark) which can be inserted through the single port. Once the lesion is identified, it will be marked with electrocautery and then, a wedge resection can be performed. Moreover, an advanced multimodality image-guided operating room (AMIGO, *Figure 18*) was used in minimally invasive thoracic surgery in 2013 by Prof. Raphael Bueno's group at Harvard University, Brigham and Women Hospital, Boston (20). It is a good attempt that should be concerned. On one hand, preoperative hookwire localization can be performed in the same room just before operation. On the other hand, similar to the principle of percutaneous coronary intervention (PCI), a real-time on-table scan can be performed without inserting hookwire.

In our opinion, with the speedy development of productivity, science and technology, all the problems will be solved appropriately in the near future. Nowadays, discovery of the clinical issues and formation of novel notions are the most important things.

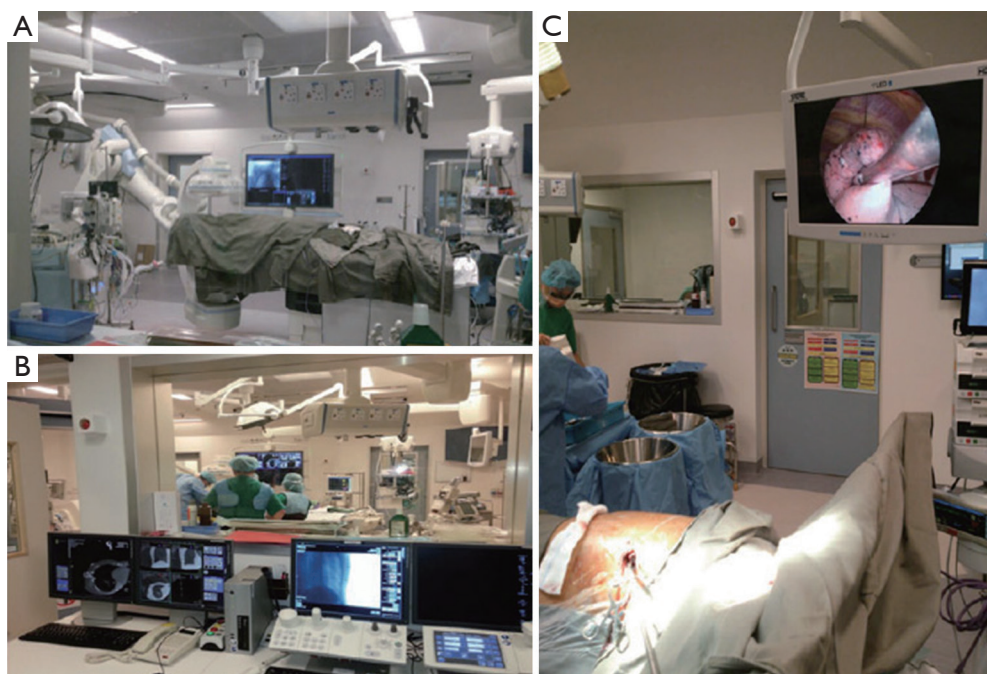


Figure 18 (A) Advanced multimodality image-guided operating room used to perform image-guided video-assisted thoracic surgery; (B) the adjacent control room and; (C) in this case uniportal (single-port) video-assisted thoracic lobectomy (20).

Conclusions

Currently, more and more reports identify the feasibility and safety of single port VATS lobectomy. However, there is no reliable evidence to demonstrate the potential superior short and long term effects of single port approach for the reason that it is a newer technique. As accumulation of experience and many ongoing clinical trials among the units (including ours), confirmation of the advantages of single port VATS is just around the corner. Needless to say, along with the development of devices and concepts, there is no doubt that it is an exciting and intriguing future.

Acknowledgements

None.

Footnote

Conflicts of Interest: The authors have no conflicts of interest to declare.

References

1. Rocco G, Martin-Ucar A, Passera E. Uniportal VATS wedge pulmonary resections. *Ann Thorac Surg* 2004;77:726-8.
2. Jutley RS, Khalil MW, Rocco G. Uniportal vs standard three-port VATS technique for spontaneous pneumothorax: comparison of post-operative pain and residual paraesthesia. *Eur J Cardiothorac Surg* 2005;28:43-6.
3. Rocco G, Brunelli A, Jutley R, et al. Uniportal VATS for mediastinal nodal diagnosis and staging. *Interact Cardiovasc Thorac Surg* 2006;5:430-2.
4. Athanassiadi K, Kakaris S, Theakos N, et al. Muscle-sparing versus posterolateral thoracotomy: a prospective study. *Eur J Cardiothorac Surg* 2007;31:496-9; discussion 499-500.
5. Elshiekh MA, Lo TT, Shipolini AR, et al. Does muscle-sparing thoracotomy as opposed to posterolateral thoracotomy result in better recovery? *Interact Cardiovasc Thorac Surg* 2013;16:60-7.
6. McKenna RJ Jr, Houck W, Fuller CB. Video-assisted thoracic surgery lobectomy: experience with 1,100 cases. *Ann Thorac Surg* 2006;81:421-5; discussion 425-6.
7. Zhu Q, Xiao H, Xu E, et al. Right middle lobectomy: the first case of c-VATS lobectomy we performed in October, 2005. *Asvide* 2015;2:109. Available online: <http://www.asvide.com/articles/551>

8. Zhu Q, Xiao H, Xu E, et al. Uniportal VATS right upper lobectomy. *Asvide* 2015;2:110. Available online: <http://www.asvide.com/articles/552>
9. Gonzalez-Rivas D, Paradelo M, Fieira E, et al. Single-incision video-assisted thoracoscopic lobectomy: initial results. *J Thorac Cardiovasc Surg* 2012;143:745-7.
10. Gonzalez-Rivas D, Paradelo M, Fernandez R, et al. Uniportal video-assisted thoracoscopic lobectomy: two years of experience. *Ann Thorac Surg* 2013;95:426-32.
11. Gonzalez-Rivas D, Fieira E, Delgado M, et al. Uniportal video-assisted thoracoscopic lobectomy. *J Thorac Dis* 2013;5 Suppl 3:S234-45.
12. Zhu Q, Xiao H, Xu E, et al. Transform single port to multiport VATS to manage bleeding. *Asvide* 2015;2:111. Available online: <http://www.asvide.com/articles/553>
13. Cadeddu J, Fernandez R, Desai M, et al. Novel magnetically guided intra-abdominal camera to facilitate laparoendoscopic single-site surgery: initial human experience. *Surg Endosc* 2009;23:1894-9.
14. Park BJ, Flores RM, Rusch VW. Robotic assistance for video-assisted thoracic surgical lobectomy: technique and initial results. *J Thorac Cardiovasc Surg* 2006;131:54-9.
15. Park BJ. Robotic lobectomy for non-small cell lung cancer (NSCLC): Multi-center registry study of long-term oncologic results. *Ann Cardiothorac Surg* 2012;1:24-6.
16. Park BJ. Robotic lobectomy for non-small cell lung cancer: long-term oncologic results. *Thorac Surg Clin* 2014;24:157-62, vi.
17. Ding J, Goldman RE, Xu K, et al. Design and Coordination Kinematics of an Insertable Robotic Effectors Platform for Single-Port Access Surgery. *IEEE ASME Trans Mechatron* 2013:1612-24.
18. Paul S, Jalbert J, Isaacs AJ, et al. Comparative effectiveness of robotic-assisted vs thoracoscopic lobectomy. *Chest* 2014;146:1505-12.
19. Rocco G, Cicalese M, La Manna C, et al. Ultrasonographic identification of peripheral pulmonary nodules through uniportal video-assisted thoracic surgery. *Ann Thorac Surg* 2011;92:1099-101.
20. Ng CS, Rocco G, Wong RH, et al. Uniportal and single-incision video-assisted thoracic surgery: the state of the art. *Interact Cardiovasc Thorac Surg* 2014;19:661-6.

Cite this article as: Zhu Q, Xiao H, Xu E, Liao M, Tang Y, Xuan Y, Su K, He Z, Peng X, Zhang Z, Liu Y, Qiao G. From open to single port video-assisted thoracoscopic lobectomy: a stepwise and return progression of the experience from Department of Thoracic Surgery, General Hospital of Guangzhou Military Command of P.L.A. *J Thorac Dis* 2015;7(7):1252-1263. doi: 10.3978/j.issn.2072-1439.2015.06.12