

# Unusual Presentation of Dengue Fever-Cerebral Venous Thrombosis

NATARAJAN VASANTHI<sup>1</sup>, PRADHOSH M VAIRAMON<sup>2</sup>, THIRUVENGADAM GOWTHAM<sup>3</sup>, ASHOK KUMAR DAS<sup>4</sup>

## ABSTRACT

Dengue infection can present as febrile illness with thrombocytopenia, dengue shock syndrome and dengue haemorrhagic fever. Neurological manifestation of dengue infection is more predominant in endemic region. Here, we report a case with unusual neurological presentation of dengue infection. A 16-year-old boy presented with fever for two week duration, headache and double vision involving left eye for two days. He had multiple erythematous rashes all over the body on 3<sup>rd</sup> day and treated conservatively. On examination he had bilateral papilloedema, left eye restricted abduction. His investigation revealed thrombocytopenia and positive dengue serology. His MRI brain with venogram showed bilateral transverse sinus thrombosis. Hence he was diagnosed as cerebral venous thrombosis due to dehydration with underlying dengue infection. He was hydrated and managed conservatively. On 3<sup>rd</sup> day his double vision started improving. His repeat MR Venogram was done after two week duration, which revealed recanalisation of bilateral transverse sinus.

**Keywords:** Double vision, Papilloedema, Thrombocytopenia

## CASE REPORT

A 16-year-old boy presented to our tertiary care centre in puducherry in the month of October 2014 with high grade, intermittent fever for 10 days duration. He had double vision involving left eye and headache for two days duration. He had multiple erythematous lesion all over the body on 3<sup>rd</sup> day of fever. At home his skin rash was assumed as chicken pox by mother; he was kept at home and treated conservatively with antipyretics.

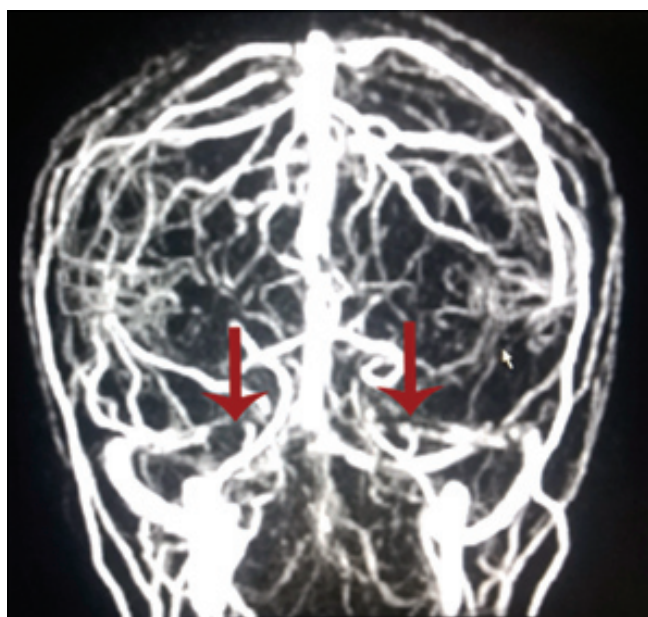
As he developed double vision he was referred to our hospital. There was no vomiting. On admission, his vitals were normal. There was no skin rashes. His fundus showed-bilateral papilloedema, left eye restricted abduction. There was no neck stiffness. Other system examination was normal.

His investigation revealed thrombocytopenia with platelet count 45000 /cumm, total count-7100/cumm Hb-13gm%, PCV -39.4, elevated liver enzymes SGOT-82u/L SGPT-187U/L.

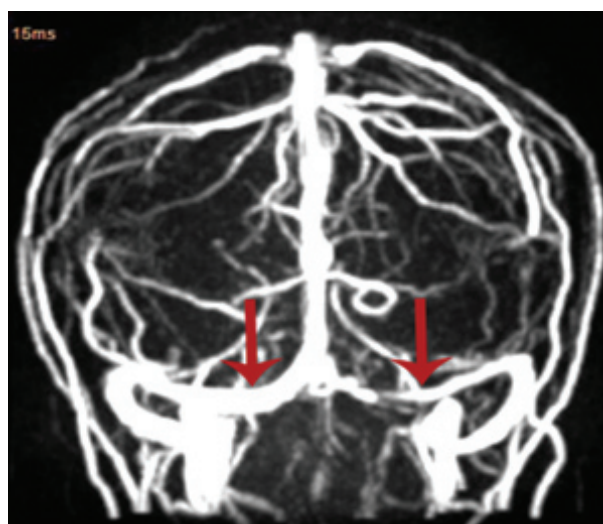
His dengue serology Ig M & Ig G -positive. As he had fever, double vision and papilloedema MRI brain with venogram [Table/Fig-1] was done which showed- bilateral transverse sinus thrombosis.

He was diagnosed as cerebral venous thrombosis due to severe dehydration with underlying dengue infection. As main treatment option in dengue fever is proper hydration, he was hydrated well and serial platelet count was monitored. His initial CSF analysis showed total count-81 with lymphocytic predominance 88%, elevated protein-321mg/dl sugar-65 mg/dl.

On 3<sup>rd</sup> day his double vision started improving. On 5<sup>th</sup> day it disappeared. As CVT is due to severe dehydration with underlying viral infection, and there was improvement in vision, anticoagulation was not started. He was treated conservatively with antipyretics and parenteral fluid replacement. After two week his repeat MRI brain with venogram [Table/Fig-2] was done which revealed recanalisation of bilateral transverse sinus.



[Table/Fig-1]: MRI brain venogram showing bilateral thrombosis of transverse sinus



[Table/Fig-2]: Repeat - MRI brain venogram showing complete recanalisation of left transverse sinus

## DISCUSSION

Cerebral venous thrombosis (CVT) is more common in females especially during pregnancy and puerperium. Though so many genetic and acquired causes has been demonstrated for CVT, infectious causes are reduced nowadays, because of advances in the newer medications. Severe dehydration can also causes venous thrombosis. Here we report a case of CVT in a patient with dengue infection due to severe dehydration.

Dengue infection is caused by a virus belongs to genus *Flavivirus*. There are four serologically distinct viruses that spread infection through mosquito. Because of multiple serotypes it causes periodic epidemics. Dengue infection can present as maculopapular skin rash on third or fourth day of illness. The clinical manifestation of dengue infection is mild febrile illness, haemorrhagic fever and dengue shock syndrome.

The common neurologic presentation with dengue infection is impaired level of consciousness, coma, focal or generalized seizures, focal neurologic deficit. Our patient presented with double vision involving left eye. In 2009 WHO criteria for diagnosis of dengue infection has included neurologic manifestation with impaired conscious level. Among the various clinical presentation of dengue fever neurologic manifestation constitutes about 1% [1].

Neurological manifestation of dengue infection are encephalitis, meningitis, vascular events either haemorrhage or thrombosis, guillian barre syndrome, acute disseminated encephalomyelitis, transverse myelitis, and cranial nerve involvement and neuro ophthalmic events. The predominant reported neurologic manifestation is dengue encephalitis [2,3].

Cerebrovascular events especially haemorrhage is more common than ischemic events in dengue infection [1]. Among the total dengue cases 0.26% of stroke has been reported from Indian Study [4]. Less common areas of haemorrhage reported are cerebellar, pontine haemorrhage, pituitary adenoma with haemorrhage [1], subarachnoid haemorrhage [5]. Pathogenesis behind the vascular events are multifactorial- release of cytokines, plasma leakage, increased capillary permeability, thrombocytopenia, altered prothrombin time [1].

There is only one case report of CVT due to underlying dengue infection treated with anticoagulation [6]. Dengue infection presenting as diplopia is rare. Venous thrombosis in dengue infection is mainly due to severe dehydration resulting from plasma leakage. Dehydration related CVT secondary to diabetic ketoacidosis [7], hyperosmolar nonketotic state, acute gastroenteritis [8] has been reported previously. Though the clinical presentation of dengue fever varies from asymptomatic to organ failure, proper hydration is very important in early stages to prevent such a neurological complication like CVT.

In our patient, his skin rash was assumed as chickenpox by mother, he was kept at home without adequate hydration. Then he

presented with headache, double vision and diagnosed as CVT and he improved with hydration and antipyretics.

In managing dehydration related venous thrombosis the need of anticoagulation should be individualized. There are case reports with dehydration related cvt due to underlying diabetic ketoacidosis and acute gastroenteritis, in which anticoagulation was started and improved [7,8]. Apart from dengue viral infection, CVT secondary to parasitic infection-malarial fever (*plasmodium falciparum* and *vivax*) [9] and leptospirosis [10] has been reported.

## CONCLUSION

As severe dehydration is one of the causes for cerebral venous sinuses, proper and adequate hydration in the initial period is very important to prevent dreaded dengue related neurological complications. Proper hydration could achieve complete recanalisation of sinuses without anticoagulation. In endemic region any patient with fever, thrombocytopenia and acute neurological symptoms underlying dengue infection should be ruled out.

## ACKNOWLEDGMENT

I acknowledge Department of Neurology for their support.

## REFERENCES

- [1] Carod-Artal FJ, Wichmann O, Farrar J, Gascón J. Neurological complications of dengue virusinfection. *Lancet Neurol*. 2013;12(9):906-19.
- [2] Misra UK, Kalita J, Syam UK, Dhole TN. Neurological manifestations of dengue virus Infection. *J Neurol Sci*. 2006;244(1-2):117-22.
- [3] Solomon T, Dung NM, Vaughn DW, Kneen R, Thao LT, Raengsakulrach B, et al. Neurological manifestations of dengue infection. *Lancet*. 2000;355(9209):1053.
- [4] Mathew S, Pandian JD. Stroke in patients with dengue. *J Stroke Cerebrovasc Dis*. 2010;19(3): 253-56.
- [5] Patey O, Ollivaud L, Breuil J, Lafaix C. Unusual neurologic manifestations occurring during dengue fever infection. *Am J Trop Med Hyg*. 1993;48(6):793-802.
- [6] Tilara M, Shah AN, Negi S, Dadhania J. A Case of Cerebral Venous Thrombosis in the Patient with Dengue. *International Journal of Scientific and Research Publications*. 2014;4(8).
- [7] Keane S, Gallagher A, Ackroyd S, Mc Shane MA, Edge JA. Cerebral venous thrombosis during diabetic ketoacidosis. *Arch Dis Child*. 2002;86:204-05.
- [8] Kuo EY, Chung MH, Lin HJ, Chen KT. Gastroenteritis followed by headache: A rare presentation of cerebral venous thrombosis. *Journal of Acute Medicine*. 2012; 2(3):92-4.
- [9] Krishnan A, Karnad DR, Limaye U, Siddharth W. Cerebral venous and dural sinus thrombosis in severe falciparum malaria. *J Infect*. 2004;48(1):86-90.
- [10] V Turhan, et al. Cerebral venous thrombosis as a complication of leptospirosis. *Journal of Infection*. 2007;53(6):e247-49.

### PARTICULARS OF CONTRIBUTORS:

1. Assistant Professor, Department of Medicine, Pondicherry Institute of Medical Science, Puducherry, India.
2. Senior Resident, Department of Medicine, Pondicherry Institute of Medical Science, Puducherry, India.
3. Senior Resident, Department of Medicine, Pondicherry Institute of Medical Science, Puducherry, India.
4. Professor, Department of Medicine, Pondicherry Institute of Medical Science, Puducherry, India.

### NAME, ADDRESS, E-MAIL ID OF THE CORRESPONDING AUTHOR:

Dr. Natarajan Vasanthi,  
Assistant Professor, Department of Medicine, Pondicherry Institute of Medical Science,  
Puducherry-605014, India.  
Email: vasanthikarthi2004@yahoo.co.in

FINANCIAL OR OTHER COMPETING INTERESTS: None.

Date of Submission: **Jan 20, 2015**

Date of Peer Review: **Apr 14, 2015**

Date of Acceptance: **May 01, 2015**

Date of Publishing: **Jun 01, 2015**