

# In Vivo Confocal Microscopy Demonstrates Bilateral Loss of Endothelial Cells in Unilateral Herpes Simplex Keratitis

Rodrigo T. Müller,<sup>1</sup> Roxanna Pourmirzaie,<sup>1</sup> Deborah Pavan-Langston,<sup>1</sup> Bernardo M. Cavalcanti,<sup>1</sup> Shruti Aggarwal,<sup>1</sup> Clara Colón,<sup>1</sup> Arsia Jamali,<sup>2</sup> Andrea Cruzat,<sup>1</sup> and Pedram Hamrah<sup>1,2</sup>

<sup>1</sup>Ocular Surface Imaging Center, Cornea & Refractive Surgery Service, Massachusetts Eye & Ear, Harvard Medical School, Boston, Massachusetts, United States

<sup>2</sup>Schepens Eye Research Institute, Massachusetts Eye & Ear, Department of Ophthalmology, Harvard Medical School, Boston, Massachusetts, United States

Correspondence: Pedram Hamrah, Cornea Service, New England Eye Center, Department of Ophthalmology, Tufts Medical Center, Tufts University School of Medicine, 800 Washington Street, Boston, MA 02111, USA; phamrah@tuftsmedicalcenter.org.

Submitted: January 23, 2015

Accepted: June 9, 2015

Citation: Müller RT, Pourmirzaie R, Pavan-Langston D, et al. In vivo confocal microscopy demonstrates bilateral loss of endothelial cells in unilateral herpes simplex keratitis. *Invest Ophthalmol Vis Sci*. 2015;56:4899–4906. DOI:10.1167/iov.15-16527

**PURPOSE.** To report bilateral corneal endothelial cell density (ECD), as well as its correlation with subbasal nerve changes, in patients with unilateral herpes simplex keratitis (HSK).

**METHODS.** Thirty-six eyes of 36 patients with corneal scarring caused by HSK, as well as their respective contralateral clinically unaffected eyes, were prospectively studied and compared with 26 eyes of 26 healthy volunteers. In vivo confocal microscopy and corneal sensation of the central cornea were performed bilaterally in all patients and in one random eye of controls. The ECD and subbasal corneal nerve density, including the lengths of total nerves, main trunks, and branches were evaluated and correlated to central corneal sensation.

**RESULTS.** The ECD was significantly lower in eyes affected with HSK than in controls ( $2304 \pm 578$  vs.  $2940 \pm 370$  cells/mm<sup>2</sup>,  $P < 0.0001$ ). Surprisingly, lower ECD was also detected in contralateral clinically unaffected eyes ( $2548 \pm 423$ ), compared to controls ( $P = 0.02$ ). Both affected and contralateral eyes showed decrease in total nerve length, compared to controls ( $10.0 \pm 6.3$  vs.  $17.6 \pm 6.3$  vs.  $21.9 \pm 4.3$  mm/mm<sup>2</sup>, respectively;  $P < 0.05$  for all). The ECD correlated positively with total nerve length ( $r = 0.39$ ,  $P = 0.0009$ ) and with corneal sensation ( $r = 0.31$ ,  $P = 0.009$ ).

**CONCLUSIONS.** In vivo confocal microscopy findings demonstrated alterations in corneal ECD in both affected and clinically unaffected contralateral eyes of patients with unilateral HSK. Moreover, the positive significant correlation between the ECD and the subbasal nerve density may suggest a potential link between corneal innervation and corneal endothelial cell homeostasis.

**Keywords:** neurotrophic keratopathy, corneal endothelial cells, corneal innervation, in vivo confocal microscopy

The herpes simplex viruses (HSVs) are ubiquitous pathogens, capable of causing either asymptomatic or symptomatic disease. Herpes simplex virus keratitis (HSK) is the most frequent infectious cause of blindness in developed countries.<sup>1</sup> Liesegang et al.<sup>2</sup> have reported an incidence of 8.4 primary ocular HSV infections per 100,000 person-years. Moreover, further investigation of the natural history of HSK shows a recurrence rate, after the first episode, of 9.6% at 1 year, 22.9% at 2 years, and 63.2% at 20 years.<sup>2</sup>

The cornea is the most densely innervated tissue of the body, supplied by the terminal branches of the ophthalmic division of the trigeminal nerve as ciliary nerves.<sup>3,4</sup> Corneal nerves penetrate the corneal periphery in a radial distribution and form the subbasal nerve plexus between the Bowman's layer and the basal epithelium.<sup>3</sup> Corneal innervation provides protective and trophic functions and regulates epithelial integrity, proliferation, and wound healing.<sup>5,6</sup> Recently, in vivo confocal microscopy (IVCM) has greatly advanced the microscopic evaluation of ocular structures. Specifically, the corneal subbasal nerve plexus and endothelial layers have been shown to be important indicators of corneal health and disease.<sup>7–10</sup>

One of the sequelae of HSK is neurotrophic keratopathy, caused by impaired corneal innervation.<sup>1,11</sup> The insufficient supply of trophic neural factors and impairment of the tear and blink reflexes are caused by loss of corneal innervation.<sup>2,12</sup> More recent studies<sup>5,6,13,14</sup> have shown changes in subbasal corneal nerves in patients with early-stage Fuchs' endothelial corneal dystrophy (FECD). These findings suggest that corneal nerve alterations may be involved not only in the pathogenesis of FECD, but also potentially in other diseases resulting in decreased endothelial cell density. The embryologic similarities between endothelium and neuronal cells may support the theory that FECD has a neurodegenerative component.<sup>7–10,15</sup> Further, Koh et al.<sup>16,17</sup> have reported that the neuropeptide vasoactive intestinal peptide (VIP) has a protective effect on the corneal endothelium, playing an active role in maintaining the differentiated state and suppressing apoptosis in endothelial cells. Finally, in a recent preclinical study, we have demonstrated that trigeminal nerve axotomy results in a continuous loss of corneal endothelial cells centrally and peripherally, which correlates with a significant decrease in VIP after axotomy. Loss of endothelial cells is prevented through daily replenishment of the neuropeptide VIP (Yamaguchi T, et al. *IOVS* 2014;55:ARVO E-Abstract 2077).

Thus, in the current study, hypothesizing that corneal nerves may mediate endothelial cell homeostasis, we performed IVCM in patients with a unilateral HSK, in order to analyze bilateral corneal endothelial cell density (ECD), as well as its correlation to subbasal nerve morphology and function.

## PATIENTS AND METHODS

### Patients

This was a prospective, cross-sectional, and controlled single-center study conducted in patients with unilateral corneal scarring due to a history of HSV keratitis. None of the patients was immunocompromised, and all eyes had a single focal central or peripheral corneal scar, with no signs of active keratitis. Both the affected and the contralateral clinically unaffected eyes were studied. Subjects were recruited from the Cornea Service of the Massachusetts Eye & Ear Infirmary, Harvard Department of Ophthalmology, Boston, Massachusetts, between 2010 and 2014, during their periodic clinical follow-up visits. Subjects with a history of ocular inflammatory disease, nonherpetic infectious keratitis, endotheliitis, keratouveitis, ocular trauma, ocular surgery, contact lens use, diabetes, or any other systemic neuropathies were excluded from the study. The control group consisted of healthy volunteers without diabetes, any inflammatory systemic disease, any history of infectious or inflammatory eye disease, a history of ocular surgery, current use of contact lenses, or current use of eye drops. Before recruitment into the study, all patients and healthy subjects underwent a complete baseline ophthalmologic examination, including visual acuity measurement, anterior segment evaluation with a slit-lamp biomicroscope, fundus examination, and intraocular pressure measurement.

The protocol was approved by the Institutional Review Board/Ethics Committee from the authors' institution, complied with the Health Insurance Portability and Accountability Act, and was conducted in accordance with the provisions of the Declaration of Helsinki. Informed consent was obtained from the subjects after explanation of the nature and possible consequences of the study.

### In Vivo Confocal Microscopy

Laser scanning IVCM (Heidelberg Retina Tomograph 3 with the Rostock Cornea Module; Heidelberg Engineering GmbH, Heidelberg, Germany) of the central cornea was performed in all subjects as previously described.<sup>7</sup> This microscope uses a 670-nm wavelength diode laser source and is equipped with a 63× objective immersion lens with a numerical aperture of 0.9 (Olympus, Tokyo, Japan). The laser confocal microscope provides images that represent a coronal section of the cornea of 400 × 400 μm, which is 160,000 μm<sup>2</sup>, at a selectable corneal depth, and is separated from adjacent images by approximately 1 to 4 μm, with a lateral resolution of 1 μm/pixel. Digital images were stored on a computer workstation at three frames per second. A disposable sterile polymethylmethacrylate cap (Tomo-Cap; Heidelberg Engineering GmbH), filled with a layer of hydroxypropyl methylcellulose 2.5% (GenTeal gel; Novartis Ophthalmics, East Hanover, NJ, USA) in the bottom, was mounted in front of the cornea module optics for each examination. One drop of topical anesthesia 0.5% proparacaine hydrochloride (Alcaine; Alcon, Fort Worth, TX, USA) was instilled in both eyes, followed by a drop of hydroxypropyl methylcellulose 2.5% (GenTeal gel) in both eyes. One drop of hydroxypropyl methylcellulose 2.5% was also placed on the outside tip of the cap to improve optical coupling and manually advanced until the gel contacted the central surface

of the cornea. Corneal images were obtained by asking subjects to fixate their gaze at a red fixation light, assisting the IVCM operator to obtain images at specific corneal locations. Sequence scans were obtained from the central cornea of both eyes in patients with HSV keratitis, and in one randomly selected eye of controls. The three best representative images of the subbasal nerve plexus and the best representative image of the endothelial cell layer were selected for each eye by an experienced investigator (RM), masked to the study groups.

### Corneal Sensation

Corneal sensation was measured in the central area of the cornea, in all subjects, with the Cochet-Bonnet esthesiometer (Luneau Ophthalmologie, Chartres, France) as previously described.<sup>18</sup> This test mechanically stimulates corneal nerves by touching the tip of a retractable 6.0-cm long monofilament nylon thread of 0.12-mm diameter against the corneal surface, decreasing in steps of 1.0 cm if a positive response was not obtained or advancing by 0.5 cm if a positive response was obtained. The longest filament length that resulted in a positive response was considered the corneal threshold.

### Image Analysis

Two observers (RM and RP), masked to the study groups and diagnoses, performed the IVCM image analyses, using the semi-automated tracing program Neuron J,<sup>19</sup> a plug-in for ImageJ 1.46r (<http://www.imagescience.org/meijering/software/>); provided in the public domain by Wayne Rasband, National Institutes of Health [NIH], Bethesda, MD, USA). The nerve densities of the main trunks, branching and total nerves, in addition to ECD, were recorded. Each observer completed the analyses for three subbasal nerve layer images. Total nerve density was assessed by measuring the total length of the nerve fibers in micrometers per square millimeter. Main nerve trunks were defined as the total length of main nerves in square millimeter. Nerve branching was defined as the total length of nerve branches per square millimeter. The number of total nerves, main nerves and branches were defined as the sum of all nerves in one image. The ECD was calculated in a semiautomated fashion by using endothelial cell counter function in the software inbuilt in HRT3 (Heidelberg Eye Explorer, version 1.3.0; Heidelberg Engineering GmbH). At least two observers completed the ECD analyses in two consecutive measurements, for images with the best quality, counting at least 50 cells per image.

### Statistical Analysis

Descriptive statistics, including mean and standard deviation for the normally distributed data, and median, 25th and 75th percentiles for the not normally distributed data, were used. Distribution of data was analyzed by the Kolmogorov-Smirnov test, demonstrating normal distribution of data. The Levene's test was used to evaluate the equality of the variances to assess assumptions of unpaired Student's *t*-test. Unpaired Student's *t*-test and analysis of variance (ANOVA) were applied to compare the differences among groups, where appropriate. Bonferroni post hoc test was used for further analysis among the groups. The  $\chi^2$  test was applied to evaluate the differences among qualitative variables. Pearson correlation coefficient was used to measure the association between quantitative variables. General linear model was applied to adjust the effect of age, sex, time since first episode, time since last episode, scar size, location of the scar, and corneal sensation on the association of nerve parameters and endothelial density.  $P < 0.1$  in univariate analysis was used as the entry level. The intraclass correlation

**TABLE 1.** Baseline Characteristics of Controls and Patients With Corneal Scarring Due to HSK

	Controls	Herpes Simplex Keratitis
No. of patients	26	36
Sex, male/female, <i>n</i>	10/16	17/19*
Age, y	48.8 ± 11.1	53.0 ± 18.8†
Time since first episode, y	—	6.3 (3.2; 13.1)‡
Time since last episode, y	—	0.6 (0.2; 2.8)‡
No. of patients with central/peripheral cornea scar	—	21/15
Quadrant location of peripheral scar, superior/inferior/nasal/temporal	—	6/1/2/6
Corneal scar diameter, <2 mm/>2 mm	—	25/11

Data presented as mean ± standard deviation unless otherwise noted.

\*  $P = 0.50$  ( $\chi^2$  test) compared to controls.

†  $P = 0.31$  (unpaired Student's *t*-test) compared to controls.

‡ Values are expressed as median (25th; 75th percentiles).

coefficient (ICC) was calculated to estimate the repeatability of the measurements between the observers. For each test, differences were considered significant at  $P < 0.05$ .

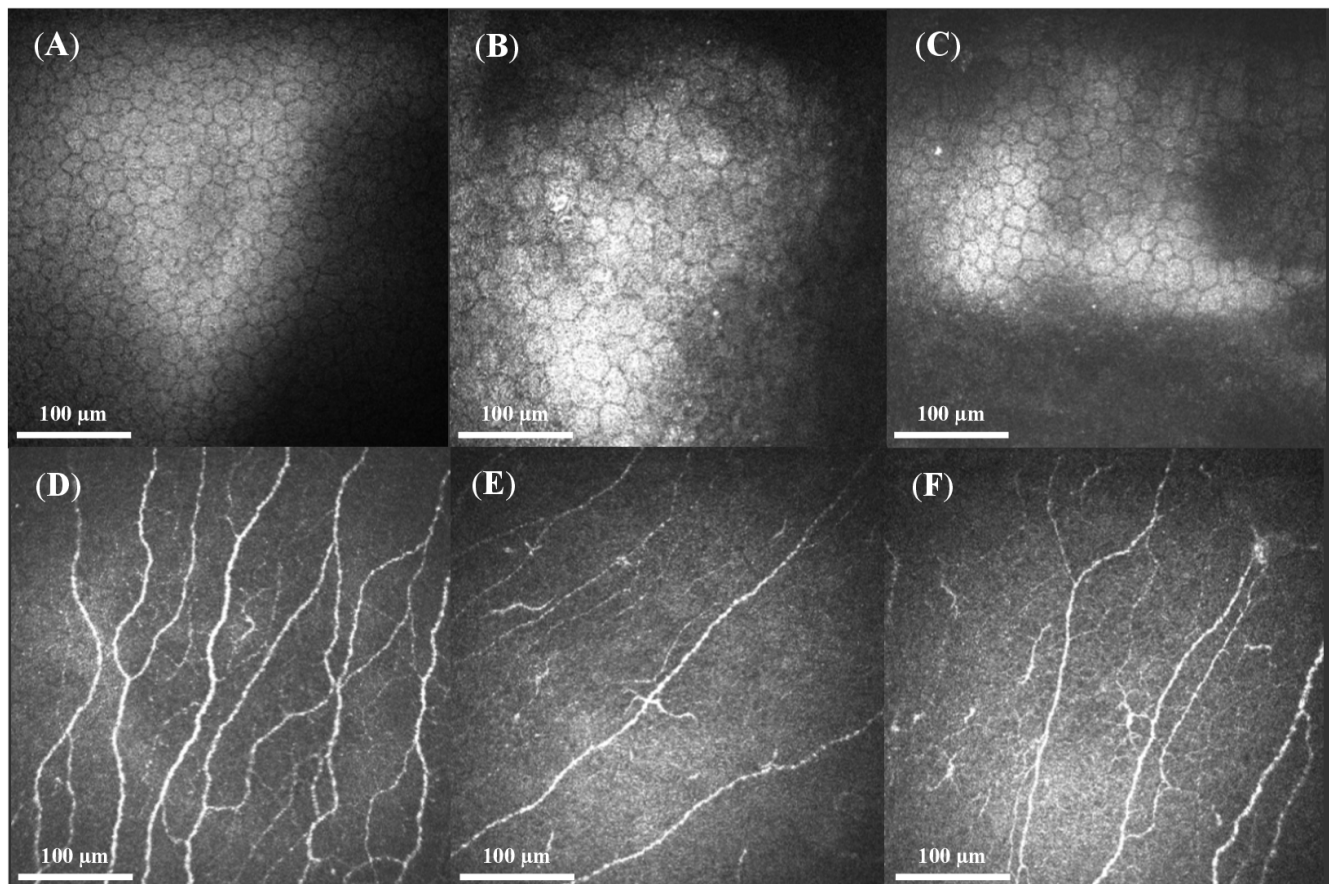
## RESULTS

The results were based on the analysis of 36 eyes of 36 patients with corneal scarring caused by HSK, as well as their respective contralateral clinically unaffected eyes. Twelve patients with history of recurrent keratouveitis, including

anterior uveitis, iritis, trabeculitis, and endotheliitis, in addition to four pseudophakic patients, were not included in the IVC analysis. Twenty-six eyes of 26 age-matched healthy volunteers comprised the control group. Demographics of patients and controls are presented in Table 1.

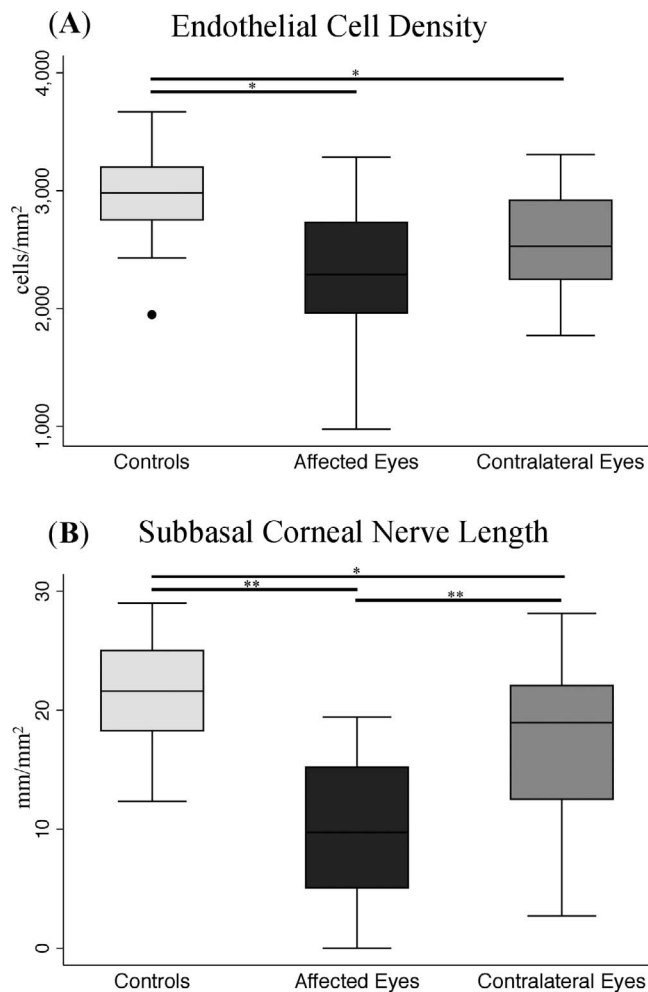
### Corneal Endothelial Cell Density

The mean ECD was significantly lower in affected eyes with corneal scarring due to HSK than in controls ( $2304 \pm 578$  vs.  $2940 \pm 370$  cells/mm<sup>2</sup>,  $P = 0.0001$ ; Figs. 1A, 1B, 2A; Table 2).



**FIGURE 1.** In vivo confocal microscopy images obtained at the level of the endothelial cell layer and subbasal nerve plexus. (A) Normal endothelial cells layer of a normal patient of the control group. (B) Decreased ECD in the affected eye of a patient with HSK. (C) Decreased ECD in the contralateral clinically unaffected eye of a HSK patient. (D) Normal corneal subbasal nerve plexus of a normal patient of the control group. (E) Decrease in number and length of nerves in the affected eye of a patient with HSK. (F) Decrease in number and length of nerves in the contralateral clinically unaffected eye of a HSK patient.





**FIGURE 2.** Graphs showing ECD and subbasal corneal nerve length. (A) Endothelial cell density in affected and clinically unaffected eyes in patients with HSK as well as in the control group. (B) Subbasal corneal nerve alterations in affected and clinically unaffected eyes in patients with HSK, as well as in the control group for total nerve length. \* $P < 0.05$  and \*\* $P < 0.0001$ .

Surprisingly, lower ECD was also detected in contralateral clinically unaffected eyes ( $2548 \pm 423$  cells/mm<sup>2</sup>), compared to controls ( $P = 0.02$ ; Figs. 1A, 1C, 2A; Table 2), while the affected eyes and nonaffected eyes in patients with HSK were not significantly different ( $P = 0.23$ ). The endothelial cell density in patients with central scars ( $2243 \pm 489$ ) was not significantly different from that of patients with peripheral scars

( $2392 \pm 709$ ,  $P = 0.56$ ). No statistical difference was noted between patients with recent HSK (last episode within past 2 years) as compared to patients with HSK of longer than 2 years ( $2281 \pm 662$  vs.  $2329 \pm 477$  cells/mm<sup>2</sup>, respectively,  $P = 0.85$ ).

### Subbasal Corneal Nerve Density

A significant diminishment in the subbasal corneal nerve density was found in affected eyes with HSK, compared with controls, including decreased main nerve trunk length ( $4.8 \pm 3.3$  vs.  $9.6 \pm 2.2$  mm/mm<sup>2</sup>,  $P < 0.0001$ ), branch nerve length ( $5.2 \pm 3.5$  vs.  $12.3 \pm 3.3$  mm/mm<sup>2</sup>,  $P < 0.0001$ ), and total nerve length ( $10.0 \pm 6.3$  vs.  $21.9 \pm 4.3$  mm/mm<sup>2</sup>,  $P < 0.0001$ ; Figs. 1E, 1F, 2B; Table 2). The contralateral clinically unaffected eyes also demonstrated a significant diminishment, compared with the control group, including main nerve trunk length ( $8.0 \pm 2.6$  mm/mm<sup>2</sup>,  $P = 0.01$ ), branch nerve length ( $9.6 \pm 4.8$  mm/mm<sup>2</sup>,  $P = 0.02$ ). Furthermore, the affected eyes demonstrated significantly lower nerve density than the contralateral unaffected eyes ( $P < 0.0001$  for all parameters; Figs. 1F, 1G, 2B; Table 2). Patients with central scars showed significantly lower total nerve length ( $8.1 \pm 6.1$  mm/mm<sup>2</sup>) and total number of nerves ( $6.8 \pm 5.2$  n/frame) in comparison with patients with peripheral scars ( $12.5 \pm 5.7$  and  $11.9 \pm 5.5$ , respectively,  $P < 0.05$  for all). Patients with recent HSK (last episode within past 2 years) showed lower total nerve length ( $7.5 \pm 5.8$  mm/mm<sup>2</sup>) and total number of nerves ( $7.0 \pm 11.6$  n/frame) than patients with last episode of HSK of longer than 2 years ( $13.2 \pm 5.5$  and  $11.6 \pm 5.3$ , respectively,  $P < 0.05$  for all), suggestive of nerve regeneration over time.

### Corneal Sensation

Central corneal sensation in eyes affected with HSK ( $3.4 \pm 2.2$  cm) was lower than that of their contralateral clinically unaffected eyes ( $5.6 \pm 0.9$  cm) and also lower than that of the controls ( $6.0 \pm 0.0$  cm), ( $P < 0.0001$  for both; Table 2). Although the mean of corneal sensation of the contralateral clinically unaffected eyes was lower than that of the controls, the difference was not statistically significant ( $P = 0.08$ ).

### Correlation and Regression Analysis

The two-way ICC, between the observers, was 0.99 (95% confidence interval [CI], 0.98–0.99) for ECD, 0.93 (95% CI, 0.85–0.96) for nerve number parameters, and 0.98 (95% CI, 0.96–0.99) for nerve length parameters.

Significant direct correlations were observed between ECD and nerve density. The ECD correlated positively with branch nerve length ( $r = 0.36$ ,  $P = 0.002$ ), main nerve trunk length ( $r =$

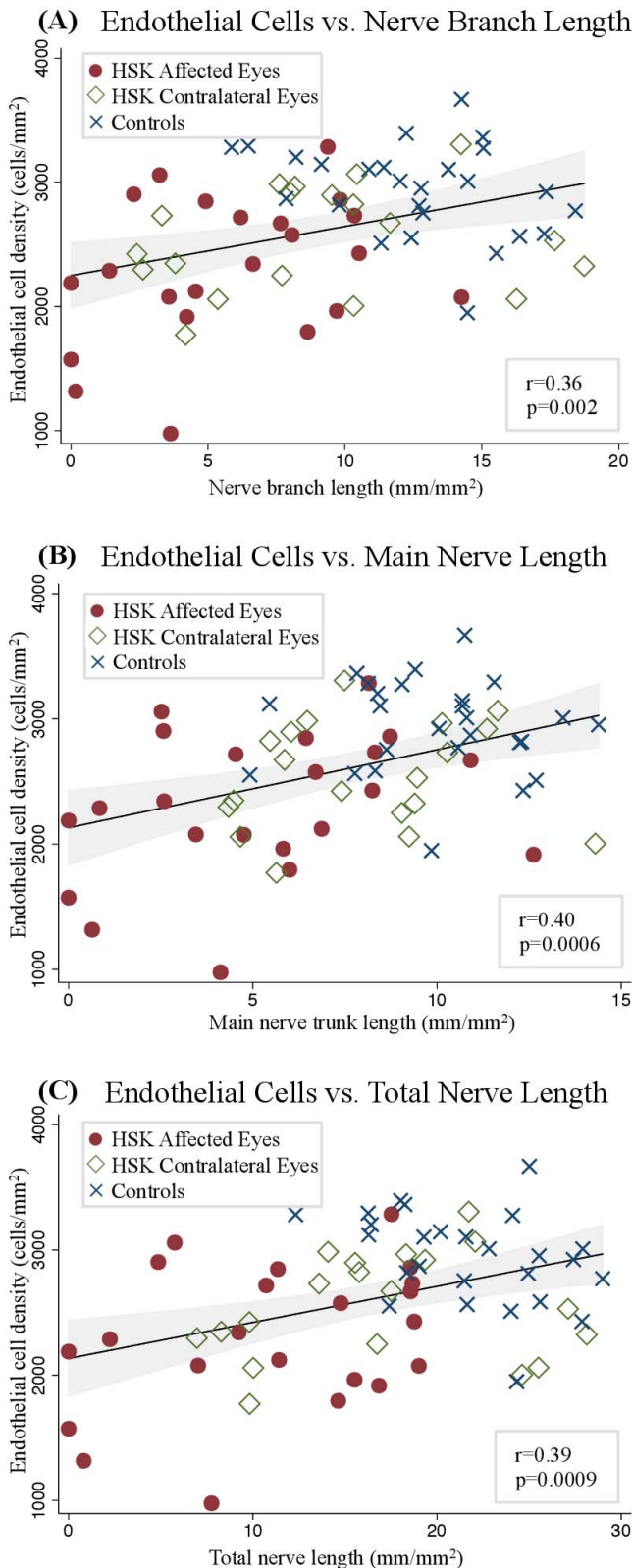
**TABLE 2.** In Vivo Confocal Microscopy Parameters and Corneal Sensation of Controls and Patients With Corneal Scarring Due to HSK

	Controls	Affected Eye	$P^*$	Contralateral Unaffected Eye	$P^*$
Endothelial cell density, cells/mm <sup>2</sup>	$2940 \pm 370$	$2304 \pm 578$	<0.0001	$2548 \pm 423$	0.02
Total nerve length, mm/mm <sup>2</sup>	$21.9 \pm 4.3$	$10.0 \pm 6.3$ †	<0.0001	$17.6 \pm 6.3$	0.02
Main nerve trunk length, mm/mm <sup>2</sup>	$9.6 \pm 2.2$	$4.8 \pm 3.3$ †	<0.0001	$8.0 \pm 2.6$	0.01
Branch nerve length, mm/mm <sup>2</sup>	$12.3 \pm 3.3$	$5.2 \pm 3.5$ †	<0.0001	$9.6 \pm 4.8$	0.01
Total number of nerves, n/frame	$20.6 \pm 8.2$	$9.0 \pm 5.9$ †	<0.0001	$16.8 \pm 8.0$	0.18
No. of main nerve trunks, n/frame	$3.9 \pm 0.8$	$1.9 \pm 1.4$ †	<0.0001	$3.3 \pm 1.1$	0.07
No. of branch nerves, n/frame	$16.7 \pm 7.9$	$7.1 \pm 4.8$ †	<0.0001	$13.5 \pm 7.4$	0.17
Corneal sensation, cm	$6.0 \pm 0.0$	$3.4 \pm 2.2$ †	<0.0001	$5.6 \pm 0.9$	0.9

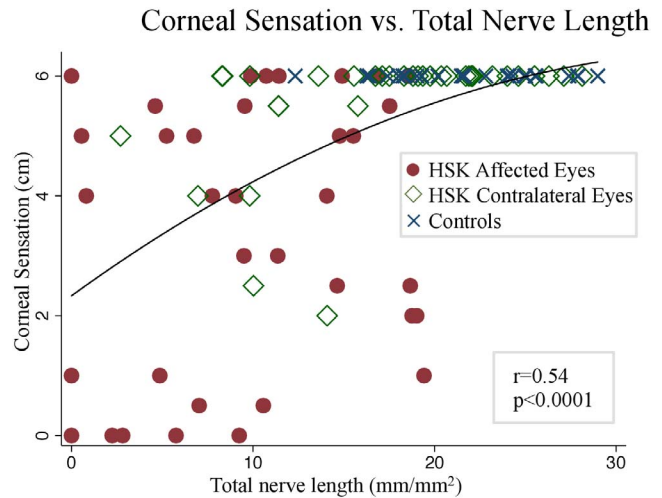
Data presented as mean  $\pm$  standard deviation.

\* Comparison between studied groups and controls (ANOVA with Bonferroni post hoc analysis).

†  $P < 0.0001$ , comparison between affected and contralateral unaffected eyes.



**FIGURE 3.** Graphs showing the correlation between ECD and corneal subbasal nerve parameters. Endothelial cell density is correlated significantly to nerve branch length (A), main nerve length (B), and total nerve length (C). Pearson's correlation coefficients ( $r$ ) and  $P$  values are shown.



**FIGURE 4.** Graph showing the correlation between corneal sensation and total nerve length. Pearson's correlation coefficient ( $r$ ) and  $P$  value are shown.

0.40,  $P = 0.0006$ ), and total nerve length ( $r = 0.39$ ,  $P = 0.0009$ ; Figs. 3A-C).

Corneal sensation showed a significant correlation with main nerve length ( $r = 0.53$ ,  $P < 0.0001$ ), branch nerve length ( $r = 0.47$ ,  $P < 0.0001$ ), and total nerve length ( $r = 0.54$ ,  $P < 0.0001$ ; Fig. 4). A significant positive correlation was found between ECD and corneal sensation ( $r = 0.31$ ,  $P = 0.009$ ).

General linear model demonstrated that after multiple adjustments for age, sex, time since first episode, time since last episode, number of recurrences, size of the corneal scar, and corneal sensation, the association between the nerve density parameters and ECD remained significant in the model; specifically, main nerve length ( $\beta = 0.31$  and  $P = 0.01$ ), branch nerve length ( $\beta = 0.86$  and  $P = 0.002$ ), and total nerve length ( $\beta = 0.55$  and  $P = 0.007$ ) were independent predictors of ECD in the model.

## DISCUSSION

The present laser IVCM study demonstrated that the density of the subbasal corneal nerve plexus was reduced both in eyes affected with HSK and in contralateral clinically unaffected eyes, as compared to controls, consistent with our previous study performed with white light confocal microscopy.<sup>18</sup> Although corneal innervation is believed to be mediated along a unilateral ophthalmic nerve pathway,<sup>20</sup> bilateral nerve alterations after unilateral nerve damage have recently been reported by our group in patients with HSK<sup>18</sup> and more recently in those with herpes zoster ophthalmicus (HZO).<sup>21</sup> In both HSK and HZO patients, the loss of corneal sensation has been correlated with profound diminishment of the subbasal nerve plexus.

Herein, we observed a statistically significant decrease in ECD in eyes with HSK, as well as their respective contralateral clinically unaffected eyes, compared to eyes of healthy controls. Our data further showed a significant correlation between the ECD and the subbasal corneal nerve density. To our knowledge, this is the first study showing a bilateral decrease of ECD in eyes with unilateral corneal disease.

Neuropeptides and neurotrophins, such as substance P, VIP, calcitonin gene-related peptide,  $\alpha$ -melanocyte-stimulating hormone, nerve growth factor, brain-derived neurotrophic factor, and glial cell-derived neurotrophic factor are found in

the cornea with anti-inflammatory and antiapoptotic effects.<sup>16,22-24</sup> In addition, the corneal endothelium has been shown to secrete VIP and ciliary neurotrophic factor.<sup>25,26</sup> Interestingly, VIP has been shown to suppress inflammation and to promote the survival of endothelial cells in stored human donor corneoscleral grafts.<sup>16,17,27</sup> In a recent preclinical study (Yamaguchi T, et al. *IOVS* 2014;55:ARVO E-Abstract 2077), our group has shown that trigeminal axotomy results in continuous loss of corneal ECD in the axotomized eye, as compared to sham procedures. Furthermore, we have shown that VIP gene and protein expression levels are significantly decreased after the axotomy, as compared to controls. Additionally, daily injection of intraperitoneal VIP after axotomy prevents loss of central corneal endothelial cells. These preliminary findings support the hypothesis that the peripheral nervous system may promote corneal endothelial cell survival and homeostasis (Yamaguchi T, et al. *IOVS* 2014;55:ARVO E-Abstract 2077). Our IVCM data in the current study demonstrated low subbasal nerve and endothelial cell densities in the contralateral clinically unaffected eye of patients with corneal scar due to HSK. The low to moderate positive correlations between ECD and subbasal corneal nerve parameters could potentially be attributed to the fact that bilateral loss of corneal nerves observed after unilateral HSK could result in decreased levels of neuropeptides, including VIP, subsequently resulting in bilateral endothelial cell loss.

Recently, studies from our group and others have demonstrated alterations in corneal innervation in patients with early-stage FECD.<sup>13,14</sup> The significant correlation between ECD and corneal nerve densities supports the theory of a potential interaction between corneal innervation and endothelial cell homeostasis.<sup>14</sup> In addition, previous studies<sup>28,29</sup> have shown that the mean central subbasal nerve density is significantly reduced in patients with corneal edema, including patients with FECD, pseudophakic bullous keratopathy, recurrent HSK, and glaucoma filtration surgery. Moreover, Zuh et al.<sup>15</sup> have recently suggested that FECD may be a neurodegenerative disorder, on the basis of similarities in the embryologic origins between the corneal endothelium and neuronal cells. The corneal endothelium originates from the cranial neural crest and migrates over the corneal stroma during embryogenesis.<sup>30</sup> Human corneal endothelial cells contain precursors that retain neuronal markers with the capability to differentiate into endothelial cells, but they can also produce neuronal and mesenchymal cell proteins.<sup>15,30,31</sup> Moreover, in a study performed in patients who developed unilateral neurotrophic keratopathy after neurosurgery, Lambiase et al.<sup>32</sup> have demonstrated that in addition to a significant decrease in subbasal nerve density and corneal sensation, the ECD is also significantly reduced in the neurotrophic eyes compared with both contralateral unaffected eyes and healthy controls. Moreover, lower ECD is also associated with a longer duration of neurotrophic keratopathy. Previous studies<sup>33,34</sup> have shown evidence that the contralateral diminishment of corneal nerves could be mediated by the central nervous system in a neurogenic fashion, with peripheral trigeminal nerve fibers being directly projected to bilateral areas of brainstem nuclei and the caudal medulla. Therefore, primary trigeminal fibers could cross the pontine tegmentum to reach the contralateral principal nucleus. The presence of these nervous system circuits makes it possible that unilateral nerve injury may result in bilateral changes in central nervous system signaling.<sup>21</sup> Although these data are in line with our current study and suggest that impairment of corneal innervation may induce alterations of endothelial cell function, they do not allow for conclusions about a direct link between nerve damage leading to ECD loss.

Hillenaar et al.<sup>35</sup> have previously reported endothelial cell alterations in patients with HSK. In their study, there is a significant difference between the ECD in the eyes affected by HSV keratitis and the contralateral clinically unaffected eyes. However, in the current study, we also demonstrated significantly lower ECD in both affected and contralateral clinically unaffected eyes in patients with HSK, when compared to healthy controls. This discrepancy can be explained by the distinct difference regarding the mean ECD in the two control groups of the two studies. The stringent inclusion and exclusion criteria defined in our control group (including the absence of diabetes, any inflammatory systemic disease, any history of infectious or inflammatory eye disease, a history of ocular surgery, and current use of contact lenses) could be factors in accounting for the higher mean ECD found in our healthy controls, compared to the study by Hillenaar et al.<sup>35</sup> While there is a relatively wide range regarding the average of the ECD in the healthy population cited in the literature, our stringent inclusion and exclusion criteria resulted in a higher normal control range than that reported in the study by Hillenaar et al.<sup>35</sup> but one that is in line with several other studies that demonstrate a similar range.<sup>36-40</sup>

Vannas et al.<sup>41</sup> have previously reported a mean ECD of 2947 and 2990 cells/mm<sup>2</sup> in the affected and contralateral clinically unaffected eyes of patients with herpetic keratouveitis. In that study, the interval between the acute phase of the HSK and the date of corneal imaging is on average 16.1 weeks. In our study, by contrast, the acute phase predated the time of corneal imaging on average by 11.3 years. Considering that HSK typically recurs, the immune-mediated recurrent episodes over time can lead to a cumulative increase in damage to the subbasal corneal nerve plexus, as well as to the endothelial layer.

Patients with more recent HSK showed a lower nerve density than patients with HSK of longer than 2 years' duration; nevertheless, no difference was found in ECD between these two groups. These data suggest nerve regeneration over time, which has been demonstrated in a variety of conditions that cause corneal nerve damage, such as after corneal transplants, corneal laser refractive surgeries, and after infectious keratitis, including HSV keratitis.<sup>9,42-46</sup> In contrast, previous reports<sup>47,48</sup> have shown that endothelial cells have a limited proliferative capacity, not proliferating at all or in a rate that does not follow the rate of cell loss. Thus, the limitation in corneal endothelial cell proliferation corroborates our current data, as even with increase in corneal nerve density, the endothelial cells do not recover.

It is important to note that inflammation in eyes with HSK could, at least in part, affect endothelial cell survival, resulting in loss of endothelial cells.<sup>49,50</sup> Despite purposefully excluding patients who had any history or signs of keratouveitis, endotheliitis, and intraocular surgery, we cannot rule out the possibility of direct viral damage to the endothelial cell layer. Moreover, inflammation that occurs during recurrent episodes of HSK could also be responsible for the low ECD in the affected eyes, but not in contralateral unaffected eyes. Although the contralateral clinically unaffected eye had no history of keratitis, it could potentially have subclinical involvement by the HSV, with the frequency of bilateral ocular infection varying between 3% and 11.9%.<sup>51,52</sup> Nevertheless, this scenario is less likely, as contralateral inflammation in the unaffected eye was not observed in our patients at any time point, while contralateral loss of nerves is seen as shown in our study. However, acute and chronic intraocular inflammations are known to injure endothelial cells, and a potential subclinical inflammation in the contralateral unaffected eye could be one reason for a concomitant loss of nerves and endothelial cells.<sup>53</sup>



Our study has several limitations. First, we only evaluated the central area of the cornea by IVCN and corneal sensation, regardless of the location of the corneal involvement. While we did not find significant difference in ECD in the central area of the cornea between the central and peripheral scar groups, the nerve density showed significant differences. The residual stromal scarring and fibrotic tissue present in the same location of the IVCN scans could potentially result in decrease of corneal nerve density in subjects with central corneal scars. Recently, studies from our group have shown that there is a differential corneal nerve damage and immune response in patients with HSK, depending upon the location of the corneal scarring (Muller RT, et al. *IOVS* 2014;55:ARVO E-Abstract 2846). Thus, one cannot necessarily extrapolate our findings to the peripheral cornea. In addition, topographic reproducibility and the difficulty of ensuring that exactly the same locations are tested with both techniques are currently not optimal. Further, the cross-sectional design of the study did not allow us to determine if the endothelial cell loss was progressive or not. Although our study showed decreased ECD in the contralateral clinically unaffected eyes, we are not proposing that corneal nerve density is the only predictor for ECD loss. Additional studies, with larger sample size and with longitudinal designs, are required to study the specific interaction and potential direct link between corneal nerves and endothelial cells.

In conclusion, our IVCN findings demonstrated alterations in corneal ECD in both the affected and clinically unaffected contralateral eyes of patients with unilateral corneal scarring due to HSK. The significant positive correlation between the endothelial cell density and the subbasal nerve density may suggest a potential connection between neurogenic homeostasis and corneal endothelial cell health. Additional studies are required to elucidate the specific interaction between corneal nerves and the endothelial cell layer, especially in patients with unilateral corneal disease.

### Acknowledgments

Presented in part at the Association of Research in Vision and Ophthalmology, Orlando, Florida, United States, May 2014.

Supported by National Institutes of Health K08-EY020575 (PH), New England Corneal Transplant Research Fund (PH), Falk Medical Research Foundation (PH), a Career Development Award from Research to Prevent Blindness (PH), Johnstone Research Fund (DP-L), and Stevens Research Fund (DP-L). The funding organizations had no role in the design or conduct of this research.

Disclosure: **R.T. Müller**, None; **R. Pourmirzaie**, None; **D. Pavan-Langston**, None; **B.M. Cavalcanti**, None; **S. Aggarwal**, None; **C. Colón**, None; **A. Jamali**, None; **A. Cruzat**, None; **P. Hamrah**, P

### References

- Liesegang TJ. Herpes simplex virus epidemiology and ocular importance. *Cornea*. 2001;20:1-13.
- Liesegang TJ. Epidemiology of ocular herpes simplex: natural history in Rochester, Minn, 1950 through 1982. *Arch Ophthalmol*. 1989;107:1160-1165.
- Müller LJ, Marfurt CF, Kruse F, Tervo TMT. Corneal nerves: structure, contents and function. *Exp Eye Res*. 2003;76:521-542.
- Belmonte C, Acosta MC, Gallar J. Neural basis of sensation in intact and injured corneas. *Exp Eye Res*. 2004;78:513-525.
- Oliveira-Soto L, Efron N. Morphology of corneal nerves using confocal microscopy. *Cornea*. 2001;20:374-384.
- Guthoff RE, Wiens H, Hahnel C, Wree A. Epithelial innervation of human cornea: a three-dimensional study using

- confocal laser scanning fluorescence microscopy. *Cornea*. 2005;24:608-613.
- Cruzat A, Witkin D, Baniyadi N, et al. Inflammation and the nervous system: the connection in the cornea in patients with infectious keratitis. *Invest Ophthalmol Vis Sci*. 2011;52:5136-5143.
- Cruzat A, Pavan-Langston D, Hamrah P. In vivo confocal microscopy of corneal nerves: analysis and clinical correlation. *Semin Ophthalmol*. 2010;25:171-177.
- Patel DV, McGhee CNJ. In vivo confocal microscopy of human corneal nerves in health, in ocular and systemic disease, and following corneal surgery: a review. *Br J Ophthalmol*. 2009;93:853-860.
- Sheng H, Bullimore MA. Factors affecting corneal endothelial morphology. *Cornea*. 2007;26:520-525.
- Bonini S, Rama P, Olzi D, Lambiase A. Neurotrophic keratitis. *Eye (Lond)*. 2003;17:989-995.
- Nishida T, Yanai R. Advances in treatment for neurotrophic keratopathy. *Curr Opin Ophthalmol*. 2009;20:276-281.
- Bucher F, Adler W, Lehmann HC, et al. Corneal nerve alterations in different stages of Fuchs' endothelial corneal dystrophy: an in vivo confocal microscopy study. *Graefes Arch Clin Exp Ophthalmol*. 2014;252:1119-1126.
- Schrems-Hoesl LM, Schrems WA, Cruzat A, et al. Cellular and subbasal nerve alterations in early stage Fuchs' endothelial corneal dystrophy: an in vivo confocal microscopy study. *Eye (Lond)*. 2013;27:42-49.
- Zhu AY, Eberhart CG, Jun AS. Fuchs endothelial corneal dystrophy: a neurodegenerative disorder? *JAMA Ophthalmol*. 2014;132:377-378.
- Koh S-WM, Cheng J, Dodson RM, Ku C-YT, Abbondandolo CJ. VIP down-regulates the inflammatory potential and promotes survival of dying (neural crest-derived) corneal endothelial cells ex vivo: necrosis to apoptosis switch and up-regulation of Bcl-2 and N-cadherin. *J Neurochem*. 2009;109:792-806.
- Koh S-WM. Corneal endothelial autocrine trophic factor VIP in a mechanism-based strategy to enhance human donor cornea preservation for transplantation. *Exp Eye Res*. 2012;95:48-53.
- Hamrah P, Cruzat A, Dastjerdi MH, et al. Corneal sensation and subbasal nerve alterations in patients with herpes simplex keratitis: an in vivo confocal microscopy study. *Ophthalmology*. 2010;117:1930-1936.
- Meijering E, Jacob M, Sarria J-CF, Steiner P, Hirling H, Unser M. Design and validation of a tool for neurite tracing and analysis in fluorescence microscopy images. *Cytometry A*. 2004;58:167-176.
- Walker HK, Hall WD, Hurst JW, Walker HK. *Cranial Nerve V: the Trigeminal Nerve*. 3rd ed. Boston: Butterworths; 1990.
- Hamrah P, Cruzat A, Dastjerdi MH, et al. Unilateral herpes zoster ophthalmicus results in bilateral corneal nerve alteration: an in vivo confocal microscopy study. *Ophthalmology*. 2013;120:40-47.
- Garcia-Hirschfeld J, Lopez-Briones LG, Belmonte C. Neurotrophic influences on corneal epithelial cells. *Exp Eye Res*. 1994;59:597-605.
- Lambiase A, Manni L, Bonini S, Rama P, Micera A, Aloe L. Nerve growth factor promotes corneal healing: structural, biochemical, and molecular analyses of rat and human corneas. *Invest Ophthalmol Vis Sci*. 2000;41:1063-1069.
- You L, Kruse FE, Völcker HE. Neurotrophic factors in the human cornea. *Invest Ophthalmol Vis Sci*. 2000;41:692-702.
- Koh S-WM. Ciliary neurotrophic factor released by corneal endothelium surviving oxidative stress ex vivo. *Invest Ophthalmol Vis Sci*. 2002;43:2887-2896.
- Koh SW, Waschek JA. Corneal endothelial cell survival in organ cultures under acute oxidative stress: effect of VIP. *Invest Ophthalmol Vis Sci*. 2000;41:4085-4092.

27. Koh S-WM, Gloria D, Molloy J. Corneal endothelial autocrine VIP enhances its integrity in stored human donor corneal scleral explant. *Invest Ophthalmol Vis Sci.* 2011;52:5632-5640.
28. Alomar TS, Al-Aqaba M, Gray T, Lowe J, Dua HS. Histological and confocal microscopy changes in chronic corneal edema: implications for endothelial transplantation. *Invest Ophthalmol Vis Sci.* 2011;52:8193-8207.
29. Al-Aqaba M, Alomar T, Lowe J, Dua HS. Corneal nerve aberrations in bullous keratopathy. *Am J Ophthalmol.* 2011;151:840-849.e1.
30. Hatou S, Yoshida S, Higa K, et al. Functional corneal endothelium derived from corneal stroma stem cells of neural crest origin by retinoic acid and Wnt/ $\beta$ -catenin signaling. *Stem Cells Dev.* 2013;22:828-839.
31. Amano S, Yamagami S, Mimura T, Uchida S, Yokoo S. Corneal stromal and endothelial cell precursors. *Cornea.* 2006;25(10 suppl 1):S73-S77.
32. Lambiase A, Sacchetti M, Mastropasqua A, Bonini S. Corneal changes in neurosurgically induced neurotrophic keratitis. *JAMA Ophthalmol.* 2013;131:1547-1553.
33. Jacquin MF, Chiaia NL, Rhoades RW. Trigeminal projections to contralateral dorsal horn: central extent, peripheral origins, and plasticity. *Somatosens Mot Res.* 1990;7:153-183.
34. Pfaller K, Arvidsson J. Central distribution of trigeminal and upper cervical primary afferents in the rat studied by anterograde transport of horseradish peroxidase conjugated to wheat germ agglutinin. *J Comp Neurol.* 1988;268:91-108.
35. Hillenaar T, Weenen C, Wubbels RJ, Remeijer L. Endothelial involvement in herpes simplex virus keratitis: an in vivo confocal microscopy study. *Ophthalmology.* 2009;116:2077-2086.e1-2.
36. Hoffer KJ, Kraff MC. Normal endothelial cell count range. *Ophthalmology.* 1980;87:861-866.
37. Matsuda M, Yee RW, Edelhauser HF. Comparison of the corneal endothelium in an American and a Japanese population. *Arch Ophthalmol.* 1985;103:68-70.
38. Sanchis-Gimeno JA, Lleó-Pérez A, Alonso L, Rahhal MS, Martínez Soriano F. Corneal endothelial cell density decreases with age in emmetropic eyes. *Histol Histopathol.* 2005;20:423-427.
39. Hollingsworth J, Perez-Gomez I, Mutalib HA, Efron N. A population study of the normal cornea using an in vivo, slit-scanning confocal microscope. *Optom Vis Sci.* 2001;78:706-711.
40. Patel HY, Patel DV, McGhee CNJ. Identifying relationships between tomography-derived corneal thickness, curvature, and diameter and in vivo confocal microscopic assessment of the endothelium in healthy corneas of young adults. *Eye (Lond).* 2009;23:270-278.
41. Vannas A, Ahonen R, Mäkitie J. Corneal endothelium in herpetic keratouveitis. *Arch Ophthalmol.* 1983;101:913-915.
42. Shaheen BS, Bakir M, Jain S. Corneal nerves in health and disease. *Surv Ophthalmol.* 2014;59:263-285.
43. Erie JC, McLaren JW, Hodge DO, Bourne WM. Recovery of corneal subbasal nerve density after PRK and LASIK. *Am J Ophthalmol.* 2005;140:1059-1064.
44. Darwish T, Brahma A, O'Donnell C, Efron N. Subbasal nerve fiber regeneration after LASIK and LASEK assessed by noncontact esthesiometry and in vivo confocal microscopy: prospective study. *J Cataract Refract Surg.* 2007;33:1515-1521.
45. Al-Aqaba MA, Otri AM, Fares U, Miri A, Dua HS. Organization of the regenerated nerves in human corneal grafts. *Am J Ophthalmol.* 2012;153:29-37.e4.
46. Chucair-Elliott AJ, Zheng M, Carr DJJ. Degeneration and regeneration of corneal nerves in response to HSV-1 infection. *Invest Ophthalmol Vis Sci.* 2015;56:1097-1107.
47. Mimura T, Yamagami S, Amano S. Corneal endothelial regeneration and tissue engineering. *Prog Retin Eye Res.* 2013;35:1-17.
48. Joyce NC. Proliferative capacity of the corneal endothelium. *Prog Retin Eye Res.* 2003;22:359-389.
49. Hamrah P, Sahin A, Dastjerdi MH, et al. Cellular changes of the corneal epithelium and stroma in herpes simplex keratitis: an in vivo confocal microscopy study. *Ophthalmology.* 2012;119:1791-1797.
50. Mocan MC, Irkec M, Mikropoulos DG, Bozkurt B, Orhan M, Konstas AGP. In vivo confocal microscopic evaluation of the inflammatory response in non-epithelial herpes simplex keratitis. *Curr Eye Res.* 2012;37:1099-1106.
51. Liesegang TJ. Epidemiology and natural history of ocular herpes simplex virus infection in Rochester, Minnesota, 1950-1982. *Trans Am Ophthalmol Soc.* 1988;86:688-724.
52. Miserocchi E, Fogliato G, Bianchi I, Bandello F, Modorati G. Clinical features of ocular herpetic infection in an Italian referral center. *Cornea.* 2014;33:565-570.
53. Rowland FN, Donovan MJ, Lindsay M, Weiss WI, O'Rourke J, Kreutzer DL. Demonstration of inflammatory mediator-induced inflammation and endothelial cell damage in the anterior segment of the eye. *Am J Pathol.* 1983;110:1-12.