

Nodular Foot Myxedema Masquerading as Lymphedema

Javier A. Couto, BS*

Birgitta A. R. Schmidt, MD†
Arin K. Greene, MD, MMSc*‡

Summary: Lymphedema results from abnormal development or injury to the lymphatic system. One-fourth of patients with lower extremity enlargement are erroneously labeled with “lymphedema.” We describe a patient with hypothyroidism who developed soft-tissue overgrowth of her foot. She was referred to our Lymphedema Program for management of “lymphedema” and overgrown toes. The patient’s lymphoscintigram showed normal lymphatic function in her extremities, and she was diagnosed with myxedema by histopathology. Nodular localized myxedema should be included in the differential diagnosis of lymphedema. (*Plast Reconstr Surg Glob Open* 2015;3:e457; doi: 10.1097/GOX.0000000000000427; Published online 16 July 2015.)

Lymphedema is the chronic, progressive swelling because of inadequate lymphatic function. The accumulation of protein-rich fluid in the interstitial space causes subcutaneous adipose deposition. Secondary lymphedema occurs after injury to lymphatic vessels or lymph nodes. Primary (idiopathic) lymphedema is rare, affecting 1:100,000 persons.¹ We report a patient referred to our Lymphedema Program because of “swollen” toes who instead was diagnosed with foot myxedema.

CASE REPORT

A 59-year-old woman developed soft-tissue overgrowth of the right foot during the previous year. She complained of pain and difficulty fitting shoes. Her only risk factor for lymphedema was a history of morbid obesity. She underwent a bariatric weight-loss procedure 13 years previously and decreased

her body mass index from 63 to 30 kg/m². She denied a family history of lymphedema, travel to areas endemic for filariasis, or inguinal trauma (ie, operations, lymphadenectomy, radiation). The patient was healthy except for hypothyroidism, which was treated with levothyroxine 0.2 mg/d.

Physical examination showed dorsal overgrowth of the large and adjacent toe of the right foot (Fig. 1). Although soft-tissue overgrowth can occur with lymphedema, the feet did not exhibit signs commonly present with the disease: pitting edema and a Stemmer sign (ie, the skin of the dorsum of the foot cannot be pinched between 2 fingers). Because the patient had a risk factor for lymphedema (previous body mass index > 60) and overgrown soft tissue of the toes, a lymphoscintigram was performed to determine whether or not she had lymphedema. Lymphoscintigraphy showed normal lymphatic function in both lower extremities (ie, normal transit time, absence of dermal backflow).^{2,3} To improve her symptoms, the soft-tissue overgrowth was resected. Histopathological examination illustrated cutaneous myxedema.

DISCUSSION

Patients with an overgrown extremity are often labeled with “lymphedema” regardless of the etiology of their condition. One-fourth of individuals referred to a Lymphedema Program have

Disclosure: The authors have no financial interest to declare in relation to the content of this article. The Article Processing Charge was paid for by the authors.

From the *Department of Plastic and Oral Surgery, †Department of Pathology, and ‡Vascular Anomalies Center, Boston Children’s Hospital, Harvard Medical School, Boston, Mass.

Received for publication March 3, 2015; accepted May 28, 2015.

Copyright © 2015 The Authors. Published by Wolters Kluwer Health, Inc. on behalf of The American Society of Plastic Surgeons. All rights reserved. This is an open-access article distributed under the terms of the Creative Commons Attribution-Non Commercial-No Derivatives License 4.0 (CCBY-NC-ND), where it is permissible to download and share the work provided it is properly cited. The work cannot be changed in any way or used commercially.

DOI: 10.1097/GOX.0000000000000427

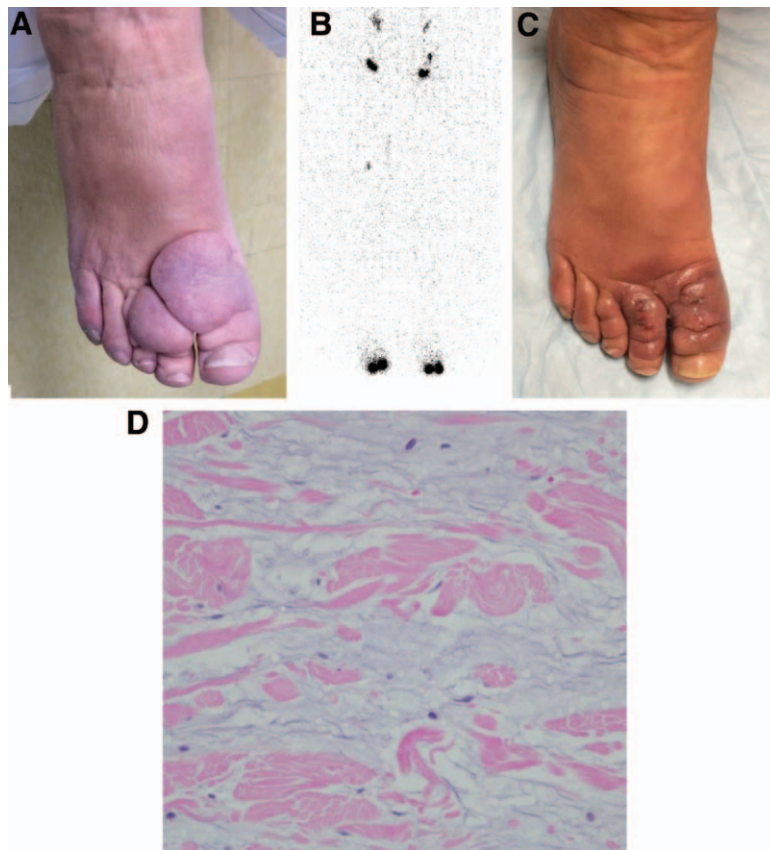


Fig. 1. A, A 59-year-old woman with localized tissue overgrowth on the dorsum of the first 2 toes of the right lower extremity. B, Lymphoscintigram image 45 minutes post injection showing normal uptake of radiolabeled tracer in the inguinal lymph nodes and no dermal backflow bilaterally. C, Postoperative appearance of foot. D, Hematoxylin–eosin image showing separation of the collagen fibers by increased mucin deposition; there is no increase in dermal fibroblasts ($\times 40$).

another disease.^{4,5} The differential diagnosis of lymphedema includes vascular anomalies, venous insufficiency, lipedema, obesity, systemic conditions (eg, cardiac, renal, hepatic dysfunctions), hemihypertrophy, orthopedic pathology (eg, ligament sprain, tenosynovitis), and rheumatologic conditions.^{4,5} In this report, we describe a patient who was referred with “lymphedema” because of overgrown toes who was diagnosed instead with localized myxedema.

Localized myxedema is also known as pretibial myxedema or thyroid dermatopathy.⁶ It affects up to 4% of patients with thyroid disease; 91% have hyperthyroidism, 6% are hypothyroid, and 3% are euthyroid.⁷ Eighty percent of patients are female, and the mean age at diagnosis is 53 years.⁷ The pretibial area is affected in 93% of patients; the feet are the second most common site (4%).⁷ There are 4 forms of the condition: nonpitting edema (43%), plaque (27%), nodular (19%), and elephantiasic (3%).⁷ Histopathological examina-

tion shows separation of collagen by mucin in the reticular dermis and large amounts of glycosaminoglycans.⁷

The pathophysiology of localized myxedema is unclear. It is hypothesized that thyroid-stimulating hormone receptor antibody might stimulate fibroblasts to produce glycosaminoglycans.⁷ The pretibial area may be most susceptible because of dependent positioning in an area subjected to stress forces.⁶ Localized myxedema can improve over time; one study showed 50% remission in patients with 17 years of follow-up.⁷ The most commonly used treatment for symptomatic lesions is topical corticosteroid; other interventions have included compression dressings, intralesional octreotide or corticosteroid, systemic corticosteroid, immunoglobulin, plasmapheresis, and resection.⁷

The patient presented in this report had a less common presentation for localized myxedema because she was hypothyroid, the foot was affected, and she had the nodular form of the disease. Although pa-

tients with lymphedema can have hyperkeratosis and lymphatic vesicles, massive soft-tissue overgrowth isolated to 2 toes over a period of 12 months is not consistent with the disease. Localized myxedema should be included in the differential diagnosis of lymphedema.

Arin K. Greene, MD, MMSc

Department of Plastic Surgery and Oral Surgery
Boston Children's Hospital
300 Longwood Ave., Boston
MA 02115

E-mail: arin.greene@childrens.harvard.edu

REFERENCES

1. Smeltzer DM, Stickler GB, Schirger A. Primary lymphedema in children and adolescents: a follow-up study and review. *Pediatrics* 1985;76:206–218.
2. Gloviczki P, Calcagno D, Schirger A, et al. Noninvasive evaluation of the swollen extremity: experiences with 190 lymphoscintigraphic examinations. *J Vasc Surg*. 1989; 9:683–689.
3. Szuba A, Rockson SG. Lymphedema: classification, diagnosis and therapy. *Vasc Med*. 1998;3:145–156.
4. Schook CC, Fishman SJ, Mulliken JB, et al. Primary lymphedema: clinical features and management in 138 pediatric patients. *Plast Reconstr Surg*. 2011; 127:2419–2431.
5. Maclellan RA, Couto RA, Sullivan JE, et al. Management of primary and secondary lymphedema: analysis of 225 referrals to a center. *Ann Plast Surg*. 2014 April 8. [Epub ahead of print].
6. Fatourech V. Pretibial myxedema: pathophysiology and treatment options. *Am J Clin Dermatol*. 2005;6:295–309.
7. Schwartz KM, Fatourech V, Ahmed DD, et al. Dermopathy of Graves' disease (pretibial myxedema): long-term outcome. *J Clin Endocrinol Metab*. 2002;87:438–446.