

# Chronic neutrophilic leukemia with overexpression of EVI-1, and concurrent *CSF3R* and *SETBP1* mutations: A case report

OTGONBAT ALTANGEREL<sup>1,2</sup>, SHANNAN CAO<sup>3</sup>, JUANXIA MENG<sup>1</sup>, PENG LIU<sup>3</sup>,  
GONG HAIYAN<sup>3</sup>, YUANFU XU<sup>3</sup> and MINGFENG ZHAO<sup>1</sup>

<sup>1</sup>Department of Hematology, Tianjin First Central Hospital, First Central Clinical College of Tianjin Medical University, Tianjin 300192, P.R. China; <sup>2</sup>Department of Internal Medicine, Division of Hematology, Mongolian National University of Medical Sciences, Ulaanbaatar 14210, Mongolia; <sup>3</sup>State Key Laboratory of Experimental Hematology, Institute of Hematology and Blood Diseases Hospital, Chinese Academy of Medical Sciences and Peking Union Medical College, Tianjin 300020, P.R. China

Received September 17, 2014; Accepted June 3, 2015

DOI: 10.3892/ol.2015.3485

**Abstract.** Chronic neutrophilic leukemia (CNL) is a rare type of myeloproliferative neoplasm, characterized by sustained neutrophilia, splenomegaly, bone marrow granulocytic hyperplasia (without evidence of dysplasia) and an absence of the Philadelphia chromosome. Thus far, ~150 cases of CNL have been described in the literature; however, none have demonstrated overexpression of the ecotropic viral integration site-1 (EVI-1, also known as *MECOM*) gene. The present study describes a case that fulfilled the World Health Organization diagnostic criteria for CNL, and was associated with overexpression of EVI-1, as well as novel concurrent mutations of colony stimulating factor 3 receptor (*CSF3R*) and SET binding protein-1 (*SETBP1*). In addition, the current study briefly reviewed the relevant literature regarding novel genetic findings associated with the diagnosis and treatment of CNL. To the best of our knowledge, this is the first case report of CNL with associated EVI-1 overexpression, and concurrent *CSF3R* and *SETBP1* mutations.

## Introduction

Chronic neutrophilic leukemia (CNL) is a rare myeloproliferative neoplasm (MPN) that is primarily characterized by leukocytosis, but is often lacking in distinct clinical, laboratory and molecular features (1). The majority of CNL cases are fatal, most often due to severe cerebral hemorrhage, with a median survival time of

<2 years (2). Management is typically symptomatic, however, allogeneic transplantation in younger patients may represent a curative treatment strategy. The optimal therapeutic regime for CNL remains uncertain (3). Until recently, the molecular pathogenesis of CNL was unknown; therefore, diagnoses were based on morphological analysis, clinical criteria and the exclusion of known genetic entities, such as mutations of the breakpoint cluster region (*BCR*)/*ABL* proto-oncogene 1 (*ABL1*) gene transcript or Janus kinase 2 (*JAK2*).

Colony-stimulating factor 3 (*CSF3R*) encodes the receptor for CSF3, a cytokine that controls the generation, differentiation and function of granulocytes (4,5). Mutations in *CSF3R* are associated with severe congenital neutropenia. Maxson *et al* (6) recently demonstrated that *CSF3R* mutations are associated with CNL and atypical chronic myeloid leukemia (aCML). In addition, the following association between CNL and activating *CSF3R* mutations was established: Oncogenic *CSF3R* mutations may be used as molecular markers of sensitivity to SRC family tyrosine kinase non-receptor 2 and JAK inhibitors. The aforementioned studies may facilitate the development of novel therapeutic strategies for CNL (7). In humans, ecotropic viral integration site-1 (EVI-1, also known as *MECOM*) is located at chromosome 3q26 and, in cases of hematological malignancy, rearrangements at this locus frequently lead to increased EVI-1 expression. In addition, overexpression of EVI-1 occurs with high frequency in leukemia patients who do not possess chromosome 3q26 abnormalities. Therefore, high EVI-1 expression is an independent negative prognostic indicator for certain types of cancer, irrespective of the presence of chromosome 3q26 rearrangements (8). SET binding protein-1 (*SETBP1*) stabilizes the protein SET, an inhibitor of the tumor suppressor protein phosphatase 2A (PP2A). *SETBP1*-mutated cells express higher levels of SETBP1 and thus, exhibit lower PP2A activity with higher proliferative rates compared with their wild-type *SETBP1* counterparts (9). Clinically, patients with *SETBP1* mutations exhibit a significantly higher number of leukocytes and a worse prognosis than patients with wild-type *SETBP1* (9). A previous study demonstrated that 4/12 (33%) patients with CNL were found to carry a *SETBP1* mutation. All patients coexpressed the *CSF3RT*<sup>618I</sup> mutation and exhibited a

---

*Correspondence to:* Professor Mingfeng Zhao, Department of Hematology, Tianjin First Central Hospital, First Central Clinical College of Tianjin Medical University, 24 Fu Kang Road, Tianjin 300192, P.R. China  
E-mail: zmfzmf@hotmail.com

*Key words:* chronic neutrophilic leukemia, colony stimulating factor 3 receptor mutation, SET binding receptor mutation, ecotropic viral integration site-1

trend towards reduced survival (10). Therefore, *SETBP1* mutations may be a prognostic indicator for CNL.

The present study reports a patient with double-mutated CNL exhibiting *CSF3R*<sup>T618I</sup> and *SETBP1*<sup>D868N</sup> with associated overexpression of EVI-1. To the best of our knowledge, this is the first reported case of CNL with an associated mutation in EVI-1.

### Case report

**Presentation.** On September 4, 2012, a 67-year-old man was admitted to the First Central Clinical College of Tianjin Medical University (Tianjin, China) with a number of symptoms, including ecchymosis, fatigue, and edema and pain in the right leg. Skin ecchymosis had been present for 4 months and was not associated with bleeding from any orifice, or with a history of deep bleeding. The patient exhibited edema and pain in the right leg 10 days prior to admission that caused difficulty walking. These symptoms were associated with fatigue, however, there was no evidence to indicate an infection. The patient had no significant history of recent cytotoxic, immunosuppressive or growth factor therapy, or exposure to chemicals. Furthermore, the patient's personal and family medical history were not relevant to the symptoms exhibited. Physical examination revealed mild pallor, a small number of ecchymotic patches on the skin and considerable edema in right leg. However, hypertrophy of the gums, hepatomegaly, splenomegaly or enlargement of the peripheral lymph nodes were not observed.

The ethics committee of the First Central Clinical College of Tianjin Medical University approved the use of patient-derived cells and the protocols of the present study. Written informed consent was obtained from the patient's family.

**Clinical investigation.** Laboratory investigations performed upon initial admission revealed a hemoglobin level of 69 g/dl (normal range, 130-175 g/dl), a red blood cell count of  $2.41 \times 10^{12}/l$  (normal range,  $4.31-5.82 \times 10^{12}/l$ ), a white blood cell count of  $49.41 \times 10^9/l$  (normal range,  $3.50-9.49 \times 10^9/l$ ) and a platelet count of  $94 \times 10^9/l$  (normal range,  $150-350 \times 10^9/l$ ). A peripheral blood film (98.5% neutrophils, 1.30% lymphocytes, 0.01% monocytes, 0.10% eosinophils and 0.09% basophils) indicated leukocytosis with an increased number of segmented and band-stage neutrophils. A small number of myelocytes and an occasional blast were noted, however, basophilia or eosinophilia were not observed.

Serum electrolyte levels and liver function test results were normal, however, lactate dehydrogenase levels were high at 925.1 U/l (normal range, 135.0-255.0 U/l). A serum assay indicated elevated ferritin (688.6 ng/ml; normal range, 15.0-200.0 ng/ml), vitamin B<sub>12</sub> (1,512 pg/ml; normal range, 210-1,100 pg/ml) and uric acid (567  $\mu$ mol/l; normal range, 238-506  $\mu$ mol/l) levels. Furthermore, the patient's peripheral blood neutrophil alkaline phosphatase (NAP) score was 292.8 (normal range, 69.9-103.3). However, laboratory investigations did not detect any monoclonal protein in the serum or urine and coagulation tests were normal. Bone marrow aspiration and biopsy demonstrated a notable hypercellular marrow with marked granulocytic proliferation, predominantly consisting of band-stage and segmented neutrophils, with no dysplastic changes evident. Erythroid and megakaryocytic cell levels were depressed, however, the

morphology was normal. In addition, the myeloid:erythroid ratio was 9.8:1, and there was no increase in the proportion of basophils and eosinophils. A trephine biopsy of the bone marrow demonstrated similar results and there was no increase in the number of reticulin fibres. Systemic examinations using X-rays, computed tomography scans and analysis of the tumor markers, including  $\alpha$ -fetoprotein, acid phosphatase and prostatic-specific antigen, demonstrated no evidence of malignancy. Furthermore, ultrasonography of the abdomen did not reveal any abnormalities and there appeared to be no detectable underlying disease causing the leukemoid reaction. Flow cytometry analysis was consistent with marked myeloid hyperplasia without an increase in the number of blasts or monocytes.

Conventional cytogenetic analysis revealed a normal karyotype [46, XY (16 cells)] and an absence of the Philadelphia (Ph) chromosome. Furthermore, molecular biology investigations demonstrated negativity for the p210 BCR/ABL1 (e13a2, e14a2), p230 BCR/ABL1 (e19, e20) and p190 BCR/ABL1 (e1a2) fusion proteins, an absence of the *JAK2*<sup>V617F</sup> mutation, and no mutations in the platelet derived growth factor receptor  $\alpha/\beta$  polypeptides (*PDGFRA/PDGFRB*). Additional genetic analysis was conducted using bone marrow samples, qualitatively screening 31 leukemia fusion genes by nested polymerase chain reaction (PCR) using the Whole Blood RNA Extraction Kit (BioChain Institute, Inc., Newark, CA, USA). The following genes were included in the screen: MLL (also known as *KMT2A*)/AFX (also known as *FOXO4*), MLL/AF6 (also known as *MLLT4*), MLL/*ELL*, *CBFB/MYH11*, MLL/AF1P (also known as *EPS15*), MLL/AF10 (also known as *MLLT10*), MLL/AF17 (also known as *MLLT6*), dupMLL, E2A (also known as *TCF3/PBX1*), E2A/*HLF*, *STIL/TALI*, TEL (also known as *ETV6*)/AML1 (also known as *RUNX1*), AML1/*ETO*, AML1/EV11, TLS (also known as *FUS*)/*ERG*, MLL/AF1Q (also known as *MLLT11*), MLL/AF4 (also known as *AFF1*), MLL/AF9 (also known as *MLLT3*), MLL/ENL (also known as *MLLT1*), *BCR/ABL1*, TEL/*PDGFRB*, *DEK/CAN* (also known as *NUP214*), *SET/CAN*, *PML/RARA*, PLZF (also known as *ZBTB16*)/*RARA*, *NPM1/ALK*, *NPM1/MLF1*, *NPM1/RARA*, TEL/*ABL1*, HOX11 (also known as *TLX1*) and EVI-1. The results of this qualitative analysis demonstrated that only EVI-1 was expressed in the bone marrow (Table I). During the clinical course, karyotyping and expression analysis of the *BCR-ABL1* transcripts and EVI-1 gene were repeated three times, with similar results.

In consideration of the results of the nested PCR screen, correlation between EVI-1 expression and the pathogenesis of CNL was investigated by analyzing cell apoptosis, migration and cell cycle distribution. First, neutrophils were purified from bone marrow samples by Ficoll-Hypaque gradient centrifugation and erythrocytes were removed using EasySep™ Red Blood Cell Lysis Buffer (STEMCELL Technologies, Inc., Vancouver, BC, Canada). After washing three times, the purified neutrophils were labeled with fluorescein isothiocyanate (FITC)-cluster of differentiation (CD)15 (BD Biosciences, Franklin Lakes, NJ, USA). The labeled cells were analyzed using flow cytometry (LSR II; BD Biosciences) and 93.9% were identified as mature neutrophils.

To investigate apoptosis, the purified neutrophils were cultured in RPMI 1640 medium with 10% fetal bovine serum. Cells were collected at specific time points (0, 6, 12,

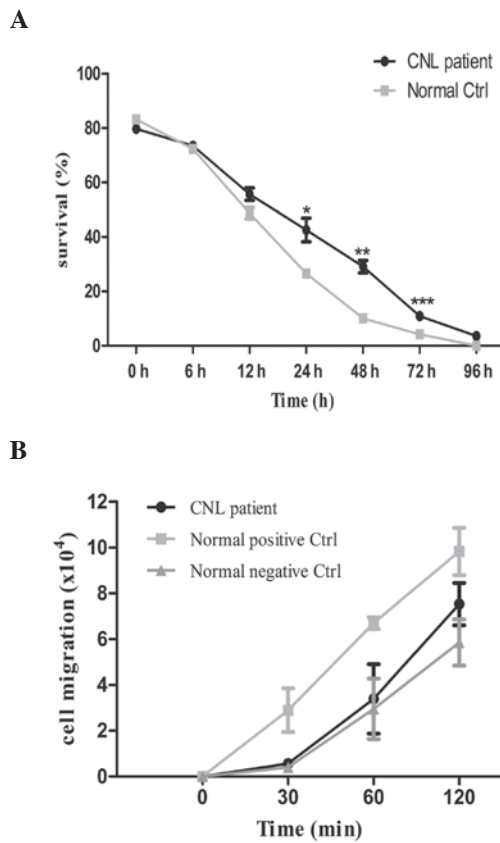


Figure 1. Cell survival curve and cell migration assay. (A) Cell survival data obtained at different time points indicating that the patient's neutrophils survive significantly longer than those of the normal control group. \*P=0.210 vs. control; \*\*P=0.0012 vs. control; and \*\*\*P=0.0010 vs. control. (B) Extent of cell migration, as determined by N-formyl-methionyl-leucyl-phenylalanine (fMLP) treatment. Migration of the patient neutrophils was low compared with the normal positive Ctrl cells (incubated with fMLP), but high compared with the normal negative Ctrl cells (incubated without fMLP). CNL, chronic neutrophilic leukemia; ctrl, control.

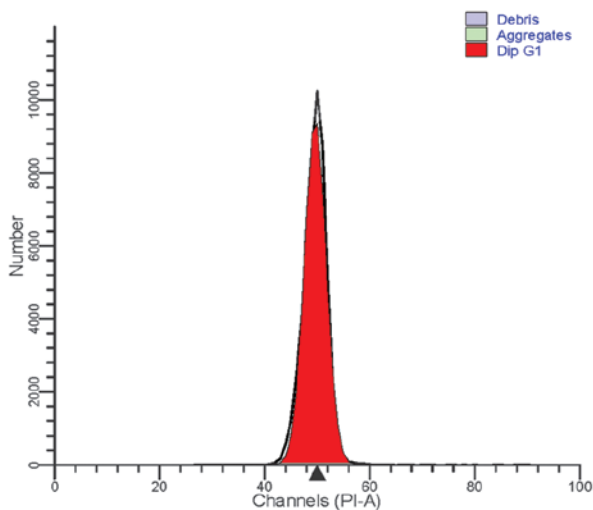


Figure 2. Cell cycle analysis determined by flow cytometry. All cells were terminally differentiated and there was no cell division.

24, 48, 72 and 96 h), and labeled with Annexin V and propidium iodide (BD Biosciences). Apoptosis of the patient's neutrophils was measured using flow cytometry (LSR II; BD

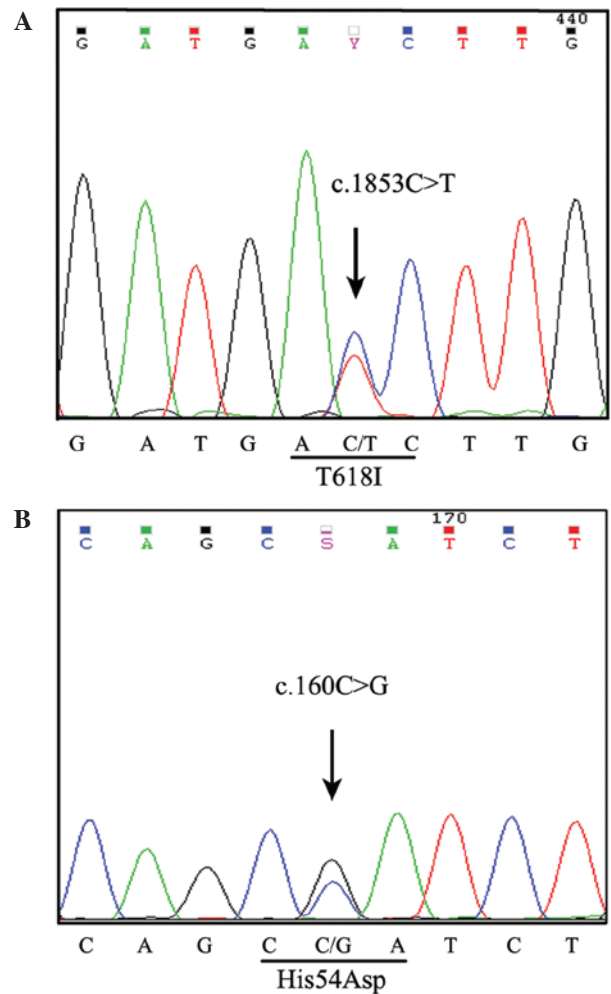


Figure 3. Detection of the T618I and His54Asp point mutations in colony stimulating factor 3 receptor (*CSF3R*). (A) Sequencing of exon 14 of *CSF3R* detected a base-pair mutation (C to T) at nucleotide 1853. (B) Sequencing of exon 4 of *CSF3R* detected a base-pair mutation (C to G) at nucleotide 160.

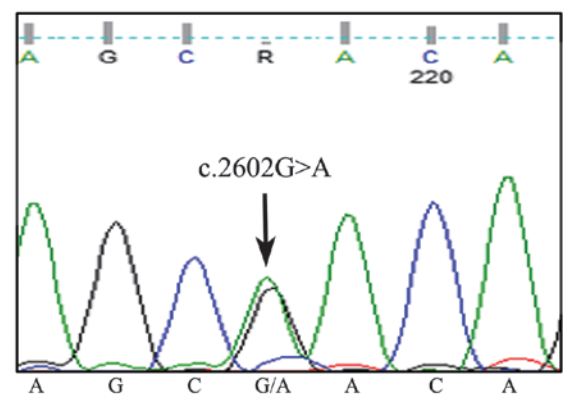


Figure 4. Detection of the p.Asp868Asn point mutation in the SET binding protein 1 gene.

Biosciences) and compared with the apoptosis of neutrophils obtained from healthy donors (control group cells). Flow cytometric analysis revealed that a significantly higher number of patient neutrophils survived to 72 h compared with control neutrophils (Fig. 1A; P=0.0010).

Table I. Qualitative and quantitative EVI-1 screening tests.

Test	Bone marrow sample	EVI-1 expression
Qualitative screening of 36 leukemic fusion genes September 13, 2012	Total	Positive
Quantitative screening of EVI-1 expression September 25, 2012	Total	499.87 <sup>a</sup> (overexpression)
November 5, 2012	CD34 <sup>+</sup> cell fraction	214.82 <sup>a</sup> (overexpression)
November 5, 2012	CD15 <sup>+</sup> cell fraction	34.21 <sup>a</sup> (low expression)
May 15, 2012	Total	151.27 <sup>a</sup> (overexpression)

<sup>a</sup>2<sup>-ΔΔCt</sup> values. When 2<sup>-ΔΔCt</sup> ≤ 8, EVI-1 expression is negative; when 8 ≤ 2<sup>-ΔΔCt</sup> ≤ 32, EVI-1 gene expression is low; when 2<sup>-ΔΔCt</sup> ≥ 32, EVI-1 is overexpressed. EVI-1, ectopic viral integration site-1, also known as *MECOM*; Ct, cycle threshold; CD, cluster of differentiation.

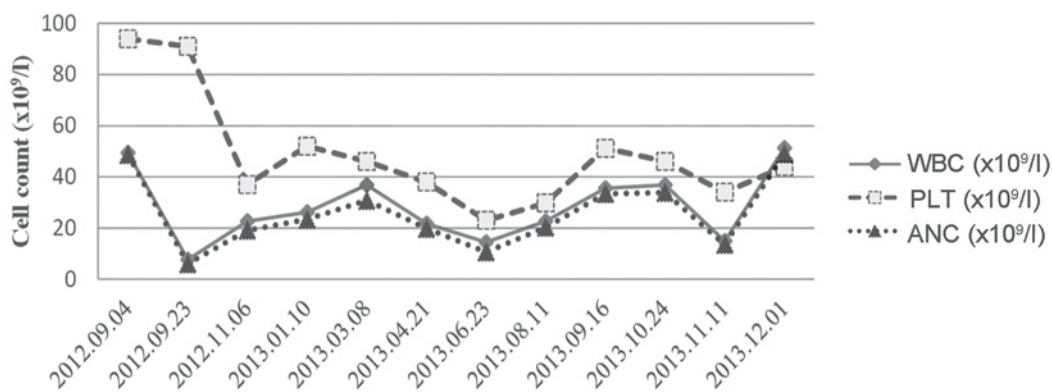


Figure 5. Cell count recorded throughout the disease course. WBC, white blood cells; PLT, platelets; ANC, absolute neutrophil count.

To assay migration, the patient-derived purified neutrophil sample, and the negative and positive control cells were cultured in Transwell® inserts (Corning, Inc., Corning, NY, USA) (1x10<sup>6</sup> cells/well). Subsequently, 1 μM chemotactic peptide N-formyl-methionyl-leucyl-phenylalanine (fMLP; Sigma-Aldrich, St. Louis, MO, USA) was added to the lower compartment. The number of the cells in the lower compartment was counted at each time point (0, 30, 60 and 120 min). The data revealed that fMLP-induced cell migration was lower in the patient-derived neutrophils compared with the positive control cells incubated with fMLP, but higher than negative control neutrophils incubated without fMLP. However, the differences were not statistically significant (Fig. 1B). Cell apoptosis and migration data were analyzed using Graphpad Prism 5 (GraphPad Software, Inc., San Diego, CA, USA).

For cell cycle analysis of the patient-derived neutrophils, a Cycletest™ Plus DNA Reagent kit (BD Biosciences) was used, according to the manufacturer's instructions. Flow cytometric analysis of the cell cycle revealed a normal distribution. All cells were terminally differentiated and no cell division was observed (Fig. 2).

Following detection of EVI-1 overexpression by a nested PCR screen of 31 leukemia fusion genes, the expression of EVI-1 was quantitatively analyzed in September 2012. This was achieved by sorting the bone marrow samples into CD34<sup>+</sup> and CD15<sup>+</sup> cell fractions (BD FACSAria™ III;

BD Biosciences), and performing reverse transcription quantitative-PCR (RT-qPCR) to detect EVI-1 expression at three time points during the clinical course. Fluorescent Taqman® probes (Applied Biosystems Life Technologies, Foster City, CA, USA) were used to detect the expression of EVI-1 and an endogenous reference gene (*ABL1*) using the following oligonucleotide primers: Forward, 5'-GTACTTGAGCCAGCTTCCAACA-3', and reverse, 5'-CTTCTTGACTAAAGCCCTTGA-3' for EVI-1; and forward, 5'-TGGAGATAACACTCTAAGCATAACTAAAGGT-3', and reverse, 5'-GATGTAGTTGCTTGGGACCCA-3' for *ABL1*. Cycle threshold (Ct) values (LightCycler; Roche Diagnostics, Basel, Switzerland) of bone marrow samples obtained from healthy volunteers (control) were then used to calculate the relative quantification of EVI-1 expression, as follows:  $\Delta Ct_{\text{control}} = Ct_{\text{control EVI1}} - Ct_{\text{control ABL1}}$  and  $\Delta Ct_{\text{patient}} = Ct_{\text{patient EVI1}} - Ct_{\text{patient ABL1}}$ . Subsequently,  $\Delta\Delta Ct = \Delta Ct_{\text{patient}} - \Delta Ct_{\text{control}}$  was calculated and used to determine the fold-change in EVI-1 gene expression, defined as 2<sup>-ΔΔCt</sup>.

The 2<sup>-ΔΔCt</sup> value was <8 in the healthy control samples. Based on this data, the present study used the following criteria for categorizing gene expression: 2<sup>-ΔΔCt</sup> ≤ 8, low EVI-1 expression; 8 ≤ 2<sup>-ΔΔCt</sup> ≤ 32, middle EVI-1 expression; and 2<sup>-ΔΔCt</sup> ≥ 32, high EVI-1 expression. Notably, the RT-qPCR data yielded similar results across samples, particularly for the detection of EVI-1 overexpression in total bone marrow samples and



Table II. WHO diagnostic criteria for CNL and aCML with corresponding patient clinical data.

Patient data	WHO diagnostic criteria		Fulfills criterion	
	CNL	aCML	CNL	aCML
25x10 <sup>9</sup> /l WBC, including >80% neutrophils, and no dysgranulopoiesis	≥25x10 <sup>9</sup> /l WBCs, including >80% segmented neutrophils <sup>a</sup>	≥13x10 <sup>9</sup> /l WBCs with dysgranulopoiesis	+	-
Hypercellular marrow with mature cells	Hypercellular marrow <sup>b</sup>	Hypercellular marrow <sup>c</sup>	+	+
No Ph or <i>BCR/ABL1</i> fusion gene	No Ph or <i>BCR/ABL1</i> fusion gene	No Ph or <i>BCR/ABL1</i> fusion gene	+	+
No rearrangement of <i>PDGFRA/PDGFRB</i>	No rearrangement of <i>PDGFRA/PDGFRB</i> or <i>FGFR1</i>	No rearrangement of <i>PDGFRA/PDGFRB</i>	+	+
Blood neutrophil precursors comprising <10% of WBCs	Immature granulocytes comprising <10% of WBCs	Blood neutrophil precursors comprising ≥10% of WBCs	+	-
No basophilia in the blood or bone marrow	No basophilia in the blood or bone marrow	Minimal basophilia (<2%) in the blood and bone marrow	+	+
1% monocytes	No monocytosis	Minimal monocytosis (<10%)	+	+
<20% blasts in the blood and marrow	<1% myeloblasts in the blood and bone marrow	<20% blasts in the blood and marrow	+	+
Mild hepatosplenomegaly	Hepatosplenomegaly	No hepatosplenomegaly	+	-
No physiologic cause for neutrophilia	No physiological cause for neutrophilia	No physiological cause for neutrophilia	+	+
No evidence of PV, ET or PM	No evidence of PV, ET or PM	No evidence of PV, ET or PM	+	+
No evidence of MDS or MDS/MPD	No evidence of MDS or MDS/MPD	No evidence of MDS or MDS/MPD	+	+

<sup>a</sup>>80% segmented and band-forms neutrophil, <10% immature granulocytes and <1% myeloblasts. <sup>b</sup>Granulocytic proliferation and granulocytic dysplasia with or without dysplasia in the erythroid and megakaryocytic lineages. <sup>c</sup>Increased number of proportion of neutrophilic granulocytes with myeloblasts constituting <5% of the nucleated marrow cells, a normal neutrophil maturation pattern, and normal or left-shifted megakaryocytes. WHO, World Health Organization; CNL, chronic neutrophilic leukemia; aCML, atypical chronic myelogenous leukemia; WBC, white blood cell; Ph, Philadelphia chromosome; *BCR/ABL1*, breakpoint cluster region/ABL proto-oncogene 1; *PDGRF*, platelet-derived growth factor receptor; *FGFR*, fibroblast growth factor receptor; PV, polycythemia vera; ET, essential thrombocythemia; PM, primary myelofibrosis; MDS, myelodysplastic syndrome; MPD, myeloproliferative disorder.

CD34<sup>+</sup> cell fractions, however, the CD15<sup>+</sup> cell fraction demonstrated overexpression of EVI-1 (Table I).

A *CSF3R* mutation spanning an entire exon and intron was detected in the CD34<sup>+</sup> and CD15<sup>+</sup> cell fractions using a PCR-based DNA pyrosequencing method (6,7). The p.Thr618Ile membrane proximal mutation was detected on exon 14 of *CSF3R* (Fig. 3A). Additionally, a novel mutation site was revealed on exon 4 of the p.His54Asp heterozygous *CSF3R* mutation (Fig. 3B). Somatic *SETBP1* mutational alteration analysis was performed by PCR amplification followed by Sanger sequencing for codons located at base pairs 706-917 of exon 3. The results of this analysis indicated that a somatic heterozygous *SETBP1* mutation was encoded at the location p.Asp868Asn, c.2602C>A (Fig. 4).

**Differential diagnosis.** The assessment of a patient with atypical myeloproliferative features and the determination of a correct diagnosis of CNL may pose a challenge for clinicians. In the present study, the World Health Organization (WHO) diagnostic criteria (11) was used to determine the following differential diagnoses upon admission: CML, aCML, CNL

and reactive leukocytosis. Using the additional data obtained in the aforementioned laboratory investigations, the patient's initial differential diagnosis was further restricted to aCML versus CNL. Utilizing the rigorous diagnostic criteria defined by the WHO, a direct comparison of the clinical and laboratory features of the case was performed. The patient met all the criteria for a diagnosis of CNL, while a diagnosis of aCML was less likely considering the lack of evidence of overt neutrophilic dysgranulopoiesis, a virtual absence of circulating immature myeloid cells and the demonstration of only mild splenomegaly upon physical examination (Table II). Thus, a diagnosis of CNL was determined and the patient's clinical course was followed up for 15 months.

**Treatment.** On September 14, 2012, the patient commenced with a treatment strategy of hydroxyurea (1,500 mg/day) and subcutaneous interferon- $\alpha$  (IFN- $\alpha$ ; 300 IU/day, three times a week). The patient's leukocyte count decreased to 7.67x10<sup>9</sup>/l following 3 weeks of treatment (76.8% neutrophils, 12.3% lymphocytes, 9.6% monocytes, 1.0% eosinophils and 0.3% basophils). As a result of this, the doses were reduced to

500 mg/day hydroxyurea and 300 IU/day IFN- $\alpha$ , two times a week. The patient's treatment continued for the next 15 months, with monitoring and control of the leukocyte count within a range of 15-30 $\times 10^9/l$ . In September 2013, ~1 year subsequent to the patient's initial admission, the patient exhibited bleeding gums, splenomegaly and lymphadenopathy. The splenomegaly was palpable 4 cm below the costal margin, and lymph nodes of the cervical and inguinal folds were enlarged to 1.5 cm. The platelet count persistently decreased from 90 $\times 10^9/l$  to 20 $\times 10^9/l$  during the clinical course. Adjustment of the treatment dose was difficult due to this progressive thrombocytopenia (Fig. 5). In December 2013, the leukocyte count fluctuated and increased to 52 $\times 10^9/l$ . Later in December 2013, the patient succumbed to a serious fungal infection of the lung.

## Discussion

Following the initial description of CNL in 1920 (12), >150 cases have been reported in the literature (13). However, EVI-1 overexpression has not been observed in any of these cases. CNL is a rare disorder and can be distinguished from CML by an absence of the Ph chromosome or the *BCR/ABL1* fusion gene. In addition, rearrangements in genes encoding *PDGFRA/PDGFRB* and fibroblast growth factor receptor 1 are not present. CNL is an MPN characterized by persistent neutrophilia and splenomegaly, and typically affects elderly patients of both genders. The majority of patients with CNL have a poor prognosis, with a mean survival time of 21 months (2,3). However, Reilly performed a survival analysis study of 33 patients considered to have CNL and identified an overall median survival time of 30 months, with a 5-year survival rate of 28% (14). Clinical and laboratory findings, including negative molecular testing for the *JAK2*<sup>V617F</sup> mutation, facilitated in the exclusion of other common MPNs, such as polycythemia vera (PV), essential thrombocythemia (ET) and primary myelofibrosis. However, this mutation has been detected in 13 cases of CNL to date, indicating that the *JAK2*<sup>V617F</sup> mutation is a rare event in patients with atypical MPN (15). Treatment approaches for individuals with this disorder are heterogeneous.

The case presented in the current study was characterized by marked and sustained neutrophilia, an increased NAP score, absence of the Ph chromosome, a lack of *BCR/ABL1* fusion transcripts, as detected by RT-qPCR, and no underlying disorders causing leukemoid reaction. Carcinoma and infectious disease were eliminated during differential diagnosis, no monoclonal gammopathy was identified, as in multiple myeloma, and no complications, such as PV, ET or myelodysplastic syndrome (MDS), were observed. In the present case, hepatosplenomegaly was not detected in the patient upon initial admission, however, other laboratory findings satisfied the WHO diagnostic criteria for CNL. Due to progression of the disease, the patient exhibited bleeding gums, splenomegaly and lymphadenopathy 1 year later. The following mean peripheral blood cell counts were obtained during the patient's clinical course: A leukocyte count of 28.36 $\times 10^9/l$  (range, 7.67-51.28 $\times 10^9/l$ ), including 88.5% mature neutrophils (range, 78.8-98.5%), and a platelet count of 33.3 $\times 10^9/l$  (range, 23-94 $\times 10^9/l$ ). Thrombocytopenia was observed in the patient upon presentation and followed a progressive course,

exhibiting no response to treatment with hydroxyurea and IFN- $\alpha$ . Notably, the present study identified EVI-1 expression bone marrow samples from the patient by performing qualitative and quantitative screening tests. EVI-1 is an oncogene that confers poor prognosis in human hematological malignancies, including acute myeloid leukemia, CML and MDS (8). It was initially identified as the integration site of the ecotropic retrovirus that causes myeloid leukemia in murine model systems (16). The significant function of EVI-1 in hematopoietic stem cell regulation indicates that EVI-1 may participate in the generation of leukemic stem cells. These leukemic stem cells are a potential cause of therapeutic resistance in patients with leukemia (8). Furthermore, increased expression of EVI-1 may be important in development of human leukemias, particularly in the progression from the chronic to blastic crisis phases of CML, and even in cases without chromosome 3q26 abnormalities (17). In patients for whom the cause of neutrophilia is not easily discernible, the incorporation of *CSF3R* mutation testing may be a useful point-of-care diagnostic tool to evaluate the presence of a clonal myeloid disorder, as well as providing the potential for genetically-informed treatment. Maxson *et al* (6) detected a *CSF3R* mutational frequency of 89% in CNL and 44% in aCML, the most common of which is the p.T618I membrane proximal mutation. The present patient's results in the demonstrated a p.T618I membrane proximal mutation of *CSF3R* in the CD15<sup>+</sup> and CD34<sup>+</sup> cell fractions. Determining the presence and type of *CSF3R* mutation is valuable, as they may be useful in the differential diagnosis of leukocytosis and act as indicators of sensitivity to different kinase inhibitors. Thus, categorizing the type of *CSF3R* mutation in a patient with CNL/aCML promotes individualized therapy. Pardanani *et al* (10) recently performed *SETBP1* mutation screening in CNL/aCML cases and closely associated MNP cases. Overall, *SETBP1* mutational frequencies in WHO-defined CNL, aCML, chronic myelomonocytic leukemia and PMF were 33, 0, 7 and 3%, respectively. By contrast, Piazza *et al* (9) recently identified *SETBP1* mutations in 25% of aCML patients. Notably, Pardanani *et al* (10) identified no significant correlation between the presence of *CSF3R* mutations and age, gender or leukocyte count. In addition, it was identified that the presence or absence of *CSF3R* mutations did not affect survival, whereas there was a trend for shortened survival among *SETBP1*-mutated patients. Accordingly, the overexpression of EVI-1 and the presence of a *SETBP1* mutation identified in the current patient are indicators of poor prognosis. Unusually, genetic analysis of the current patient indicated concurrent mutations of *CSF3R* and *SETBP1*. A previous study identified that these two mutations are not mutually exclusive in CNL/aCML. Follow-up sequencing of an expanded cohort of 29 patients with CNL/aCML revealed that 21% exhibited *CSF3R* and *SETBP1* mutations, including 31% with *CSF3R* mutations only and 7% with *SETBP1* mutations only (7). These concurrent mutations indicate a requirement for different therapeutic approaches tailored to the molecular profile of individual patients (6). In the present study, there was insufficient time to commence treatment with JAK2 inhibitors, such as ruxolitinib, prior to the patient succumbing to the disease. However, Lasho *et al* (18) recently described a double-mutated CNL patient (*CSF3R* and *SETBP1*) who was refractory to treatment with ruxolitinib and hydroxyurea.

In conclusion, the present study reports the case of a 67-year-old man who presented with sustained neutrophilia, persistent thrombocytopenia, absent *BCR-ABL1* transcripts and a *JAK2*<sup>V617F</sup> mutation, in addition to overexpression of *EVI-1* and a novel, concurrent mutation of *CSF3R* and *SETBP1*. The patient was ultimately diagnosed with CNL. The current study demonstrates the difficulty in establishing a correlation between *EVI-1* overexpression and the pathogenesis of CNL; therefore, additional investigations are required to elucidate the mechanism by which *EVI-1* is associated with the pathogenesis of CNL.

### Acknowledgements

This study was supported by the National Natural Sciences Foundation of China (grant no. 81400092), the National Natural Sciences Foundation of Tianjin (grant no. 13JCYBJC23400) and the Science and Technique Foundation of Tianjin (grant no. 13KG106)

### References

- Bain BJ, Brunning BR, Vardiman JW and Thiele J: Chronic neutrophilic leukaemia. WHO Classification of Tumors of Haematopoietic and Lymphoid Tissues. IARC Press, Lyon, France, pp38-39, 2008.
- Böhm J and Schaefer HE: Chronic neutrophilic leukaemia: 14 new cases of an uncommon myeloproliferative disease. *J Clin Pathol* 55: 862-864, 2002.
- Elliott MA: Chronic neutrophilic leukemia and chronic myelomonocytic leukemia: WHO defined. *Best Pract Res Clin Haematol* 19: 571-593, 2006.
- Beekman R and Touw IP: G-CSF and its receptor in myeloid malignancy. *Blood* 115: 5131-5136, 2010.
- Dong F, van Buitenen C, Pouwels K, *et al*: Distinct cytoplasmic regions of the human granulocyte colony-stimulating factor receptor involved in induction of proliferation and maturation. *Mol Cell Biol* 13: 7774-7781, 1993.
- Maxson JE, Gotlib J, Pollyea DA, Fleischman AG, Agarwal A, Eide CA, *et al*: Oncogenic *CSF3R* mutations in chronic neutrophilic leukemia and atypical CML. *N Engl J Med* 368: 1781-1790, 2013.
- Gotlib J, Maxson JE, George TI and Tyner JW: The new genetics of chronic neutrophilic leukemia and atypical CML: Implications for diagnosis and treatment. *Blood* 122: 1707-1711, 2013.
- Goyama S and Kurokawa M: Pathogenetic significance of ecotropic viral integration site-1 in hematological malignancies. *Cancer Sci* 100: 990-995, 2009.
- Piazza R, Valletta S, Winkelmann N, Redaelli S, Spinelli R, Pirola A, *et al*: Recurrent *SETBP1* mutations in atypical chronic myeloid leukemia. *Nat Genet* 45: 18-24, 2013.
- Pardanani A, Lasho TL, Laborde RR, Elliott M, Hanson CA, Knudson RA, *et al*: *CSF3R* T618I is a highly prevalent and specific mutation in chronic neutrophilic leukemia. *Leukemia* 27: 1870-1873, 2013.
- Vardiman J and Hyjek E: World Health Organization classification, evaluation, and genetics of the myeloproliferative neoplasm variants. *Hematology Am Soc Hematol Educ Program* 1: 250-256, 2011.
- Tuohy E: A case of splenomegaly with polymorphonuclear neutrophil hyperleukocytosis. *Am J Med Sci* 160: 18-24, 1920.
- Böhm J, Kock S, Schaefer HE and Fisch P: Evidence of clonality in chronic neutrophilic leukaemia. *J Clin Pathol* 56: 292-295, 2003.
- Reilly JT: Chronic neutrophilic leukaemia: A distinct clinical entity? *Br J Haematol* 116: 10-18, 2002.
- Elliott MA and Tefferi A: The molecular genetics of chronic neutrophilic leukaemia: Defining a new era in diagnosis and therapy. *Curr Opin Hematol* 21: 148-154, 2014.
- Morishita K, Parker DS, Mucenski ML, Jenkins NA, Copeland NG and Ihle JN: Retroviral activation of a novel gene encoding a zinc finger protein in IL-3-dependent myeloid leukemia cell lines. *Cell* 54: 831-840, 1988.
- Ogawa S, Kurokawa M, Tanaka T, Tanaka K, Hangaishi A, Mitani K *et al*: Increased *EVI-1* expression is frequently observed in blastic crisis of chronic myelocytic leukemia. *Leukemia* 10: 788-794, 1996.
- Lasho TL, Mims A, Elliott MA, Finke C, Pardanani A and Tefferi A: Chronic neutrophilic leukemia with concurrent *CSF3R* and *SETBP1* mutations: Single colony clonality studies, *in vitro* sensitivity to JAK inhibitors and lack of treatment response to ruxolitinib. *Leukemia* 28: 1363-1365, 2014.