

The Healing Effect of *Arnebia Euchroma* Ointment versus Silver Sulfadiazine on Burn Wounds in Rat

Ebrahim Nasiri¹, Seyed Jalal Hosseinimehr^{1*}, Mohammad Azadbakht¹, Jafar Akbari¹, Reza Enayati-Fard², Sohail Azizi³, Masoud Azadbakht⁴

1. Traditional and Complementary Medicine Research Center, Faculty of Pharmacy, Mazandaran University of Medical Sciences, Sari, Iran;
2. Department of Pharmaceutics, Faculty of Pharmacy, Mazandaran University of Medical Sciences, Sari, Iran;
3. Department of Laboratory Medicine, Faculty of Allied Medical Sciences, Mazandaran University of Medical Sciences, Sari, Iran;
4. Sana Institute, Mazandaran, Sari, Iran

*** Corresponding Authors:**
Seyed Jalal Hosseinimehr, PhD,
Traditional and Complementary
Medicine Research Center,
Faculty of Pharmacy, Mazandaran
University of Medical Sciences,
Sari, Iran.
Tel/Fax: +98-11-33544308
Email: sjhosseinim@yahoo.com,
sjhosseinim@mazums.ac.ir
Received: Dec. 10, 2014
Revised: March 9, 2015
Accepted: April 6, 2015

ABSTRACT

BACKGROUND

Burn is still a major devastating condition in emergency medicine departments among both genders and all age groups in all developed and developing countries, leading to physical, psychological scars and economical burden. The present study aimed to determine the healing effect of topical treatment with *Arnebia euchroma* on second-degree burn wound in rats.

METHODS

Fifty rats were divided into 4 equal groups receiving the ointment base, normal saline (NS), standard 1% silver sulfadiazine (SSD), and 5% and 10% *Arnebia euchroma* ointments (AEO). The mean of burn area, percentage of wound contraction, histopathological and bacteriological assessments in the injured area were determined during the study.

RESULTS

Average area of wound on the 10th day was 10.2±2.3, 8.4±2.6, 12.4±2.5, 5.9±2.2 and 5.7±2 cm² for ointment base, NS, 1% SSD, and 5% and 10% AEO, respectively. Wound size was significantly lower in 10% AEO than 1% SSD and control groups on the 10th day post-burn injury. On day 11, the percentage of wound contraction in 5% and 10% AEO was 53.9%±14.7% and 55.9±10.5% which was more than 1% SSD (15.3±10.8%). The collagen fibers were well formed and horizontally-oriented in 5% and 10% AEO groups when compared with other groups.

CONCLUSION

Arnebia euchroma ointment was an effective treatment for healing of burn wounds in comparison with SSD and can be regarded as an alternative topical treatment for burn wounds.

KEYWORDS

Arnebia euchroma; Burns; Silver sulfadiazine; Rat; Wound healing

Please cite this paper as:

Nasiri E, Hosseinimehr SJ, Azadbakht M, Akbari J, Enayati-Fard R, Azizi S, Azadbakht M. The Healing Effect of *Arnebia Euchroma* Ointment versus Silver Sulfadiazine on Burn Wounds in Rat. World J Plast Surg 2015;4(2):134-144.

INTRODUCTION

Burn is still a major devastating condition in emergency medicine

departments among both genders and all age groups in all developed and developing countries, leading to physical, psychological scars and economical burden.¹ Thermal burn injury causes considerable incidence of disability, increase of hospitalization and rehabilitation. It is a crucial factor of morbidity and mortality, throughout the world, especially in the developing countries.^{2,3} Previous studies showed that thermal burn injury in different parts of world is high and treatment of burn wounds is a problem in public health systems.^{3,4} For survivors, the most persisting problem is scarring, so the process of wound healing and the final outcome of this process is under investigation with the hope of decreasing the problems related to scar. Burn wound healing is a complex process including inflammation, granulation, and remodeling of the tissue.⁵

There are many topical agents applied for burn wounds treatment. Silver sulfadiazine (SSD) is applied as standard topical therapy in healing of burn wounds with antibacterial activities.^{3,6} SSD cream has several side effects such as, neutropenia, erythema multiform, methemoglobinemia, leukopenia and renal toxicity. It might also delay of the wound healing. Previous studies were reported that SSD cream should not be used for long time on extensive wounds.^{3,6} Therefore, there is a need for new agents for treatment of burn wounds in health care practice with less adverse problems and better efficacy.⁷

It is important to find more effecting drugs with shorter healing time as compare to SSD in burn injury. The use of natural products to support of the wound healing is a common practice in the world. For centuries, the medicinal plants have been extensively used in wound healing of burned injuries.⁸⁻¹² Avicenna, the Persian scholar introduced some medicinal plants for dressing of wounds in his well-known book, Canon of Medicine, at 980-1037 AD.¹³ Today, evaluation of natural products on burns is a main part of health management and together is a capable way to offer more effective and cheaper healthcare options.^{3,14}

Arnebia euchroma (Royle) I. Johst from the Boraginaceae family grows in different countries such as India, North Africa, Turkey, Himalaya and Iran especially in the mountain areas in north of Iran.^{15,16} *A. roots* is known as Havachoobeh in folklore and Iranian traditional Medicine (ITM) and it has been used traditionally for centuries by the Iranian people for treatment of the burn

wounds as “ Marhame Havachoobeh.¹⁷⁻¹⁹ *A. euchroma* has also analgesic properties.²⁰

Arnebia euchroma roots contains important chemical components such as naphthoquinones, shikonin, alkanin and isohexeny Inaphthazarin esters derivatives that have many pharmacological properties.^{6,21} These components have biological properties such as wound healing and antibacterial effects.²¹ This herb was evaluated to have many pharmacological properties such as anti-inflammatory,^{15,22} antimicrobial activity,^{6,23} antiamebic, antitumor, and anticancer effects.^{12,15,21} The purpose of this study was to evaluate of the healing effect of *A. euchroma* ointment on second degree burn wounds in rats in comparison to SSD.

MATERIALS AND METHODS

The roots of *A. euchroma* were prepared from a local herbal market in Sari in north of Iran during October 2013. It was confirmed by botanists Dr. Masoud and Dr. Mohammad Azadbakht at the Mazandaran University of Medical Science, Iran (Herbarium number: 1001). The roots of the *A. euchroma* were washed and dried in a hot air oven at 40°C for 8 hours.

The dried materials were powdered in a grinder. Then samples were sieved and levigated with glycerine. Finally, liquid paraffin and eucerin were added and mixed. *A. euchroma* ointment (AEO) was made from *Arnebia euchroma* (10 g), glycerin (25 g), eucerin (60 g) and liquid paraffin (5 g). This formulation with the weight ratio of AEO (1:2.5:0.5: 6) was prepared as described before.^{24,25} Levigated AEO was mixed with liquid paraffin, eucerin, propyl and methyl paraben, then the composition was mixed and homogenized at 500 rpm for 10 min. This ointment containing 5 and 10% AEO were prepared identically. All formulations were filled in tubes and stored in 4, 25, and 40°C for two weeks and the stability of ointments were evaluated.

The experimental protocol was approved by Ethical and Research Committee of Mazandaran University of Medical Sciences (No=118-92, 3). All animals were obtained from this university. Male Wistar rats (n=50) weighing 160-200 g with average age of 10 weeks old were used and housed under standard condition at room temperature with a 12-h light/dark cycle. Animals were allowed free access to

laboratory food and water *ad libitum*. The rats were anesthetized by intraperitoneal injection of 50 mg/kg sodium thiopental.

The dorsal portion of the body was shaved using an electrical clipper and 70% alcohol was used to disinfect the dorsal area. Deep anesthetized rats were kept in prone position. A deep second degree burn wound was caused by a hot plate (diameter: 5 cm × 2.5 cm) warmed 5 min within boiling water and put for 10 s on the skin with an equal weight and pressure as described before.⁷

All rats were immediately resuscitated with injection of 5 ml normal saline.²⁶ The burned animals were randomly divided into five groups of ten rats. Group 1 was control that was only washed with normal saline (NS) during dressing without any topical treatment; group 2 was treated with the ointment base without any effective agent; group 3 was treated with 1% SSD (Behvarzan Pharmaceutical Company, Iran). Groups 4 and 5 were treated with 5 and 10% AEO, and then sterile plain gauze was covered and fixed on wound for 24 hours.

All wounds were washed with normal saline, and wound in each group was applied with cream and dressed. Wounds were dressed once per day. Rats were washed with normal saline before dressing in all groups. In order to quantify the rate of wound healing, the size of lesions was determined on 1, 3, 7, 10, 15, 20, 25, and 30 days after burn injury. The wound area was displayed as cm². The area of wounds at each day was determined by a formula, where represents the area (cm²) by length, and latitude rectangular.

Percentage of wound contraction at each time point was derived by the following formula: percent wound contraction=(initial wound area-current wound area)/initial wound area×100%.

Also, the sum of the scales in each part of histopathological evaluation was divided to four groups. We evaluated extent of granulation tissue, the new dermis, collagen organization and re-epithelization, according to Table 1 as a histological study.²⁷⁻²⁹ Histopathological conditions of the complete burn wound healing and re-epithelialization was evaluated on 7 and 21 days after burn injury. Burned skin tissue samples were taken for histological studies with a small excision containing part of the wound area. Tissue samples were fixed in 10% formalin solution. Paraffin embedded tissue section of 4 μm were prepared and tissue processing stained with hematoxylin and eosin. Light microscopy was used to assessing pathological changes.

These tissue sections were assessed by a blinded pathologist. The average of ten microscopic fields was recorded by him for each specimen. Histopathological criterias were defined according to a modified scoring system for surgical wound healing taken from previous studies according to the sum of the scales for wound healing divided to three groups.²⁷⁻²⁹ Extent of granulation tissue was scored based on seven parameters on 7th day includin (i) Monocytic macrophage (0-3), (ii) Neovascularization (0-3), (iii) Fibroblastic proliferation (0-3), (iv) Degree of granulation tissue (0-3), (v) Matrix (mucopolisacarid deposition) (0-3), (vi) Degree of inflammation (0-3), and (vii) Extend of bacterial

Table 1: Scales for the burn wound healing accordind to histopathological components

Sum of components variables	Difinition of Scales
Extent of granulation tissue (7 parameters) [(-3)-18]	(-3-0)=not healing (1-4)=low (5-12)=moderate healing (13-18)=good wound healing.
Re-epithelization (6 components) [0-18]	0=not healing (1-6)=low (7-12)=moderate healing (13-18)=good wound healing.
New dermis (5 parameters) [0-15]	0=not healing (1-5)=low (6-10)=moderate healing (11-15)=good wound healing.
Sum of three components [0-57]	[(-3)-0]=not healing [1-18]=low (19-37)=moderate healing (38-57)=good wound healing

colonization (-3 to 0).

The sum of scales related to granulation state was a range from -3 to 18. The 18 value was highest degree of granulation tissue formation on the 7th day after burn injury while [-3-0]=absent granulation, [1-4]=low, [5-12]=moderate, and [13-18] was determined as good extent of granulation tissue. The re-epithelization was monitored by evaluation of six components as following on the 7th day including (i) Epidermal thickness extent with (0-3), (ii) Thickness of granular cell layer (0-3), (iii) Maturation and organization of squamous cells (0-3), (iv) Extent of keratin layer (0-3), (v) Orthokeratin (0-3) and (vi) Parakeratosis (0-3). In full thickness, thin with completely well organized and showed with score of 3(+++). The sum of scales related to re-epithelization was at range of 0 to 18. The 18 value was the highest degree of re-epithelization on the 7th day after burn injury including 0=no epithelialization, [1-6]= low, [7-13]=moderate, and [14-18] was determined as good re-epithelization.²⁷⁻²⁹

The histopathological examination of the complete wound healing or the new dermis was scored based on five components as follows: (i) Degree of scar formation (0-3), (ii) Matrix of collagenization organization (0-3), (iii) Extent of hair follicles (0-3), (iv) Extent of lymphatic ducts (0-3), and (v) Degree of innervation (0-3). The sum of score was at a range between 0 to 15. The best condition for new dermis was scored 15 on 21st day after burn injury. The sum of scales for wound healing were divided to four groups as follows: 0=no healing, (1-5)=low, (6-10)=moderate healing, and (11-15)=good healing.²⁷⁻²⁹ The sum of scales for each part of histopathological evaluation was divided to three groups (extent of granulation, new dermis, and re-epithelization) as shown in Table 1.

Main parameters of new dermis, and collagen organization were defined at four levels, and each level was scored and defined as follows: (-) or 0=lacking down disorganized and poorly oriented collagen fiber none or absent, (+) or 1=10-20% collagen fibers are horizontally oriented, (++) or 2=30-40% collagen fibers are horizontally oriented, and (+++) or 3=well formed and horizontally oriented collagen fiber. Complete healing was evaluated by degree of scar formation, collagenization organization, hair follicles and degree of innervations after three weeks of burn induction. A score was

defined for all parameters evaluated: including 0= absent, 1=mild presence, 2=moderate presence and 3=strong presence.³⁰

Swabs were taken from the burn wound during dressing change on 4th and 8th days. The collected swabs were immediately transferred to the laboratory for microbial test. In the quantitative count study, 0.5 ml of normal saline was added to each of the samples. Each sample dilution was spread onto blood and Macconkey agar, and the plates were incubated at 37°C for 24 hours. Diagnostic test for the colonies was applied with neopucine.

Wound sites were assessed daily. Macroscopic visual evaluation was measured by direct observation of wound during dressing each day. Inflammatory tissue was defined to have edema, secretion, redness, dark secretion or pus, pain and wound bleeding during dressing washing. At each follow-up visit, the wound area was noted as being absent for any secretion, and have red, edematous, dirty and light or dark secretions.

Statistical analysis was carried out using the SPSS and Excel software. One-way analysis of variance (ANOVA) was used to compare variables in all groups. Post Hoc multiple comparisons Tukey test was used to compare the means and also, Kruskal Wallis H test for qualitative variables between groups (SPSS, version 15.0 for windows, Chicago, IL, USA). The differences were considered significant at $p < 0.05$.

RESULTS

The effect of burn injury on losing weight of rat was shown in Table 2. No significant differences were noticed between AEO and control groups for weight loss after burn injury. Skin wounds were measured on days 1, 3, 7, 10, 15, 20, 25 and 30 post-burn injury. The average area of wound on the 7th day was 11.2 ± 2.4 , 9.9 ± 1.7 , 13.1 ± 1.6 , 10.3 ± 2.5 and 9 ± 2 cm² in ointment base, NS, 1% SSD, 5 and 10% AEO, respectively ($p < 0.002$). The wound sizes were not significantly different between groups on the 1st and 3rd days after burn injury.

On the 7th day of the post-burn injury, wound area was significantly different between groups following multiple comparison by Tukey post Hoc test showing that NS, 5 and 10% AEO exhibited a lower wound size as compared to 1% SSD at the 7th day after burn injury, respectively ($p < 0.03$, $p < 0.04$ and $p < 0.001$) (Table 3). There was not any evidence of noticeable skin irritation

Table 2: Mean weights (gram) of the rats after burn injury

Group*	1 st day	3 rd day	7 th day	15 th day	25 th day	30 th day
BO	183±16	191±18	196±21	209±24	219±31	227±27
N/S	183±13	191±13	197±12	209±12	227±15	239±11
SSD	184±12	190±11	197±11	209±11	228±12	241±9
5% A	182±18	192±21	198±20	210±21	225±22	237±14
10% A	182±17	190±18	197±17	209±15	226±9	239±21
<i>P value</i>	0.999	1	0.998	1	0.874	0.515

*Ointment base (BO), normal saline (N/S), 1% silver sulfadiazine (1% SSD) and 5 and 10% *Arnebia euchroma* ointment (5% A, 10% A).

Table 3: Mean wound area (cm²) of the animals treated with various topical ointments post-burn injury

Group*	1 st day	3 rd day	7 th day	10 th day	15 th day	20 th day	25 th day	30 th day
BO	13.1±2.8	14.2±2	11.2±2.4	10.2±2.3	5.1±1.5	1.8±0.6	1±0.6	0.4±0.3
N/S	11.9±2.5	12.5±2.2	9.9±1.7	8.4±2.6	6.9±2.2	3.9±1.5	0.7±0.4	0.08±0.1
SSD	13.5±2.2	13.9±2.6	13.1±1.6	12.4±2.5	10.5±1.5	5.5±1.5	3.1±1.3	1.9±0.8
5% A	13±3.8	14.6±2.6	10.3±2.5	5.9±2.2	2.4±0.6	0.4±0.3	0	0
10% A	12.8±2.2	15.8±2.9	9±2	5.7±2	2.1±0.3	0.4±0.3	0	0
<i>P value</i>	0.795	0.089	0.002	0.001	0.001	0.001	0.001	0.001

*Ointment base (BO), normal saline (N/S), 1% silver sulfadiazine (1% SSD) and 5 and 10% *Arnebia euchroma* ointment (5% A, 10% A).

such as erythema, edema and inflammation during the study period.

The wound area was not significantly difference between control groups (1% SSD, ointment base and NS) on the 10th day of post-burn injury. The difference was significant between 5 and 10% AEO and SSD. No significant difference was noticed regarding the wound size between 5 and 10% AEO treated groups on 10th and 15th days after burn injury. The percentage of wound contraction in different groups was shown in Table 4 showing a significant increase in the 5 and 10% AEO groups when compared to the control group. Animals receiving 1% SSD ointment had a longer healing time in comparison to rats in the AEO treatment groups. These findings were shown in Figure 1. It is clear that wound contraction started from day 5 in all groups, which was faster in the 5 and 10% AEO groups as

compared to the control group. On day 7, animals treated with 10% AEO exhibited significant increase in the percentage of wound contraction as compared to other experimental groups (29.7% in 10% AEO as compared to 3.4% in SSD, 14.4% in ointment base and 16.2% in NS groups).

On day 15 of post-burn injury, 5% and 10% AEO showed about 95% wound healing, whereas it was 32.2%, 56% and 65.5% for rats treated with %1 SSD, NS and ointment base, respectively. On day 25, No scar was seen in animals treated with 10% AEO, while this improvement was observed for 1% SSD group after day 35. A completed wound healing was noticed in animals treated with 5% and 10% AEO on 25th day, while this time period was 35th day for 1% SSD and control groups. It is clear that wound care in the rats treated with AEO was at least 10 days shorter than 1% SSD and

Table 4: Comparison of the percentage of wound contraction between *Arnebia euchroma* and other groups

Group*	3 rd day (%)	7 th day (%)	11 th day (%)	15 th day (%)	20 th day (%)	25 th day (%)	30 th day (%)	35 th day (%)
BO	-8.6±12.7	10±8.7	19.8±10.6	65.5±6	86.7±4.4	92.3±3	96.8±2.3	99.4±1.2
N/S	-6.4±10.6	14.6±9.7	27.9±16.8	56±11.2	68.2±8.1	93.8±2.4	98.9±1.5	98.6±1.8
1% SSD	-2.7±7	3.5±8.4	15.3±10.8	32.2±12.6	61.3±9.6	77.9±9.8	86.8±5.5	95.8±3.2
5% A	-8.6±7.6	22.5±11.5	53.9±14.7	95.5±4.3	97.1±2.7	99.6±.6	100	100
10% A	16.8±6.3	26.9±10.6	55.9±10.5	96.3±3.6	97.9±2.3	100	100	100

*Ointment base (BO), normal saline (N/S), 1% silver sulfadiazine (1% SSD) and 5 and 10% *Arnebia euchroma* ointment (5% A, 10% A).

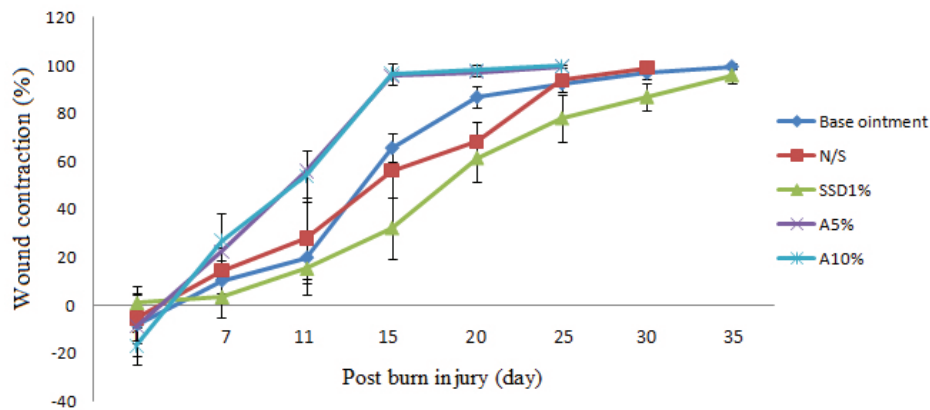


Fig. 1: Comparison of the percentage of wound contraction between *Arnebia euchroma* and other groups. 5 and 10% *Arnebia euchroma* ointment showed a faster wound contraction.

the control groups (Table 4 and Figure 1). The condition of wound healing on the 4th and 16th days after burns was illustrated in Figure 2.

The extent of granulation tissue formation, matrix organization, re-epithelialization and formation of a new dermis were determined. On day 7, samples revealed an increase in macrophage and cellular infiltration in animals treated with 5 and 10% AEO in comparison to SSD and NS groups. The extent of maturation, tissue organization and re-epithelialization was more in groups treated with 5 and 19% AEO

when compared with SSD and ointment base groups (Figure 3).

At the 7th day of the experiment, histopathological evaluation showed the highest formation of granulation tissue for *A. euchroma* and the lowest extent for NS group (Table 5). The re-epithelialization parameter for 5% AEO treated group was significantly more than 1% SSD and controls groups ($p < 0.05$) (Table 6). The collagen organization in 10% AEO group was better than 1% SSD and control groups on 21st day. The score of collagen organization in 10% AEO, SSD, 5%

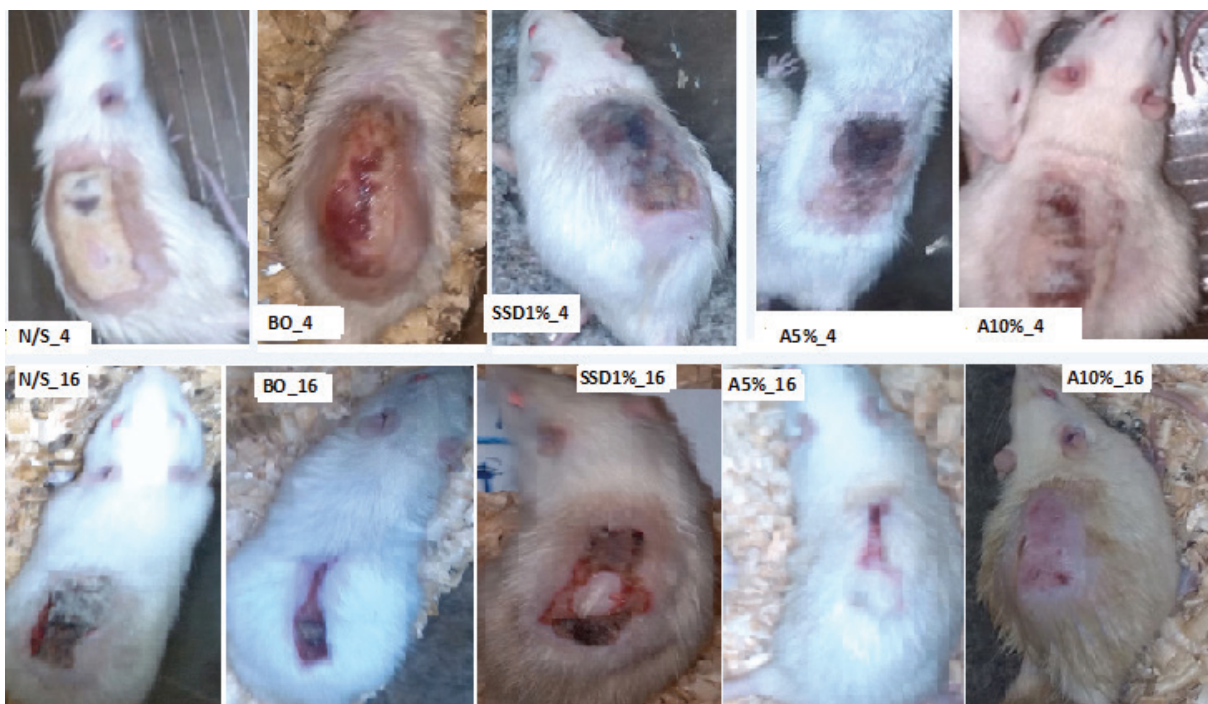

Fig. 2: Burn wound healing patterns in Normal saline (N/S), ointment Base (BO), 1% silver sulfadiazine (1% SSD) and 5 and 10% *Arnebia euchroma* ointment (5% A, 10% A) in rats after 4 and 16 days. Average wound size was smaller and the healing rate was faster in 5% A and 10% *Arnebia euchroma* ointment than other groups; $p < 0.001$.

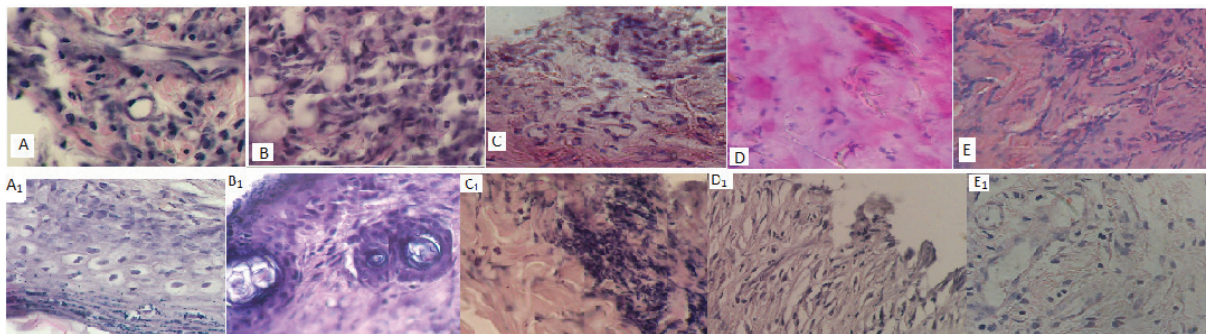


Fig. 3: Comparison of the histopathology of samples from second degree burn wounds on 7th and 21st days after treatment with ointment base (BO), normal saline (N/S), silver sulfadiazine (1% SSD), and 5% *Arnebia euchroma* (5% A) and 10% *Arnebia euchroma* (10% A). Macrophage infiltration, neovascularization and fibroblastic proliferation were more in 10% A, and 5% A, compared with 1% SSD, BO and N/S groups on the 7th day. Also, thickness of granular cell layer and epidermal thickness extent were prominent in *Arnebia euchroma* groups in comparison with other groups on 7th and 21st days. A=5% *Arnebia euchroma*_7th day, A₁=5% *Arnebia euchroma*_21st day, B=10% *Arnebia euchroma*_7th day, B₁=10% *Arnebia euchroma*_21st day, C=1% Silver sulfadiazine_7th day, C₁=1% Silver sulfadiazine_21st day, D=Ointment base_7th day, D₁=Ointment base_21st day, E=Normal saline_7th day, E₁=Normal saline_21st day.

Table 5: Histopathology of granulation tissue formation among different groups on the 7th day after burn injury

Components/Groups*	BO	1% SSD	N/S	5% A	10% A
Macrophage histocytic infiltration	3	2	2	3	3
Neovascularization	2	2	2	3	3
Fibroblastic proliferation	2	2	2	3	3
Matrix mucopolisaccharide deposition	1	2	2	2	2
Degree of inflammation	2	3	1	3	3
Extent of bacterial colonization	-1	-2	-1	-1	-1
Degree of granulation tissue formation	2	2	1	3	3
Total	11	11	9	16	16

*Ointment base (BO), normal saline (N/S), 1% silver sulfadiazine (1% SSD) and 5 and 10% *Arnebia euchroma* ointment (5% A, 10% A).

Table 6: Comparison regarding re-epithelialization between groups on the 7th day post-burn injury

Group*/ Components	Epidermal thickness (0-3)	Thickness of granular cell layer	Maturation organization of squamous cells	Extent of keratin layer	Orthokeratin	Parakeratosis	Total
BO	1	1	1	1	1	0	5
N/S	10	0	0	0	0	0	0
1% SSD	1	1	1	1	1	1	6
5% A	3	3	2	2	2	0	12
10% A	3	3	3	3	3	0	15
<i>P value</i>							0.001

*Ointment base (BO), normal saline (N/S), 1% silver sulfadiazine (1% SSD) and 5 and 10% *Arnebia euchroma* ointment (5% A, 10% A).

AEO, ointment base and NS groups was 3, 2, 2, 1 and 2, respectively (Table 7).

Histopathological findings showed a complete wound healing and new dermis formation in 10% AEO, whereas 5% AEO and

1% SSD and ointment base groups showed a moderate wound healing score. The assessment of granulation tissue formation demonstrated that SSD and ointment base groups when compared with AEO groups (5 and 10%) did

Table 7: Comparison of new dermis formation between groups on the 21st day post-burn injury time

Groups*	Degree of scar formation	Collagenization/ organization	Extent of hair follicles	Extent of lymphatic ducts	Degree of innervations	Total
5% A	2	2	2	1	0	7
10% A	3	3	3	2	1	12
1% SSD	2	2	1	0	0	5
Base Ointment	2	1	1	1	1	6
N/S	2	2	1	0	0	5

*Ointment base (BO), normal saline (N/S), 1% silver sulfadiazine (1% SSD) and 5 and 10% *Arnebia euchroma* ointment (5% A, 10% A).

not have any significant differences, whereas NS group did have a significant difference with AEO treated groups ($p < 0.38$). Formation of new dermis in AEO groups was better than SSD and control groups ($p < 0.017$). The sum of three main histopathology components of wound healing were shown in Table 7.

According to histopathological findings (Table 8), 5 and 10% AEO treated groups had a good healing, 1% SSD and ointment base groups had moderate healing and NS group had a low wound healing score. No edema, inflammation or discharges were seen in rats treated with AEO and SSD during the study. The period of re-epithelialization time among the study groups were different. The re-epithelialization time for 10% AEO was 20.3 ± 4 days and for 5% AEO, NS, ointment base and 1% SSD was 20.8 ± 3.6 , 29.5 ± 3.1 , 33 ± 3.6 and 34.7 ± 3 days, respectively ($p < 0.001$).

A complete wound healing was observed in animals treated with 5 and 10% AEO on 20th day, while this time was 34.7 days for 1% SSD and almost similar for the other control groups. It is clear that wound care in the rats treated with AEO was 9-14 days shorter than the control groups. Visual observations of the burn wounds in the NS and ointment base groups showed a moderate secretion, redness and edema in the

wound area, whereas wounds treated with AEO and 1% SSD showed a negligible redness and edema without any secretion.

The laboratory assessments indicated no evidence of bacteria. In the 4th and 8th days, a little secretion appeared in wounds in some rats treated with ointment base, NS, SSD and 5% AEO. These samples were cultured on blood agar and were positive for growth of Gram positive cocci while were sensitive to neopucine that was considered as an epidermal normal flora.

DISCUSSION

The purpose of this study was to evaluate the effect of AEO on healing of burn wounds in experimental rats. Results showed a significant improvement in wound healing of rats treated by topical 5 and 10% AEO during the experimental period, as compared with 1% SSD and other control groups. Topical AEO were much more effective in wound healing than 1% SSD, ointment base and NS groups. Wound size was remarkable less in 5 and 10% AEO groups as compared with control and 1% SSD groups after 7 days. AEO did not show any toxicity and side effects.¹⁸ The root of *A. euchroma* used to prepare AEO has been used in Iranian traditional medicine in different parts of Iran and also in

Table 8: The sum of the Scales of three histopathological components for burn wound healing

Group	Re-epithelialization [0-15]	Extent of granulation tissue [(-3)-18]	New dermis formation [0-15]	Sum of scales [(-3)-58]
BO	5	12	6	23
N/S	1	9	5	15
1% SSD	6	11	5	22
5% A	12	16	7	35
10% A	15	16	12	43
<i>P value</i>				$p < 0.001$

*Ointment base (BO), normal saline (N/S), 1% silver sulfadiazine (1% SSD) and 5 and 10% *Arnebia euchroma* ointment (5% A, 10% A).table

other countries for treatment of wound healing.

Many chemical components have been identified in *A. euchroma* roots and leaves from Boraginaceae family.^{15,26} Alkannins and Shikonins existed in the external layer of the roots of the *A. euchroma*. Pharmaceutical formulations with wound healing properties based on alkannins and shikonins have been in the market for many years. Previous studies revealed that *A. euchroma* was rich in naphthoquinones, hydroxynaphthoquinone, phenolic acids, alkaloids, shikonins and Alkannins.^{21,27} It was shown that shikonins derivatives and alkannins from *A. euchroma* and Boraginaceae family had anti-inflammatory and wound healing properties.^{15,19}

In addition, antibacterial,²⁸ anti-inflammatory,²² antioxidant, antiviral, antifungal, antitumor, anticancer,^{21,26,27} and analgesia effects,^{17,26,27} of *A. euchroma* have been reported before. In the present work, our findings denoted to the efficiency of *A. euchroma* root which was superior to 1% SSD in burn wound healing.

The anti-inflammatory, antibacterial and antioxidant properties of *A. euchroma* would be a potential to improve wound healing. Our finding showed that 5% and 10% AEO could effectively prevent secondary complications of burn such as swelling, erythema and secretion or wound infection that may be due to antibacterial properties of this ointment. Improved rate of wound contraction and reduction was observed in animal treated with *A. euchroma* roots. This result is consistent with other reports of wound healing of the most other species of Boraginaceae family, raising the possibility that this family has a wound healing potential.^{16,22}

The wound healing rate of *A. euchroma* was shorter than that of the standard 1% SSD ointment. A delay in burn wound healing was observed in the ointment base, NS and 1% SSD groups when compared with 10% AEO. In the AEO group in comparison to the 1% SSD treated group, less complications were visible explaining the delay in wound healing in control groups as compared to AEO group. Although previous study showed that 1% SSD ointment was a standard ointment in burn wounds, but it was associated with longer hospitalization.^{3,28,29}

In histopathological assessment, re-epithelialization was significantly more in animals treated 10% AEO. Re-epithelialization was dependent on the thickness of granular cell

layer, epidermal thickness extent, maturation and organization of squamous cells and migration of epithelial cells that all these components showed an increasing trend. Previous studies reported the anti-inflammatory effect of some Boraginaceae species and development of collagen fibers and epithelium regeneration that were accelerated and also the epithelium thickness improved.^{16,28,29}

In this study, the wound repair process in AEO group was better than 1% SSD and other control groups regarding the degree of inflammation, mucopolysaccharid deposition, fibroblastic proliferation, macrophage infiltration, granulation tissue formation and neovascularization. No pathogenic organism was noticed when AEO was administered.

A. euchroma treatment measure lead to an increase in neovascularization, short period of epithelialization and absence of any infection. Re-epithelialization significantly increased in the 10% AE group in comparison to other groups. Collagen plays an essential role in wound healing and as a principal component of connective tissue provides a structural framework for the tissue regeneration. Collagen is produced by fibroblasts affecting the healing process during wound healing.³⁰ The effects of AEO on wound healing is through changes in cell regeneration and collagen synthesis and density of blood vessels.^{25,26} Wound healing process is complex and occurs during coagulation, inflammation, debridement and re-epithelialization phases and is associated with proliferation, migration and integration of squamous epithelial cells of the epidermis. In the end stage of the healing process, collagen deposition and remodeling occurs in the dermis.³¹ The granulation tissue formation and re-epithelialization on the 7th day post-burn injury and formation of the new dermal tissue on the 21st day was better in AEO group when compared with other groups. In most cases, the AEO in high concentration showed better healing effects than the other groups. One possible assumption for this could be due to important phytochemical constituents of *A. euchroma* for wound healing such as flavonoids, alkannin derivatives, according to the ITM program, Marhame Havachoobeh being used traditionally for centuries by Iranian people for treatment of the burn wounds. Formulation of the Marhame Havachoobeh was simple. It was prepared based on sesame oil and wax. Also, the roots of Boraginaceae family plants soaked in butter

were used in treatment of local wounds.^{17,18,24} Also, the roots of Boraginaceae family plants soaked in butter are used in treatment of local wound. *A. euchroma* ointment was prepared on eucerin. This simple levigated ointment may be better released from constituents in the Arnebia roots.^{16,32} Results of this study showed that preparation of *A. euchroma* roots is simple and with low cost and effective in burn wound healing in comparison to silver sulfadiazine. Therefore, topical administration of *A. euchroma* ointment can be an alternative in healing of burn wounds.

ACKNOWLEDGMENTS

This study was supported by a grant from Mazandaran University of Medical Sciences, Sari, Iran. This research was the subject of a PhD thesis of Ebrahim Nasiri as a student of Mazandaran University of Medical Sciences.

CONFLICT OF INTEREST

The authors declare no conflict of interest.

REFERENCES

- Mohammadi AA, Amini M, Mehrabani D, Kiani Z, Seddigh A. A survey on 30 months electrical burns in Shiraz niversity of Medical Sciences Burn Hospital. *Burns* 2008;**34**:111-13.
- Pasalar M, Mohammadi AA, Rajaeefard AR, Neghab M, Tolidie HR, Mehrabani D. Epidemiology of burns during pregnancy in southern Iran: Effect on maternal and fetal outcomes. *World Appl Sci J* 2013;**28**:153-8.
- Khorasani G, Hosseinimehr SJ, Azadbakht M, Zamani A, Mahdavi MR. Aloe versus silver sulfadiazine creams for second-degree burns: a randomized controlled study. *Surg Today* 2009;**39**:587-91.
- Kulac M1, Aktas C, Tulubas F, Uygur R, Kanter M, Erboga M, Ceber M, Topcu B, Ozen OA. The effect of topical treatment with curcumin on burn wound healing in rats. *J Mol Histol* 2013;**44**:83-90.
- Tanideh N, Haddadi MH, Rokni-Hosseini MH, Hossienzadeh M, Mehrabani D, Sayehmiri K, Koochi-Hossienabadi O. The healing effect of *Scrophularia striata* on experimental burn wounds infected to *Pseudomonas aeruginosa* in rat. *World J Plast Surg* 2015;**4**:16-22.
- Hosseini SV, Tanideh N, Kohanteb J, Ghodrati Z, Mehrabani D, Yarmohammadi H. Comparison between Alpha and silver sulfadiazine ointments in treatment of *Pseudomonas* infections in 3rd degree burns. *Int J Surg* 2007;**5**:23-6.
- Manafi A, Kohanteb J, Mehrabani D, Japoni A, Amini M, Naghmachi M, Zaghi AH, Khalili N. Active immunization using exotoxin a confers protection against *Pseudomonas aeruginosa* infection in a mouse burn model. *BMC J Microbiol* 2009;**9**:19-23.
- Amini M, Kherad M, Mehrabani D, Azarpira N, Panjehshahin MR, Tanideh N. Effect of plantago major on burn wound healing in rat. *J Appl Anim Res* 2010;**37**:53-6.
- Hazrati M, Mehrabani D, Japoni A, Montasery H, Azarpira N, Hamidian-Shirazi AR, Tanideh N. Effect of honey on healing of *Pseudomonas aeruginosa* infected burn wounds in rat. *J Appl Anim Res* 2010;**37**:106-10.
- Hosseini SV, Niknahad H, Fakhar N, Rezaianzadeh A, Mehrabani D. The healing effect of honey, putty, vitriol and olive oil in *Pseudomonas aeruginosa* infected burns in experimental rat model. *Asian J Anim Vet Adv* 2011;**6**:572-9.
- Tanideh N, R okhsari P, M ehrabani D, Mohammadi Samani S, Sabet Sarvestani F, Ashraf MJ, Koochi Hosseinabadi O, Shamsian Sh, Ahmadi N. The healing effect of licorice on *Pseudomonas aeruginosa* infected burn wounds in experimental rat model. *World J Plast Surg* 2014;**3**:99-106.
- Mehrabani D, Farjam M, Geramizadeh B, Tanideh N, Amini M, Panjehshahin MR. The Healing Effect of Curcumin on Burn Wounds in Rat. *World J Plast Surg* 2015;**4**:29-35.
- Mohajeri G, Masoudpour H, Heidarpour M, Khademi EF, Ghafghazi S, Adibi S, Akbari M. The effect of dressing with fresh kiwifruit on burn wound healing. *Surgery* 2010;**148**:963-8.
- Suntar IP, Akkol EK, Yilmazer D, Baykal T, Kirmizibekmez H, Alper M, Yesilada E. Investigations on the in vivo wound healing potential of *Hypericum perforatum* L. *J Ethnopharmacol* 2010;**127**:468-77.
- Kaith BS, Kaith NS, Chauhan NS. Anti-inflammatory effect of *Arnebia euchroma* root extracts in rats. *J Ethnopharmacol* 1996;**55**:77-80.
- Kosger HH, Ozturk M, Sokmen A, Bulut ESA. Wound healing effects of arnebia densiflora root extrcts on rat palatal mucosa.

- Eur J Dent* 2009;**3**:96-9.
- 17 Aliasl JFK. Traditional herbal remedies for burn wound healing in Canon of Avicenna. *Jundishapur J Nat Pharm Prod* 2013;**8**:192-6.
 - 18 Nasiri E, Hosseinimehr SJ, Azadbakht M, Madani SA. A review of natural products for burn healing based on the Iranian traditional medicine. *J Mazand Univ Med Sci* 2014;**23**:263-76.
 - 19 Aghilikhorasani MH. *Gharabadin kabir*. Tehran Med Univ. Press, Tehran, 2009.
 - 20 Soltanian AR, Mehdibarzi D, Faghihzadeh S, Naseri M, Gerami A. Mixture of *Arnebia euchroma* and *Matricaria chamomilla* (Marhame-Mafasel) for pain relief of osteoarthritis of the knee-a two-treatment, two-period crossover trial. *Arch Med Sci* 2010;**6**:950-5.
 - 21 Pirbalouti AG, Yousefi M, Nazari H, Karimi I. Evaluation of burn healing properties of *Arnebia euchroma* and *Malva sylvestris*. *Electronic J Biol* 2009;**5**:62-6.
 - 22 Singh B, Sharma MK, Meghwal PR, Sahu PM, Singh S. Anti-inflammatory activity of shikonin derivatives from *Arnebia hispidissima*. *Phytomedicine* 2003;**10**:375-80.
 - 23 Shen CC, Syu WJ, Li SY, Lin CH, Lee GH, Sun CM. Antimicrobial activities of naphthazarins from *Arnebia euchroma*. *J Nat Prod* 2002;**65**:1857-62.
 - 24 Khalil EA, Afifi FU, Al-Hussaini M. Evaluation of the wound healing effect of some Jordanian traditional medicinal plants formulated in pluronic F127 using mice (*Mus musculus*). *J Ethnopharmacol* 2007;**109**:104-12.
 - 25 Aliasl J, Khoshzaban F, Barikbin B, Naseri M, Kamalinejad M, Emadi F, Razzaghi Z, Talei D, Yousefi M, Aliasl F, Barati M, Mohseni-Moghaddam P, Hasheminejad SA, Esmailzad Nami H. Comparing the healing effects of *Arnebia euchroma* ointment with petrolatum on the ulcers caused by fractional CO₂ laser: A single-blinded clinical trial. *Iran Red Crescent Med J* 2014;**16**:e16239.
 - 26 Hosseinimehr SJ, Khorasani G, Azadbakht M, Zamani P, Ghasemi M, Ahmadi A. Effect of aloe cream versus silver sulfadiazine for healing burn wounds in rats. *Acta Dermatovenerol Croat* 2010;**18**:2-7.
 - 27 Haghdoost, F, Baradaran- Mahdavi, M M, Zandifar, A, and Sanei, M H B Z. Pistacia atlantica Resin Has a Dose-Dependent Effect on Angiogenesis and Skin Burn Wound Healing in Rat. *Evid Based Complement Alternat Med* 2013;**893425**:1-8.
 - 28 Khorasani GA, Hosseinimehr SJ, Zamani P, Ghasemi MAA. The effect of Saffron (*Crocus Sativus*) extract for healing of second-degree burn wound in rats. *Keio J Med* 2008;**57**:190-5.
 - 29 Edraki M, Akbarzadeh A, Hosseinzadeh M, Tanideh N, Salehi A, Koochi-Hosseiniabadi O. Healing Effect of Sea Buckthorn, Olive Oil, and Their Mixture on Full-Thickness Burn Wounds. *Adv Skin Wound Care* 2014;**27**:317-23.
 - 30 Tavares Pereira Ddos S, Lima-Ribeiro MH, de Pontes-Filho NT, Carneiro-Leao AM, Correia MT. Development of animal model for studying deep second-degree thermal burns. *J Biomed Biotechnol* 2012;**2012**:460841.
 - 31 Pirbalouti AG, Koochpayeh A, Azizi S, Golparvar A. Evaluation of the Burn Healing Properties of *Arnebia Euchroma* Rolye (Johnst) in Diabetic Rats. *Int Conference Biosci Biochem Bioinform* 2011;**5**:144-6.
 - 32 Papageorgiou VP, Assimopoulou AN, Ballis AC. Alkannins and shikonins: a new class of wound healing agents. *Curr Med Chem* 2008;**15**:3248-67.