

Rituximab therapy for primary glomerulonephritis: Report on two cases

Fabrizio Fabrizi, Donata Cresseri, Giovanni B Fogazzi, Gabriella Moroni, Patrizia Passerini, Paul Martin, Piergiorgio Messa

Fabrizio Fabrizi, Donata Cresseri, Giovanni B Fogazzi, Gabriella Moroni, Patrizia Passerini, Piergiorgio Messa, Division of Nephrology, Maggiore Hospital, IRCCS Foundation, 20122 Milano, Italy

Paul Martin, Division of Hepatology, School of Medicine, University of Miami, Florida, FL 33124, United States

Author contributions: All authors contributed to this manuscript.

Institutional review board statement: Maggiore Hospital, IRCCS Foundation, Milano, Italy gave the permission to publish the manuscript.

Informed consent statement: All study participants, or their legal guardian, provided informed written consent prior to study enrolment.

Conflict-of-interest statement: The authors declare they have no conflict of interest to report.

Open-Access: This article is an open-access article which was selected by an in-house editor and fully peer-reviewed by external reviewers. It is distributed in accordance with the Creative Commons Attribution Non Commercial (CC BY-NC 4.0) license, which permits others to distribute, remix, adapt, build upon this work non-commercially, and license their derivative works on different terms, provided the original work is properly cited and the use is non-commercial. See: <http://creativecommons.org/licenses/by-nc/4.0/>

Correspondence to: Fabrizio Fabrizi, MD, Division of Nephrology, Maggiore Hospital, IRCCS Foundation, Pad. Croff, via Commenda 15, 20122 Milano, Italy. fabrizi@policlinico.mi.it
Telephone: +39-2-55033525
Fax: +39-2-55033770

Received: September 28, 2014
Peer-review started: September 29, 2014
First decision: December 17, 2014
Revised: January 10, 2015
Accepted: June 18, 2015
Article in press: June 19, 2015
Published online: August 16, 2015

Abstract

The evidence in the medical literature on the efficacy and safety of rituximab therapy for primary glomerulonephritis is limited and controversial. We describe two male Caucasian patients with rapidly progressive kidney failure due to primary proliferative glomerulonephritis. Both of them received high-dose intravenous corticosteroids and oral cyclophosphamide with limited benefit. The first patient (hepatitis C virus-negative mixed cryoglobulinemia) underwent plasma-exchange with intravenous immunoglobulins; he showed significant benefit on kidney function (he became dialysis independent with serum creatinine going back to 1.6 mg/dL) after one rituximab pulse even if urinary abnormalities were still present. No improvement in renal function or urinary changes occurred in the second patient. Both these individuals developed sepsis over the follow-up, the first patient died two months after rituximab therapy. This report is in keeping with the occurrence of severe infections after rituximab therapy in patients with renal impairment at baseline and concomitant high-dose steroids.

Key words: Chronic kidney disease; Cryoglobulinemic vasculitis; Membranoproliferative glomerulonephritis; Rituximab

© **The Author(s) 2015.** Published by Baishideng Publishing Group Inc. All rights reserved.

Core tip: A small but growing body of evidence is emerging on the efficacy and safety of rituximab therapy for primary glomerulonephritis. Various authors have claimed that rituximab for glomerular diseases is effective and has minimal adverse effects. We report on two male Caucasian patients who were refractory to conventional immunosuppressive therapy; each of them received one rituximab pulse and developed sepsis over the follow-up, the first patient died two months after rituximab therapy. The risks (and the predictive

factors) of severe infections in kidney patients on rituximab therapy are unclear and appear an area of active research.

Fabrizi F, Cresseri D, Fogazzi GB, Moroni G, Passerini P, Martin P, Messa P. Rituximab therapy for primary glomerulonephritis: Report on two cases. *World J Clin Cases* 2015; 3(8): 736-742 Available from: URL: <http://www.wjgnet.com/2307-8960/full/v3/i8/736.htm> DOI: <http://dx.doi.org/10.12998/wjcc.v3.i8.736>

INTRODUCTION

Primary glomerulonephritis (GN) remains an important cause of end-stage kidney disease. Preliminary trials have recently shown the efficacy of rituximab for adult-onset primary GN^[1]; rituximab being a genetically chimeric monoclonal antibody directed to CD20 antigen, a B-cell-specific transmembrane found on immature and mature cells, as well as on malignant B cells. Following treatment with rituximab (RTX), B-cells are prevented from proliferating, and undergo apoptosis and lysis through complement-dependent and - independent mechanisms. B-cell depletion usually persists for 6-9 mo in around 80% of patients, but the degree of depletion is greatly variable. Rituximab is currently approved for treating various malignancies including B cell non-Hodgkin's lymphoma and chronic lymphocytic leukemia; also, it has been licensed for refractory rheumatoid arthritis, granulomatosis with polyangiitis (Wegener's granulomatosis) and microscopic polyangiitis. Rituximab was expected to inhibit the production of autoantibodies involved in the pathogenesis of the disease without the toxicity of nonspecific immunosuppression. It has been the first monoclonal employed for the treatment of glomerular diseases and has been initially used for patients with membranous nephropathy but its use has rapidly spread to other glomerular diseases^[1]. Membranous nephropathy and membranoproliferative GN are characterized by glomerular deposition of immune complexes; a crucial role of B cells in membranous (MN) and membranoproliferative glomerulonephritis pathogenesis through autoantibody production and antigen presentation has been mentioned. A small but growing body of literature is emerging on the benefits of rituximab in MN and membranoproliferative glomerulonephritis as primary treatment or as treatment of lesions refractory to other immunomodulatory regimens. In this setting, the drug appears to be well tolerated with small adverse events (Table 1)^[2-8].

We report here our experience on rituximab use in two patients with progressive kidney failure due to primary proliferative GN. Both of them received conventional immunosuppressive therapy with limited benefit on urinary and biochemical abnormalities; then, they underwent one RTX pulse but developed sepsis over the follow-up. A brief review on the safety and efficacy of rituximab for primary GN has been also

added.

CASE REPORT

Patient 1

A 51-year-old Caucasian male patient was admitted to hospital for two-week's duration of abdominal pain with vomiting and diarrhoea. His medical history included arterial hypertension and symptomatic hepatitis C virus (HCV)-negative mixed cryoglobulinemia (since three years) with recurrent purpura and peripheral neuropathy at the lower extremities. Skin biopsy had shown leukocytoclastic vasculitis whereas neurological evaluation had revealed mono-neuritis at the left foot with axonal ischemic damage, probably related to cryoprecipitable immune complexes in the vasa nervorum. He had received low dose oral corticosteroids and azathioprine with partial control of cutaneous and neurological abnormalities. A bone marrow biopsy had reported no evidence of malignant lymphoma, and a small expansion of B lymphocytes (10%-15%).

A physical examination showed bilateral edema and hypertension (180/100 mmHg), purpuric rash with ulcers at the legs (Figure 1); no bowel movements were apparent from the clinical standpoint, this being confirmed by an abdomen X-ray. An ultrasound scan of the abdomen showed normal sized kidneys bilaterally, with normal echotexture. At presentation (Table 1), abnormal laboratory results included serum creatinine level of 2.5 mg/dL, proteinuria, 3.6 g/24 h, and hypoalbuminemia (2 g/L). Other pertinent chemistries were: positive cryoglobulins, with a cryocrit of 3% (polyclonal IgG and monoclonal IgMk), elevated rheumatoid factor (148 IU/mL) and hypocomplementemia. Serology was negative for hepatitis B virus (HBV), HCV and human immuno-deficiency virus (HIV) markers, polymerase chain reaction tested negative for HCV RNA. Repeat urine sediment, analyzed by phase-contrast microscopy, showed severe microscopic hematuria (> 50 erythrocytes/microscopic field), many dysmorphic erythrocytes and casts (ialine, granular and red cell casts). Bence Jones proteinuria (kappa type) was positive. The search for anti-neutrophil cytoplasmic antibody (proteinase 3 and myeloperoxidase), anti-glomerular basement membrane antibody, extractable nuclear antigen antibody, antinuclear and anti-double stranded DNA tested negative.

Renal biopsy was not performed due to anatomic reasons, and a diagnosis of essential MC with rapidly progressive renal failure due to nephritic/nephrotic syndrome was made. Treatment was initiated with intravenous methylprednisolone (600 mg/d for three days), oral prednisone (50 mg/d on taper), and oral cyclophosphamide (100 mg daily). The progressive deterioration of kidney function (serum creatinine raised to 6.3 mg/dL, blood urea nitrogen to 279 mg/L) led us to make sequential plasma-exchange (nine sessions) and high-dose intravenous immunoglobulins (five procedures); in addition, hemodialysis was started. We

Table 1 Blood chemistries at presentation and over follow-up (patient 1)

	Admission	Discharge	Middle follow-up	Final follow-up
Creatinine (0.5-1.2, mg/dL)	2.8	1.59	1.76	0.8
Blood urea nitrogen (8-20, mg/dL)	147	104	86	85
AST (5-32, IU/L)	12	24	27	23
ALT (5-31, IU/L)	9	43	39	7
γGT (5-36, IU/L)	12	44	41	69
Cholinesterasis (5300-12900, IU/L)	3833	2160	2920	3173
Total bilirubin (0.2-1.1, mg/dL)	0.2	0.25	0.22	0.23
Direct bilirubin (0-0.3, mg/dL)	0.09	0.07	0.08	0.16
Total protein (6.6-8.7, g/dL)	3.9	4.6	4.6	4.5
Albumin (3.4-4.8, g/dL)	2.4	3	2.5	3
Prothrombin time (0.88-1.16)	1.08	1.07	1.06	1.08
Partial thromboplastin time (0.85-1.18)	1.01	1	1.03	1.19
C ₃ (90-180)	20	56	59	99
C ₄ (10-40)	0	1	3	2
Cryoglobulins	Present	Absent	Absent	Present
Leucocytes (4.8-10.8, 10 ³ /mmc)	10670	3440	3400	3730
Hemoglobin (12-16, g/dL)	10.8	9.7	10.2	10.5
Platelets (130-400, 10 ³ /mmc)	313000	159000	153000	73000

AST: Aspartate aminotransferase; ALT: Alanine aminotransferase; γGT: Gamma-glutamyl transpeptidase.

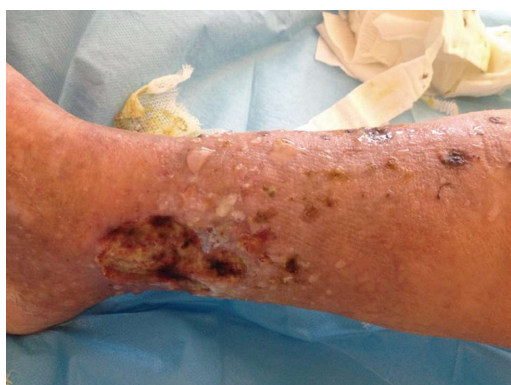

Figure 1 Purpuric rash with ulcers at the leg (patient 1).

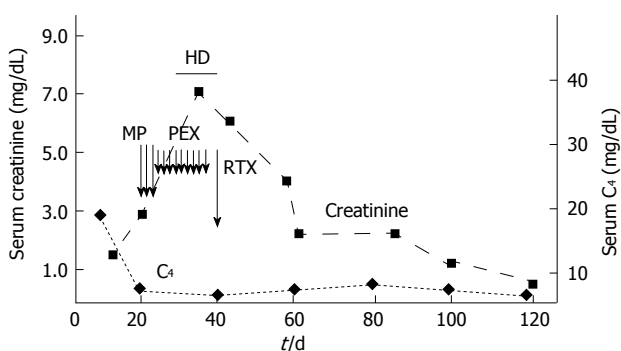


Figure 2 Biochemical/serological response to therapy (patient 1). HD: Haemodialysis; MP: High-dose methylprednisolone; PEX: Plasma-exchange; RTX: Rituximab.

observed healing of skin ulcers and improvement of neuropathic pain; GI disorders disappeared but immunosuppressive therapy was complicated by *Clostridium Difficile*-positive diarrhea, which was successfully treated with oral vancomycin. Due to the persistence of severe renal failure (serum creatinine of 4.2 mg/dL), he received

one infusion of RTX (375 mg/m²) off-label (Figure 2); by day 6 of the RTX dose, an improvement of urine output occurred. Since then, serum creatinine went back to 1.6 mg/dL, and blood urea nitrogen to 104 mg/dL. At discharge from the hospital, his medications included oral steroids, rabeprazole, amlodipine, furosemide, calcium carbonate, gabapentine, and darbepoetin.

Two weeks after hospital discharge, serum creatinine was 1.76 mg/dL, blood urea nitrogen, 86 mg/dL, serum albumin 2.5 g/dL; severe and dysmorphic hematuria and non-nephrotic proteinuria (1.43 g/L) being still present. Low white blood cell count after RTX administration ($3.4 \times 10^3/\text{mmc}$) occurred. According to flow cytometry, CD20⁺ B cells were 19% of total peripheral blood lymphocytes (before RTX) and fell to 1% (after RTX, since day 6) with no increase over the following weeks.

One month later, he became pyrexial with a temperature around 38 °C and was admitted again to the hospital. Pertinent biochemistry included serum creatinine (0.8 mg/dL), cryoglobulins and rheumatoid factor tested positive. Complete blood count gave the following features: white blood cells $2.67 \times 10^3/\text{mmc}$, erythrocytes $3.57 \times 10^6/\text{mmc}$, platelets $209 \times 10^3/\text{mmc}$. Flow cytometry: lymphocytes $169/\text{mm}^3$, CD3⁺ cells 142 (83.9%), CD19⁺ 0 (0%), natural killer cells 25 (14.9%). Gamma globulins were 0.16 g/dL (3.9%, 11%-18.8%). IgA < 4 mg/dL (70-400), IgG 84 mg/dL (700-1600), IgM 108 mg/dL (40-230). Monoclonal component by serum electrophoresis (IgMk + oligoclonal Ig) was again detected. An active urinary sediment with non-nephrotic proteinuria (1.21 g/d) was still present. Sepsis from *Enterococcus Spp.* was identified whereas the chest radiograph reported multiple pneumoniae. The culture of the bronchoalveolar lavage fluid was positive for *Candida albicans*, thus, we initiated intravenous imipenem and antifungal

medications. Medical and supportive therapy was unsuccessful and the patient ultimately expired due to septic shock (two months after RTX pulse).

Patient 2

A 49-year-old Caucasian male underwent kidney biopsy for evaluation of serum creatinine 1.35 mg/dL [estimated glomerular filtration rate (eGFR) 56 mL/min per 1.73 m² by MDRD equation], 3.2 g of proteinuria on 24-h urine collection and active urinary sediment (severe microscopic hematuria with red blood cell casts). Renal biopsy showed global ialinosis in some glomeruli (5 out of 14); the others had intense glomerular hypercellularity (mainly due to mesangial proliferation), a limited number of mesangial immune deposits and segmental thickening of glomerular basement membrane were also present. Final diagnosis was mesangial proliferative GN with immune deposits of unclear significance. Other pertinent chemistries were: negative cryoglobulins, normal rheumatoid factor and complement fractions; serum protein electrophoresis in the normal range. Serology tested negative for HBV, HCV and HIV markers, polymerase chain reaction was negative for HCV RNA. The search for anti-neutrophil cytoplasmic antibody (proteinase 3 and myeloperoxidase), anti-glomerular basement membrane antibody, extractable nuclear antigen antibody, antinuclear and anti-double stranded DNA tested negative. At discharge from the hospital, his medications included oral steroids, rabeprazole, amlodipine, doxazosine, furosemide, calcium carbonate, and darbepoetin. Partial remission of nephritic/nephrotic syndrome with improvement of kidney function (serum creatinine going back to 1.1 mg/dL) was obtained with intravenous methylprednisolone pulses, oral cyclophosphamide, azathioprine, and mycophenolate mofetil in variable associations. Eight years later, he was again admitted to our unit, showing bilateral lower-extremity edema, arterial hypertension and serum creatinine of 2.9 mg/dL (eGFR 23 mL/min per 1.73 m² by MDRD equation). Nephrotic proteinuria was demonstrated (proteinuria of 9.2 g/d) with active urinary sediment. A repeat kidney biopsy revealed intracapillary/extracapillary glomerular proliferation with several crescents and fibrinoid necrosis, diffuse arteriosclerosis, in addition to uniform and diffuse thickening of the glomerular basement membrane. Immunofluorescence demonstrated sporadic and granular deposition of C1q/C3 in the mesangium and capillary walls; fibrinogen in the Bowman space. Renal biopsy was complicated by perirenal hematoma and a few units of red packed cells were given. He received high-dose intravenous diuretic therapy with edema resolution and body weight loss, and intravenous methylprednisolone pulse therapy (500 mg daily intravenous for three alternate days) with low-dose oral steroids was not effective. Thus, one infusion of RTX (375 mg/m²) off-label was administered. One month after rituximab administration he was again hospitalized (acute pulmonary insufficiency with septic shock); serum creatinine of 4.56 mg/dL (eGFR, 11

mL/min per 1.73 m²). Active urinary sediment and nephrotic proteinuria persisted. Pulmonary aspergillosis was documented- medical plus supportive therapy was initiated and the patient recovered in a few weeks; however, he developed irreversible kidney failure and initiated dialysis acutely. He is currently doing well on maintenance hemodialysis (thrice weekly) treatment.

DISCUSSION

We report here on two patients with rapidly progressive renal failure due to idiopathic proliferative GN who were resistant to conventional immunosuppressive therapy. Both the patients underwent rituximab treatment in off-label condition, RTX infusion was well tolerated by both the patients but sepsis developed over the follow-up, fatal course occurring in patient 1. Numerous case reports and case series have suggested that the addition of rituximab to standard chemotherapy for malignant lymphoma increases the risk of viral infections such as varicella zoster^[9], cytomegalovirus^[10], HBV^[11], parvovirus^[12], and enteroviral encephalitis^[13]. The risk of HBV reactivation has been added to the existing Boxed Warning of the rituximab label by the Food and Drug Administration in 2013^[14]. Impaired immunity against non-viral pathogen agents such as *Pneumocystis jirovecii*^[15] or *cryptococcus*^[16] after rituximab therapy has been also noted.

A recent systematic review and meta-analysis has shown that rituximab plus standard chemotherapy for malignant lymphoma increases the incidence of severe leucopenia (RR = 1.24; 95%CI: 1.12-1.37) and granulocytopenia (RR = 1.07; 95%CI: 1.02-1.12) even if the overall risk of severe infections has not been increased (RR = 1.0; 95%CI: 0.87-1.14)^[17]. We have already reported on a case of cholestatic hepatitis C after rituximab therapy for gastric cancer in a renal transplant recipient^[18]. On the other hand, various authors have claimed that rituximab use for glomerular diseases is effective and has minimal adverse effects (Table 2)^[1,19,20].

Our first patient presented idiopathic cryoglobulinemic vasculitis which has undefined therapeutic management^[21]. There is some evidence on the efficacy and tolerance of RTX in patients with HCV-associated mixed cryoglobulinemia vasculitis who were naïve, resistant or intolerant to antiviral therapy^[22-25]. Two randomized controlled trials have compared RTX with conventional immunosuppressive therapy for HCV-related mixed cryoglobulinemia vasculitis^[26,27]. As listed in Table 3, evidence in the medical literature on RTX use among patients with non-infectious cryoglobulinemia vasculitis targeting kidneys is extremely limited, and a total of 16 cases were retrieved^[28-37]. Patient 1 gives emphasis on the efficacy of RTX, as one RTX pulse made possible the control of renal disease: kidney function normalized, nephrotic syndrome disappeared and only nephritic urinary changes persisted. However, RTX use was complicated by sepsis a few weeks after

Table 2 Literature review: Adverse events during rituximab therapy for primary membranous and membranoproliferative glomerulonephritis

Ref.	n	Rituximab treatment dose	Follow-up period	Concomitant therapy	Response to RTX	Side-effects after RTX
Fervenza <i>et al</i> ^[21]	15	1 g × 2, on days 1 and 15	12 mo	ACE-I + ARB	Complete (n = 2) or partial remission (n = 6)	Nonserious transient AE (n = 10) pneumonia (n = 1)
Segarra <i>et al</i> ^[31]	13	375 mg/m ² once weekly × 4	30 mo	Tac (n = 10), CyA (n = 3), CCS (n = 3)	Partial remission (n = 13)	None
Fervenza <i>et al</i> ^[41]	20	375 mg/m ² once weekly × 4	24 mo	ACE-I + ARB	Complete (n = 4) or partial remission (n = 12)	Nonserious transient AE (n = 11) pneumonia (n = 1)
Michel <i>et al</i> ^[51]	28	375 mg/m ² once weekly × 2 or 3 or 4 (n = 27) 1 g × 2, on days 1 and 15 (n = 1)	12 mo	ACE-I + ARB, CCS (n = 1), Tac (n = 1)	Complete (n = 6) or partial remission (n = 13)	Nonserious transient AE (few)
Ruggenenti <i>et al</i> ^[61]	100	375 mg/m ² once weekly × 4	29 mo	CCS	Complete (n = 27) or partial remission (n = 38)	Nonserious transient AE (n = 28)
Dillon <i>et al</i> ^[71]	6	1 g × 2, on days 1 and 15	12 mo	ACE-I + ARB	Complete (n = 2) or partial remission (n = 3)	None
Kong <i>et al</i> ^[81]	13	500 mg × 1 (n = 6) 500 mg × 2 (n = 3) 500 mg × 4 (n = 4)	31.5 mo	CCS (os) (n = 9) CyA (n = 2) CCS (iv) (n = 2)	Remission (n = 19)	Nonserious transient AE (n = 8) Pneumonia (n = 1)

ACE-I: Angiotensin converting enzyme inhibitors; AE: Adverse events; ARB: Angiotensin receptor blockers; CCS: Corticosteroids [by intravenous (iv) or oral (os) route]; CyA: Cyclosporine; MN: Membranous nephropathy; MPGN: Membranoproliferative glomerulonephritis; Tac: Tacrolimus; RTX: Rituximab.

Table 3 Overview of cases with non-viral hepatitis mixed cryoglobulinemia (and kidney involvement) on rituximab

Ref.	n	Age (yr)/gender	Treatment prior to RTX	Features	Response to RTX	Side-effects after RTX
Arzoo <i>et al</i> ^[281]	1	71/F	CS	C, N, R	Remission	None
Ghijssels <i>et al</i> ^[291]	1	44/M	CS, CPH, CHL	C, Ca, R	Remission	None
Koukoulaki <i>et al</i> ^[301]	1	48/F	CS, CPH	GI, P, R	Partial remission	None
Bryce <i>et al</i> ^[311]	1	NA	NA	R	No response	None
Ruch <i>et al</i> ^[321]	1	64/M	CS	R	Remission	Cold agglutinine disease, sepsis
Annear <i>et al</i> ^[331]	1	42/F	CS	C, R	Remission	None
Terrier <i>et al</i> ^[341]	7	73 ± 5/M (n = 4)	CS (n = 4)	C (n = 6), N (n = 2), A (n = 2), R (n = 7)	Remission (n = 3), partial remission (n = 1), NA (n = 3)	Severe infections (n = 4)
Wink <i>et al</i> ^[351]	1	72/F	CS, Aza	C, P, R	Remission	None
Choudhry <i>et al</i> ^[361]	1	61/F	CS, CPH	C, P, R	Remission	None
Kamel <i>et al</i> ^[371]	1	77/F	CS	C, A, R	Remission	None
Own case	1	51/M	CS, Aza	C, GI, N, R	Remission	Severe infection

A: Arthralgias; Aza: Azathioprine; C: Cutaneous; Ca: Cardiac; CHL: Chlorambucil; CPH: Cyclophosphamide; CS: Corticosteroids; GI: Gastrointestinal; N: Neurological; NA: Not available; P: Pulmonary; R: Renal; RTX: Rituximab.

RTX pulse. On the basis of the evidence reported in Table 3, severe infections after RTX treatment are not uncommon [35% (6/17)].

RTX therapy in patients with nonviral cryoglobulinemia vasculitis or membranoproliferative GN raises various questions such as the role of RTX as first-line or rescue therapy, the efficacy/safety of maintenance therapy with RTX, and the tolerance to RTX. In the absence of randomized controlled trials, such questions remain unanswered; as an example, the poor tolerance of our patients after RTX administration remains unclear. The French multicenter CryoVas survey retrospectively evaluated 242 patients with non-infectious mixed cryoglobulinemia vasculitis, RTX plus corticosteroids had greater therapeutic efficacy compared with corticosteroids alone and corticosteroids plus alkylating agents^[38]. However, RTX plus corticosteroids was associated with more frequent infections than corti-

costeroids alone (HR = 9; 95%CI: 3.1-20, *P* < 0.001). Prospective data from the AIR (AutoImmunity and Rituximab) registry, which includes data on patients treated with rituximab off-label, have shown that among patients (n = 23) with nonviral cryoglobulinemia vasculitis on RTX, side-effects occurred in almost half of the patients (n = 11), including severe infections^[34]. Infectious episodes were mostly reported in a patient subgroup (age > 70 years, essential type II MC, GFR < 60 mL/min, and high-dose steroids) and were fatal in many (n = 3)^[34]. Both our patients had important kidney impairment at baseline and concomitant therapy with intravenous high-dose corticosteroids, among other immunosuppressive agents.

The current study calls for further research on the RTX-based treatment of essential cryoglobulinemic vasculitis or membranoproliferative GN but the low frequency of patients in individual centers would make

randomised controlled trials extremely difficult. Rituximab has surfaced as potential treatment option for some primary glomerular diseases and the HCV KDIGO Study Group^[39] had already included rituximab among the recommended drugs (steroids, and cyclophosphamide) for the immunosuppressive treatment of HCV-associated kidney disease. The risks (and the predictive factors) of infections in kidney patients on RTX-therapy are not yet understood and are an area of active research. These patients should be monitored over the follow-up to avoid the occurrence of infectious episodes.

COMMENTS

Case characteristics

Two male Caucasian patients with progressive kidney failure.

Clinical diagnosis

Arterial hypertension, bilateral lower-extremity edema.

Differential diagnosis

Progressive kidney failure due to secondary glomerular disease.

Laboratory diagnosis

At presentation serum creatinine ranged between 2.5 and 2.9 mg/dL and proteinuria 3.6 and 9.2 g/d, microscopic haematuria with dysmorphic erythrocytes and red cell casts.

Imaging diagnosis

Computed tomography scan revealed normal sized kidneys bilaterally with normal echotexture in both the patients.

Pathological diagnosis

Renal biopsy (patient 2) showed intracapillary/extracapillary glomerular proliferation with several crescents and fibrinoid necrosis, in addition to uniform diffuse thickening of the glomerular basement membrane.

Treatment

Both the patients received one infusion of rituximab (375 mg/m²) off-label.

Related reports

Various authors have claimed that rituximab use for glomerular diseases is effective and has minimal adverse effects.

Term explanation

Phase-contrast microscopy is a microscopy technique to analyze the morphology of urine erythrocytes.

Experiences and lessons

The risks and the predictive factors of severe infections in kidney patients on rituximab therapy are still unclear and appear an area of active research.

Peer-review

It is a good article.

REFERENCES

- 1 **Manrique J**, Cravedi P. Role of monoclonal antibodies in the treatment of immune-mediated glomerular diseases. *Nefrologia* 2014; **34**: 388-397 [PMID: 24798567 DOI: 10.3265/Nefrologia.pre2014.Feb.12506]
- 2 **Fervenza FC**, Cosio FG, Erickson SB, Specks U, Herzenberg AM, Dillon JJ, Leung N, Cohen IM, Wochos DN, Bergstralh E, Hladunewich M, Cattran DC. Rituximab treatment of idiopathic membranous nephropathy. *Kidney Int* 2008; **73**: 117-125 [PMID: 17943078 DOI: 10.1038/sj.ki.5002628]
- 3 **Segarra A**, Praga M, Ramos N, Polanco N, Cargol I, Gutierrez-Solis E, Gomez MR, Montoro B, Camps J. Successful treatment of membranous glomerulonephritis with rituximab in calcineurin inhibitor-dependent patients. *Clin J Am Soc Nephrol* 2009; **4**: 1083-1088 [PMID: 19478097 DOI: 10.2215/CJN.06041108]
- 4 **Fervenza FC**, Abraham RS, Erickson SB, Irazabal MV, Eirin A, Specks U, Nachman PH, Bergstralh EJ, Leung N, Cosio FG, Hogan MC, Dillon JJ, Hickson LJ, Li X, Cattran DC. Rituximab therapy in idiopathic membranous nephropathy: a 2-year study. *Clin J Am Soc Nephrol* 2010; **5**: 2188-2198 [PMID: 20705965 DOI: 10.2215/CJN.05080610]
- 5 **Michel PA**, Dahan K, Ancel PY, Plaisier E, Mojaat R, De Seigneux S, Dugas E, Matignon M, Mesnard L, Karras A, François H, Pardon A, Caudwell V, Debiec H, Ronco P. Rituximab treatment for membranous nephropathy: a French clinical and serological retrospective study of 28 patients. *Nephron Extra* 2011; **1**: 251-261 [PMID: 22470399 DOI: 10.1159/000333068]
- 6 **Ruggenti P**, Cravedi P, Chianca A, Perna A, Ruggiero B, Gaspari F, Rambaldi A, Marasà M, Remuzzi G. Rituximab in idiopathic membranous nephropathy. *J Am Soc Nephrol* 2012; **23**: 1416-1425 [PMID: 22822077 DOI: 10.1681/ASN.2012020181]
- 7 **Dillon JJ**, Hladunewich M, Haley WE, Reich HN, Cattran DC, Fervenza FC. Rituximab therapy for Type I membranoproliferative glomerulonephritis. *Clin Nephrol* 2012; **77**: 290-295 [PMID: 22445472 DOI: 10.5414/CN107299]
- 8 **Kong WY**, Swaminathan R, Irish A. Our experience with rituximab therapy for adult-onset primary glomerulonephritis and review of literature. *Int Urol Nephrol* 2013; **45**: 795-802 [PMID: 22798030 DOI: 10.1007/s11255-012-0206-0]
- 9 **Bermúdez A**, Marco F, Conde E, Mazo E, Recio M, Zubizarreta A. Fatal visceral varicella-zoster infection following rituximab and chemotherapy treatment in a patient with follicular lymphoma. *Haematologica* 2000; **85**: 894-895 [PMID: 10942955]
- 10 **Suzan F**, Ammor M, Ribrag V. Fatal reactivation of cytomegalovirus infection after use of rituximab for a post-transplantation lymphoproliferative disorder. *N Engl J Med* 2001; **345**: 1000 [PMID: 11575282 DOI: 10.1056/NEJM200109273451315]
- 11 **Dervite I**, Hober D, Morel P. Acute hepatitis B in a patient with antibodies to hepatitis B surface antigen who was receiving rituximab. *N Engl J Med* 2001; **344**: 68-69 [PMID: 11187122 DOI: 10.1056/NEJM200101043440120]
- 12 **Song KW**, Mollee P, Patterson B, Brien W, Crump M. Pure red cell aplasia due to parvovirus following treatment with CHOP and rituximab for B-cell lymphoma. *Br J Haematol* 2002; **119**: 125-127 [PMID: 12358915]
- 13 **Quartier P**, Tournilhac O, Archimbaud C, Lazaro L, Chaleteix C, Millet P, Peigue-Lafeuille H, Blanche S, Fischer A, Casanova JL, Travade P, Tardieu M. Enteroviral meningoencephalitis after anti-CD20 (rituximab) treatment. *Clin Infect Dis* 2003; **36**: e47-e49 [PMID: 12539090 DOI: 10.1086/345746]
- 14 **US Food and Drug Administration**. FDA Drug Safety Communication: Boxed Warning and new recommendations to decrease risk of hepatitis B reactivation with the immune-suppressing and anti-cancer drugs Arzerra (ofatumumab) and Rituxan (rituximab). Available from: URL: <http://www.fda.gov/drugs/drugsafety/ucm366406.htm>
- 15 **Ennishi D**, Terui Y, Yokoyama M, Mishima Y, Takahashi S, Takeuchi K, Ikeda K, Tanimoto M, Hatake K. Increased incidence of interstitial pneumonia by CHOP combined with rituximab. *Int J Hematol* 2008; **87**: 393-397 [PMID: 18409079 DOI: 10.1007/s12185-008-006-7]
- 16 **Basse G**, Ribes D, Kamar N, Mehrenberger M, Sallusto F, Esposito L, Guitard J, Lavayssièrre L, Oksman F, Durand D, Rostaing L. Rituximab therapy for mixed cryoglobulinemia in seven renal transplant patients. *Transplant Proc* 2006; **38**: 2308-2310 [PMID: 16980074 DOI: 10.1016/j.transproceed.2006.06.131]
- 17 **Lanini S**, Molloy AC, Fine PE, Prentice AG, Ippolito G, Kibbler

- CC. Risk of infection in patients with lymphoma receiving rituximab: systematic review and meta-analysis. *BMC Med* 2011; **9**: 36 [PMID: 21481281 DOI: 10.1186/1741-7015-9-36]
- 18 **Fabrizi F**, Martin P, Elli A, Montagnino G, Banfi G, Passerini P, Campise MR, Tarantino A, Ponticelli C. Hepatitis C virus infection and rituximab therapy after renal transplantation. *Int J Artif Organs* 2007; **30**: 445-449 [PMID: 17551909]
- 19 **Bomback AS**, Derebail VK, McGregor JG, Kshirsagar AV, Falk RJ, Nachman PH. Rituximab therapy for membranous nephropathy: a systematic review. *Clin J Am Soc Nephrol* 2009; **4**: 734-744 [PMID: 19279120 DOI: 10.2215/CJN.05231008]
- 20 **Tanna A**, Tam FW, Pusey CD. B-cell-targeted therapy in adult glomerulonephritis. *Expert Opin Biol Ther* 2013; **13**: 1691-1706 [PMID: 24188581 DOI: 10.1517/14712598.2013.851191]
- 21 **Fabrizi F**, Plaisier E, Saadoun D, Martin P, Messa P, Cacoub P. Hepatitis C virus infection, mixed cryoglobulinemia, and kidney disease. *Am J Kidney Dis* 2013; **61**: 623-637 [PMID: 23102733 DOI: 10.1053/j.ajkd.2012.08.040]
- 22 **Zaja F**, De Vita S, Mazzaro C, Sacco S, Damiani D, De Marchi G, Michelutti A, Bacarani M, Fanin R, Ferraccioli G. Efficacy and safety of rituximab in type II mixed cryoglobulinemia. *Blood* 2003; **101**: 3827-3834 [PMID: 12560225 DOI: 10.1182/blood-2002-09-2856]
- 23 **Sansonno D**, De Re V, Lauletta G, Tucci FA, Boiocchi M, Dammacco F. Monoclonal antibody treatment of mixed cryoglobulinemia resistant to interferon alpha with an anti-CD20. *Blood* 2003; **101**: 3818-3826 [PMID: 12506023 DOI: 10.1182/blood-2002-10-3162]
- 24 **Roccatello D**, Baldovino S, Rossi D, Giachino O, Mansouri M, Naretto C, Di Simone D, Francica S, Cavallo R, Alpa M, Napoli F, Sena LM. Rituximab as a therapeutic tool in severe mixed cryoglobulinemia. *Clin Rev Allergy Immunol* 2008; **34**: 111-117 [PMID: 18270864 DOI: 10.1007/s12016-007-8019-0]
- 25 **Terrier B**, Saadoun D, Sène D, Sellam J, Pérard L, Coppéré B, Karras A, Blanc F, Buchler M, Plaisier E, Ghillani P, Rosenzwaig M, Cacoub P. Efficacy and tolerability of rituximab with or without PEGylated interferon alfa-2b plus ribavirin in severe hepatitis C virus-related vasculitis: a long-term followup study of thirty-two patients. *Arthritis Rheum* 2009; **60**: 2531-2540 [PMID: 19644879 DOI: 10.1002/art.24703]
- 26 **Sneller MC**, Hu Z, Langford CA. A randomized controlled trial of rituximab following failure of antiviral therapy for hepatitis C virus-associated cryoglobulinemic vasculitis. *Arthritis Rheum* 2012; **64**: 835-842 [PMID: 22147444 DOI: 10.1002/art.34322]
- 27 **De Vita S**, Quartuccio L, Isola M, Mazzaro C, Scaini P, Lenzi M, Campanini M, Naclerio C, Tavoni A, Pietrogrande M, Ferri C, Mascia MT, Masolini P, Zabotti A, Maset M, Roccatello D, Zignego AL, Pioltelli P, Gabrielli A, Filippini D, Perrella O, Migliaresi S, Galli M, Bombardieri S, Monti G. A randomized controlled trial of rituximab for the treatment of severe cryoglobulinemic vasculitis. *Arthritis Rheum* 2012; **64**: 843-853 [PMID: 22147661 DOI: 10.1002/art.34331]
- 28 **Arzoo K**, Sadeghi S, Liebman HA. Treatment of refractory antibody mediated autoimmune disorders with an anti-CD20 monoclonal antibody (rituximab). *Ann Rheum Dis* 2002; **61**: 922-924 [PMID: 12228164 DOI: 10.1136/ard.61.10.922]
- 29 **Ghijssels E**, Lerut E, Vanrenterghem Y, Kuypers D. Anti-CD20 monoclonal antibody (rituximab) treatment for hepatitis C-negative therapy-resistant essential mixed cryoglobulinemia with renal and cardiac failure. *Am J Kidney Dis* 2004; **43**: e34-e38 [PMID: 15112197 DOI: 10.1053/j.ajkd.2003.12.057]
- 30 **Koukoulaki M**, Abeygunasekara SC, Smith KG, Jayne DR. Remission of refractory hepatitis C-negative cryoglobulinaemic vasculitis after rituximab and infliximab. *Nephrol Dial Transplant* 2005; **20**: 213-216 [PMID: 15632353 DOI: 10.1093/ndt/gfh564]
- 31 **Bryce AH**, Dispenzieri A, Kyle RA, Lacy MQ, Rajkumar SV, Inwards DJ, Yassenchak CA, Kumar SK, Gertz MA. Response to rituximab in patients with type II cryoglobulinemia. *Clin Lymphoma Myeloma* 2006; **7**: 140-144 [PMID: 17026826 DOI: 10.3186/CLM.2006.n.052]
- 32 **Ruch J**, McMahon B, Ramsey G, Kwaan HC. Catastrophic multiple organ ischemia due to an anti-Pr cold agglutinin developing in a patient with mixed cryoglobulinemia after treatment with rituximab. *Am J Hematol* 2009; **84**: 120-122 [PMID: 19097173 DOI: 10.1002/ajh.21330]
- 33 **Annear NM**, Cook HT, Atkins M, Pusey CD, Salama AD. Non-hepatitis virus associated mixed essential cryoglobulinemia. *Kidney Int* 2010; **77**: 161-164 [PMID: 19890273 DOI: 10.1038/ki.2009.416]
- 34 **Terrier B**, Launay D, Kaplanski G, Hot A, Larroche C, Cathébras P, Combe B, de Jaureguiberry JP, Meyer O, Schaevebeke T, Somogyi A, Tricot L, Zénone T, Ravaut P, Gottenberg JE, Mariette X, Cacoub P. Safety and efficacy of rituximab in nonviral cryoglobulinemia vasculitis: data from the French Autoimmunity and Rituximab registry. *Arthritis Care Res (Hoboken)* 2010; **62**: 1787-1795 [PMID: 20740617 DOI: 10.1002/acr.20318]
- 35 **Wink F**, Houtman PM, Jansen TL. Rituximab in cryoglobulinaemic vasculitis, evidence for its effectivity: a case report and review of literature. *Clin Rheumatol* 2011; **30**: 293-300 [PMID: 21053035 DOI: 10.1007/s10067-010-1612-2]
- 36 **Choudhry M**, Rao N, Juneja R. Successful treatment of cryoglobulinaemia with rituximab. *Case Rep Nephrol Urol* 2012; **2**: 72-77 [PMID: 23197959 DOI: 10.1159/000339400]
- 37 **Kamel M**, Thajudeen B, Bracamonte E, Madhira M. Idiopathic Nonviral Cryoglobulinemia Treated Successfully With Rituximab. *Am J Ther* 2014; Epub ahead of print [PMID: 24914502]
- 38 **Terrier B**, Krastinova E, Marie I, Launay D, Lacraz A, Belenotti P, de Saint-Martin L, Quemeneur T, Huart A, Bonnet F, Le Guenno G, Kahn JE, Hirschberger O, Rullier P, Diot E, Lazaro E, Bridoux F, Zénone T, Carrat F, Hermine O, Léger JM, Mariette X, Senet P, Plaisier E, Cacoub P. Management of noninfectious mixed cryoglobulinemia vasculitis: data from 242 cases included in the CryoVas survey. *Blood* 2012; **119**: 5996-6004 [PMID: 22474249 DOI: 10.1182/blood-2011-12-396028]
- 39 **Kidney Disease: Improving Global Outcomes (KDIGO)**. KDIGO clinical practice guidelines for the prevention, diagnosis, evaluation, and treatment of hepatitis C in chronic kidney disease. *Kidney Int Suppl* 2008; **(109)**: S1-99 [PMID: 18382440 DOI: 10.1038/ki.2008.81]

P- Reviewer: Fujita T S- Editor: Ji FF
L- Editor: A E- Editor: Liu SQ





Published by **Baishideng Publishing Group Inc**

8226 Regency Drive, Pleasanton, CA 94588, USA

Telephone: +1-925-223-8242

Fax: +1-925-223-8243

E-mail: bpgoffice@wjgnet.com

Help Desk: <http://www.wjgnet.com/esps/helpdesk.aspx>

<http://www.wjgnet.com>

