

Analysis of Protrusio Acetabuli Using a CT-based Diagnostic Method in Korean Patients with Marfan Syndrome: Prevalence and Association with Other Manifestations

Kwang Jin Chun,¹ Jeong Hoon Yang,^{1,2}
Shin Yi Jang,¹ Seung Hwa Lee,¹
Hye Bin Gwag,¹ Tae-Young Chung,³
June Huh,⁴ Chang-Seok Ki,⁵ Kiick Sung,⁶
Seung-Hyuk Choi,¹ Sung Mok Kim,⁷
Yeon Hyeon Choe,⁷ and Duk-Kyung Kim¹

¹Division of Cardiology, Department of Medicine, Heart Vascular Stroke Institute, ²Department of Critical Care Medicine, ³Department of Ophthalmology, ⁴Department of Pediatrics, ⁵Department of Laboratory Medicine and Genetics, ⁶Department of Thoracic and Cardiovascular Surgery, ⁷Department of Radiology, Cardiovascular and Stroke Imaging Center, Samsung Medical Center, Sungkyunkwan University School of Medicine, Seoul, Korea

Received: 14 November 2014

Accepted: 13 May 2015

Address for Correspondence:

Duk-Kyung Kim, MD

Division of Cardiology, Department of Medicine, Heart Vascular Stroke Institute, Samsung Medical Center, Sungkyunkwan University School of Medicine, 81 Irwon-ro, Gangnam-gu, Seoul 135-710, Korea

Tel: +82.2-3410-3419, Fax: +82.2-3410-3849

E-mail: dukkyung.kim@gmail.com

Funding: This work was supported by the Samsung Biomedical Research Institute (grant C-A9-204-3).

INTRODUCTION

Marfan syndrome (MFS) is an autosomal dominant connective tissue disorder with cardiovascular, skeletal and ocular manifestations (1). The diagnosis of MFS relies on the revised Ghent nosology, which weights cardiovascular manifestations more heavily and in which aortic root aneurysm and ectopia lentis are the cardinal clinical features (2, 3). In the revised Ghent nosology, the most selective systemic features were included in the systemic score and each element was assigned one, two, or three points based on its importance to diagnosis (2). Protrusio acetabuli (PA) was assigned two points, as was dural ectasia, spontaneous pneumothorax, anterior chest deformity, and hind-foot deformity (2).

PA has various etiologies, including infectious, neoplastic, inflammatory, metabolic, traumatic, and genetic causes (4). There are a few methods to diagnose PA using plain anteroposterior

A new CT-based diagnostic method of protrusio acetabuli (PA) was introduced. However, prevalence of PA by this method and correlation between PA and other manifestations of Marfan syndrome (MFS) is unknown in Korean MFS patients. This study aimed to investigate the prevalence of PA diagnosed by a CT-based method in Korean patients with MFS, the association of PA with other manifestations of MFS, and the contribution of PA to MFS diagnosis. We retrospectively reviewed the records of 146 MFS patients with the presence of a causative *FBN1* mutation and 146 age- and sex-matched controls from a single tertiary care center. All MFS patients underwent a complete assessment of criteria based on the revised Ghent nosology. PA was assessed quantitatively using a CT-based circle-wall distance (CWD) method. PA was diagnosed in 77.4% of patients in the MFS group and in 11.0% of the control group. CWD was significantly different between the two groups (1.50 mm vs. -0.64 mm, $P < 0.001$). The presence of PA did not correlate with the presence of ectopia lentis, aortic root diameter, or history of aortic dissection. The presence of PA did not have a significant impact on the final diagnosis of MFS. Even though the presence of PA does not related to the cardinal clinical features of MFS or influence MFS diagnosis, its presence may be helpful for the suspicion of MFS when aortic dissection or aneurysm is found on CT angiography of the aorta because of the high frequency of PA in MFS patients.

Keywords: Protrusio Acetabuli; Marfan Syndrome; *FBN1* Mutation; Computed Tomography

radiographs of the pelvis. The prevalence of PA, which is different according to the diagnostic method, is 23%-46% in Korean MFS patients and 16%-100% in Western countries (5-9). The three most widely used criteria are the Steel method (using a center-edge angle of Wiberg $> 50^\circ$), the Armbuster method (an acetabular-ilioischial distance of ≥ 3 mm in male patients or ≥ 6 mm in female patients), and crossing of the teardrop figure (Fig. 1) (5, 10, 11). Some consider the Armbuster method the most reliable measurement of PA, but other studies have reported that plain radiographic measurements of PA become unreliable as pelvic tilt increases (11, 12).

In MFS, computed tomography (CT) angiography is commonly performed to investigate the abnormality of aorta. In the axial view, the loss of the normal oval shape of the pelvic inlet at the level of the acetabulum can be easily identified and is considered a sign of PA. A new CT-based diagnostic criterion was recently introduced and the degree of PA could be measured

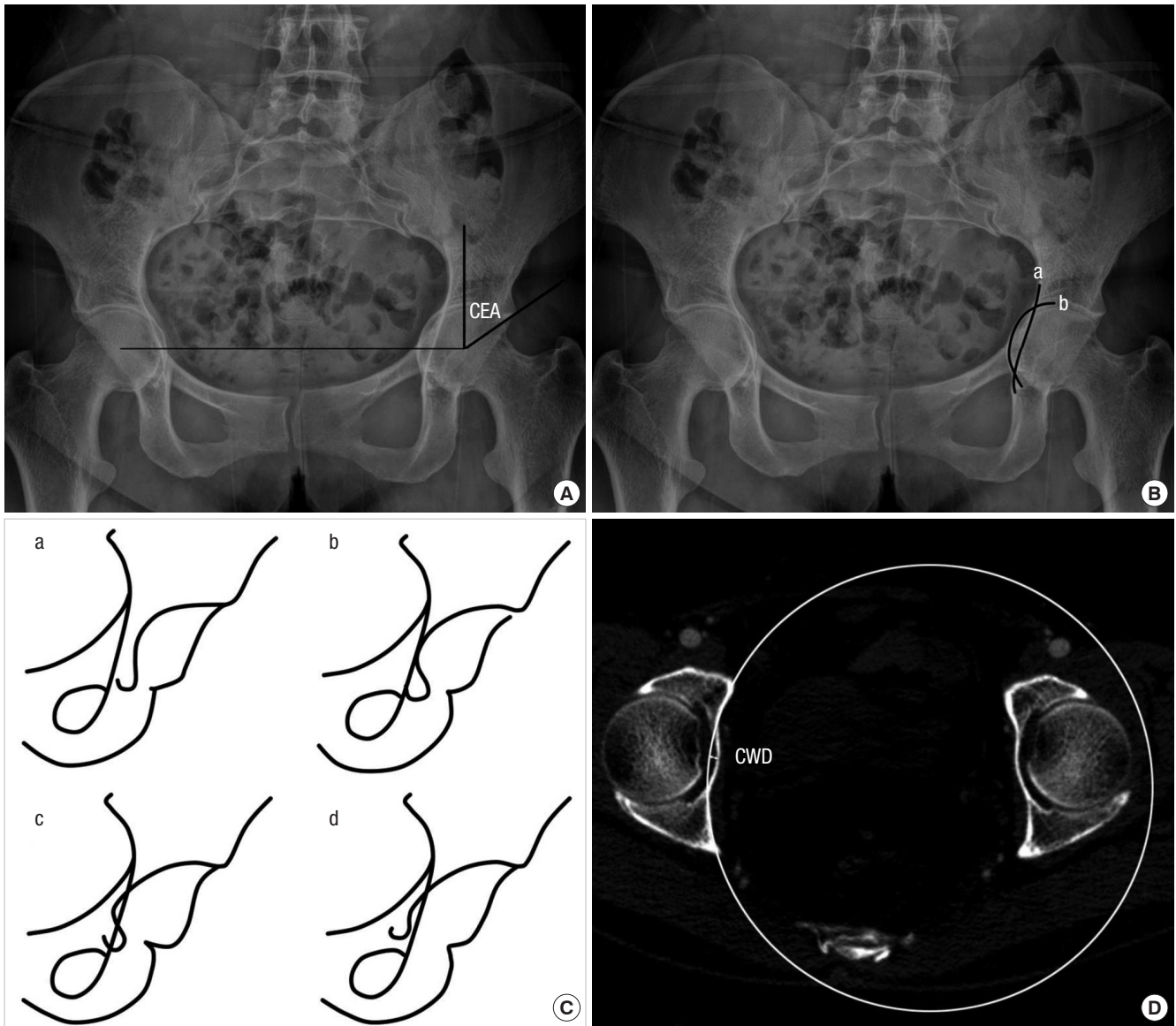


Fig. 1. Diagnostic methods for protrusio acetabuli using plain anteroposterior radiographs of the pelvis and CT images. **(A)** The center-edge angle (CEA) is formed by a vertical line drawn through the center of the femoral head and a line drawn from the center through the lateral edge of the acetabular roof. A CEA of $>50^\circ$ is considered indicative of protrusio acetabuli. **(B)** The acetabular-ilioischial distance represents the transverse distance between the ilioischial line (a) and the acetabular line (b). Crossing of the ilioischial line by the acetabular line by > 3 mm medially in men or > 6 mm in women is considered indicative of protrusio acetabuli. **(C)** Radiographic changes of the teardrop figure in protrusio acetabuli. a, opened; b, closed; c, crossed; d, reversed. **(D)** CT-based circle-wall distance (CWD) method. A 10 cm radius circle is adapted to the inner acetabular wall of the pelvis. The distance between the line of the circle and the medial most point of the inner pelvic wall of the acetabular fossa was measured. Measurement of CWD is indicated. CT, computed tomography.

using this method (13).

Some skeletal manifestations of MFS have been known to be associated with other skeletal manifestations or the severity of aortic root dilatation (14, 15). One study reported that dural ectasia was related to skeletal manifestations and aortic Z-scores (14). However, PA has not been evaluated to correlate with other skeletal manifestations of MFS or aortic root dilatation.

Therefore, we investigated the prevalence of PA using the CT-based diagnostic method in Korean patients with MFS, the association of PA with other manifestations of MFS, and contribution of PA to MFS diagnosis.

MATERIALS AND METHODS

Study population

We reviewed data that was entered into our Marfan database between March 2006 and September 2013. Total 154 patients ≥ 18 yr of age with a *FBNI* mutation were identified. Eight patients who did not undergo CT examination due to renal dysfunction and contrast allergy were excluded. All 146 patients fulfilled MFS diagnostic criteria by the revised Ghent nosology.

Revised Ghent nosology

In the revised Ghent nosology, cardiovascular manifestations are more heavily weighted and aortic root aneurysm and ectopia lentis are the cardinal clinical features. In the absence of any family history, the presence of these two manifestations is sufficient for diagnosis of MFS. In the absence of either of the cardinal clinical features, the presence of a *FBN1* mutation or a combination of systemic score is required (Table 1).

Control population

The control cases were selected from patients who visited the emergency room between July 2007 and December 2013 and underwent abdominal and/or pelvic CT, and were age- and sex-matched to Marfan patients. Control candidates with hip joint problems or any known connective tissue disease were excluded from this study.

CT image

Multidetector computed tomography (MDCT) was performed using a dual-source CT scanner (Definition Flash; Siemens Healthcare, Forchheim, Germany) with $2 \times 64 \times 0.6$ mm collimation, section acquisition of $2 \times 64 \times 0.6$ mm, and z-flying focal spot technique in both the study and control populations. The scanning parameters were 100 kV, 200 mA with automatic tube current modulation (Caredose 4D; Siemens Healthcare), a pitch of 1.0-1.2 and a 0.28-sec tube rotation time.

Measurements and definitions

PA was assessed quantitatively by the CT-based circle-wall dis-

tance (CWD) method (Fig. 1). This method uses axial CT images and was introduced by Lundby et al. (13) in 2011. In this method, PA was quantified by using a circle with a 10 cm radius. The circle was fitted to the inner pelvic wall at the level of the acetabulum where the cranial border of the superior pubic ramus fuses with the anterior column of the acetabulum. This level usually includes the fovea of the femoral head. The circle was best fitted to the concavities of the inner walls of the anterior and posterior columns of the acetabulum. We then measured the distance between the line of the circle and the medial most point of the inner pelvic wall of the acetabular fossa (CWD). A positive distance indicates that this medial most point is medial to the circle. Increasing degrees of PA have increasing positive values of CWD. A cut-off value of 1.25 mm was used for diagnosis of PA via the CWD method (13).

We divided the systemic scores into a skeletal score, which included all skeletal manifestations, and non-skeletal scores which included pneumothorax, skin striae, myopia > 3 diopters, and mitral valve prolapse.

Statistics

Continuous data are expressed as the mean \pm standard deviation or median and interquartile range. Categorical data are expressed as frequency and percentage. To evaluate differences between the study groups, we used the Student's unpaired *t*-test for normally distributed data and the Mann-Whitney test for skewed data. Categorical data was analyzed using the chi-square test or Fisher's exact tests by SPSS software (SPSS for Windows, version 20.0, IBM Corp., Armonk, NY, USA).

Table 1. Diagnostic criteria for Marfan syndrome (MFS) according to the revised Ghent nosology

In the absence of family history (FH)

- (1) Ao ($Z \geq 2$) AND EL = MFS
- (2) Ao ($Z \geq 2$) AND FBN1 = MFS
- (3) Ao ($Z \geq 2$) AND Systemic score (≥ 7 pts) = MFS
- (4) EL AND FBN1 with known Ao = MFS

In the presence of FH

- (5) EL AND FH of MFS (as defined above) = MFS
- (6) Systemic score (≥ 7 pts) AND FH of MFS (as defined above) = MFS
- (7) Ao ($Z \geq 2$ above 20 yr old, ≥ 3 below 20 yr) AND FH of MFS (as defined above) = MFS

Scoring of systemic feature (maximum total 20 points)

- Wrist AND thumb sign - 3 (wrist OR thumb sign - 1)
- Pectus carinatum deformity - 2 (pectus excavatum or chest asymmetry - 1)
- Hind foot deformity - 2 (plain pes planus - 1)
- Pneumothorax - 2
- Dural ectasia - 2
- Protrusio acetabuli - 2
- Reduced US/LS AND increased arm/height AND no severe scoliosis - 1
- Scoliosis or thoracolumbar kyphosis - 1
- Reduced elbow extension - 1
- Facial features (3/5) - 1 (dolichocephaly, enophthalmos, downslanting palpebral fissures, malar hypoplasia, retrognathia)
- Skin striae - 1
- Myopia > 3 diopters - 1
- Mitral valve prolapse (all types) - 1

Ao, aortic diameter at the sinuses of Valsalva above indicated Z-score or aortic root dissection; EL, ectopia lentis; FBN1, fibrillin-1 mutation; US/LS, upper segment/lower segment ratio.

Ethics statement

This study received institutional review board approval (IRB File No. 2015-03-081). Informed consent was waived due to retrospective study.

RESULTS

PA was diagnosed in 77.4% of the MFS group and in 11.0% of controls (Table 2). The median CWD was 1.50 mm (range, -5.90 – 9.40 mm) in MFS group and -0.64 mm (range, -4.00 – 3.20 mm) in controls ($P < 0.001$, Fig. 2).

Clinical characteristics of MFS patients according to presence of PA were summarized in Table 3. Of patients with MFS and PA, 45.1% were male; in patients with MFS but without PA, 84.8% were male ($P < 0.001$). The mean height of patients with PA versus those without PA was 176.4 vs. 181.6 cm ($P = 0.015$), mean weight was 66.1 vs. 74.2 kg ($P = 0.011$), mean body mass index (BMI) was 21.2 vs. 22.4 kg/m² ($P = 0.069$), and median body surface area (BSA) was 1.76 vs. 1.98 m² ($P = 0.005$), respectively. Hence, anthropometric data showed that patients with PA generally had a smaller body habitus. Important diagnostic criteria,

Table 2. Prevalence of protrusio acetabuli in Marfan syndrome and normal controls

Variables	MFS (n = 146)	Controls (n = 146)	P value
No. of hips (persons)	292 (146)	292 (146)	
Age (yr)	39.1 (± 12.2)	39.1 (± 12.2)	0.970
Males, No. (%)	79 (54.1)	79 (54.1)	1.000
Protrusio acetabuli, No. (%)	113 (77.4)	16 (11.0)	< 0.001
CWD (mm)			< 0.001
Median	1.50	-0.64	
(min, max)	(-5.90, 9.40)	(-4.00, 3.20)	
(interquartile range)	(0.65–2.60)	(-1.40–0.63)	

MFS, Marfan syndrome; CWD, circle-wall distance.

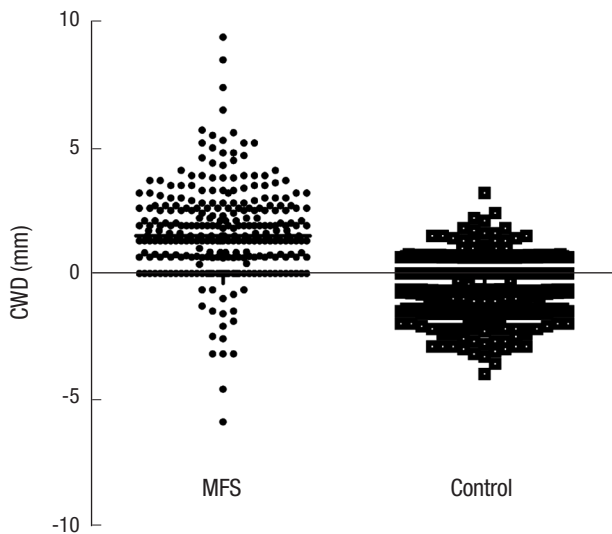


Fig. 2. Scattergram of CWD in patients with MFS and normal controls. CWD, circle-wall distance; MFS, Marfan syndrome.

such as a family history of MFS, ectopia lentis, and aortic root diameter, were not significantly different between the two groups ($P = 0.684$, $P = 0.814$, and $P = 0.062$, respectively). Rates of aortic dissection did not differ between the two groups ($P = 0.333$).

The prevalence of systemic score points ≥ 7 was more common in the PA-positive group than in the PA-negative group (78.8 vs. 60.6%, $P = 0.035$, Table 4). Median systemic score points were

Table 3. Clinical characteristics of patients with vs. without protrusio acetabuli in Marfan syndrome

Variables	Protrusio acetabuli by CWD (n = 146)		
	Yes (n = 113)	No (n = 33)	P value
Male (%)	51 (45.1)	28 (84.8)	< 0.001
Age (yr)	39.2 (± 12.7)	39.0 (± 10.7)	0.933
Height (cm)	176.4 (± 11.1)	181.6 (± 9.1)	0.015
Weight (kg)	66.1 (± 14.0)	74.2 (15.7)	0.011
BMI (kg/m ²)	21.2 (± 3.3)	22.4 (± 3.9)	0.069
BSA (m ²)	1.76 (1.63-1.95)	1.98 (1.75-2.11)	0.005
Proband, No. (%)	70 (61.9)	25 (75.8)	0.143
Family history of Marfan syndrome, No. (%)	78 (69.0)	24 (72.7)	0.684
Ectopia lentis, No. (%)*	58 (52.7)	16 (55.2)	0.814
Aortic root diameter (mm) [†]	42.0 (38.1-53.0)	47.0 (44.0-52.0)	0.062
Z-score of aortic root diameter [†]	4.25 (2.66-7.96)	5.57 (3.82-7.19)	0.211
Previous aortic root surgery, No. (%)	53 (46.9)	22 (66.7)	0.046
Any aortic dissection, No. (%)	25 (22.1)	10 (30.3)	0.333
Type A aortic dissection, No. (%)	17 (15.0)	8 (24.2)	0.217
Type B aortic dissection, No. (%)	8 (7.1)	2 (6.1)	1.000

*7 patients were not assessed for ectopia lentis; [†]22 patients who previously underwent aortic root surgery at an outside hospital could not be assessed for aortic root diameter. CWD, circle-wall distance; BMI, body mass index; BSA, body surface area.

Table 4. Analysis of systemic scores of patients with vs. without protrusio acetabuli in Marfan syndrome

Variables	Protrusio acetabuli by CWD (n = 146)		
	Yes (n = 113)	No (n = 33)	P value
Systemic score ≥ 7 , No. (%)	89 (78.8)	20 (60.6)	0.035
Systemic score (point)	10.0 (7.0-12.0)	7.0 (4.0-8.0)	< 0.001
Skeletal score (point)	8.0 (6.0-10.0)	6.0 (3.5-7.5)	< 0.001
Wrist and/or thumb sign, No. (%)	84 (74.3)	19 (57.6)	0.063
Pectus carinatum or excavatum deformity, No. (%)	12 (10.6)	5 (15.2)	0.538
Hindfoot deformity, No. (%)	68 (60.2)	23 (69.7)	0.321
Dural ectasia, No. (%)	68 (60.2)	20 (60.6)	0.965
Reduced US/LS and increased arm/height ratio, No. (%)	26 (23.0)	5 (15.2)	0.332
Scoliosis or thoracolumbar kyphosis, No. (%)	23 (20.4)	2 (6.1)	0.055
Reduced elbow extension, No. (%)	22 (19.5)	6 (18.2)	0.869
Facial features, No. (%)	81 (71.7)	21 (63.6)	0.376
PA (-) skeletal score (point)	6.0 (4.0-8.0)	6.0 (3.5-7.5)	0.322
Non-skeletal score (point)	1.0 (1.0-2.0)	1.0 (0.5-2.0)	0.493
Pneumothorax, No. (%)	14 (12.4)	3 (9.1)	0.763
Skin striae, No. (%)	74 (65.5)	23 (69.7)	0.652
Myopia > 3 diopters, No. (%)	32 (28.3)	9 (27.3)	0.906
MVP, No. (%)	39 (34.5)	6 (18.2)	0.074

CWD, circle-wall distance; PA, protrusio acetabuli; US/LS, upper segment/lower segment ratio; MVP, mitral valve prolapse.

Table 5. Fulfilled by revised Ghent nosology with or without *FBN1* mutation or protrusio acetabuli

	Not considering PA point	Considering PA point
Fulfilled revised Ghent nosology, No. (%)	145 (99.3)	146 (100.0)
Fulfilled revised Ghent nosology before <i>FBN1</i> mutation was confirmed, No. (%)	141 (96.6)	143 (97.9)

FBN1, fibrillin-1 mutation; PA, protrusio acetabuli.

higher in the PA-positive group (10.0 vs. 7.0 points, $P < 0.001$) and median skeletal score points were also higher in the PA-positive group (8.0 vs. 6.0 points, $P < 0.001$). Because the presence of PA is worth 2 points in the calculation of the systemic score, we compared skeletal score points other than PA points. The median skeletal score points excluding PA did not differ between the two groups (6.0 vs. 6.0 points, $P = 0.322$). We analyzed each element of the skeletal score. There was also no association between PA and the elements comprising the skeletal score. However, scoliosis was numerically but not statistically significantly more frequent in the PA-positive group (20.4 vs. 6.1%, $P = 0.055$). The median non-skeletal score points were not significantly different (1 vs. 1 point, $P = 0.493$). CWD was weakly correlated with skeletal score points ($P < 0.001$, correlation coefficient = 0.391).

Among 146 patients with *FBN1* mutation, only one patient did not fulfill the revised Ghent nosology if the two points attributable to PA were not included (Table 5). In real world clinical practice, genetic diagnosis of *FBN1* mutation takes several weeks or months. Therefore, if we assume that we do not know the *FBN1* mutation status, three patients would not have met the revised Ghent nosology. If both *FBN1* mutation and presence of PA were not included, five patients did not meet the diagnostic criteria for MFS.

DISCUSSION

In the revised Ghent nosology, two points are assigned to the presence of PA in systemic score criteria (2). There are various methods for diagnosing PA, usually using plain anteroposterior radiographs of the pelvis. Of this, the Steel and Armbuster methods were representative. The Steel method uses the center-edge angle of Wiberg, and the Armbuster method uses the acetabular-ilioischial distance. In one study, the prevalence of PA in patients with MFS differed depending on the method used, with 27% of patients considered to have PA using the Steel method and 16% using the Armbuster method (9). Other studies have reported that CT or magnetic resonance imaging (MRI) are going to be more reliable (11, 12).

In patients with MFS, CT is commonly used to evaluate dilatation, aneurysm, or dissection of the aorta. In PA, a loss of the normal oval shape of the pelvic inlet at the level of the acetabulum is typically noted on axial CT images. Lundby et al. (13) recently introduced a new method to diagnose PA using axial CT

images. They measured the distance between the line of the imaginary 10 cm radius circle and the medial most point of the inner pelvic wall of the acetabular fossa. In their study, the exact prevalence of PA by the CWD method was not reported, but was calculated to be 74.7% in Ghent nosology positive patients and 3.7% in controls (13). In our study, the prevalence of PA using the CWD method was similar in the MFS group and more frequent in controls compared to Lundby's study. PA developed more frequently in females and patients with a smaller body habitus.

The CWD method uses a circle with a 10 cm radius to quantify and cut-off value for diagnosis of PA was 1.25 mm. Some study reported that there might be racial and ethnic differences in clinical manifestations between Asian and Western MFS patients (16, 17). Akutsu et al. (16) reported that major skeletal criteria were less frequent in the Japanese population than the Western population, especially arm span to height ratio > 1.05 , scoliosis, reduced extension at elbows, and joint hypermobility. Yoo et al. (17) reported that Korean MFS patients less frequently fulfilled major skeletal criteria than Western MFS patients. Therefore, further study is needed to investigate the prevalence of PA between Asian and Western MFS patients, and establish appropriate cut-off value when using the CWD method for diagnosis of PA in Korean MFS patients. However, the absence of a gold standard for PA diagnosis prevents the establishment of an appropriate cut-off value.

MFS has multiple manifestations that may be related to each other. Indeed, PA was known to associate with scoliosis (15). Sheikhzadeh et al. (14) reported that dural ectasia, which adds two points to the systemic score like PA, correlates with aortic Z-scores and skeletal involvement. In our study, aortic root diameter, aortic Z-scores, family history of MFS, and ectopia lentis was not significantly different between the PA-positive and PA-negative groups. Furthermore, PA was neither associated with a history of aortic dissection nor a particular type of aortic dissection. Patients with PA had higher total systemic and skeletal scores than those without PA, but this difference was lost when PA was not included in systemic and skeletal scores. Considering each element of the skeletal score, there was no relationship between each element of the skeletal score and PA, except the higher tendency for scoliosis observed in the MFS group. In the study of Sheikhzadeh et al. (14), they included dural ectasia points in their skeletal score calculation. Therefore, if dural ectasia was not considered in their skeletal score calculation, it might be possible that there was no association between dural ectasia and skeletal score. An other study reported that no association between aortic dilatation and dural ectasia (18).

CT angiography is useful in the diagnosis of other manifestations of MFS in addition to cardiovascular findings. We can evaluate the presence of pectus carinatum or excavatum, scoliosis or thoracolumbar kyphosis, apical blebs, and dural ectasia as

well as the presence of PA. Sohn et al. (7) reported that 24% of the study population could be diagnosed with MFS using only CT images. Among our 146 patients, only one patient would not fit criteria for MFS if we excluded the presence of PA. Even though PA does not greatly impact MFS diagnosis, the presence of PA may be helpful for the suspicion of MFS when aortic dissection or aneurysm is found on CT angiography of the aorta.

Our study has several limitations. First, the symptoms and signs of PA were missing in our study. Because of retrospective design of the study, we could not assess how many MFS patients with PA had the symptoms. Second, our MFS patients were unlikely to represent individuals from the general population. Our hospital is a major hospital in Korea, and most patients were referred from other hospitals for surgery for aortic root dilatation or dissection. Accordingly, most of our MFS patients satisfy the aortic Z-score or aortic root dissection criteria, which are essential for the diagnosis of MFS under the revised Ghent nosology. Third, our study did not include patients less than 18 yr of age, because they usually do not undergo CT due to concerns regarding radiation exposure.

In conclusion, even though the presence of PA does not related to the cardinal clinical features of MFS or influence MFS diagnosis, its presence may be helpful for the suspicion of MFS when aortic dissection or aneurysm is found on CT angiography of the aorta because of the high frequency of PA in MFS patients.

AUTHOR CONTRIBUTION

Conception and design of this study: Chun KJ, Choi SH, Kim DK. Data collection: all authors. Analysis and interpretation of data: Chun KJ, Choi SH, Kim DK. Manuscript preparation: Chun KJ, Kim DK. Manuscript approval: all authors.

ORCID

Kwang Jin Chun <http://orcid.org/0000-0001-7683-1343>
 Shin Yi Jang <http://orcid.org/0000-0003-4319-7029>
 Seung-Hyuk Choi <http://orcid.org/0000-0002-0304-6317>
 Duk-Kyung Kim <http://orcid.org/0000-0001-9227-4196>

REFERENCES

- Koh KK, Hyon MS, Lim HJ, Kim CH, Oh BH, Park YB, Choi YS, Seo JD, Lee YW. *Cardiovascular manifestations of marfan syndrome. Korean Circ J* 1987; 17: 777-82.
- Loeys BL, Dietz HC, Braverman AC, Callewaert BL, De Backer J, Devereux RB, Hillhorst-Hofstee Y, Jondeau G, Faivre L, Milewicz DM, et al. *The revised Ghent nosology for the Marfan syndrome. J Med Genet* 2010; 47: 476-85.
- De Paepe A, Devereux RB, Dietz HC, Hennekam RC, Pyeritz RE. *Revised diagnostic criteria for the Marfan syndrome. Am J Med Genet* 1996; 62: 417-26.
- McBride MT, Muldoon MP, Santore RF, Trousdale RT, Wenger DR. *Protrusio acetabuli: diagnosis and treatment. J Am Acad Orthop Surg* 2001; 9: 79-88.
- Steel HH. *Protrusio acetabuli: its occurrence in the completely expressed Marfan syndrome and its musculoskeletal component and a procedure to arrest the course of protrusion in the growing pelvis. J Pediatr Orthop* 1996; 16: 704-18.
- Do T, Giampietro PF, Burke SW, Davis JG, Raggio C, Schneider R, Boachie-Adjei O, Brill P. *The incidence of protrusio acetabuli in Marfan's syndrome and its relationship to bone mineral density. J Pediatr Orthop* 2000; 20: 718-21.
- Sohn GH, Jang SY, Moon JR, Yang JH, Sung K, Ki CS, Oh JK, Choe YH, Kim DK. *The usefulness of multidetector computed tomographic angiography for the diagnosis of Marfan syndrome by Ghent criteria. Int J Cardiovasc Imaging* 2011; 27: 679-88.
- Yang JH, Han H, Jang SY, Moon JR, Sung K, Chung TY, Lee HJ, Ki CS, Kim DK. *A comparison of the Ghent and revised Ghent nosologies for the diagnosis of Marfan syndrome in an adult Korean population. Am J Med Genet A* 2012; 158A: 989-95.
- Sponseller PD, Jones KB, Ahn NU, Erkula G, Foran JR, Dietz HC 3rd. *Protrusio acetabuli in Marfan syndrome: age-related prevalence and associated hip function. J Bone Joint Surg Am* 2006; 88: 486-95.
- Armbruster TG, Guerra J Jr, Resnick D, Goergen TG, Feingold ML, Niwayama G, Danzig LA. *The adult hip: an anatomic study. Part I: the bony landmarks. Radiology* 1978; 128: 1-10.
- Van de Velde S, Fillman R, Yandow S. *Protrusio acetabuli in Marfan syndrome. History, diagnosis, and treatment. J Bone Joint Surg Am* 2006; 88: 639-46.
- Richards PJ, Pattison JM, Belcher J, Decann RW, Anderson S, Wynn-Jones C. *A new tilt on pelvic radiographs: a pilot study. Skeletal Radiol* 2009; 38: 113-22.
- Lundby R, Kirkhus E, Rand-Hendriksen S, Hald J, Pripp AH, Smith HJ. *CT of the hips in the investigation of protrusio acetabuli in Marfan syndrome. A case control study. Eur Radiol* 2011; 21: 1485-91.
- Sheikhzadeh S, Sondermann C, Rybczynski M, Habermann CR, Brockstaedt L, Keyser B, Kaemmerer H, Mir T, Staebler A, Robinson PN, et al. *Comprehensive analysis of dural ectasia in 150 patients with a causative FBN1 mutation. Clin Genet* 2014; 86: 238-45.
- Wenger DR, Dittkoff TJ, Herring JA, Mauldin DM. *Protrusio acetabuli in Marfan's syndrome. Clin Orthop Relat Res* 1980; 147: 134-8.
- Akutsu K, Morisaki H, Takeshita S, Ogino H, Higashi M, Okajima T, Yoshimuta T, Tsutsumi Y, Nonogi H, Morisaki T. *Characteristics in phenotypic manifestations of genetically proved Marfan syndrome in a Japanese population. Am J Cardiol* 2009; 103: 1146-8.
- Yoo EH, Woo H, Ki CS, Lee HJ, Kim DK, Kang IS, Park P, Sung K, Lee CS, Chung TY, et al. *Clinical and genetic analysis of Korean patients with Marfan syndrome: possible ethnic differences in clinical manifestation. Clin Genet* 2010; 77: 177-82.
- Fattori R, Nienaber CA, Descovich B, Ambrosetto P, Reggiani LB, Pepe G, Kaufmann U, Negrini E, von Kodolitsch Y, Gensini GF. *Importance of dural ectasia in phenotypic assessment of Marfan's syndrome. Lancet* 1999; 354: 910-3.