

RESEARCH

Open Access



T1 ρ MRI of healthy and fibrotic human livers at 1.5 T

Anup Singh^{1,2*}, Damodar Reddy¹, Mohammad Haris^{1,3}, Kejia Cai^{1,4}, K. Rajender Reddy⁵, Hari Hariharan¹ and Ravinder Reddy¹

Abstract

Background: Liver fibrosis is a public health problem worldwide. There is a need of noninvasive imaging based methods for better diagnosis of this disease. In the current study, we aim to evaluate the potential of T1 ρ MRI technique in detecting and characterizing different grades of liver fibrosis in vivo in humans.

Methods: Healthy subjects and patients with liver fibrosis were prospectively recruited for T1 ρ MRI of liver on a 1.5 T MR scanner. Single slice T1 ρ weighted images were acquired at different spin lock duration (0, 10, 20 and 30 ms) with spin lock amplitude of 500 Hz in a single breath-hold. Additionally, liver's T1 ρ images were acquired from five healthy subjects on the same day (n = 2) and different day (n = 2) sessions for test-retest study. Liver biopsy samples from patients were obtained and used to calculate the METAVIR score to define the stage of fibrosis and inflammation grade. T1 ρ maps were generated followed by computation of mean and standard deviation (SD) values. Coefficient of variation (COV) of T1 ρ values between two MRI scans was computed to determine reproducibility in liver. *T* test was used to compare T1 ρ values between healthy and fibrotic liver. Pearson correlation was performed between stages of liver fibrosis and T1 ρ values.

Results: The mean (SD) T1 ρ value among subject with healthy liver was 51.04 (3.06) ms. The COV of T1 ρ values between two repetitions in the same day session was $0.83 \pm 0.8\%$ and in different day session was $5.4 \pm 2.7\%$. T1 ρ values in fibrotic liver were significantly higher compared to those of healthy liver ($p < 0.05$). A statically significant correlation between stages of fibrosis and T1 ρ values was observed ($r = 0.99$, $p < 0.05$). Inflammation score for one patient was 2 and for remaining patients it was 1.

Conclusions: Proposed T1 ρ pulse sequence design and protocol enabled acquisition of a single slice T1 ρ weighted images in a single breath-hold and hence mitigated breathing motion related artifacts. Preliminary results have shown the sensitivity of T1 ρ values to changes induced by liver fibrosis, and may potentially be used as a clinical biomarker to delineate the stages of liver fibrosis. Further, studies on a large number of subjects are required to validate the observations of the current study. Nevertheless, T1 ρ imaging can be easily setup on a clinical scanner to monitor the progression of liver fibrosis and to the evaluate efficacy of anti-fibrotic drugs.

Keywords: MRI, Spin lock, T1 ρ , Liver fibrosis

Background

Liver cirrhosis and liver cancer are significant health problems worldwide. Liver fibrosis, which is due to damage/insults by toxic metabolites and viral infections [1], leads to cirrhosis. Chronic hepatitis C, chronic hepatitis

B, alcoholic liver disease (ALD) and nonalcoholic fatty liver disease (NALD) are the most common causes of fibrosis progression.

Liver fibrosis is the deposition of excess and abnormal extracellular matrix (ECM), known as scar, in the liver in response to a variety of chronic liver injuries [1]. These matrix proteins include collagens, fibronectin, and proteoglycans. The severity of fibrosis is categorized based on the organization of matrix deposition in the liver.

*Correspondence: anups.minhas@gmail.com; anupsm@iitd.ac.in

² Center for Biomedical Engineering, Indian Institute of Technology Delhi, Block-II, Room No. 389, Hauz Khas, Delhi 110016, India

Full list of author information is available at the end of the article

Cirrhosis, for example, refers to the end-stage of fibrosis in which parenchymal nodules are surrounded by scar tissue. Assignment to a specific stage has prognostic value and is important in the management of individual patients as well as in trials of potential anti-fibrotic agents. Inflammation is another condition that occurs in response to liver injury. Detection of early fibrosis offers multiple benefits and also aids in assessing disease severity and treatment response. When identified early, liver fibrosis is treatable, even at the stage of cirrhosis by using antiviral agents for hepatitis C and B and also taking steps to limit alcohol consumption, overweight and reducing the incidence of type-2 diabetes mellitus.

Liver biopsy is considered as the gold standard for diagnosis of fibrosis. Biopsies, however, carry a risk of significant morbidity and mortality [2]. Moreover, biopsies are plagued with poor reproducibility and may misclassify up to one-third of cirrhotic livers [3]. The limitations of biopsies have proven to be significant practical and financial barriers in clinical care and clinical trials. Existing non-invasive diagnostic tests include a variety of serum tests and transient elastography [Fibroscan and magnetic resonance elastography (MRE)] [4–6]. Among imaging methods, MRE have shown some potential in diagnosis and staging of liver fibrosis. However, MRE requires additional hardware and software, consequently limiting their availability in most clinical settings. Double contrast MRI using gadolinium chelates and super paramagnetic iron oxides (SPIOs) was suggested to visualize liver fibrosis directly based on the hepatic texture alterations [7, 8]. Other MR-based techniques including diffusion-weighted imaging, MR spectroscopy and magnetization transfer (MT) imaging had also shown limited sensitivity, especially in the early and middle stages of fibrosis [6, 9–11]. Spin–lattice relaxation time (T1) and spin–spin relaxation time (T2) MRI mapping have been used to study liver fibrosis. However, the clinical utility of these techniques for staging liver fibrosis has yet to be established. Research and clinical studies are being carried out to evaluate the potential of these techniques for better diagnosis as well as clinical feasibility.

Spin lock relaxation time constant in rotating frame (T1 ρ) MRI technique is another potential technique, which can be used for studying liver fibrosis. This technique has been mainly used for investigating changes during knee osteoarthritis [12, 13], myocardial infarction [14], Alzheimer disease [15]. Recent preclinical study [16] on rat liver have shown the potential of T1 ρ MRI in staging liver fibrosis. Increase in T1 ρ values with increase in the stage of fibrosis has been reported [16]. The exact mechanism behind T1 ρ changes in the liver is not very clear. As such, excessive accumulation of ECM should reduce T1 ρ values; however, increase in T1 ρ values

suggests that other factors like inflammation and change in exchange rate as well as correlation times might dominate T1 ρ contrast in liver fibrosis. A few T1 ρ MRI studies of human liver have been carried in clinical scanners [17–19]. These preliminary studies have also shown that fibrotic liver exhibits higher T1 ρ values compared to normal liver. However, these clinical studies have investigated only late stage fibrosis patients. More T1 ρ MRI studies are required, with different stage of fibrosis, for evaluating the true potential of this technique in the staging of fibrosis. In addition, a T1 ρ MRI pulse sequence which enables T1 ρ mapping data with reduced breathing artifacts is required. As such, in Allkemper et al.'s study respiratory triggering was used, however, it is difficult to control small motion displacement between different times of spin lock (TSLs) data. In other reported liver studies, poor breath holding or respiration induced displacement between different TSLs could be a substantial source of error [20]. Acquisition of entire T1 ρ map data with different TSLs, corresponding to a single slice, in a single breath-hold can mitigate motion problems due to breathing.

In the current study, we have evaluated the potential of T1 ρ MRI technique in the diagnosis of human patients with liver fibrosis. We implemented a spin locked MRI pulse sequence for T1 ρ mapping of human liver in vivo on a 1.5 T clinical scanner and evaluated the feasibility of proton T1 ρ relaxation mapping in detecting and quantifying changes due to liver fibrosis. Proposed pulse sequence enables acquisition of single 2D slice T1 ρ MRI data with different TSLs in a single breath-hold. T1 ρ values of patients were compared with histological staging and inflammation score of the liver in patients.

Methods

Fourteen subjects, seven healthy (age = 27–65 years old) and seven patients (age = 40–70 years old) with liver fibrosis underwent MRI on 1.5 T clinical scanners (Siemens Medical Systems, Malvern, PA, USA). All the liver patients were diagnosed with chronic hepatitis C. The study protocol was approved by the Institutional Review Board of the institute and all subjects provided written informed consent. Subjects were positioned in the bore of the magnet, headfirst supine, with the body array coil placed superiorly and the vendor-supplied spine array coil located inferiorly. All the subjects were instructed to provide a gap of around 3 h between meal and MRI scan.

To minimize breathing related motion artifacts, MRI data were acquired during breath-hold. A gap of around 20 s was provided before starting next MRI acquisition. Imaging started with a tri-plane localizer followed by regular clinical anatomical imaging sequences, including T1- and T2-weighted imaging. For T1 ρ imaging, an axial slice

in the center of the liver was selected guided by anatomical T2 weighted images. T1 ρ pulse sequence consisted of two parts: spin-lock pulse cluster and segmented turbo-flash readout with a spoiler for each part. T1 ρ pulse clusters consist of 90°(+x) – SL(+y) – 180°(+y) – SL(–y) – 90°(–x) pulse [21], where SL represents spin lock. This is an optimized version of basic T1 ρ pulse clusters [22] to account for B₀ inhomogeneity. The SL pulse consists of spin lock amplitude, B_{1sl} ($= \gamma B_1 / 2\pi = \omega_1 / 2\pi$) and spin lock duration (TSL). Parameter γ represent Gyromagnetic ratio, ω_1 represents frequency. In order to retain maximum T1 ρ weighting and minimizing the T₁ recovery, centric encoding was implemented.

T1 ρ imaging protocol T1 ρ imaging was performed with spin lock duration (TSL) = 0, 10, 20, 30 ms, spin lock pulse amplitude B_{1sl} = 500 Hz, TR/TE = 5.1/2.4 ms, flip angle = 10°, FOV = 300 × 300 mm², matrix size = 128 × 128, slice thickness = 10 mm, number of shots = 1. The delay between successive T1 ρ clusters was set to 2.5 s. The data corresponding to a single slice and four TSLs were acquired during one breath-hold period (scan time = ~12 s).

Before acquiring final data from subjects, the T1 ρ imaging protocol was optimized in term of scan time and numbers of TSLs. Maximum TSL was limited by the scanner. Reproducibility studies were also performed on five healthy subjects. Two data sets in the same day MRI session (5 min gap) and different day MRI session were acquired for testing reproducibility of T1 ρ mapping.

Liver Histology The biopsy specimens from each patient were obtained and fixed in a formalin solution and embedded in paraffin. Immunohistochemistry was performed to calculate the METAVIR score. Following METAVIR score [23] were used by Pathologists for staging liver fibrosis (F): 0 = no scarring; 1 = minimal scarring; 2 = scarring has occurred and is inside the areas of the liver including, blood vessels; 3 = bridging fibrosis (the fibrosis is spreading and connecting to other areas that contain fibrosis); 4 = cirrhosis or advanced scarring of the liver. Additionally, following grades, based upon METAVIR scoring [24], were used for determining inflammation activity (A) in liver biopsy specimens: 0 = no; 1 = mild; 2 = moderate; 3 = sever inflammation.

Image Processing and Data Analysis Liver tissue was manually segmented on T1 ρ -weighted MRI image corresponding to TSL = 30 ms. The choice of T1 ρ W image corresponding to longest TSL was based upon the observation that areas with any B₀/B₁ inhomogeneity artifacts are better visible on T1 ρ W image corresponding to long TSL. Therefore, areas corresponding to these B₀/B₁ inhomogeneity artifacts can be easily avoided. Moreover, longest TSL in the current study was only 30 ms, so SNR was fairly good for segmentation. The T1 ρ -weighted

(T1 ρ -W) data signal (S(TSL)) corresponding to four TSLs were fitted voxel-wise to mono-exponential decay expression, $S(TSL) = S(0) * \exp(-TSL/T1\rho)$, for computing T1 ρ values using an in-house written code in MATLAB (2007b). Coefficient of determination (R²) was used to determine quality of exponential function fit and voxels with R² less than 0.8 were excluded from T1 ρ map of liver. Mean and standard deviation (SD) of T1 ρ values were computed for a single region of interest (ROI) on liver tissue, excluding any visible blood vessel voxels, from all the data. The size and location of ROI on T1 ρ map was kept similar across all the subjects. T1 ρ color maps of manually segmented liver sections were overlaid on baseline gray scale images (TSL = 0). Coefficient of variation (COV) for repeatability test was determined as ratio of SD to mean value of two measurements for each subject's data. COV was calculated for the same ROI as mentioned above. Final COV was reported as average value of COVs for five subjects.

Student's T-test was performed to compare T1 ρ values between healthy and fibrotic livers. For studying correlation between T1 ρ values vs stage of fibrosis, subject's data were divided into four groups based upon the stage of fibrosis on the basis of histological information on patients. All healthy volunteer's data were considered into group-0, subjects with stage-1 fibrosis in group-1, subjects with stage-2 in group-2 and subjects with stage-3 or 4 in group-3. Bar plots of liver T1 ρ values were plotted against different groups. Correlation between T1 ρ values of fibrotic liver and stage of fibrosis was computed. Relationship between T1 ρ values of fibrotic liver and inflammation score was also studied.

Results

Average T1 ρ value along with inter subject SD in healthy liver was 51.04 ± 3.06 ms. T1 ρ -W (TSL = 30 ms) image and T1 ρ map from healthy liver are shown in Fig. 1. Average T1 ρ values in ROI marked on liver in Fig. 1a is 55.6 ms. T1 ρ values in voxels containing large blood vessels were set to zero based on poor R² (<0.8) value. B₀ and B₁ field inhomogeneity artifacts appeared on T1 ρ weighted images of some subjects, particularly on the edges close to heart. Usually these voxels exhibited poor fit and were excluded from the main analysis. While some of the voxels containing blood vessels can still be visualized as high T1 ρ values compared to normal liver tissue and these might interfere with interpretation of results. To avoid this problem ROIs were carefully drawn in liver tissue, excluding any visible blood vessel voxel. The COV of T1 ρ values between two repetitions in the same day session was 0.83 ± 0.8 % and in different day session was 5.4 ± 2.7 %.

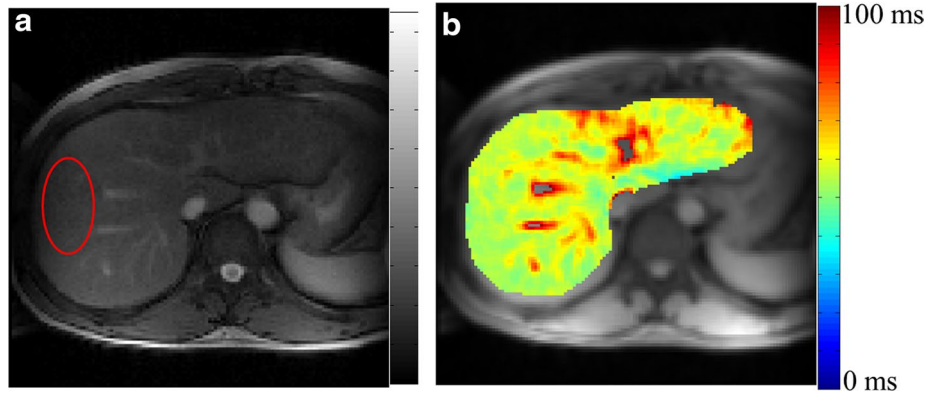


Fig. 1 T1 ρ MRI weighted image corresponding to TSL = 30 ms (a) and map (b) of healthy human liver. T1 ρ map of segmented liver is color overlaid on anatomical image. T1 ρ value in ROI marked on weighted image (a) is 55.6 ± 2.3 ms

In the current study, following fibrosis scores were observed: 0 for one patient; 1 for two patients; 2 for three patients; 3 for one patient and 4 for one patient. For healthy subject data fibrosis score were not available. In the current study, we assumed fibrosis score of zero for healthy subjects data. An inflammation score of 2 for one patient and 1 for remaining patients was observed.

T1 ρ maps of another healthy subject (Fig. 2a) and patients with different fibrosis stage-1, 2, 3 and 4 are shown in Fig. 2. All of the patients had a same inflammation score (score = 1). Elevated T1 ρ values in fibrotic livers are observed compared to the healthy liver. T1 ρ maps of healthy subject, stage-1 and stage-2 (Fig. 2a–c) are homogeneous compared to stage-3 and 4 (Fig. 2d, e), excluding blood vessels. White arrow points to the areas having possible field inhomogeneity artifacts.

Bar plot of T1 ρ values corresponding to different groups (fibrosis grades) is shown in Fig. 3. T1 ρ values were 51.0 ± 3.0 , 59.2 ± 2.5 , 64.2 ± 4.5 and 69.9 ± 5.4 ms in healthy, stage-1, stage-2 and stage-3 and 4 respectively. T1 ρ values in fibrotic liver were significantly ($p < 0.05$) higher compared to a healthy liver. Inter subject variations of T1 ρ values are reflected by error bars. A high correlation (coefficient of correlation = 0.99) between T1 ρ and fibrosis staging was observed. T1 ρ values (mean \pm SD) for all the patients along with fibrosis score and inflammation grades are shown in Table 1.

Figure 4 show T1 ρ map of patient, having stage-0 fibrosis and inflammation grade equal to 1, based upon METAVIR scale. For this subject elevated T1 ρ values were observed all across the liver compared to healthy subject's liver. In fact T1 ρ value for this subject was higher compared to average values in group-3 also. However, the overall T1 ρ map of liver, except blood vessels, was homogeneous. During analysis, in stage-0 we have included all the healthy subjects and this subject's data was excluded from analysis.

Discussion

In the current study, the feasibility of single slice T1 ρ mapping of liver in a single breath-hold was demonstrated on 1.5 T clinical scanner and preliminary data from healthy and fibrotic human liver is presented along with histological results from fibrotic livers. Preliminary results from current studies have shown the potential of differentiating between healthy and fibrotic livers. These results are in agreements with recently reported T1 ρ studies in liver [17, 18]. Previous reported studies have included data only from late stage fibrosis and healthy subjects. In the current study, data from healthy as well as fibrotic liver corresponding to different stage of fibrosis have been included. Preliminary results from current studies have also shown a high correlation between the stage of fibrosis and T1 ρ values. However, the number of subjects in different stages of fibrosis were small and therefore further studies on more subjects need to be performed for conforming the current observations. In the current study, inflammation score for all patients was equal to 1 except for one subject it was 2. For healthy subjects, it was assumed to be equal to 0. Increase in fluid level should increase T1 ρ values and which was also reflected by higher T1 ρ values in the patients data compared to healthy liver. However, this change in inflammation score is poorly correlated with an increase in fibrosis. This might be due to the fact that during liver fibrosis, other mechanisms such as change in ECM also take place.

Breathing induced motions, which could result in erroneous T1 ρ mapping, were avoided by collecting T1 ρ data corresponding to multiple TSLs in a single breath-hold period. Design and protocol of T1 ρ pulse sequence used in the current study enabled collection of entire T1 ρ data, required for generation of T1 ρ map, in a single breath-hold period of ~ 12 s. T1 ρ data corresponding to multiple slices can be collected in a similar manner during

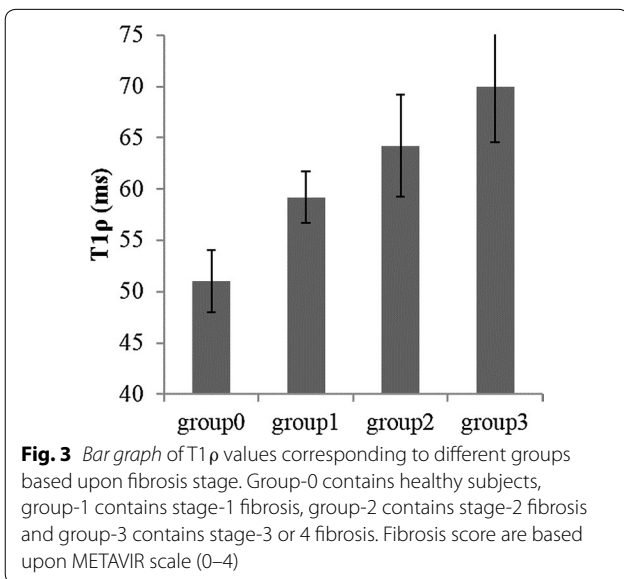
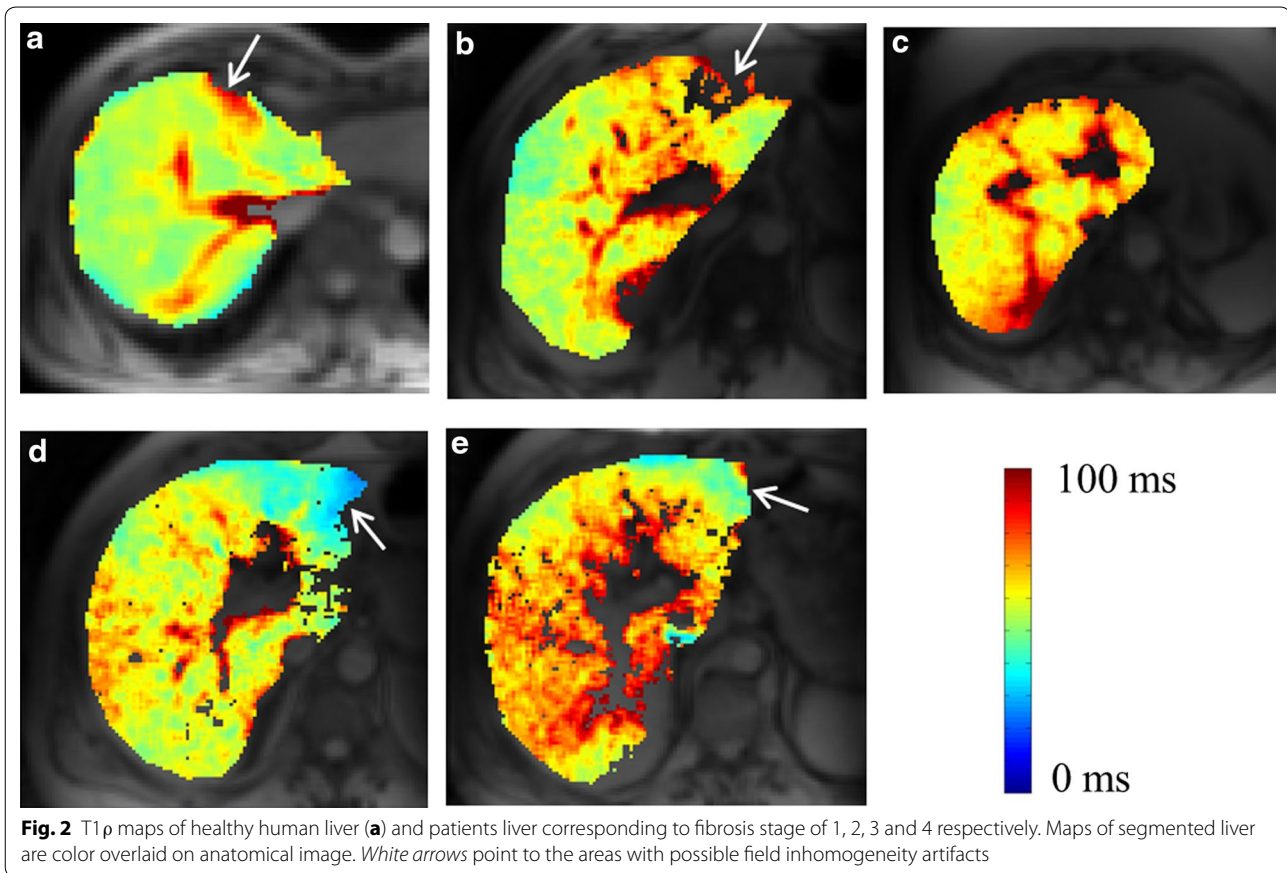


Table 1 T1ρ values (mean ± SD) for all the patients along with fibrosis score and inflammation grades based upon METAVIR score

Patient number	Fibrosis score	Inflammation grade	T1ρ (ms)
1	0	1	73.0 ± 3.7
2	1	1	57.4 ± 3.2
3	1	1	61.0 ± 3.5
4	2	2	60.7 ± 3.7
5	2	1	67.7 ± 5.4
6	3	1	66.1 ± 5.0
7	4	1	73.8 ± 6.4

steatohepatitis, affect the liver in a relatively uniform way [25]. In the current study, all the patients were diagnosed with chronic hepatitis C. Therefore, the results of the current study should not be affected by choice of mismatch between biopsy location and imaging slice or a single ROI results. Therefore, results from a single slice of liver should be sufficient for the initial demonstration purpose. Moreover, it is feasible to apply the same approach to acquire data from multiple slices. In fact, we did collect T1ρ data corresponding to multiple slices (n = 8)

different breath-hold periods. In the current study, we have presented data corresponding to single slice. In most cases of chronic liver diseases causing fibrosis, such as viral and autoimmune hepatitis, as well as

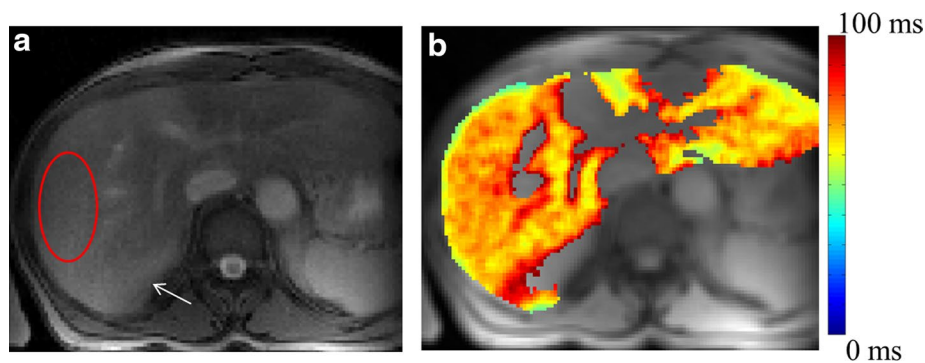


Fig. 4 T1 ρ weighted image corresponding to TSL = 30 ms (a) and map (b) of patient liver having stage-0 fibrosis and inflammation grade equal to 1. T1 ρ map of segmented liver is color overlaid on anatomical image. T1 ρ values in ROI marked on weighted image (a) is 73 ± 9 ms. White arrow points to liver tissue with partial volume to kidney

for some subjects. This data was collected in multiple s, a single slice data (4 T1 ρ W images) per breath hold was collected. Since multiple slice data was not collected for all the subjects, we have not included the results of multi-slice T1 ρ mapping in the current study.

Another, challenge in liver imaging is extensive vasculature of the liver parenchyma. Computation of T1 ρ values in voxels containing vasculature is erroneous due to flow as well as the use of short TSLs. The majority of voxels in or containing large blood vasculature were removed based upon R² values; however, voxels containing small vasculature were present in final T1 ρ maps. T1 ρ values in these voxels are not reliable and therefore these voxels should not be considered in the final analysis. To avoid this problem, we have presented T1 ρ values from a small ROI excluding voxels with any visible vasculature.

T1 ρ values were reproducible as demonstrated by small COV values for T1 ρ in two different time experiments. Moreover, variations (SD) of ~ 3 ms (which is $\sim 6\%$ of mean value) were observed among healthy subjects average T1 ρ values.

In the current study, we have used Pearson correlation coefficient for assessing correlation between T1 ρ values and fibrosis score. Reported preliminary studies on T1 ρ in liver have shown higher T1 ρ values for fibrotic liver. For simplicity we have assumed a linear increase and that is the reason for use of Pearson correlation. As such, T1 ρ values for stage-4 (74 ms) are higher compared to stage-3 (66 ms); however, due to only one subject for each of these two stages we have combined results of stage-3 and 4.

In the current study, we have scanned subjects over a wide age range. Aging results change in liver at both structural and functional level [26]. However, recently published study [17] have shown no relevant correlation between T1 ρ values and age in liver.

Segmented turbo-flash readout has an advantage in terms of reduction in SAR deposition and fast imaging. However, flash readout can reduce T1 ρ contrast, due to T₁ recovery. In order to preserve maximum true T1 ρ contrast, we used a centric encoding scheme in the current study and acquired only 128 lines during a single shot. This number was chosen based upon temporal resolution and T1 ρ contrast preservation.

Depending on the tissue under consideration, correction of B₀ and B₁ field inhomogeneities and a proper combination of B1sl amplitude and SL duration is required for accurate computation of T1 ρ map. Liver tissues have high field inhomogeneities, and automatic or interactive shimming does not work well in liver tissue. In recent years, significant attempts have been made in T1 ρ technique implementation to minimize B₁ and B₀ inhomogeneities [21, 22]. Inclusion of a 180° pulse in T1 ρ pulse cluster elevates SAR, although it minimizes the artifacts that can arise from B₀ field inhomogeneities. In spite of use of this B₀ and B₁ field inhomogeneity compensation pulse cluster, some artifacts were observed in the voxels on liver particularly close to the lung. For reducing SAR accumulation, low SAR readout option has been used in the current study. There may be small errors associated with T1 ρ estimation as we have used TSLs of only up to 30 ms.

Conclusions

In conclusion, T1 ρ mapping of human liver is feasible within SAR limits on 1.5 T clinical scanner. Proposed T1 ρ pulse sequence design and protocol enabled the acquisition of entire T1 ρ data of a single slice, corresponding to 4 TSLs, in a single breath-hold period and hence mitigated breathing motion related artifacts. Preliminary T1 ρ MRI results suggest the potential of using T1 ρ values in the diagnosis of liver fibrosis. Data acquisition from

a large pool of patients, with different stages of fibrosis, is required before making any final conclusions on the potential use of T1 ρ MRI for diagnosis and staging of liver fibrosis.

Authors' contributions

AS provided conception, designed and performed experiments, analyzed data and wrote the manuscript; DR, MH and KC helped in experiments, interpretation of results and edited manuscript; RR helped in data acquisition, interpretation of results, provided clinical support and edited manuscript; HH provided pulse sequence design and technical guidance and edited manuscript; and RR provided conception and overall experimental design and contributed to manuscript writing and editing. All authors read and approved the final manuscript.

Author details

¹ Department of Radiology, CMROI, University of Pennsylvania, Philadelphia, PA, USA. ² Center for Biomedical Engineering, Indian Institute of Technology Delhi, Block-II, Room No. 389, Hauz Khas, Delhi 110016, India. ³ Research Branch, Sidra Medical and Research Center, Doha, Qatar. ⁴ Department of Radiology, University of Illinois at Chicago, Chicago, IL, USA. ⁵ Division of Gastroenterology, Department of Medicine, University of Pennsylvania, Philadelphia, PA, USA.

Acknowledgements

The authors thank Dr Emma Furth and Dr Rebecca Wells for liver biopsy study and Mr. Ben Handler for help in data processing.

Funding

This project was performed at NIH-NCRR supported Biomedical Technology Research Center (P41-RR02305) and partly supported by NIH Grant R01DK058123.

Compliance with ethical guidelines

Competing interests

The authors declare that they have no competing of interests to declare.

Received: 13 June 2015 Accepted: 21 August 2015

Published online: 08 September 2015

References

- Bataller R, Brenner DA. Liver fibrosis. *J Clin Invest*. 2005;115:209–18.
- Thampanitchawong P, Piratvisuth T. Liver biopsy: complications and risk factors. *World J Gastroenterol*. 1999;5:301–4.
- Wells RG. Antifibrotic and HepatoProtectant therapies-hot prospect and challenges to clinical testing. 2008 AASLD Postgraduate Course.
- Verveer C, de Kneegt RJ. Non-invasive measurement of liver fibrosis: application of the FibroScan in hepatology. *Scand J Gastroenterol*. 2006;41:85–8.
- Huwart L, Peeters F, Sinkus R, Annet L, Salameh N, ter Beek LC, Horsmans Y, Van Beers BE. Liver fibrosis: non-invasive assessment with MR elastography. *NMR Biomed*. 2006;19:173–9.
- Faria SC, Ganesan K, Mwangi I, Shiehmorteza M, Viamonte B, Mazhar S, Peterson M, Kono Y, Santillan C, Casola G, Sirlin CB. MR imaging of liver fibrosis: current state of the art. *Radiographics*. 2009;29:1615–35.
- Aguirre DA, Behling CA, Alpert E, Hassanein TI, Sirlin CB. Liver fibrosis: noninvasive diagnosis with double contrast material-enhanced MR imaging. *Radiology*. 2006;239:425–37.
- Hughes-Cassidy F, Chavez AD, Schlang A, Hassanein T, Gamst A, Wolfson T, Sirlin C. Superparamagnetic iron oxides and low molecular weight gadolinium chelates are synergistic for direct visualization of advanced liver fibrosis. *J Magn Reson Imaging*. 2007;26:728–37.
- Razek AA, Abdalla A, Omran E, Fathy A, Zalata K. Diagnosis and quantification of hepatic fibrosis in children with diffusion weighted MR imaging. *Eur J Radiol*. 2009;78:129–34.
- Chen JH, Yeung HN, Lee SK, Chai JW. Evaluation of liver diseases via MTC and contrast agent. *J Magn Reson Imaging*. 1999;9:257–65.
- Qayyum A. MR spectroscopy of the liver: principles and clinical applications. *Radiographics*. 2009;29:1653–64.
- Singh A, Haris M, Cai K, Kogan F, Hariharan H, Reddy R. High resolution T1rho mapping of in vivo human knee cartilage at 7T. *PLoS One*. 2014;9:e97486.
- Regatte RR, Akella SV, Lonner JH, Kneeland JB, Reddy R. T1rho relaxation mapping in human osteoarthritis (OA) cartilage: comparison of T1rho with T2. *J Magn Reson Imaging*. 2006;23:547–53.
- Witschey WR, Pilla JJ, Ferrari G, Koomalsingh K, Haris M, Hinmon R, Zsido G, Gorman JH 3rd, Gorman RC, Reddy R. Rotating frame spin lattice relaxation in a swine model of chronic, left ventricular myocardial infarction. *Magn Reson Med*. 2010;64:1453–60.
- Haris M, McArdle E, Fenty M, Singh A, Davatzikos C, Trojanowski JQ, Melhem ER, Clark CM, Borthakur A. Early marker for Alzheimer's disease: hippocampus T1rho (T(1rho)) estimation. *J Magn Reson Imaging*. 2009;29:1008–12.
- Wang YX, Yuan J, Chu ES, Go MY, Huang H, Ahuja AT, Sung JJ, Yu J. T1rho MR imaging is sensitive to evaluate liver fibrosis: an experimental study in a rat biliary duct ligation model. *Radiology*. 2011;259:712–9.
- Allkemper T, Sagmeister F, Cicinnati V, Beckebaum S, Kooijman H, Kanthak C, Stehling C, Heindel W. Evaluation of fibrotic liver disease with whole-liver T1rho MR imaging: a feasibility study at 1.5 T. *Radiology*. 2013;271:408–15.
- Rauscher I, Eiber M, Ganter C, Martirosian P, Safi W, Umgelter A, Rummeny EJ, Holzappel K. Evaluation of T1rho as a potential MR biomarker for liver cirrhosis: comparison of healthy control subjects and patients with liver cirrhosis. *Eur J Radiol*. 2014;83:900–4.
- Deng M, Zhao F, Yuan J, Ahuja AT, Wang YX. Liver T1rho MRI measurement in healthy human subjects at 3 T: a preliminary study with a two-dimensional fast-field echo sequence. *Br J Radiol*. 2014;85:e590–5.
- Wang YX, Yuan J. Evaluation of liver fibrosis with T1rho MR imaging. *Quant Imaging Med Surg*. 2014;4:152–5.
- Witschey WR 2nd, Borthakur A, Elliott MA, Mellon E, Niyogi S, Wallman DJ, Wang C, Reddy R. Artifacts in T1 rho-weighted imaging: compensation for B(1) and B(0) field imperfections. *J Magn Reson*. 2007;186:75–85.
- Charagundla SR, Borthakur A, Leigh JS, Reddy R. Artifacts in T(1rho)-weighted imaging: correction with a self-compensating spin-locking pulse. *J Magn Reson*. 2003;162:113–21.
- Intraobserver and interobserver variations in liver biopsy interpretation in patients with chronic hepatitis C. The French METAVIR Cooperative Study Group. *Hepatology*. 1994; 20:15–20.
- Bedossa P, Poynard T. An algorithm for the grading of activity in chronic hepatitis C. The METAVIR Cooperative Study Group. *Hepatology*. 1996;24:289–93.
- Germani G, Hytiroglou P, Fotiadu A, Burroughs AK, Dhillon AP. Assessment of fibrosis and cirrhosis in liver biopsies: an update. *Semin Liver Dis*. 2011;31:82–90.
- Schmucker DL. Age-related changes in liver structure and function: implications for disease? *Exp Gerontol*. 2005;40:650–9.

Submit your next manuscript to BioMed Central and take full advantage of:

- Convenient online submission
- Thorough peer review
- No space constraints or color figure charges
- Immediate publication on acceptance
- Inclusion in PubMed, CAS, Scopus and Google Scholar
- Research which is freely available for redistribution

Submit your manuscript at
www.biomedcentral.com/submit

