

**Sir,
 Intravitreal aflibercept for choroidal neovascularisation
 in angioid streaks**

Choroidal neovascularisation (CNV) is a well-known complication of angioid streaks (AS). It affects 42–86% of patients and if untreated can result in significant vision loss.¹ Treatment options have included laser photocoagulation and photodynamic therapy;^{1,2} with the advent of anti-vascular endothelial growth factor (VEGF) therapies, off-label anti-VEGF has become the treatment of choice and both bevacizumab and

ranibizumab have been shown to be effective.^{1–3} We describe the off-label use of 2 mg intravitreal aflibercept in two patients as primary treatment for AS-associated CNV (AS-CNV).

Case report

The first is a 57-year-old woman with recent left eye (OS) distortion. Visual acuities (VA) were 20/20 right and 20/25 left. Fundoscopy showed bilateral AS and a classic CNV OS (Figures 1a and b). Fluorescein angiography (FA) and

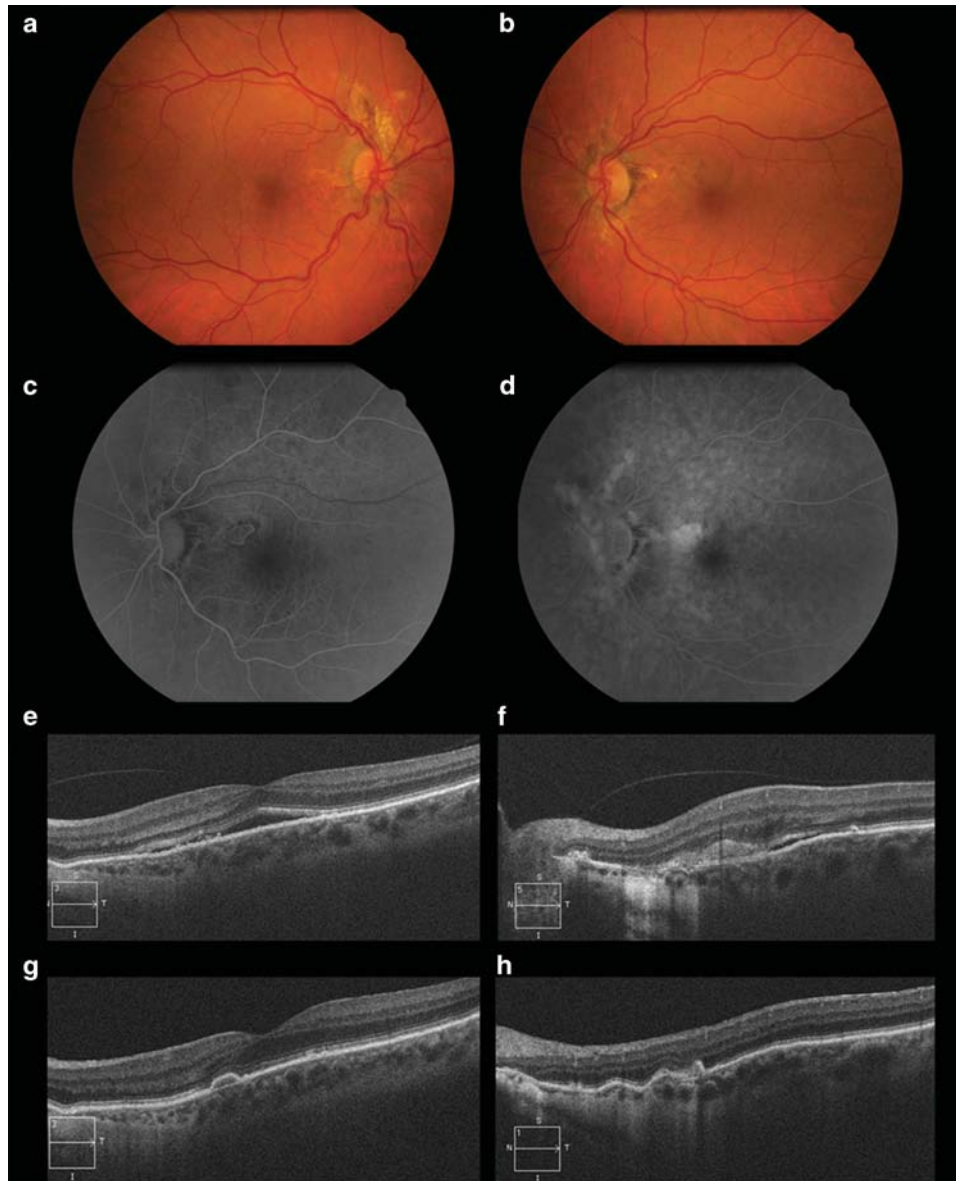

Figure 1 Colour fundus photographs of the first patient, whose sister was known to be affected by AS and pseudoxanthoma elasticum, show bilateral AS, OD (a) and OS (b), along with an extrafoveal greyish area of CNV, with associated subretinal haemorrhages in OS. Early-phase fundus fluorescein angiography demonstrates a well-demarcated lesion (c) with late leakage (d) in OS, compatible with a classic CNV. Spectral-domain optical coherence tomography reveals a neurosensory detachment involving the fovea (e) and a hyperreflective lesion with subretinal fluid above the retinal pigment epithelium in the cross-section through the lesion. After treatment, there was resolution of the foveal subretinal fluid (f) with scarring of the CNV (g).

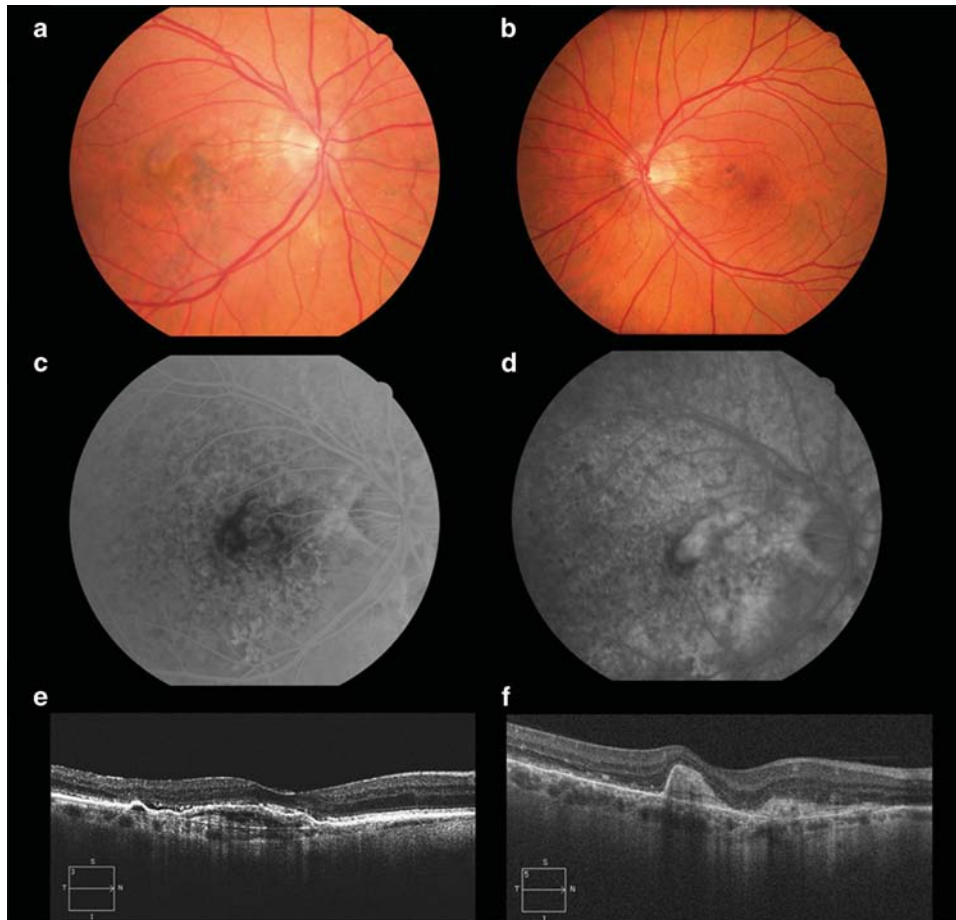


Figure 2 Colour fundus photographs show bilateral angioid streaks, OD (a) and OS (b) and a justafoveal choroidal neovascular membrane in OD (a). Fundus fluorescein angiography shows an early well-demarcated lesion (c) with late leakage (d) corresponding to a predominantly classic choroidal neovascularisation. Spectral-domain optical coherence tomography reveals a subfoveal pigment epithelium detachment with associated subretinal fluid (e) at baseline and resolution of the fluid and subretinal fibrosis after treatment (f). Diagnostic work-up to rule-out systemic associations was negative.

spectral-domain optical coherence tomography (SD-OCT) confirmed the diagnosis (Figures 1c–f) and she was started on a pro re nata (PRN) off-label aflibercept regimen. VA was 20/20 after a single injection and at 12-months follow-up there were no signs of recurrence (Figures 1g and h).

The second case relates to a 56-year-old male presenting with right eye (OD) reduced vision and known OS amblyopia. VA was 20/200 OD and 20/40 OS. Fundoscopy, SD-OCT and FA revealed bilateral AS (Figures 2a and b) and a predominantly classic CNV OD (Figures 2a and c–e). He was started on a 3+PRN off-label aflibercept regimen. VA increased to 20/50 after the loading dose and at 9 months follow-up there was no need for further intervention (Figure 2f).

Comment

The advent of anti-VEGF agents to treat age-related macular degeneration has encouraged the use of these therapies for CNV of other causes.³ To the best of our knowledge this is the first report to describe the clinical benefit of aflibercept for AS-CNV. Moreover, as the one of the major difficulties in treating CNV secondary to AS is recurrence,² it may be that

aflibercept offers an additional benefit over other anti-VEGF agents as it has a higher affinity for VEGF-A as well as the ability to bind VEGF-B and placental growth factor, resulting in a more effective inhibition of the pathological angiogenic process.^{4,5} Further longitudinal studies with a larger cohort of patients are required to verify this hypothesis.

Conflict of interest

Dr Vaz-Pereira has received consultant fees from Bayer and Novartis and has received travel grants from Bayer, Novartis, Alcon, Allergan and Alimera Sciences. Dr Collaço has received travel grants from Bayer. Dr De Salvo has received travel grants from Bayer and Heidelberg Engineering. Dr van Zeller declares no conflict of interest.

References

- Mimoun G, Tilleul J, Leys A, Coscas G, Soubrane G, Souied EH. Intravitreal ranibizumab for choroidal neovascularization in angioid streaks. *Am J Ophthalmol* 2010; **150**: 692–700.e1.

- 2 Sawa M, Gomi F, Tsujikawa M, Sakaguchi H, Tano Y. Long-term results of intravitreal bevacizumab injection for choroidal neovascularization secondary to angioid streaks. *Am J Ophthalmol* 2009; **148**: 584–590.e2.
- 3 Heier JS, Brown D, Ciulla T, Abraham P, Bankert JM, Chong S *et al.* Ranibizumab for choroidal neovascularization secondary to causes other than age-related macular degeneration: a phase I clinical trial. *Ophthalmology* 2011; **118**: 111–118.
- 4 Stewart MW, Rosenfeld PJ. Predicted biological activity of intravitreal VEGF Trap. *Br J Ophthalmol* 2008; **92**: 667–668.
- 5 Papadopoulos N, Martin J, Ruan Q, Rafique A, Rosconi MP, Shi E *et al.* Binding and neutralization of vascular endothelial growth factor (VEGF) and related ligands by VEGF Trap, ranibizumab and bevacizumab. *Angiogenesis* 2012; **15**: 171–185.

S Vaz-Pereira^{1,2,3}, L Collaço¹, G De Salvo⁴ and P van Zeller¹

¹Department of Ophthalmology, Clínica São João de Deus, Lisbon, Portugal

²Department of Ophthalmology, Hospital de Santa Maria, Lisbon, Portugal

³Department of Ophthalmology, Faculty of Medicine, University of Lisbon, Lisbon, Portugal

⁴Eye Unit, University Hospital Southampton NHS Foundation Trust, Southampton, UK
E-mail: saravazpereira@gmail.com

Eye (2015) **29**, 1236–1238; doi:10.1038/eye.2015.92;
published online 29 May 2015

Sir,
Factors influencing the outcome of polypoidal choroidal vasculopathy following combined treatment with photodynamic therapy and intravitreal ranibizumab

We read with interest the article by Ho *et al*¹ describing the factors influencing the treatment outcomes for polypoidal choroidal vasculopathy (PCV) following combination photodynamic therapy and intravitreal ranibizumab injections. This study highlights the key role of indocyanine green angiography (ICGA) in the diagnosis and management of PCV.^{2–4}

In addition to the clinical and angiographic features described, it is also important to consider insights from studies that classified PCV into various subtypes. It has been suggested that PCV may not be a single disease entity, but may consist of different subtypes that influence the long-term prognosis. In a study of 107 consecutive patients with PCV, three subtypes of PCV were identified on the basis of the features seen on ICGA and fluorescein angiography.² The PCV subtype significantly affected the visual outcome at 5 years. In our series, 21.5% of patients experienced ≥ 0.3 LogMAR unit decrease in visual acuity at 1 year. However, the rates of visual loss differed significantly among the three subtypes: 0% for type A PCV, 8.7% for type B, and 35.3% for type C ($P = 0.001$).² A similar pattern was observed over the subsequent 5 years.

In the first paragraph of the discussion, the authors reported ‘81% rate in polyp eradication at 1 year’.¹ However, this term is also used in the abstract, where it is stated that ‘20.2% (15/74) cases achieved polyp eradication on angiogram’, whereas 60.8% ‘achieved polyp size reduction’.¹ Thus, the statement in the discussion may be misleading to some readers, who may infer ‘eradication’ to mean total closure of the polyps, which actually occurred in only 20.2% of cases. We are curious to know how the authors determined a decrease in size of the polyps. Was this based on the total area of all polyps and, if so, what was the minimum decrease in area required? Polyp closure is an important consideration in the management of PCV because some patients may suffer massive hemorrhages, with severe loss of vision.⁵

In summary, we congratulate the authors on describing the risk factors for PCV outcomes, which highlights the need to consider various categories and subtypes of this disease.

Conflict of interest

CST receives travel support from Bayer, Heidelberg Engineering, and Novartis. He also receives research support from the National Healthcare Group Clinician Scientist Career Scheme Grant (CSCS/12005). THL receives travel support from Novartis and Heidelberg Engineering. The remaining authors declare no conflict of interest.

References

- 1 Ho M, Lo EC, Young AL, Liu DT. Outcome of polypoidal choroidal vasculopathy at 1 year by combined therapy of photodynamic therapy with ranibizumab and predictive factors governing the outcome. *Eye (Lond)* 2014; **28**: 1469–1476.
- 2 Tan CS, Ngo WK, Lim LW, Lim TH. A novel classification of the vascular patterns of polypoidal choroidal vasculopathy and its relation to clinical outcomes. *Br J Ophthalmol* 2014; **98**: 1528–1533.
- 3 Lim TH, Laude A, Tan CS. Polypoidal choroidal vasculopathy: an angiographic discussion. *Eye (Lond)* 2010; **24**: 483–490.
- 4 Tan CS, Ngo WK, Chen JP, Tan NW, Lim TH. EVEREST study report 2: imaging and grading protocol, and baseline characteristics of a randomised controlled trial of polypoidal choroidal vasculopathy. *Br J Ophthalmol* 2015; **99**: 624–628.
- 5 Tan CS, Wong HT, Lim BA, Hee OK, Lim TH. Polypoidal choroidal vasculopathy causing massive suprachoroidal haemorrhage. *Eye (Lond)* 2007; **21**: 132–133.

CS Tan^{1,2}, WK Ngo², LW Lim² and TH Lim^{1,2}

¹Fundus Image Reading Centre, National Healthcare Group Eye Institute, Singapore, Singapore and
²National Healthcare Group Eye Institute, Tan Tock Seng Hospital, Singapore, Singapore
E-mail: Colintan_eye@yahoo.com.sg

Eye (2015) **29**, 1238; doi:10.1038/eye.2015.101;
published online 19 June 2015