

research article

Correlation of diffusion MRI with the Ki-67 index in non-small cell lung cancer

Adem Karaman¹, Irmak Durur-Subasi¹, Fatih Alper¹, Omer Araz², Mahmut Subasi³, Elif Demirci⁴, Mevlut Albayrak⁴, Gökhan Polat¹, Metin Akgun², Nevzat Karabulut⁵

¹ Department of Radiology, Ataturk University, Medical Faculty, Erzurum, Turkey

² Department of Pulmonary Diseases, Ataturk University, Medical Faculty, Erzurum, Turkey

³ Department of Thoracic Surgery, Erzurum Regional Training and Research Hospital, Erzurum, Turkey

⁴ Department of Pathology, Ataturk University, Medical Faculty, Erzurum, Turkey

⁵ Department of Radiology, Pamukkale University, Medical Faculty, Denizli, Turkey

Radiol Oncol 2015; 49(3): 250-255.

Received 11 March 2015

Accepted 9 July 2015

Correspondence to: Assist. Prof. Irmak Durur-Subasi, M.D., Department of Radiology, Ataturk University, Medical Faculty, Erzurum, Turkey. Phone: +90 533 460 386; Fax: +90 442 236 1301; E-mail: irmakdurur@yahoo.com

Disclosure: No potential conflicts of interest were disclosed.

Background. The primary objective of the study was to evaluate the association between the minimum apparent diffusion coefficient (ADC_{min}) and Ki-67, an index for cellular proliferation, in non-small cell lung cancers. Also, we aimed to assess whether ADC_{min} values differ between tumour subtypes and tissue sampling method.

Methods. The patients who had diffusion weighted magnetic resonance imaging (DW-MRI) were enrolled retrospectively. The correlation between ADC_{min} and the Ki-67 index was evaluated.

Results. Ninety three patients, with a mean age 65 ± 11 years, with histopathologically proven adenocarcinoma and squamous cell carcinoma of the lungs and had technically successful DW-MRI were included in the study. The numbers of tumour subtypes were 47 for adenocarcinoma and 46 for squamous cell carcinoma. There was a good negative correlation between ADC_{min} values and the Ki-67 proliferation index ($r = -0.837$, $p < 0.001$). The mean ADC_{min} value was higher and the mean Ki-67 index was lower in adenocarcinomas compared to squamous cell carcinoma ($p < 0.0001$). There was no statistical difference between tissue sampling methods.

Conclusions. Because ADC_{min} shows a good but negative correlation with Ki-67 index, it provides an opportunity to evaluate tumours and their aggressiveness and may be helpful in the differentiation of subtypes non-invasively.

Key words: diffusion weighted-magnetic resonance imaging; apparent diffusion coefficient; Ki-67 index; adenocarcinoma; squamous cell carcinoma

Introduction

Diffusion weighted magnetic resonance imaging (DW-MRI) is a promising MRI technique used in the evaluation of lung tumours. It has been increasingly used for the detection, differential diagnosis and evaluation of tumour characteristics, including grading and prediction of the therapeutic response.¹⁻⁷ DW-MRI is a functional imaging technique that reveals physiological information by quantifying the diffusion of water molecules in tissues. The extent of this diffusion is measured

using the apparent diffusion coefficient (ADC). Malignant tissues tend to have a lower ADC and demonstrate higher signal intensity on a DW-MRI image due to their increased cellularity and larger nuclei with abundant macromolecular proteins.^{8,9}

The Ki-67 protein (also known as MKI67) is a cellular proliferation marker. During interphase, the Ki-67 antigen can only be detected within the cell nucleus; however, in mitosis, most of the Ki-67 is relocated to the surface of the chromosomes. Ki-67 protein is present during all active phases of the cell cycle (G1, S, G2, and mitosis), but is absent in

resting cells (G0). The Ki-67 proliferation index, one of the biological markers used in histopathological evaluation, is an important criterion in the differentiation of benign and malignant tumours.¹⁰⁻¹² It is also correlated with the clinical course of cancer and has been shown to have prognostic value for treatment response, tumour recurrence and survival in brain, breast, bladder and prostate tumours, meningioma and nephroblastoma.¹³⁻¹⁹ The Ki-67 index has also been used routinely in the evaluation of lung tumours and has been shown to be an important prognostic factor for lung cancer.^{3,6,20-27} Although a few studies have evaluated the association of ADC with Ki-67 index in lung tumours^{3,6}, no study has previously investigated differences in the ADC/Ki 67 correlation in different tumour subtypes.

In this study, our primary objective was to evaluate whether there is an association between the minimum ADC (ADC_{min}), determined on DW-MRI, and Ki-67, which is a cellular proliferative index. Our secondary aim was to assess whether ADC_{min} values differ between the adenocarcinomas and squamous cell carcinomas of the lungs and also differ according to the pathologic sampling method used, surgical excision specimen and biopsied material.

Methods

Study population

Between January 2012 and December 2013, records for 104 consecutive patients with histopathologically proven primary adenocarcinoma and squamous cell carcinoma of the lungs, and who had technically successful images on DW-MRI were retrieved from the hospital's pathology database. The patients who were previously treated ($n = 5$) and/or had an interval of more than 15 days between DW-MRI and biopsy ($n = 6$) were excluded from the study. All measurements, including calculation of Ki-67 index and ADC_{min} values, were done in the same lesion for each patient. The protocol of the retrospective study was approved by the institutional ethics committee and the requirement for informed consent was waived.

Imaging technique, DW-MRI

It was performed with a 3 tesla scanner (MAGNETOM Skyra, Siemens Healthcare, Erlangen, Germany). Conventional MRI included an axial T1-weighted sequence (repetition time,

104 ms; echo time, 4.92 ms; 1 excitation) and an axial T2-weighted sequence (repetition time, 1400 ms; echo time, 101 ms; 1 excitation). Breath-free DW-MRI was performed in the axial plane using a single-shot, spin-echo echo-planar imaging sequence with the following parameters: repetition time, 6500 ms; echo time, 61 ms; real spatial resolution in the phase-encoding direction, 3.7 mm; flip angle, 90°; diffusion gradient encoding in three orthogonal directions; b value $b = 50$, $b = 400$ and $b = 800$ s/mm²; field of view, 380 mm x 380 mm x 310 mm; matrix size, 113 x 192; slice thickness, 6 mm; section gap, 0 mm; 2 signals acquired.

Image analysis

We analysed the lesions using DW-MRI images in association with T1- and T2-weighted images in order to identify accurately. The ADC of the tumour was then calculated to quantitatively analyse the degree of diffusion, using the following formula: $ADC = -\ln(S/S_0) / (b-b_0)$, where S_0 and S are the signal intensities, obtained at three different diffusion gradients ($b = 50$, $b = 400$ and $b = 800$ s/mm²). The ADC maps were reconstructed at a workstation. While establishing the size and region for the ROI, positioning in the larger area was considered in order to minimize the effect of region on hemodynamic inhomogeneity of tumour by avoiding necrotic, cystic or calcific areas by referring to T2 and T1-weighted images.^{28,29} The ADC_{min} values within the ROI were then used in statistical analyses (Figure 1). In analyses workstation (Syngo Via Console, software version 2.0, Siemens AG Medical Solutions, Erlangen, Germany) was used.

Calculation of Ki-67 index

Archived paraffin blocks belonging to the patients were transferred to polylysine glass slides with 4-micron thick sections. Immunohistochemistry was performed using a Leica Bond-max automated immunostainer (Leica Microsystems, Newcastle, UK), as described manufacturers protocol. For Ki-67 staining, Ki-67 antibody (NCL-L-Ki67-MM1, monoclonal, 1:60, Novocostra, Newcastle, UK) was used. The sections prepared for examination were evaluated by two pathologists who were blinded to each-other. Firstly, ten areas having highest expression of Ki-67 were determined at low magnification. Then, these areas were further analysed at a single high power field (400 x magnification). Ki-67 expression was defined as the percent of Ki-67-positive tumour cells divided by the total number

of tumour cell within one high power field.^{26,30} In the last step, Ki-67 index was calculated as the average percentage of those fields.

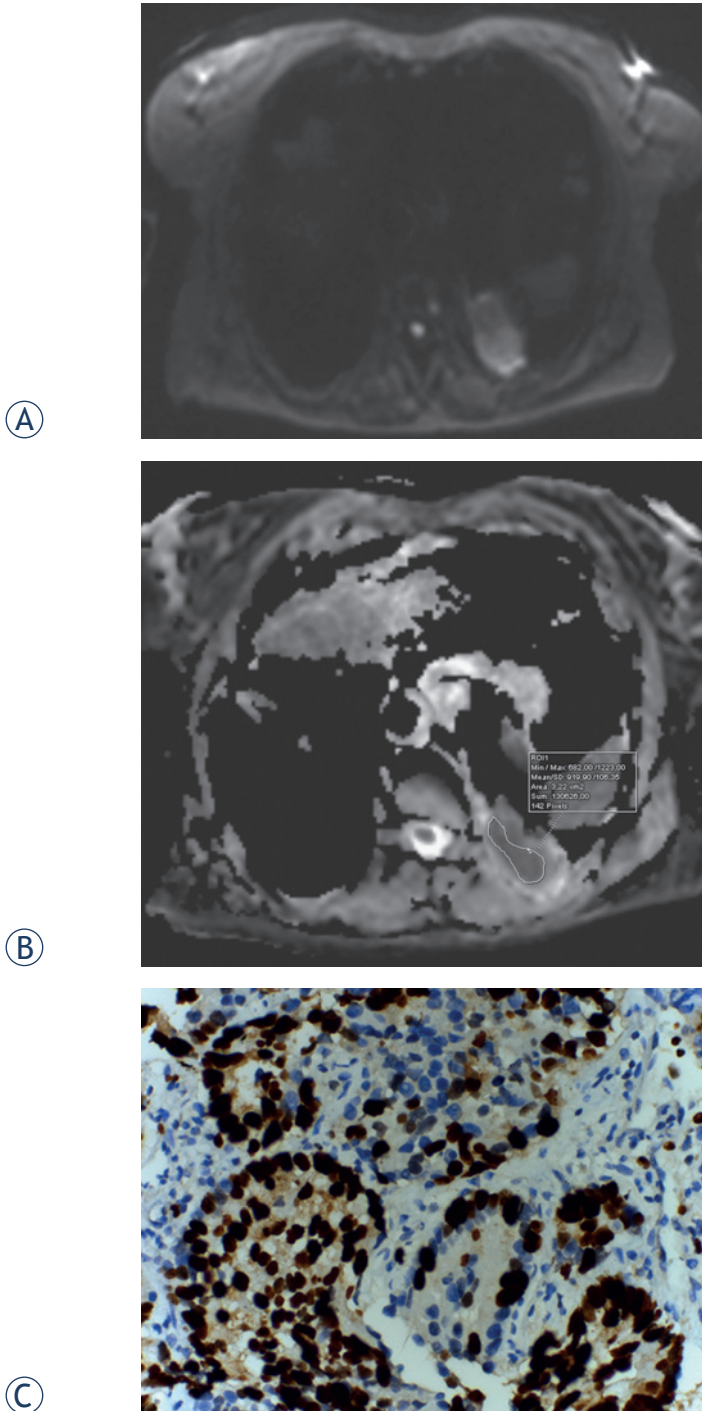


FIGURE 1. Diffusion-weighted (DW)-MRI, apparent diffusion coefficient (ADC) map of a 62-year-old female with adenocarcinoma. **(A)** Tumour shows heterogeneously high signal intensity on DW-MRI, for which the b value is 800 s/mm². **(B)** On the ADC map, the tumour demonstrates heterogeneous diffusion restriction. **(C)** Proliferative index 95% in glandular epithelium (Ki-67X400).

Statistical Analysis

Analyses were performed using IBM SPSS 20.0 for Mac software. The correlation between ADC_{min} and the Ki-67 index was evaluated using Spearman's correlation coefficient. Mann-Whitney U tests were used to assess the difference between the ADC_{min} and the Ki-67 index for the different tumour subtypes. A p value of less than 0.05 was considered statistically significant.

Results

Ninety three patients, with a mean age 65 ± 11 years ranged between 43 and 84, with histopathologically proven primary adenocarcinoma (n = 47) and squamous cell carcinoma (n = 46) of the lungs and had technically successful DW-MRI were included in the study. Histopathological diagnoses were obtained through transthoracic or transbronchial biopsy in 65 subjects and 28 patients underwent surgery.

The mean ADC_{min} value for all the lesions was 0.77 ± 0.15 × 10⁻³ mm²/sec (range, 0.50–1.00 × 10⁻³ mm²/sec). The mean ADC_{min} value for adenocarcinomas was 0.83 ± 0.12 × 10⁻³ mm²/sec and that of squamous cell carcinomas was 0.70 ± 0.16 × 10⁻³ mm²/sec; there was a significant difference between these values (p < 0.0001). The mean Ki-67 was 43.5 ± 22.2 for all the tumours (range, 5–96), with a mean of 30.8 ± 14.1 for adenocarcinomas and 55.9 ± 21.8 for squamous cell carcinoma; the difference between tumour subtypes was significant (p < 0.0001).

There was a negative correlation between ADC_{min} values and the Ki-67 proliferation index (p < 0.001, r = -0.837) (Figure 2). The ADC_{min} values were lower in the cases with higher Ki-67 grades. The mean ADC_{min} values and Ki-67 index for adenocarcinomas and squamous cell carcinomas of the lung are shown in Figure 3. There was no statistical difference of Ki-67 and ADC_{min} values between biopsied material and surgical specimen. The mean Ki-67 was 45.3 ± 22.8 vs 39.3 ± 19.8 and the mean ADC_{min} value was 0.76 ± 0.16 × 10⁻³ vs 0.78 ± 0.14 × 10⁻³ for biopsied material and surgical specimen, respectively. In the comparative evaluation of correlation between ADC_{min} and the Ki-67 proliferation index that measured either in surgical specimen or biopsied material, the Ki-67 index of surgical specimens was slightly better correlated with ADC_{min} values without statistical significance (r = -0.870 vs. -0.617) compared to biopsied material.

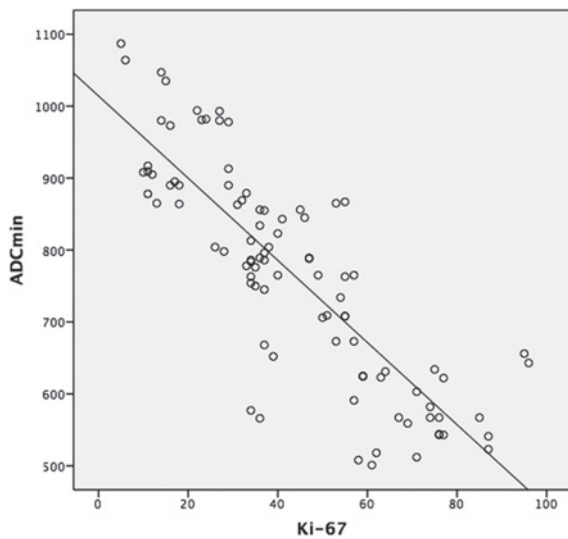


FIGURE 2. The graph shows a negative correlation between the minimum apparent diffusion coefficient (ADC_{min}) and the Ki-67 index in lung tumours ($r = -0.837$, $p < 0.001$).

Discussion

Our results showed that there is a negative correlation between the ADC_{min} and the Ki-67 index of lung cancers, which reflects aggressiveness of a tumour. ADC_{min} values for adenocarcinomas were higher than those for squamous cell carcinomas. This finding indicates that ADC_{min} may have a role in discriminating adenocarcinomas from squamous cell carcinomas, as well as being used for evaluating the aggressiveness of the tumour. Also, a low ADC_{min} value can potentially be used as a non-invasive surrogate biomarker for the Ki-67 index for the evaluation of lung tumour characteristics, regardless of subtype.

Lung cancer is the leading cause of cancer-related deaths.³¹ Until now, the Ki-67 proliferation index, reflecting aggressiveness of a tumour has been used to determine the prognosis. Malignant tumours are characterized by increased Ki-67 proliferation index due to their cellularity, larger nuclei with more abundant macromolecular proteins, a larger nuclear/cytoplasmic ratio and less extracellular space relative to normal tissue. As these characteristics also restrict the diffusion of water molecules, ADC_{min} decreases in malignant tumours.^{8,9,32}

Because ADC_{min} is found to have stronger correlation with Ki-67 index compared to ADC_{mean} , we used ADC_{min} in our study.¹⁵ Apparent diffusion coefficient can be used in the non-invasive assessment of suspicious masses, for example, to differentiate metastatic lymph nodes from those that are benign when they cannot be differentiated by size criteria.⁵

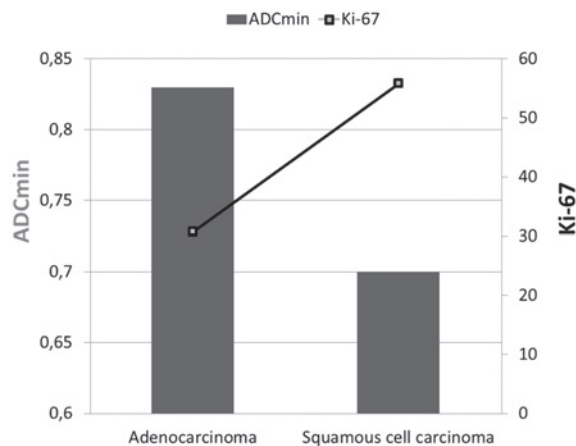


FIGURE 3. The graph shows average minimum apparent diffusion coefficient (ADC_{min}) values for adenocarcinoma and squamous cell carcinoma according to Ki-67 index. Bars are for ADC_{min} values and line is for Ki-67.

ADC values also correlate with tumour grades.^{4,17,18} Recent studies have shown that ADC may be more useful than FDG-PET in the differentiation of malignant tumours from benign lesions^{3,6} and the new approaches using PET\MRI may provide more promising results in the future.³³ Among primary lung cancers, ADC values are usually low in cases with small cell carcinomas, but the values for adenocarcinomas and squamous cell carcinomas are usually similar.^{3,4} However Matoba *et al.* stated that ADC s of well-differentiated adenocarcinoma appear to be higher than those of other histologic lung carcinoma types.²³ Our findings demonstrate that adenocarcinomas showed higher ADC values than squamous cell carcinomas, and had weaker staining diffusivity and intensity of Ki-67.

A high Ki-67 and low ADC_{min} value indicates that a tumour has a high proliferation rate. Ki-67 values obtained using an invasive method reflect only the level in the sampled tissue; this is a particular problem when using biopsy. Since lung carcinomas are not always homogenous, the biopsy site can influence the results. This could be reflected in the fact that in our study the correlation between ADC_{min} and Ki-67 proliferation index was stronger for surgical than for biopsy samples. Unlike these invasive sampling methods, ADC_{min} values obtained by DW-MRI in a non-invasive manner can be calculated from anywhere in the tumour, providing an entire and reproducible assessment of the tumour. Furthermore, since the region with the lowest ADC_{min} value is likely to be the most aggressive portion.^{17,34} DWI could also help in the selection of an appropriate biopsy site within the tumour.

An association between the ADC value and the Ki-67 index has been shown for various kinds of tumours^{2,14-18,34-38}, including lung cancer.^{3,6} Wang *et al.*, in their study on DWI in pancreatic endocrine tumours, reported a correlation coefficient of -0.70², while Onishi *et al.* reported a correlation coefficient of -0.825 for mucinous breast carcinoma.¹⁵

Previous studies reporting ADC values of lung carcinoma have been conducted under various magnet strengths, and reported ADC values are lower in magnets with a stronger field. Matoba *et al.* reported mean ADC values of $1.63 \times 10^{-3} \text{ mm}^2/\text{sec} \pm 0.5$ (mean \pm SD) for squamous cell carcinomas, $2.12 \times 10^{-3} \text{ mm}^2/\text{sec} \pm 0.6$ for adenocarcinomas, $1.30 \times 10^{-3} \text{ mm}^2/\text{sec} \pm 0.4$ for large-cell carcinomas, and $2.09 \times 10^{-3} \text{ mm}^2/\text{sec} \pm 0.3$ for small-cell carcinomas, using a 1.5 T scanner. Usuda *et al.*⁶ found that malignant nodules had a mean ADC of $1.27 \pm 0.35 \times 10^{-3} \text{ mm}^2/\text{sec}$ on a 1.5T system. Using a 3.0 T scanner, Zhang *et al.* reported that malignant pulmonary nodules had a mean ADC of $0.87 \pm 0.16 \times 10^{-3} \text{ mm}^2/\text{sec}$. Similarly, we found a mean ADC_{min} of $0.77 \pm 0.12 \times 10^{-3} \text{ mm}^2/\text{sec}$ in our study conducted on a 3.0 T scanner. These values are lower than those were reported by the studies conducted using 1.5 T systems.^{6,23} However, Kivrak *et al.* noted that ADC values vary for different MRI systems with the same magnetic field strength (1.5 T).³⁹ On the other hand, some authors reported that ADC values might not change for different organ systems under different magnetic fields.⁴⁰ However, they only used healthy volunteers and neither pathologic conditions nor image quality was not assessed. Further work is still needed to investigate the effect of magnetic field strength on the ADC of different organ systems.

One of the strongest side of our study was that we used 3 tesla MRI, which has increased signal to noise ratio, spatial resolution, temporal resolution, etc. Thus, decreased imaging time increased patients' cooperation and we had better qualified images. Our study had a few limitations. Our study population was relatively small and, although our results are robust, prospective studies with larger series are warranted to confirm our results. Additionally, to be able to generalize our results to all subtypes of lung cancer, such as small cell carcinomas and the other subtypes of non-small cell lung cancer, which we had very limited number of such cases during the study period, need to be included in future studies. Because we had no data about survival of the cases, we could not conclude any association between ADC_{min} or Ki-67 and survival. However, use of ADC_{min} may provide new

insight to the evaluation of lung cancer including benign-malignant discrimination, the possibility of evaluation all lesions and lymph nodes non-invasively, even in the cases that tissue sampling is difficult, as well as predicting the prognosis of tumour by using it as a surrogate marker of Ki-67 index.

In conclusion, our results suggested that ADC_{min} values were inversely correlated with Ki-67 index in non-small cell lung cancer and may be used as a surrogate marker of Ki-67 index in the evaluation of tumour aggressiveness with the advantage of its non-invasiveness and without requirement of tissue sampling of all the lesions.

References

1. Yabuuchi H, Hatakenaka M, Takayama K, Matsuo Y, Sunami S, Kamitani T, et al. Non-small cell lung cancer: detection of early response to chemotherapy by using contrast-enhanced dynamic and diffusion-weighted MR imaging. *Radiology* 2011; **26**: 598-604.
2. Wang Y, Chen ZE, Yaghmai V, Nikolaidis P, McCarthy RJ, Merrick L, et al. Diffusion-weighted MR imaging in pancreatic endocrine tumors correlated with histopathologic characteristics. *J Magn Reson Imaging* 2011; **33**: 1071-9.
3. Zhang J, Cui LB, Tang X, Ren XL, Shi JR, Yang HN, et al. DW MRI at 3.0 T versus FDG PET/CT for detection of malignant pulmonary tumors. *Int J Cancer* 2014; **134**: 606-11.
4. Li F, Yu T, Li W, Zhang C, Cao Y, Su D, et al. Correlation of apparent diffusion coefficient with histologic type and grade of lung cancer. *Zhongguo Fei Ai Za Zhi* 2012; **15**: 646-51.
5. Xu L, Tian J, Liu Y, Li C. Accuracy of diffusion-weighted (DW) MRI with background signal suppression (MR-DWIBS) in diagnosis of mediastinal lymph node metastasis of nonsmall-cell lung cancer (NSCLC). *J Magn Reson Imaging* 2014; **40**: 200-5.
6. Usuda K, Sagawa M, Motono N, Ueno M, Tanaka M, Machida Y, et al. Diagnostic performance of diffusion weighted imaging of malignant and benign pulmonary nodules and masses: comparison with positron emission tomography. *Asian Pac J Cancer Prev* 2014; **15**: 4629-35.
7. Türkbey B, Aras Ö, Karabulut N, Turgut AT, Akpınar E, Alibek S, et al. Diffusion-weighted MRI for detecting and monitoring cancer: a review of current applications in body imaging. *Diagn Interv Radiol* 2012; **18**: 46-59.
8. Koh DM, Collins DJ. Diffusion-weighted MRI in the body: applications and challenges in oncology. *AJR Am J Roentgenol* 2007; **188**: 1622-35.
9. Padhani AR, Liu G, Koh DM, Chenevert TL, Thoeny HC, Takahara T, et al. Diffusion-weighted magnetic resonance imaging as a cancer biomarker: consensus and recommendations. *Neoplasia* 2009; **11**: 102-25.
10. Scholzen T, Gerdes J. The Ki-67 protein: from the known and the unknown. *J Cell Physiol* 2000; **182**: 311-22.
11. Raïkhlin NT, Bukaeva IA, Smirnova EA, Gurevich LE, Delektorskaia VV, Polotskiï BE, et al. Significance of the expression of nucleolar argyrophilic proteins and antigen Ki-67 in the evaluation of cell proliferative activity and in the prediction of minimal (T1) lung cancer. *Arkh Patol* 2008; **70**: 15-18.
12. Gerdes J, Lemke H, Baisch H, Wacker HH, Schwab U, Stein H. Cell cycle analysis of a cell proliferation-associated human nuclear antigen defined by the monoclonal antibody Ki-67. *J Immunol* 1984; **133**: 1710-15.
13. Zhu L, Ren G, Li K, Liang ZH, Tang WJ, Ji YM, et al. Pineal parenchymal tumours: minimum apparent diffusion coefficient in prediction of tumour grading. *J Int Med Res* 2011; **39**: 1456-63.
14. Choi SY, Chang YW, Park HJ, Kim HJ, Hong SS, Seo DY. Correlation of the apparent diffusion coefficient values on diffusion-weighted imaging with prognostic factors for breast cancer. *Br J Radiol* 2012; **85**(1016): e474-9.

15. Onishi N, Kanao S, Kataoka M, Iima M, Sakaguchi R, Kawai M, et al. Apparent diffusion coefficient as a potential surrogate marker for Ki-67 index in mucinous breast carcinoma, *J Magn Reson Imaging* 2015; **41**: 610-5.
16. Mesko S, Kupelian P, Demanes DJ, Huang J, Wang PC, Kamrava M. Quantifying the ki-67 heterogeneity profile in prostate cancer. *Prostate Cancer* 2013; **2013**: 717080.
17. Kobayashi S, Koga F, Kajino K, Yoshita S, Ishii C, Tanaka H, et al. Apparent diffusion coefficient value reflects invasive and proliferative potential of bladder cancer. *J Magn Reson Imaging* 2014; **39**: 172-8.
18. Tang Y, Dundamadappa SK, Thangasamy S, Flood T, Moser R, Smith T, et al. Correlation of apparent diffusion coefficient with Ki-67 proliferation index in grading meningioma. *AJR Am J Roentgenol* 2014; **202**: 1303-8.
19. Martin B, Paesmans M, Mascaux C, Berghmans T, Lothaire P, Meert AP, et al. Ki-67 expression and patients survival in lung cancer: systematic review of the literature with meta-analysis. *Br J Cancer* 2004; **91**: 2018-25.
20. Usuda K, Zhao XT, Sagawa M, Aikawa H, Ueno M, Tanaka M, et al. Diffusion-weighted imaging (DWI) signal intensity and distribution represent the amount of cancer cells and their distribution in primary lung cancer. *Clin Imaging* 2013; **37**: 265-72.
21. Ohno Y, Koyama H, Yoshikawa T, Matsumoto K, Aoyama N, Onishi Y, et al. Diffusion-weighted MRI versus 18F-FDG PET/CT: performance as predictors of tumor treatment response and patient survival in patients with nonsmall cell lung cancer receiving chemoradiotherapy. *AJR Am J Roentgenol* 2012; **198**: 75-82.
22. Tanaka R, Horikoshi H, Nakazato Y, Seki E, Minato K, Iijima M, et al. Magnetic resonance imaging in peripheral lung adenocarcinoma: correlation with histopathologic features. *J Thorac Imaging* 2009; **24**: 4-9.
23. Matoba M, Tonami H, Kondou T, Yokota H, Higashi K, Toga H, et al. Lung carcinoma: diffusion-weighted MR imaging—preliminary evaluation with apparent diffusion coefficient. *Radiology* 2007; **243**: 570-7.
24. Martin B, Paesmans M, Mascaux C, Berghmans T, Lothaire P, Meert AP, et al. Ki-67 expression and patients survival in lung cancer: systematic review of the literature with meta-analysis. *Br J Cancer* 2004; **91**: 2018-25.
25. Warth A, Cortis J, Soltermann A, Meister M, Budczies J, Stenzinger A, et al. Tumour cell proliferation (Ki-67) in non-small cell lung cancer: a critical reappraisal of its prognostic role. *Br J Cancer* 2014; **111**: 1222-9.
26. Tabata K, Tanaka T, Hayashi T, Hori T, Nunomura S, Yonezawa S, et al. Ki-67 is a strong prognostic marker of non-small cell lung cancer when tissue heterogeneity is considered. *BMC Clin Pathol* 2014; **14**: 23-30.
27. Ahn HK, Jung M, Ha SY, Lee JI, Park I, Kim YS, et al. Clinical significance of Ki-67 and p53 expression in curatively resected non-small cell lung cancer. *Tumour Biol* 2014; **35**: 5735-40.
28. Alper F, Kurt AT, Aydin Y, Ozgokce M, Akgun M. The role of dynamic magnetic resonance imaging in the evaluation of pulmonary nodules and masses. *Med Princ Pract* 2013; **22**: 80-6.
29. Karaman A, Kahraman M, Bozdoğan E, Alper F, Akgün M. Diffusion magnetic resonance imaging of thorax. *Tuberk Toraks* 2014; **62**: 215-30.
30. Araz O, Demirci E, Ucar EY, Calik M, Karaman A, Durur-Subasi I, et al. Roles of Ki-67, p53, transforming growth factor- β and lysyl oxidase in the metastasis of lung cancer. *Respirology* 2014; **19**: 1034-9.
31. Siegel R, Naishadham D, Jemal A. Cancer statistics, 2013. *CA Cancer J Clin* 2013; **63**: 11-30.
32. Zhang Z, Zhou Y, Qian H, Shao G, Lu X, Chen Q, et al. Stemness and inducing differentiation of small cell lung cancer NCI-H446 cells. *Cell Death Dis* 2013; **16**: e633.
33. Schaarschmidt BM, Buchbender C, Nensa F, Gruenien J, Gomez B, Köhler J, et al. Correlation of the apparent diffusion coefficient (ADC) with the standardized uptake value (SUV) in lymph node metastases of non-small cell lung cancer (NSCLC) patients using hybrid 18F-FDG PET/MRI. *PLoS One* 2015; **10(1)**: e0116277.
34. Yoshida S, Kobayashi S, Koga F, Ishioka J, Ishii C, Tanaka H, et al. Apparent diffusion coefficient as a prognostic biomarker of upper urinary tract cancer: a preliminary report. *Eur Radiol* 2013; **23**: 2206-14.
35. Yoshida S, Koga F, Kobayashi S, Ishii C, Tanaka H, Tanaka H, et al. Role of diffusion weighted magnetic resonance imaging in predicting sensitivity to chemoradiotherapy in muscle-invasive bladder cancer. *Int J Radiat Oncol Biol Phys* 2012; **83**: e21-e7.
36. Wieduwilt MJ, Valles F, Issa S, Behler CM, Hwang J, McDermott M, et al. Immunotherapy with intensive consolidation for primary CNS lymphoma: a pilot study and prognostic assessment by diffusion-weighted MRI. *Clin Cancer Res* 2012; **18**: 1146-55.
37. Srinivasan A, Chenevert TL, Dwamena BA, Eisbruch A, Watcharotone K, Myles JD, et al. Utility of pretreatment mean apparent diffusion coefficient and apparent diffusion coefficient histograms in prediction of outcome to chemoradiation in head and neck squamous cell carcinoma. *J Comput Assist Tomogr* 2012; **36**: 131-7.
38. Pope WB, Lai A, Mehta R, Qiao J, Young JR, Xue X, et al. Apparent diffusion coefficient histogram analysis stratifies progression-free survival in newly diagnosed bevacizumab-treated glioblastoma. *AJNR Am J Neuroradiol* 2011; **32**: 882-9.
39. Kivrak AS, Paksoy Y, Erol C, Koplay M, Özbek S, Kara F. Comparison of apparent diffusion coefficient values among different MRI platforms: a multi-center phantom study. *Diagn Interv Radiol* 2013; **19**: 433-7.
40. Rosenkrantz AB, Oei M, Babb JS, Niver BE, Taouli B. Diffusion-weighted imaging of the abdomen at 3.0 Tesla: image quality and apparent diffusion coefficient reproducibility compared with 1.5 Tesla. *J Magn Reson Imaging* 2011; **33**: 128-35.