

A novel *PRKAR1A* mutation resulting in a splicing variant in a case of Carney complex

Yi Sun Jang, Sung Dae Moon, Ju Hee Kim, Ihn Suk Lee, Jong Min Lee, and Hye Soo Kim

Department of Internal Medicine,
College of Medicine, The Catholic
University of Korea, Seoul, Korea

To the Editor,

Carney complex (CNC) is an autosomal-dominant inherited disorder featuring cardiac or cutaneous myxoma, multiple endocrine tumors with endocrine overactivity, psammomatous melanotic schwannomas (PMSSs), and spotty pigmentations in the mucosa and skin. Endocrine manifestations of CNC include pituitary adenoma with acromegaly, thyroid tumors, testicular large cell calcifying Sertoli cell tumors (LCCSCTs), ovarian lesions, and primary pigmented nodular adrenal disease (PPNAD). Cushing's syndrome due to PPNAD is adrenocorticotrophic hormone (ACTH)-independent and the most frequent endocrine disorder of CNC (25%) [1]. Since the association of CNC and *PRKAR1A* mutation was first described, 117 mutations of the *PRKAR1A* gene have been reported [2]. Here, we describe a Korean case of CNC with PPNAD, and report a novel mutation of the *PRKAR1A* gene.

A 22-year-old male presented with uncontrolled hypertension and purple striae on his abdomen. Ten years previously, he had undergone brain surgery at another hospital for a 4-cm brain tumor in the right cerebello-pontine angle, which was initially diagnosed as a melanocytoma. There was no evidence of brain tumor recurrence. At that time, a testicular biopsy was also performed due to a feeling of testicular

lumps on palpation, and it showed severe atrophy. Skin nodule pathology in left infra-auricular area was reported as myxoid liposarcoma. His father, and elder brother appeared healthy, but his mother had passed away suddenly at age 32 and had also demonstrated skin nodules (Fig. 1A). The patient was 180 cm tall, weighing 76 kg, and his blood pressure was 140/90 mmHg on four antihypertensive medications. He showed typical features of Cushing's syndrome, such as moon face (Fig. 1B), truncal obesity, purple striae on the abdomen (Fig. 1C), and buffalo hump. Multiple skin nodules were noted on his scalp, left ear lobe, and both arms (Fig. 1D) and there were a few brownish pigmentations on his legs (Fig. 1E). His 24-hour urine free cortisol (UFC) was 287 mg/day (normal range, 20 to 90), while the serum ACTH and cortisol at 8:00 AM were 2.6 pg/mL and 29.37 mg/dL, respectively.

During a low-dose dexamethasone suppression test, serum cortisol and 24-hour UFC were not sufficiently suppressed (serum cortisol 33.72 mg/dL, 24-hour UFC 579 mg/day). After a high-dose dexamethasone suppression test, the serum cortisol was elevated to 35.54 mg/dL. The serum cortisol was paradoxically increased after both tests.

A computed tomography scan of the abdomen showed multiple 0.6 to 0.8 cm small nodules in both adrenal

Received: November 7, 2014
Revised : November 17, 2014
Accepted: November 27, 2014

Correspondence to Hye Soo Kim, M.D.

Department of Internal
Medicine, College of Medicine,
Daejeon St. Mary's Hospital, The
Catholic University of Korea, 64
Daeheung-ro, Jung-gu, Daejeon
34943, Korea
Tel: +82-42-220-9114
Fax: +82-42-252-6807
E-mail: drkhs@catholic.ac.kr

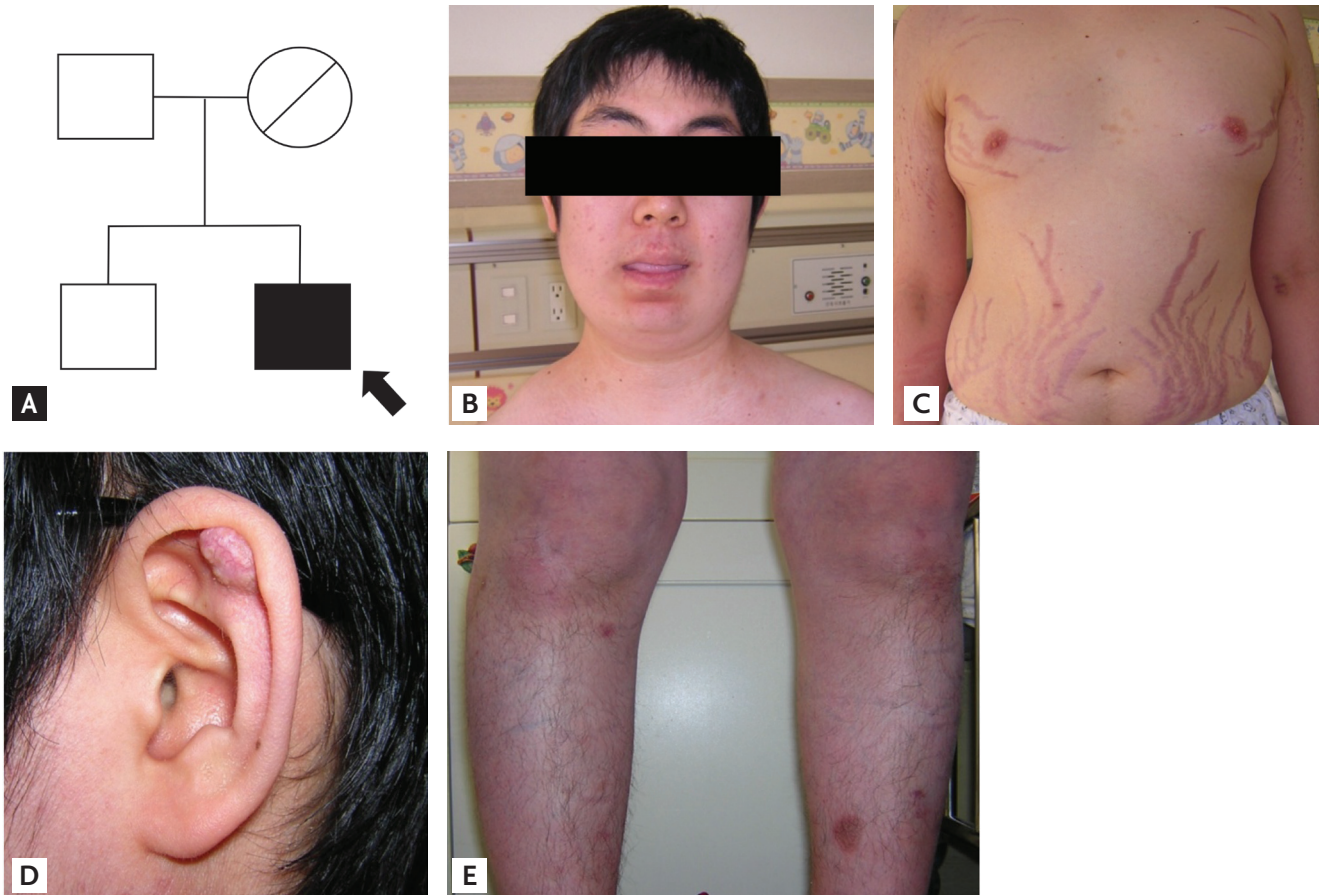


Figure 1. (A) Pedigree of the family with Carney complex. Arrow indicates the proband. Appearance of the patient with Carney complex. (B) Moon face, (C) abdominal obesity with red striae, (D) a skin nodule in the earlobe, and (E) spotty pigmentations on the legs are noted.

glands and a 1.8 cm-sized dominant one on the left (Fig. 2A and 2B). Follicle-stimulating hormone and luteinizing hormone were 2.4 and 7.3 IU/L, respectively, and total testosterone was 0.74 ng/mL. Thyroid function was normal on biochemical testing. Fasting glucose was 104 mg/dL, total cholesterol was 256 mg/dL, and triglycerides were 187 mg/dL, sodium was 145 mEq/L, and potassium was 3.7 mEq/L. Other routine laboratory data were normal. Echocardiogram and thyroid ultrasound showed normal findings.

The patient underwent a laparoscopic bilateral adrenalectomy. The histological diagnosis was PPNAD in both adrenal glands, combined with left adrenal adenoma without pigmentation (Fig. 2C and 2D). Following the adrenalectomy, he was prescribed a replacement dose of hydrocortisone and fludrocortisone and his Cushingoid features regressed. A skin nodule in the

earlobe was later removed and diagnosed as a myxoma. Ultrasound of the testicles showed multiple calcified nodules replacing the testes, suggesting testicular LCCSCTs (Fig. 2E and 2F). However, he refused surgical removal of the tumors.

We retrospectively reviewed the previous tissue slide of his brain tumor and corrected the diagnosis to PMS (Fig. 2G and 2H). We concluded that he had CNC manifesting as skin myxomas, skin pigmentations, PMS at cerebello-pontine angle, Cushing's syndrome due to PPNAD, adrenal adenoma, and testicular LCCSCTs.

DNA was extracted from his leukocytes and adrenal tissue obtained from the laparoscopic bilateral adrenalectomy. On DNA sequence analysis of the *PRKAR1A* gene, we found a novel substitution mutation (c.441-2A>G) in intron 4 (Fig. 3A) from his leukocytes and adrenal tumor tissue without a second hit in *PRKAR1A*

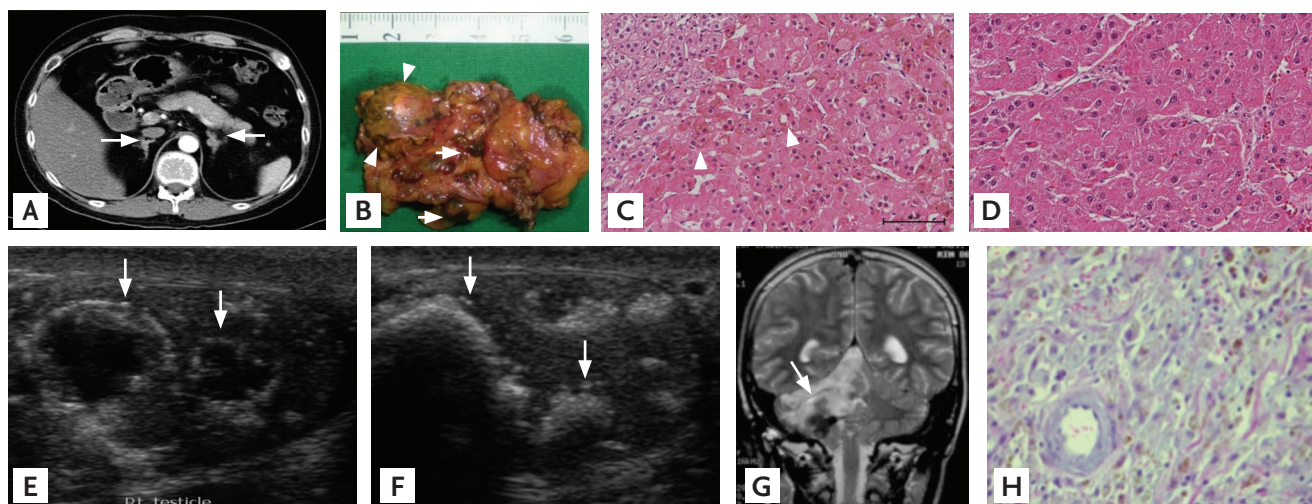


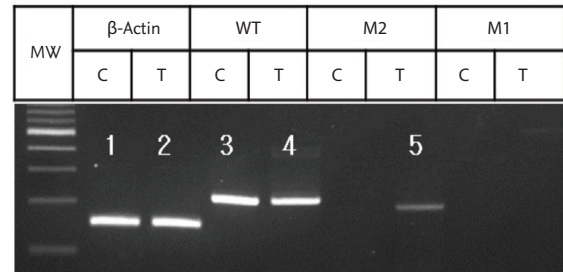
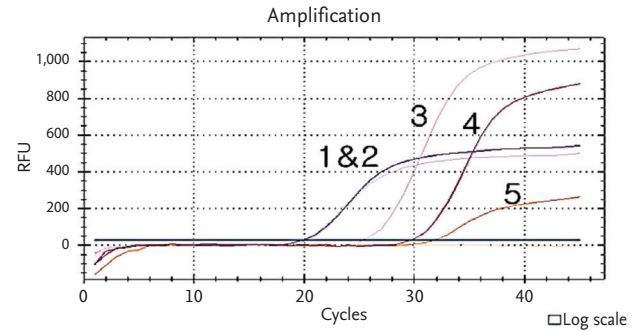
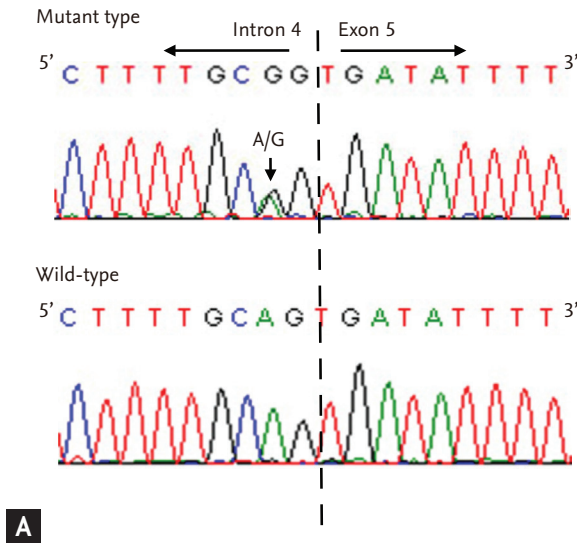
Figure 2. (A) Computed tomography of the abdomen showed multiple small nodules (arrows) with bead-string appearance in both adrenal glands. (B) The gross specimen of the removed left adrenal gland showed multiple small nodules with dark pigmentation (arrows) and a medium-sized nodule without pigmentation (arrowheads), pathologically diagnosed as primary pigmented nodular adrenal disease and an adrenal adenoma, respectively. (C) Pigmentation (arrowheads) of right adrenal micro-nodule (H&E, $\times 200$). (D) Non-pigmented left adrenal adenoma (H&E, $\times 200$). (E, F) The ultrasonography of right (E) and left (F) testicles showed multiple calcified nodules (arrows), suggesting large cell calcifying Sertoli cell tumors. (G) Previous magnetic resonance imaging showed a 4-cm mass (arrow) in the right cerebello-pontine angle. (H) Pathology of the brain tumor showed spindle cells containing pigmentation, rediagnosed as a psammomatous melanotic schwannoma (H&E, $\times 400$).

in his adrenal tumor. A mutation in intron 4 could theoretically result in two aberrantly spliced *PRKAR1A* mRNAs of 41-bp deleted and 62-bp deleted variants (Fig. 3B). To determine whether the products resulting from aberrantly spliced *PRKAR1A* mRNA were rapidly degraded, real-time polymerase chain reaction was performed to quantify expression of the mRNAs in the leukocytes and the adrenal tumor of the CNC patient. Setting the quantification ratio of the wild-type *PRKAR1A* mRNA in a control sporadic adrenal tumor at 1.0, the relative quantification ratios of the wild-type *PRKAR1A* mRNA, 41-bp deleted *PRKAR1A* mRNA, and 62-bp deleted *PRKAR1A* mRNA in the CNC were 0.46, 0.00, and 0.08, respectively (Fig. 3C). Studies have not yet been completed for the wild-type and 62-bp deleted *PRKAR1A* protein expression in this case, but the data may suggest haploinsufficiency of wild-type *PRKAR1A* mRNA and premature decay of most of the mutant mRNA.

The *PRKAR1A* gene is located on chromosome 17q22-24 and encodes the R1 α regulatory subunit of cyclic adenosine monophosphate (cAMP)-dependent protein kinase A (PKA) that plays an important role in many signaling pathway [2]. Mutations of the *PRKAR1A* gene

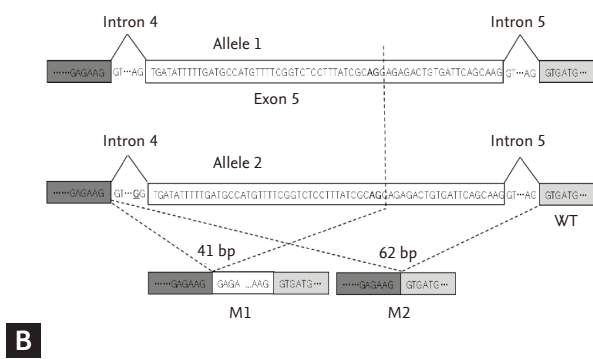
have been identified in 45% to 65% of patients with CNC [3] and CNC combined with PPNAD showed a higher rate (80%) of germline *PRKAR1A* mutations [4]. In the case of isolated PPNAD without a *PRKAR1A* mutation, another mutation was identified in the gene of the *phosphodiesterase 11A* (*PDE11A*) that regulated cAMP levels [3]. Most *PRKAR1A* mutations result in premature stop codons and mutant transcripts are degraded by nonsense-mediated mRNA decay, not showing mutant or shortened proteins [3]. The haploinsufficiency of wild-type *PRKAR1A* protein lead to increased PKA activity, followed by cell cycle abnormalities [5]. Only a minority (17.1%) of *PRKAR1A* mutation expressed mutant or shortened proteins with wild-type protein, showing more aggressive clinical manifestations [2].

Almost all *PRKAR1A* mutations in CNC are located in exons and the most frequent is a deletion in exon 5 [3], but we present a novel mutation of the *PRKAR1A* gene in intron 4. The test for an inactivating mutation of *PRKAR1A* is only a supplemental criterion for diagnosing CNC [1], but it can be useful to provide genetic counseling and monitor tumor growth in an asymptomatic CNC patient.



A

C



B

Figure 3. (A) Genomic DNA sequence analysis (5') of the IVS4/exon 5 *PRKAR1A* splice site. The heterozygous IVS4A-2A>G mutation is in the second base of the 3'-acceptor splice site of intron 4A. The A→G substitution is indicated by the bold A/G. (B) Theoretically possible *PRKAR1A* transcripts resulting from the mutation IVS4A-2A>G: the wild-type (WT), 41-bp-deleted (M1), and 62-bp-deleted (M2) *PRKAR1A* mRNAs. The exonic splice acceptor site sequence in exon 4B is indicated by the bold AG. (C) Quantification of the differentially expressed *PRKAR1A* mRNAs in Carney complex. Plot of the real-time polymerase chain reaction (PCR) amplification and high-resolution gel electrophoresis for detection of PCR products generated during the amplification cycles. RFU, relative fluorescence unit; MW, molecular weight; C, normal adrenal tissue; T, adrenal tumor of Carney complex; WT, wild-type *PRKAR1A* mRNA; M1, *PRKAR1A* mRNA with a 41-bp deletion; M2, *PRKAR1A* mRNA with a 62-bp deletion.

Keywords: Carney complex; *PRKAR1A* mutation

Conflict of interest

No potential conflict of interest relevant to this article was reported.

Acknowledgments

This work was supported by the Catholic Medical Center Research Foundation in program year 2011.

REFERENCES

1. Stratakis CA, Kirschner LS, Carney JA. Clinical and molecular features of the Carney complex: diagnostic criteria and recommendations for patient evaluation. *J Clin Endocrinol Metab* 2001;86:4041-4046.
2. Horvath A, Bertherat J, Groussin L, et al. Mutations and polymorphisms in the gene encoding regulatory subunit type 1-alpha of protein kinase A (*PRKAR1A*): an update. *Hum Mutat* 2010;31:369-379.
3. Cazabat L, Ragazzon B, Groussin L, Bertherat J. *PRKAR1A* mutations in primary pigmented nodular adreno-

cortical disease. *Pituitary* 2006;9:211-219.

4. Groussin L, Kirschner LS, Vincent-Dejean C, et al. Molecular analysis of the cyclic AMP-dependent protein kinase A (PKA) regulatory subunit 1A (PRKAR1A) gene in patients with Carney complex and primary pigmented nodular adrenocortical disease (PPNAD) reveals novel mutations and clues for pathophysiology: augmented PKA signaling is associated with adrenal tumorigenesis in PPNAD. *Am J Hum Genet* 2002;71:1433-1442.
5. Robinson-White A, Meoli E, Stergiopoulos S, et al. PRKAR1A mutations and protein kinase A interactions with other signaling pathways in the adrenal cortex. *J Clin Endocrinol Metab* 2006;91:2380-2388.