

Neutrophil infiltration and the distribution of intestinal metaplasia is associated with metachronous gastric cancer following endoscopic submucosal dissection

Takafumi Sugimoto MD^{1,2}, Yutaka Yamaji MD², Kosuke Sakitani MD², Yoshihiro Isomura MD², Shuntaro Yoshida MD², Atsuo Yamada MD², Yoshihiro Hirata MD², Keiji Ogura MD³, Makoto Okamoto MD⁴, Kazuhiko Koike MD²

T Sugimoto, Y Yamaji, K Sakitani, et al. Neutrophil infiltration and the distribution of intestinal metaplasia is associated with metachronous gastric cancer following endoscopic submucosal dissection. *Can J Gastroenterol Hepatol* 2015;29(6):321-325.

BACKGROUND: Endoscopic submucosal dissection (ESD) of early gastric cancer is a minimally invasive procedure. However, the risk for metachronous cancers after successful cancer treatment remains high and the risk factors for metachronous cancers have not been elucidated. **OBJECTIVE:** To evaluate the risk factors for metachronous gastric cancers after ESD with a long-term follow-up.

METHODS: A total of 155 consecutive patients (119 men, 36 women, mean age 68.9 years) were treated with ESD between September 2000 and September 2009. Biopsy specimens were obtained from the greater curvature of the antrum and middle corpus to evaluate gastric mucosal status, including *Helicobacter pylori*, intestinal metaplasia (IM) and neutrophil infiltration (NI) before ESD. Follow-up endoscopy after ESD was scheduled at two and six months, one year and annually thereafter. *H pylori* eradication was recommended when possible.

RESULTS: The median follow-up period was 4.2 years. Metachronous gastric cancers were found in 23 of 155 patients (3.5% per year). No local recurrences were observed. The cumulative incidence of metachronous gastric cancer was significantly high in IM and NI in the corpus (P=0.0093 and P=0.0025, respectively [log-rank test]). The ORs for IM and NI in the corpus were 2.65 and 3.06, respectively, according to the Cox proportional hazards model (P=0.024 and P=0.0091, respectively).

CONCLUSIONS: The presence of IM and NI in the corpus was closely related to the development of metachronous gastric cancer after ESD.

Key Words: Endoscopic submucosal dissection; *Helicobacter pylori*; Intestinal metaplasia; Neutrophil infiltration; Stomach neoplasms

The rate of diagnosis of early gastric cancer has increased due to improved diagnostic procedures such as endoscopic examinations including chromoendoscopy and narrow-band imaging (1,2). Endoscopic resection (ER), which includes endoscopic mucosal resection (EMR) and endoscopic submucosal dissection (ESD), has been established as a less-invasive treatment for early gastric cancer without concomitant lymph node metastasis (3-5). ESD has become accepted for en bloc resection, which is beneficial for curative treatment to avoid local recurrence (5-10). Although ER contributes to preservation of the majority of the stomach, metachronous cancers developing

La distribution de l'infiltration de neutrophiles et de la métaplasie intestinale associée au cancer gastrique métachrone après une dissection endoscopique des tissus sous-muqueux

HISTORIQUE : La dissection endoscopique des tissus sous-muqueux (DETS) du cancer gastrique précoce est une intervention à effraction minimale. Cependant, le risque de cancers métachrones demeure élevé après un traitement fructueux du cancer, et les facteurs de risque de cancers métachrones ne sont pas établis.

OBJECTIF : Évaluer les facteurs de risque des cancers gastriques métachrones après une DETS au moyen d'un suivi à long terme.

MÉTHODOLOGIE : Au total, 155 patients consécutifs (119 hommes et 36 femmes, d'un âge moyen de 68,9 ans) ont subi une DETS entre septembre 2000 et septembre 2009. Les échantillons de biopsie ont été prélevés dans la grande courbure de l'antré et le corps moyen pour évaluer l'état de la muqueuse gastrique, y compris l'*Helicobacter pylori*, la métaplasie intestinale (MI) et l'infiltration de neutrophiles (IN) avant la DETS. Une endoscopie de suivi après la DETS était planifiée au bout de deux mois, de six mois, d'un an, puis tous les ans par la suite. Dans la mesure du possible, l'éradication de l'*H pylori* était recommandée.

RÉSULTATS : La période de suivi médiane était de 4,2 ans. Les médecins ont découvert des cancers gastriques métachrones chez 23 des 155 patients (3,5 % par année). Ils n'ont observé aucune récurrence locale. L'incidence cumulative de cancers gastriques métachrones était très élevée en présence de MI et d'IN du corps de l'estomac (P=0,0093 et P=0,0025, respectivement [test de Mantel-Haenszel]). Les rapports de cote de MI et d'IN dans le corps de l'estomac correspondaient à 2,65 et à 3,06, respectivement, conformément au modèle des risques proportionnels de Cox (P=0,024 et P=0,0091, respectivement).

CONCLUSIONS : La présence de MI et d'IN dans le corps de l'estomac était étroitement liée à l'apparition de cancer gastrique métachrone après une DETS.

at other sites in the stomach may occur more frequently after ER than those after surgical partial gastrectomy (11). Several studies have reported that the incidence of metachronous cancers after ER is 2.4% to 14% (12,13). The residual gastric mucosa after ER is believed to be a high-risk microenvironment.

Helicobacter pylori is one of the most important risk factors for gastric cancer (14-17). Inflammation caused by *H pylori* infection may play an initiating role in gastric carcinogenesis (18). Based on this hypothesis, intestinal-type gastric adenocarcinoma develops through multistep mucosal changes from superficial gastritis to atrophic

¹Department of Gastroenterology, Kyoundo Hospital; ²Department of Gastroenterology, Graduate School of Medicine, the University of Tokyo;

³Department of Gastroenterology, Tokyo Metropolitan Police Hospital; ⁴Department of Gastroenterology, JR Tokyo General Hospital, Tokyo, Japan

Correspondence and reprints: Dr Takafumi Sugimoto, Department of Gastroenterology, Graduate School of Medicine, University of Tokyo,

7-3-1 Hongo, Bunkyo-ku, Tokyo 113-8655, Japan. Telephone 81-3-3815-5411 ext 33070, fax 81-3-3814-0021, e-mail sugimot-ky@umin.ac.jp

Received for publication March 4, 2015. Accepted March 7, 2015

TABLE 1
Baseline characteristics of 155 patients

	Total	Metachronous (n=23)	No recurrence (n=132)	P
Demographic characteristics				
Sex, male/female, n	119/36	20/3	99/33	0.19
Age, years, mean (range)	68.9 (50–83)	69.2 (57–80)	68.8 (50–83)	0.84
Follow-up period, years (range)	4.23 (1.02–10.8)	4.11 (1.05–7.35)	4.25 (1.02–10.8)	0.78
Outcome (alive/dead)	149/6	23/0	126/6	0.16
<i>Helicobacter pylori</i> status after endoscopic submucosal dissection, n (%)				
Negative	25 (16.1)	1 (4.3)	24 (18.1)	0.17
Eradication	100 (64.5)	17 (74.0)	83 (62.9)	
Persistent	30 (19.4)	5 (21.7)	25 (19.0)	
Histological characteristics, n (%)				
Intestinal metaplasia in the antrum	101 (65.2)	15 (65.2)	86 (65.2)	0.99
Intestinal metaplasia in the corpus	74 (47.7)	15 (65.2)	59 (44.7)	0.068
Neutrophil infiltration in the antrum	30 (19.4)	8 (34.8)	22 (16.7)	0.056
Neutrophil infiltration in the corpus	50 (32.3)	15 (65.2)	35 (26.5)	0.0004
Pepsinogen, ng/mL, mean (n=127)				
I	44.1	27.2	47.2	0.17
II	16.8	13.3	17.5	0.24
I/II	2.61	2.10	2.71	0.15
Tumour characteristics				
Location, upper/middle/lower, n	14/65/76	1/13/9	13/52/67	0.27
Size, mm, mean	15.7	20.3	14.9	0.0048
Macroscopic type, protruded/depressed, n	88/67	12/11	76/56	0.63
Pathology, adenoma/cancer, n	31/124	5/18	26/106	0.82

gastritis, intestinal metaplasia (IM) and dysplasia (18). Eradication of *H pylori* is a highly useful method of preventing primary and metachronous gastric cancers (19-21). We have reported previously that IM and neutrophil infiltration (NI) are high-risk microenvironments and risk factors for primary gastric cancers (22). However, the risk factors for metachronous cancers are unclear. Thus, the aim of the present study was to evaluate the risk factors for metachronous gastric cancers after ESD in a long-term follow-up.

METHODS

Patients

A total of 201 consecutive patients were treated using ESD at the University of Tokyo Hospital (Tokyo, Japan) between September 2000 and September 2009. All demographic data and endoscopic findings obtained before ESD were evaluated retrospectively from patient records. The location, macroscopic types and histological findings of the tumours were categorized according to the Japanese classification of gastric carcinoma (23). Expanded ESD criteria have been proposed by Gotoda et al (24). All patients were followed up for at least one year. Forty-six patients were excluded from the study: 19 did not meet the ESD specimen histology criteria and required additional surgery, five had remnant stomach cancers, nine were followed for up to one year, four did not have *H pylori* information and, in nine patients, ESD was performed before enrollment. The present study was approved by the Institutional Review Board of the University of Tokyo.

Disease assessment

Experienced endoscopists performed the gastrointestinal endoscopy procedures, and gastric cancer was diagnosed by histology. Biopsy specimens were obtained from the greater curvature of the antrum and middle corpus to evaluate gastric mucosal status including *H pylori*, IM and NI before ESD (22). Both a rapid urease test (Helicocheck, Otsuka Pharmaceuticals, Japan) and histopathological examination were performed. A positive result on at least one test was deemed to be evidence of *H pylori* infection. Blood samples were also collected before ESD to measure serum levels of pepsinogen I and II using ELISA kits (LS test Eiken Kagaku, Inc, Japan). ESD was performed as described previously

(8,9). Follow-up endoscopy after ESD for detection of metachronous gastric cancers was scheduled at two and six months, one year and annually thereafter. Lesions detected within one year of initial ESD were regarded as synchronous multiple lesions because microcancers may have been missed at the time of ESD (12,25). Metachronous gastric cancers were defined as new gastric cancers in different areas from the initial lesion and occurring at least one year after the initial ESD. Eradication of *H pylori* was recommended when possible. Metachronous gastric cancer was defined as the development of a new carcinoma in areas other than the primary gastric cancer site at least one year after ESD. *H pylori*-positive patients were treated with triple therapy consisting of 200 mg clarithromycin, 750 mg amoxicillin and 30 mg lansoprazole twice daily for one week after ER. Patients in whom *H pylori* was not eradicated were treated with second-line therapy consisting of 250 mg metronidazole instead of clarithromycin (26). Eradication was confirmed by a negative ¹³C-urea breath test (8,9).

Statistical analyses

Study subjects were categorized according to the presence of the metachronous gastric cancer. All analyses were performed using JMP version 9 (SAS Institute, USA). Student's *t* tests were used for intergroup comparison of mean age, follow-up period and tumour size. The other patient clinical characteristics and histopathological characteristics of the gastric mucosa and cancers were compared using the χ^2 test or Fisher's exact test, as appropriate. Relative risks for metachronous gastric cancer were calculated using the Cox proportional hazards model. Differences were considered to be statistically significant at the 5% probability level.

RESULTS

Baseline characteristics of the study subjects

Baseline clinical characteristics of the patients are summarized in Table 1. A total of 155 patients (119 men, 36 women, mean age 68.9 years) were followed for up to 10.8 years (mean 4.2 years). Six patients died during the study period, but none of the deaths were related to gastric cancer. Twenty-three (14%) patients developed metachronous gastric cancers (3.5% per year).

TABLE 2
Cumulative incidence of metachronous gastric cancer, univariate analysis*

	OR (95% CI)	P
Demographic characteristics		
Sex	1.78 (0.61–7.55)	0.32
Age	1.02 (0.96–1.08)	0.60
<i>Helicobacter pylori</i> status after ESD		
Negative	1	0.64
Eradication	2.56 (0.52–46.3)	0.30
Persistent	2.50 (0.40–48.3)	0.36
Histological characteristics		
Intestinal metaplasia in the antrum	0.99 (0.43–2.46)	0.97
Intestinal metaplasia in the corpus	3.00 (1.29–7.51)	0.010
Neutrophil infiltration in the antrum	1.89 (0.76–4.39)	0.16
Neutrophil infiltration in the corpus	3.47 (1.51–8.63)	0.0034
Pepsinogen (measured in 127 patients)		
I	0.98 (0.96–1.01)	0.11
II	0.96 (0.92–1.02)	0.18
I/II	0.83 (0.59–1.17)	0.28
Tumour characteristics		
Location		
Upper	1	0.29
Middle	2.26 (0.45–41.2)	0.38
Lower	1.21 (0.23–22.4)	0.85
Tumour size		
Macroscopic type (protruded/depressed)	1.05 (1.01–1.09)	0.021
Pathology (cancer/adenoma)	0.79 (0.35–1.83)	0.58
	1.18 (0.47–3.59)	0.73

*Cox proportional hazards model. ESD Endoscopic submucosal dissection

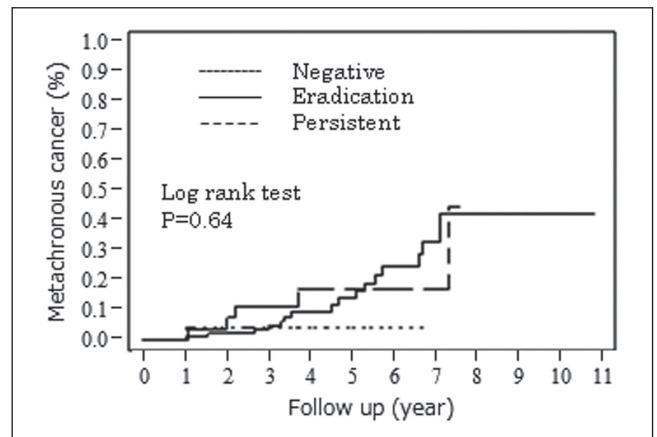


Figure 1 The cumulative incidence of metachronous gastric cancer. *Helicobacter pylori* status after endoscopic submucosal dissection

Of the 155 patients, 25 were *H pylori* negative, 27 had *H pylori* eradicated before ESD, 73 received eradication therapy and 30 experienced continuing *H pylori* infection. IM at the greater curvature of the antrum and middle corpus was observed in 101 (65.1%) and 74 (47.7%) patients, respectively. NI was observed in 30 (19.4%) and 50 (32.3%) patients, respectively.

Factors related to metachronous gastric cancers

The cumulative incidence of metachronous gastric cancer is summarized in Table 2, and Figures 1 and 2. The ORs for metachronous gastric cancers in IM and NI in the corpus were 3.00 (P=0.010) and 3.47 (P=0.0034). IM and NI in the corpus and tumour size were risk factors. Successful *H pylori* eradication did not contribute significantly to the reduction of risk for

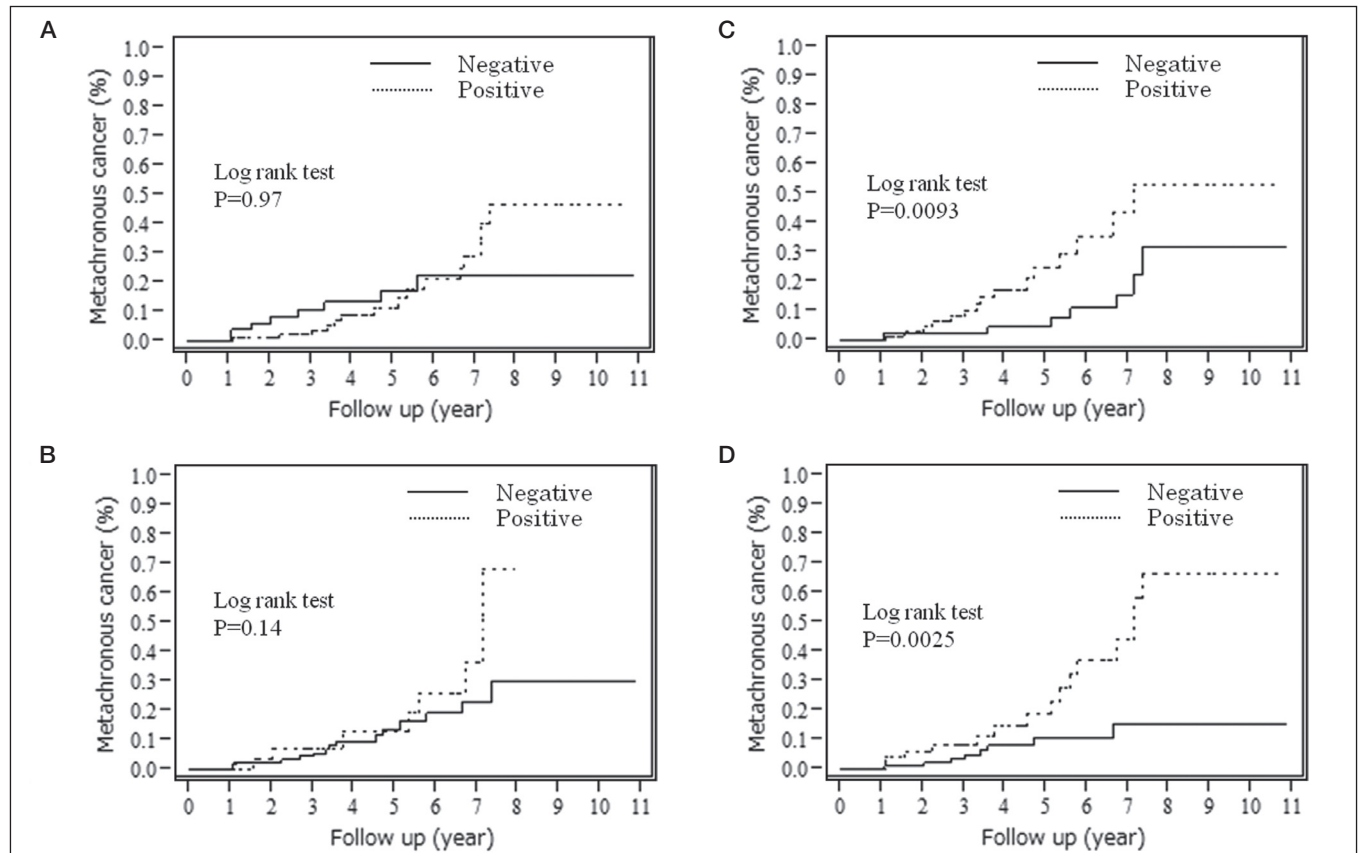


Figure 2 Cumulative incidence of metachronous gastric cancer. **A** Intestinal metaplasia in the antrum. **B** Intestinal metaplasia in the corpus. **C** Neutrophil infiltration in the antrum. **D** Neutrophil infiltration in the corpus

TABLE 3
Multivariate analysis* for metachronous gastric cancer

Variable	OR (95% CI)	P
Tumour size	1.03 (0.99–1.07)	0.20
Intestinal metaplasia in the corpus	2.65 (1.13–6.66)	0.024
Neutrophil infiltration in the corpus	3.06 (1.32–7.64)	0.0091

*Cox proportional hazards model

metachronous gastric cancer in the present analysis (OR 2.56 [95% CI 0.52 to 46.3]; P=0.30).

Multivariate analysis for metachronous gastric cancer

The multivariate analysis of tumour size, IM and NI in the corpus showed that IM and NI in the corpus were independent risk factors for metachronous gastric cancer (Table 3). The ORs for metachronous gastric cancer were 2.65 (95% CI 1.13 to 6.66; P=0.024) in the IM-positive group in the corpus and 3.06 (95% CI 1.32 to 7.64; P=0.0091) in the NI-positive group in the corpus.

DISCUSSION

The results of the present single-centre study involving 155 consecutive patients showed that IM and NI in the corpus were related to metachronous gastric cancer. IM and NI were high-risk microenvironments and risk factors for primary and metachronous gastric cancers. Not only *H pylori* eradication but also annual follow-up endoscopy may be important for improving the prognosis of patients with metachronous gastric cancer.

Although many studies of residual gastric cancer have been conducted (27,28), few reports of metachronous gastric cancers after ESD for early gastric cancer are available. The rate of recurrence of early gastric cancer in the gastric stump has been estimated to be 1% to 3% (13,29). An increased recurrence rate would be expected in patients treated with ESD, in proportion to the larger area of gastric mucosa remaining in these patients. Other studies have reported that the annual incidence of metachronous gastric cancer after EMR is 2.5% to 4% (12,20). In the present study, the annual incidence was approximately 3.5%.

In their randomized controlled study, Fukase et al (20) reported that eradicating *H pylori* reduced the risk for developing metachronous gastric cancer in patients treated with EMR. In our previous study, we reported that IM, NI and the gastritis pattern are related to developing primary gastric cancer (22). In the present study, our data revealed that IM and NI were also related to metachronous gastric cancer; however, no significant difference in *H pylori* status was observed. It has been suggested that a larger sample size would demonstrate a significant reduction in the incidence of metachronous gastric cancer after eradicating *H pylori*. Some studies have reported a significant reduction in cancer development following *H pylori* eradication in subgroups with mild atrophy or antrum-dominant atrophy (30,31). The preventive effect of *H pylori* eradication against gastric cancer may depend on the degree of baseline gastric mucosal atrophy and IM. Many patients in our study had IM, which may represent a point of no return at which the development of gastric cancer can no longer be prevented by eradicating *H pylori*.

In a previous study, we reported that NI in the corpus was related to prevalent diffuse-type gastric cancer (22). In that study, the diffuse type of the metachronous cancers were found in only two cases. A prospective study with a larger number is needed to elucidate the difference between diffuse type and intestinal type cancers.

The annual incidence of metachronous gastric cancer in the present study was 3.5%. The cumulative prevalence of gastric remnant cancer after surgical partial gastrectomy for early gastric cancer is reported to be 2.4% at five years. Patients with early gastric cancer after ESD treatment have been identified as a high-risk group for metachronous gastric cancer. If *H pylori* is eradicated, the NI status of gastric mucosa improves (32). However, IM of the gastric mucosa cannot easily be improved (33-36). Endoscopists should recognize the characteristics of metachronous gastric cancer and special attention should be devoted to detection of early gastric cancer.

Six patients died during the study period, but none of these deaths were related to gastric cancer. All patients with metachronous gastric cancer were treated completely with ESD or surgery. Annual endoscopy follow-up may be useful for detection of metachronous gastric cancer during the early stage and prevention of gastric cancer death.

A limitation of our study may be a retrospective cohort study in consecutive patients. A prospective study is needed to determine whether baseline histological characteristics can be predictive factors for metachronous gastric cancer and be used to determine the intensity of surveillance endoscopy among this patient population.

CONCLUSION

The presence of IM and NI in the corpus was closely related to the development of metachronous gastric cancer after ESD.

DISCLOSURES: The authors have no financial disclosures or conflicts of interest to declare.

ACKNOWLEDGEMENTS: The authors thank the gastroenterologists at the University of Tokyo Hospital for their endoscopic procedure. They are grateful to all the pathologists for their histopathological examinations on our subjects.

REFERENCES

- Curvers WL, van den Broek FJ, Reitsma JB, et al. Systematic review of narrow-band imaging for the detection and differentiation of abnormalities in the esophagus and stomach (with video). *Gastrointest Endosc* 2009;69:307-17.
- Polkowski M. Endoscopic diagnosis and treatment of upper gastrointestinal tumors. *Endoscopy* 2008;40:862-7.
- Kakushima N, Fujishiro M. Endoscopic submucosal dissection for gastrointestinal neoplasms. *World J Gastroenterol* 2008;21;14:2962-7.
- Yamamoto H. Technology insight: Endoscopic submucosal dissection of gastrointestinal neoplasms. *Nat Clin Pract Gastroenterol Hepatol* 2007;4:511-20.
- Gotoda T. Endoscopic resection of early gastric cancer. *Gastric Cancer* 2007;10:1-11.
- Soetikno R, Kaltenbach T, Yeh R, et al. Endoscopic mucosal resection for early cancers of the upper gastrointestinal tract. *J Clin Oncol* 2005;23:4490-8.
- Takenaka R, Kawahara Y, Okada H, et al. Risk factors associated with local recurrence of early gastric cancers after endoscopic submucosal dissection. *Gastrointest Endosc* 2008;68:887-94.
- Isomoto H, Shikuwa S, Yamaguchi N, et al. Endoscopic submucosal dissection for early gastric cancer: A large-scale feasibility study. *Gut* 2009;58:331-6.
- Sugimoto T, Okamoto M, Mitsuno Y, et al. Endoscopic submucosal dissection is an effective and safe therapy for early gastric neoplasms: A multicenter feasible study. *J Clin Gastroenterol* 2012;46:124-9.
- Jang JS, Choi SR, Qureshi W, et al. Long-term outcomes of endoscopic submucosal dissection in gastric neoplastic lesions at a single institution in South Korea. *Scand J Gastroenterol* 2009;44:1315-22.
- Choi KS, Jung HY, Choi KD, et al. EMR versus gastrectomy for intramucosal gastric cancer: comparison of long-term outcomes. *Gastrointest Endosc* 2011;73:942-8.
- Nasu J, Doi T, Endo H, et al. Characteristics of metachronous multiple early gastric cancers after endoscopic mucosal resection. *Endoscopy* 2005;37:990-3.
- Hosokawa O, Kaizaki Y, Watanabe K, et al. Endoscopic surveillance for gastric remnant cancer after early cancer surgery. *Endoscopy* 2002;34:469-73.
- Nomura A, Stemmermann GN, Chyou PH, et al. *Helicobacter pylori* infection and gastric carcinoma among Japanese Americans in Hawaii. *N Engl J Med* 1991;325:1132-6.
- Parsonnet J, Friedman GD, Vandersteen DP, et al. *Helicobacter pylori* infection and the risk of gastric carcinoma. *N Engl J Med* 1991;325:1127-31.

16. Eslick GD, Lim LL, Byles JE, et al. Association of *Helicobacter pylori* infection with gastric carcinoma: A meta-analysis. *Am J Gastroenterol* 1999;94:2373-9.
17. Uemura N, Okamoto S, Yamamoto S, et al. *Helicobacter pylori* infection and the development of gastric cancer. *N Engl J Med* 2001;345:784-9.
18. Correa P. Human gastric carcinogenesis: A multistep and multifactorial process – First American Cancer Society Award Lecture on Cancer Epidemiology and Prevention. *Cancer Res* 1992;52:6735-40.
19. Wong BC, Lam SK, Wong WM, et al. *Helicobacter pylori* eradication to prevent gastric cancer in a high-risk region of China: A randomized controlled trial. *JAMA* 2004;291:187-94.
20. Fukase K, Kato M, Kikuchi S, et al. Effect of eradication of *Helicobacter pylori* on incidence of metachronous gastric carcinoma after endoscopic resection of early gastric cancer: An open-label, randomised controlled trial. *Lancet* 2008;372:392-7.
21. Ogura K, Hirata Y, Yanai A, et al. The effect of *Helicobacter pylori* eradication on reducing the incidence of gastric cancer. *J Clin Gastroenterol* 2008;42:279-83.
22. Sakitani K, Hirata Y, Watabe H, et al. Gastric cancer risk according to the distribution of intestinal metaplasia and neutrophil infiltration. *J Gastroenterol Hepatol* 2011;26:1570-5.
23. Association JGC. Japanese classification of gastric carcinoma: Third English edition. *Gastric Cancer* 2011;14:101-12.
24. Gotoda T, Yanagisawa A, Sasako M, et al. Incidence of lymph node metastasis from early gastric cancer: Estimation with a large number of cases at two large centers. *Gastric Cancer* 2000;3:219-25.
25. Mitsudomi T, Watanabe A, Matsusaka T, et al. A clinicopathological study of synchronous multiple gastric cancer. *Br J Surg* 1989;76:237-40.
26. Maehata Y, Nakamura S, Fujisawa K, et al. Long-term effect of *Helicobacter pylori* eradication on the development of metachronous gastric cancer after endoscopic resection of early gastric cancer. *Gastrointest Endosc* 2012;75:39-46.
27. Kaneko K, Kondo H, Saito D, et al. Early gastric stump cancer following distal gastrectomy. *Gut* 1998;43:342-4.
28. Ohashi M, Katai H, Fukagawa T, et al. Cancer of the gastric stump following distal gastrectomy for cancer. *Br J Surg* 2007;94:92-5.
29. Takeda J, Toyonaga A, Koufujii K, et al. Early gastric cancer in the remnant stomach. *Hepatogastroenterology* 1998;45:1907-11.
30. Shiotani A, Uedo N, Iishi H, et al. Predictive factors for metachronous gastric cancer in high-risk patients after successful *Helicobacter pylori* eradication. *Digestion* 2008;78:113-9.
31. Yanaoka K, Oka M, Ohata H, et al. Eradication of *Helicobacter pylori* prevents cancer development in subjects with mild gastric atrophy identified by serum pepsinogen levels. *Int J Cancer* 2009;125:2697-703.
32. Tari A, Kitadai Y, Sumii M, et al. Basis of decreased risk of gastric cancer in severe atrophic gastritis with eradication of *Helicobacter pylori*. *Dig Dis Sci* 2007;52:232-9.
33. Ito M, Haruma K, Kamada T, et al. *Helicobacter pylori* eradication therapy improves atrophic gastritis and intestinal metaplasia: A 5-year prospective study of patients with atrophic gastritis. *Aliment Pharmacol Ther* 2002;16:1449-56.
34. Kodama M, Murakami K, Okimoto T, et al. *Helicobacter pylori* eradication improves gastric atrophy and intestinal metaplasia in long-term observation. *Digestion* 2012;85:126-30.
35. Forbes GM, Warren JR, Glaser ME, et al. Long-term follow-up of gastric histology after *Helicobacter pylori* eradication. *J Gastroenterol Hepatol* 1996;11:670-3.
36. Satoh K, Kimura K, Takimoto T, et al. A follow-up study of atrophic gastritis and intestinal metaplasia after eradication of *Helicobacter pylori*. *Helicobacter* 1998;3:236-40.