

Renal clear cell carcinoma with thyroid and parotid metastases: A case report

JIA-LI SHI¹, JIA-QING ZHOU² and JI-PING LI¹

Departments of ¹Otorhinolaryngology and ²Head and Neck Surgery, Renji Hospital, School of Medicine, Shanghai Jiaotong University, Shanghai, P.R. China

Received October 4, 2014; Accepted June 23, 2015

DOI: 10.3892/ol.2015.3549

Abstract. The present study reports a rare case of a renal clear cell carcinoma with thyroid and parotid metastases. A 56-year-old female, with a painless, right preauricular mass present for 6 months was referred to Renji Hospital (Shanghai, China). Physical examination revealed a mass of 3x3 cm, which was smooth, firm, immobile and non-tender. There was no accompanying facial weakness. Parotid ultrasonography revealed a hypoechoic mass within the right parotid gland, which was potentially a parotid mixed tumor. In July 2011, the patient underwent a superficial parotidectomy with preservation of the facial nerve. Pathology confirmed as right parotid clear cell carcinoma (metastasis). The patient's relevant medical history included a right radical nephrectomy for renal clear cell carcinoma (clinical stage III) in 2004. Additionally, in 2009, the patient underwent a resection of thyroid metastatic renal cell carcinoma. To the best of our knowledge, no similar case has previously been reported in English-language literature. The present study discusses a case report, and investigates the clinical features and treatment strategy.

Introduction

Clear cell carcinoma, which is common amongst males aged 50-60 years, accounts for 80-85% of adult renal malignant tumors. The 5-year survival rate following surgery is 50%, and reduces to <5% in patients with distant metastases. Renal cell carcinoma (RCC) is associated with a high metastatic

potential, and the most frequent sites of RCC metastasis include the lungs, bone, liver and skin (1). RCC metastases to the head and neck region are less common, comprising 8-14% of metastatic cases. Within the head and neck region, the thyroid gland is the most common site of RCC metastasis, while parotid gland metastasis is particularly rare. To the best of our knowledge, no similar case has previously been reported in English-language literature. The present study comprises a case report to investigate the clinical features and treatment experience of a patient with renal clear cell carcinoma with thyroid and parotid metastases. Written informed consent was provided by the patient.

Case report

A 56-year-old female, with a right preauricular painless mass present for six months, was referred to the Department of Otorhinolaryngology Head and Neck Surgery (now two separate departments), Renji Hospital, Shanghai Jiaotong University School of Medicine (Shanghai, China). Physical examination revealed a mass of 3x3 cm, which was smooth, firm, immobile and non-tender. There was no facial weakness, and no enlarged cervical lymph nodes or submandibular lymph nodes were detected. Laboratory tests revealed that blood, liver and kidney function were normal. Parotid ultrasonography identified a hypoechoic mass within the right parotid gland, and a potential diagnosis of parotid mixed tumor was suggested. In July 2011, the patient underwent an superficial parotidectomy with preservation of the facial nerve. A 2-cm diameter, easy bleeding, encapsulated tumor with a clear border was identified in the right superficial lobe of the parotid gland. The border of the tumor remained clear, without adhesion of the facial nerve. Pathology confirmed the tumor to be right parotid clear cell carcinoma (metastasis). Immunohistochemical analysis revealed positive reactions for cytokeratin (CK), vimentin, CK8 and Rcc, whereas stains for CD10, von Hippel-Lindau tumor suppressor, E3 ubiquitin protein ligase, Ki-67 and actin were negative (Fig. 1).

The patient's relevant medical history included a radical right nephrectomy for renal clear cell carcinoma (clinical stage III) in 2004. Immunohistochemical examination of the renal tumor indicated: CK8 (+), vimentin (+), CD10 (+), CK19 (-), CK7 (-) and α -methylacyl-CoA racemase (AmACR) (-). The patient received chemotherapy (5-Fluorouracil + α -interferon + interleukin-2)

Correspondence to: Dr Jia-Qing Zhou, Department of Head and Neck Surgery, Renji Hospital, School of Medicine, Shanghai Jiaotong University, 145 Shandong Middle Road, Shanghai 200025, P.R. China
E-mail: jqzhou03@163.com

Dr Ji-Ping Li, Department of Otorhinolaryngology, Renji Hospital, School of Medicine, Shanghai Jiaotong University, 160 Pujian Road, Shanghai 200127, P.R. China
E-mail: drlijiping@163.com

Key words: renal clear cell carcinoma, thyroid metastasis, parotid metastasis

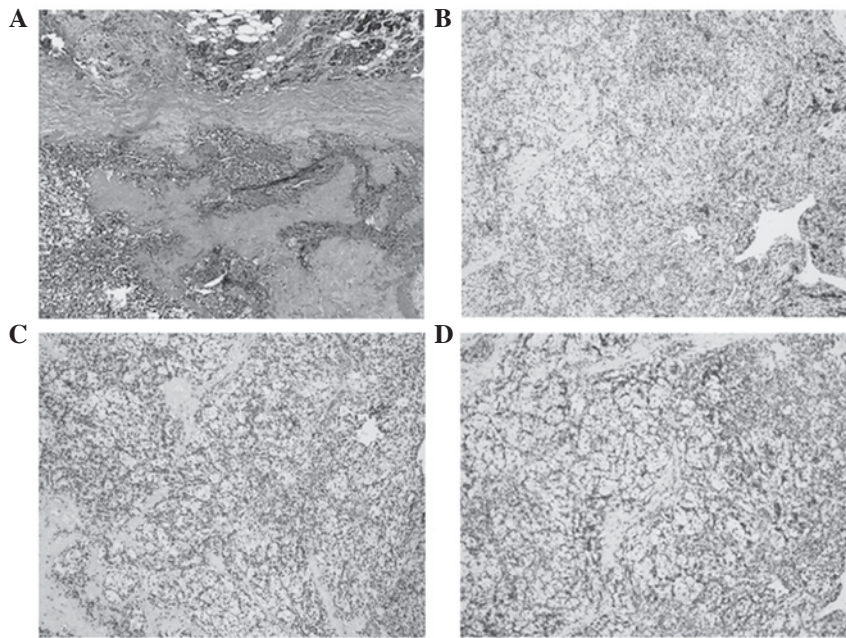


Figure 1. Pathological examination of the parotid gland resected during surgery in 2011. (A) Hematoxylin and eosin staining; (B) CD immunohistochemical staining; (C) cytokeratin immunohistochemical staining and (D) vimentin immunohistochemical staining in parotid tissue (magnification, x100).




Figure 2. Pathological examination of the thyroid tissue resected during surgery in 2009. (A) Hematoxylin and eosin staining in thyroid tissue; (B) CD immunohistochemical staining in thyroid tissue and (C) vimentin immunohistochemical staining in thyroid tissue (magnification, x100).

following surgery. In addition, the patient underwent a resection of thyroid metastatic renal cell carcinoma in 2009. Immunohistochemical examination following surgery indicated the following: Rcc (+), AmACR (-), vimentin (+++), CK (-), TPO (-), CK19 (-), galectin-3 (+++) and CD10 (++) (Fig. 2). The patient did not receive postoperative radiotherapy and/or chemotherapy. The patient was followed-up for 2 years following surgery, with no tumor metastasis detected.

Discussion

RCC accounts for ~3% of all malignant tumors (2). Metastasis is common in patients with RCC; common sites of RCC metastasis include the lungs, lymph nodes, bone and liver. However, metastases to the head and neck region are less common. The thyroid gland is the most common site of RCC metastasis within the head and neck region, however, metastasis to the parotid gland is rare. The present study reported the case of a RCC patient with thyroid and parotid metastases, which to the best of our knowledge, is the first case to be reported in the literature. Physical examination 56-year-old female patient

revealed a 3-cm diameter, smooth, high-tension immobile mass in the right preauricular region. There was no facial paralysis and no enlarged cervical lymph nodes were detected. Parotid ultrasonography identified a hypoechoic mass within the right parotid gland and a potential diagnosis of parotid mixed tumor was suggested. All other tests were normal. In July 2011, the patient underwent a superficial parotidectomy with preservation of the facial nerve. During surgery, a 2-cm diameter, crispy, easy bleeding, encapsulated tumor was identified in the right superficial lobe of the parotid gland. To the best of our knowledge, no similar case has previously been reported.

The thyroid gland has a rich blood supply (3). According to autopsy studies, the incidence of metastasis to the thyroid is 1.9-24.2% amongst patients who succumb to malignant tumors of other primary sites (4,5). Breast and lung cancer, as well as malignant melanomas, are the most frequently identified malignant neoplasms, which generate secondary cancer of the thyroid (6,7). Although RCCs were previously considered to be another cancer which may metastasize to the thyroid, this is a rare occurrence in clinical practice. The present

study identified few reports of renal clear cell carcinoma with thyroid metastases published in the English-language literature. Thyroid metastasis of renal clear cell carcinoma must be distinguished from primary thyroid clear cell carcinoma. Certain scholars have suggested that primary thyroid carcinoma is a variation of thyroid follicular carcinoma, and the clear cells in the carcinoma are the result of stimulation by thyroid-stimulating hormone (8). In addition to possessing a similar cellular morphology, the tumor cells, sheets and cords are separated by fibrous tissue. Sections of tumor tissue exhibit a small follicular structure and glial nodules. The most appropriate method for the diagnosis of thyroid metastatic carcinoma is preoperative fine needle aspiration cytology (9). In addition, the primary site may be identified using specific immunohistochemical staining with antibodies against CD10, CK and vimentin, to confirm metastatic RCC through pathological detection, particularly in the lung and thyroid (10). Currently, total thyroidectomy for treatment with combined therapy is recommended for patients with renal carcinoma metastasis of the thyroid, particularly those which grow slowly and exhibit no other evidence of distant metastasis (11).

Salivary gland metastasis of renal clear cell carcinoma is particularly rare. Malignant parotid gland tumors account for ~29% of parotid masses. Metastases to the parotid gland are uncommon, and most frequently originate from head and neck squamous cell carcinomas or melanomas of the skin (12). Parotid metastasis from RCC is very rare, accounting for only 0.5% of renal metastases (13). According to the literature, parotid metastasis may occur prior to or following primary treatment for RCC (14). The major symptom is often a painless parotid mass, as observed in the present case. Currently, ultrasonic examination has become the first choice in the diagnosis of parotid tumors as it is cheap, non-invasive and harmless (15). Yu reported that the correct rate of ultrasound diagnosis of parotid tumor was 78.6% (16). The ultrasonic characteristics of the present case were similar to those of a benign tumor, which indicated the risk of potential misdiagnosis. The present author suggested that ultrasound-guided fine needle aspiration cytology and the patient's medical history should be taken into consideration, particularly when it is difficult to distinguish between benign and malignant tumors. It is also crucial to distinguish between parotid metastases and primary cancer. Pathological examination, immunohistochemistry with antibodies against CD10, CK and vimentin, as well as systemic examination revealed that the primary kidney tumor was identifiable. For parotid metastasis from renal cell carcinoma without other metastases, the recommended therapy is superficial parotidectomy with the preservation of the facial nerve (12). When the parotid gland has invaded the surrounding tissue, the

scope of the parallel operation requires expansion to include elective lymph node dissection (II-V area).

Thyroid metastasis were identified in the present patient 4 years following radical nephrectomy and parotid gland metastasis were subsequently identified 6 years following surgery. It was therefore suggested that RCC patients require long-term follow-up, to facilitate early detection of metastasis and early comprehensive treatment.

References

1. Dekernion JB, Ramming KP and Smith RB: The natural history of metastatic renal cell carcinoma: A computer analysis. *J Urol* 120: 148-152, 1978.
2. Ohba K, Miyata Y, Mitsunari K, *et al*: Left atrial metastasis of renal cell carcinoma: A case report and review of the literature. *BMC Res Notes* 7: 520, 2014.
3. Chen H, Nicol TL and Udelsman R: Clinically significant, isolated metastatic disease to the thyroid gland. *World J Surg* 23: 177-180, 1999.
4. Abrams HL, Spiro R and Goldstein N: Metastases in carcinoma: Analysis of 1000 autopsied cases. *Cancer* 3: 74-85, 1950.
5. Shimaoka K, Sokal JE and Pickren JW: Metastatic neoplasms in the thyroid gland. Pathological and clinical findings. *Cancer* 15: 557-565, 1962.
6. Chung AY, Tran TB, Brumund KT, Weisman RA and Bouvet M: Metastases to the thyroid: A review of the literature from the last decade. *Thyroid* 22: 258-268, 2012.
7. Lam KY and Lo CY: Metastatic tumors of the thyroid gland: A study of 79 cases in Chinese patients. *Arch Pathol Lab Med* 122: 37-41, 1998.
8. Vatiakojis D, Getz ML, Paloyan E and Straus FH: Papillary clear cell carcinoma of the thyroid gland. *Hun Pathol* 6: 384-390, 1975.
9. Morgan JL, Serpell JW and Cheng MS: Fine-needle aspiration cytology of thyroid nodules: How useful is it? *Anz J Surg* 73: 480-483, 2003.
10. Mrena R, Leivo I, Passador-Santos F, Hagström J and Mäkitie AA: Histopathological findings in parotid gland metastases from renal cell carcinoma. *Eur Arch Otorhinolaryngol* 265: 1005-1009, 2008.
11. Kihara M, Yokomise H and Yamauchi A: Metastasis of renal cell carcinoma to the thyroid gland 19 years after nephrectomy: A case report. *Auris Nasus Larynx* 31: 95-100, 2004.
12. Park YW and Hlivko TJ: Parotid gland metastasis from renal cell carcinoma. *Laryngoscope* 112: 453-356, 2002.
13. Pisani P, Angeli G, Krangli M and Pia F: Renal carcinoma metastasis to the parotid gland. *J Laryngol Otol* 104: 352-354, 1990.
14. Göğüş C, Kiliç O, Tulunay O, Tulunay O and Bedük Y: Solitary metastasis of renal cell carcinoma to the parotid gland 10 years after radical nephrectomy. *Int J Urol* 11: 894-896, 2004.
15. Chen XY, Long X, Qian SS, *et al*: The clinical significance of the use of ultrasonography in the diagnosis of parotid tumors. *J Clin Stomatol* 18: 448-449, 2002 (In Chinese).
16. Yu GY (ed): *Salivary Gland Diseases*. Beijing Medical University Press, Beijing, 1994.