

# Efficacy risks of the minimal-invasive plastic and reconstructive neovagina Vecchiatti technique in Mayer-Rokitansky-Küster-Hauser syndrome

## Effizienzrisiken der minimal-invasiven plastischen und rekonstruktiven Neovagina Vecchiatti-Technik bei Mayer-Rokitansky-Küster-Hauser-Syndrom

### Abstract

**Introduction:** Mayer-Rokitansky-Küster-Hauser (MRKH) syndrome is a congenital disorder clinically defined by primary amenorrhea and infertility, congenital aplasia of the uterus and upper vagina. The patients with MRKH-syndrome have a female karyotype (46, XX), normally functioning ovaries and regular development of secondary sexual characters. Generally, the initial clinical sign of the syndrome is the failure to begin the menstrual cycle. Even though the psychological impact of the disease may be overwhelming, its physiological disorder can be successfully treated, after the surgical intervention the patients being able to have a normal sexual function. Reproduction may also be possible with assisted techniques.

**Objective:** The aim of the study was to evaluate the efficacy risks of the traditional laparoscopic Vecchiatti method in the plastic and reconstructive treatment of vaginal agenesis, documenting complications, as well as anatomical and functional results by means of a prospective, single center, single arm study.

**Material and methods:** Between 2003 and 2011, 53 patients with MRKH-syndrome were treated in the gynecological clinic of the Kochi's Lakshmi Hospital, Kerala, India. All the patients suffered from primary amenorrhea and the karyotype was (46, XX). The clinical suspicion was confirmed sonographically and intraoperatively, showing an absent uterus or the presence of rudimentary uterine horns, with normal ovaries. All the patients received a plastic laparoscopic neovagina construction, in order to achieve a satisfactory sexual function. We adopted a combined strategy: the patients were prepared by a psychological counselling, followed by the surgical intervention and a postoperative follow-up. The surgical procedure used in this series was a laparoscopic modified Vecchiatti's technique. All the patients were dismissed with the obligation to have intercourse and/or vaginal dilation 3 times a week for 6 months.

**Results:** The patients' ages varied between 13 and 40 years, with a mean age of 25 years. The mean operation time was 42.3 minutes, with a range between 36 and 63 minutes. In 2 cases, an intraoperative bladder injury occurred. A good qualitative vaginal tissue was clinically achieved in all the patients. The mean follow up period of the patients was 4 years ranging from 1 to 5 years. The anatomic success was observed in 94% of the cases and functional success in 79%.

**Conclusion:** The anatomical failures in 6% were in women not having regular intercourse or not performing vaginal dilatation postoperatively. The psychological impact of the disease in combination with the performed surgery seems responsible for the difference of 15% of the cases where the anatomical result was good, but no regular intercourse could be achieved. The minimal-invasive plastic and reconstructive

Cristina Cezar<sup>1</sup>

Rajesh Devassy<sup>2</sup>

Angelika Larbig<sup>1</sup>

Rudy Leon De Wilde<sup>1</sup>

1 University Hospital for Gynecology, Pius-Hospital Oldenburg, School of Medicine and Health Sciences, Carl von Ossietzky University Oldenburg, Oldenburg, Germany

2 GEM CLINIC Elamkulam, Kochi, India

neovagina Vecchiatti technique in MRKH-syndrome has a high success rate. In case of an intraoperative urinary bladder injury, the repair can be performed laparoscopically during the same session. Qualitatively good vaginal tissue and anatomical reconstruction can easily be achieved. In one patient desiring assisted reproductive medicine, a transvaginal oocyte retrieval was achieved.

**Keywords:** Mayer-Rokitansky-Küster-Hauser syndrome, Vecchiatti technique, laparoscopic neovagina, sexual function, efficacy risks

## Zusammenfassung

**Einleitung:** Das Mayer-Rokitansky-Küster-Hauser (MRKH)-Syndrom ist eine angeborene Fehlbildung, klinisch charakterisiert durch primäre Amenorrhö und Infertilität, kongenitale Aplasie des Uterus und der oberen Vagina. Die Patientinnen haben einen weiblichen Karyotyp (46, XX), normale ovarielle Funktion und reguläre Entwicklung der sekundären Geschlechtsmerkmale. Das erste Anzeichen des Syndroms ist normalerweise, dass der Menstruationszyklus nicht einsetzt. Die psychische Belastung des Syndroms kann überwältigend sein, die körperlichen Störungen können aber durch chirurgische Intervention erfolgreich behandelt werden. Der chirurgische Eingriff ermöglicht eine normale sexuelle Funktion. Es ist auch eine assistierte Reproduktion möglich.

Das Studienziel ist die Überprüfung der Effizienzrisiken bei der traditionellen laparoskopischen Vecchiatti-Methode in der plastischen und rekonstruktiven Chirurgie der vaginalen Agenesie. Es wurde eine prospektive, single-center, single-arm Studie durchgeführt, und Komplikationen sowie anatomische und funktionelle Ergebnisse wurden dokumentiert.

**Material und Methodik:** Die Studie wurde zwischen 2003 und 2011 in der gynäkologischen Klinik von Kochi's Lakshmi Hospital, Kerala in Indien durchgeführt, an der 53 Patientinnen mit dem MRKH Syndrom teilnahmen. Alle Patientinnen hatten primäre Amenorrhö und der Karyotyp war (46, XX). Die klinische Verdachtsdiagnose wurde ultrasonographisch und operativ bestätigt: Agenesie des Uterus oder rudimentäre Uterushörner und normale Eierstöcke. Alle Patientinnen haben eine plastische laparoskopische Konstruktion einer Neovagina erhalten. Wir führten eine kombinierte Behandlungsstrategie durch: eine präoperative psychologische Beratung, gefolgt von einem chirurgischen Eingriff und postoperativen Follow-up. Es wurde eine laparoskopisch modifizierte Vecchiatti-Methode durchgeführt. Alle Patientinnen wurden bei der Entlassung über die Notwendigkeit sexueller vaginaler Aktivitäten sowie einer vaginalen Dilatation 3x pro Woche für insgesamt 6 Monate aufgeklärt.

**Ergebnisse:** Der Altersdurchschnitt betrug 25 (13–40) Jahre und die durchschnittliche Operationsdauer betrug 42,3 (36–63) Minuten. Zwei Blasenläsionen wurden intraoperativ identifiziert und in der gleichen Sitzung verschlossen. Eine gute Qualität des vaginalen Gewebes wurde in allen Fällen erreicht. Die durchschnittliche Dauer der Follow-up-Dokumentation betrug 4 (1–5) Jahre. Die anatomische Erfolgsrate betrug 94% und die funktionelle Erfolgsrate 79%.

**Fazit:** Die minimal-invasive plastische und rekonstruktive Neovagina Vecchiatti-Methode beim MRKH-Syndrom hat eine hohe Erfolgsrate. Im Falle einer intraoperativen Harnblaseneröffnung kann der Verschluss unmittelbar laparoskopisch in der gleichen Sitzung erfolgen. Gutes Neovaginalgewebe und eine erfolgreiche anatomische Rekonstruktion können mit der Methode erreicht werden. Assistierte Reproduktionsmedizin ist durch transvaginale Eizellgewinnung möglich. Die anatomischen Misserfolge von 6% traten bei Patientinnen ohne postoperativen, regelmäßigen Geschlechtsverkehr oder selbst durchgeführte vaginale Dilatation auf. Der Unterschied von 15% bei Patienten mit einem guten

anatomischen Ergebnis, die jedoch keinen regelmäßigen postoperativen Geschlechtsverkehr hatten, scheint in der psychologischen Belastung der Erkrankung zusammen mit dem operativen Eingriff begründet zu sein.

**Schlüsselwörter:** Mayer-Rokitansky-Küster-Hauser-Syndrom, Vecchietti-Methode, laparoskopische Neovagina, sexuelle Funktion, Effizienzrisiken

## Introduction

The Mayer-Rokitansky-Küster-Hauser (MRKH) syndrome [1] defines a congenital malformation characterized by vaginal aplasia, which can be associated with other müllerian (paramesonephric) ducts abnormalities [2]. There are two types of the syndrome that can be distinguished: type I describes an isolated absence of the proximal two thirds of vagina and type II a complex syndrome or MURCS association (müllerian duct aplasia, renal dysplasia and cervical somite anomalies) [3].

The uterus, cervix and the upper two thirds of the vagina form from the fused caudal ends of the müllerian ducts. In MRKH-syndrome, between 5 and 6 weeks of gestation, the müllerian ducts stop its development, which leads to a failure of the uterine and vaginal formation. The fallopian tubes develop from the unfused upper ends and the renal system from the wolffian ducts (mesonephric). The ovaries derive from the primitive ectoderm; therefore their function is preserved and the secondary sexual characters are normal.

The feasibility and effectiveness of the Vecchietti's technique in creating a neovagina for the women with Rokitansky syndrome was proven by several reports and studies published [4], [5], [6]. The laparoscopic approach gained vast improvements of the instrumentarium and of the technique itself since it was first described in the early 1990's [7], [8], [9], [10].

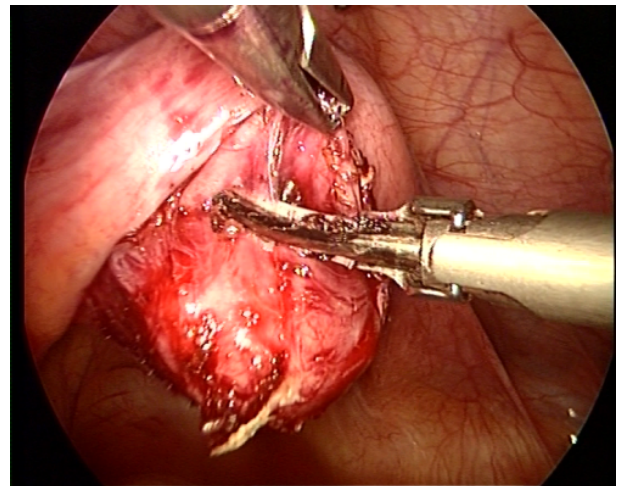
The present study describes the efficacy risks of the minimal-invasive neovagina Vecchietti technique concerning surgical, anatomical and functional results.

## Material and methods

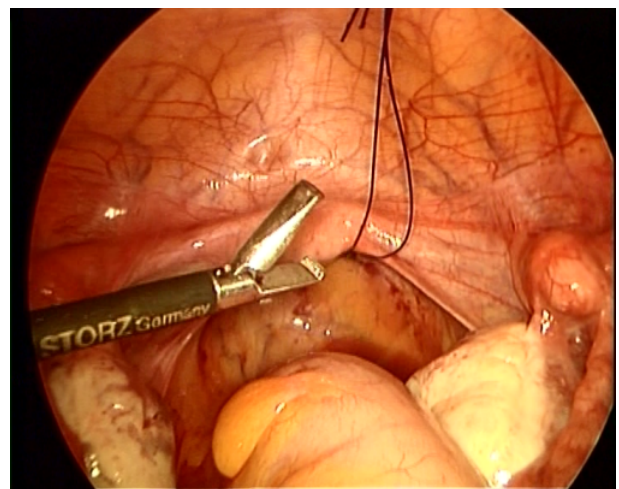
Between 2003 and 2011, 53 patients with MRKH-syndrome were treated in the gynecological clinic of the Kochi's Lakshmi Hospital, Kerala, India. All the patients suffered from primary amenorrhea and the karyotype was (46, XX). All patients with a clinically confirmed MRKH-syndrome, wanting a reconstruction of the vagina, were consecutively taken into the study. The minimal-invasive laparoscopic surgery was undertaken in general anesthesia [11], [9].

The Vecchietti's needle is introduced through abdominal wall and then directed subperitoneally to the fold between bladder and uterine rudiment. Further, the cutting needle is directed from lateromedial to craniocaudal in order to cross the space between bladder and rectum and to reach the pseudohymen (Figure 1). Two non-resorbable sutures

are passed through this membrane and tied on the vaginal mould. Suprapubically 2 incisions of 5 mm are made, throughout Maryland dissectors are tracked extraperitoneally. The sutures are withdrawn through these tracks and brought outward through the abdominal wall (Figure 2 and Figure 3). The peritoneal defect is closed at the site of dissected pelvic space. Ultimately, the threads are attached to the traction device (Figure 4) and adjusted every 5 days to pull up the mould expanding the neovagina (Figure 5). Intraoperatively a cystoscopy and rectoscopy are performed in order to detect the possible injuries of the bladder or rectum.



**Figure 1:** Dissection of rudimentary vaginal fold in the modified laparoscopic plastic and reconstructive neovagina technique



**Figure 2:** Externalisation of the threads in the neovagina technique (1)

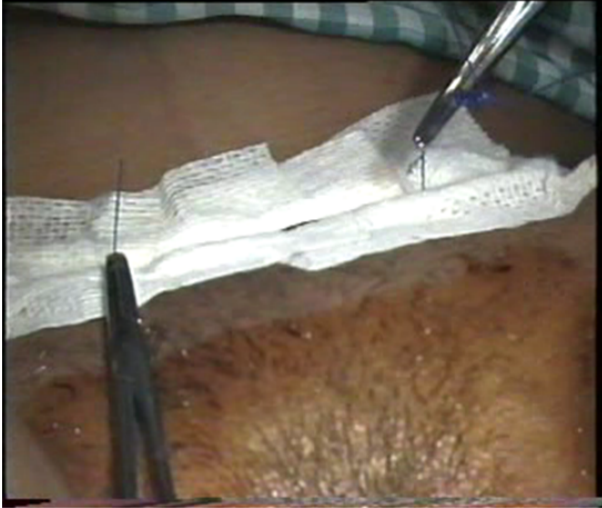


Figure 3: Externalisation of the threads in the neovagina technique (2)

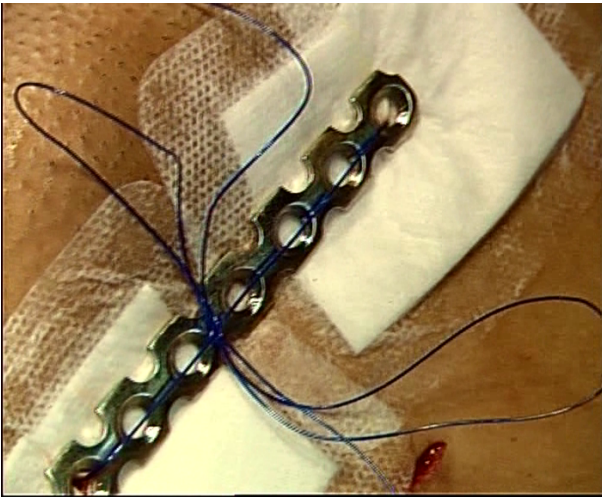


Figure 4: The traction device in the minimal-invasive plastic and reconstructive neovagina surgery

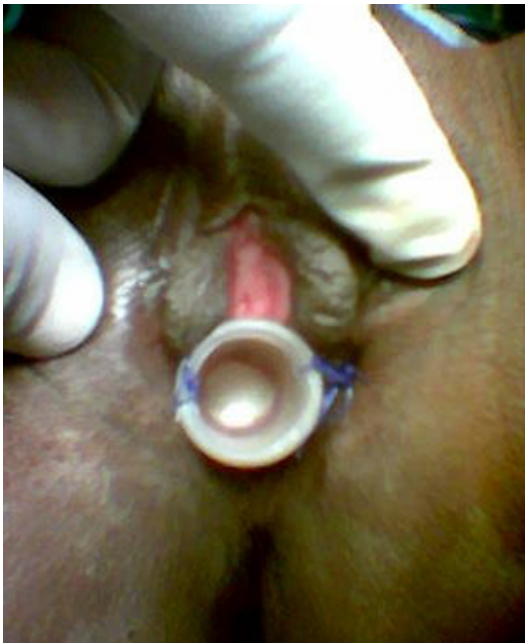

Figure 5: The vaginal mould in neovagina reconstruction

After approximately two weeks, the neovagina reached 6 cm or more in length and the traction device was removed. The neovagina was maintained postoperatively by intercourse or using vaginal dilators of increasing diameter as originally described 3 times a week for about 24 weeks [4].

## Results

The demographic characteristics of the patients included in the study are underlined in the Table 1. The age varied between 13 and 40, with a mean of 25 years. There were no associated urinary or skeletal anomalies observed. The average operation time was 42.3 and ranged between 36 and 63 minutes. As intraoperative complications, two bladder injuries were detected and immediately laparoscopically closed. These patients received a urinary bladder catheter for one week. Postoperative recovery was quickly and the patients were discharged home generally after three days. No major postoperative complications were encountered.

Table 1: Clinical and surgical description of the neovagina patients

Characteristics	Number of patients
Age of the patients	13–20 years: 11 20–30 years: 37 30–40 years: 5
Associated urinary or skeletal anomalies	None
Mean operation time	42.3 min (36–63 min)
Intraoperative complications	2 bladder injuries
Immediate postoperative complications	None

*Anatomical success* was defined by obtaining a neovagina of at least 6 cm in length, allowing an easy introduction of two fingers, 6 months after surgery and postoperative dilatating [12]. *Functional success* was considered when the patient reported regular vaginal intercourse [12]. Afterwards in all the patients a good tissue quality was obtained, the neovaginal epithelium being macroscopically similar to normal vaginal mucosa. The newly formed vaginal epithelium was fortified by the use of estrogen cream as a continuous therapy. Anatomic success was observed in 50 of 53 patients (94.3%), the length of the neovagina being  $\geq 6$  cm. In 3 cases, reported in young patients (13–20 years) the neovagina depth was insufficient ( $< 5$  cm); these 3 patients also declared not to have vaginal intercourse or postoperative dilatations. Penile contusions were present in 2 of these cases, and 3 of them had bleeding after vaginal intercourse (Table 2). Out of the 53 patients, 42 had regular sexual activity and 25 of them had orgasmic intercourse. One of the patients opted for assisted reproductive medicine: transvaginal oocyte retrieval and embryo transfer were performed

without any adverse events with the surrogate mother delivering healthy twins (Table 3).

**Table 2: Sexual dysfunction after neovaginal formation in anatomical dysfunction**

	Number of patients
Sexual dysfunctions	15/53
• deep dyspareunia	7/53
• vaginismus	8/53
Penile contusion	2/53
• in the group with deep dyspareunia	1/53
• in the group with vaginismus	1/53
Vaginal bleeding after intercourse	3/53

**Table 3: Postoperative results after the modified laparoscopic Vecchietti's plastic and reconstructive neovaginal technique**

Postoperative results	Number of patients
Good quality neovaginal epithelium	53/53
Anatomic success	
• neovagina depth $\geq 6$ cm	50/53
Regular vaginal intercourse	42/53
• orgasmic vaginal intercourse	25/53
Transvaginal oocyte retrieval	1/53

15 of the regularly sexually active patients reported vaginal dysfunctions, such as deep dyspareunia in 7 cases and vaginismus in 8 cases.

## Discussion

The principle of plastic and reconstructive neovagina surgery in women with MRKH-syndrome was used for the first time by Vecchietti [4], [11] in a large series of 307 cases. It was based on performing a *laparotomy* with dissection of the vesico-rectal septum and fixation of the vaginal "dilatation olive" using two sutures passing the pseudohymen and after that externalizing the threads to a traction device through the abdominal wall. Anatomic and functional success rates were promising and the method was used for a long time with satisfactory results (Table 4) [4], [11], [13].

Over the time, the method of Vecchietti has experienced significant improvements, the surgeons using several *laparoscopic* modifications, in which the vesico-rectal septum is protruded by a special thread-bearing cutting needle, followed by placing dilatation instruments attached to the abdominal wall with traction sutures. This laparoscopic method showed good results, with a neovaginal length  $\geq 6$  cm and a functional success rate of 86–100% (Table 4) [7], [14], [15], [16], [17], [18]. Furthermore the laparoscopic approach fulfilled several

of well-recognized advantages of minimal-invasive surgery such as small scarring, less morbidity, shorter hospitalization with faster recovery [19]. Fedele et al. [12] studied prospectively a large series of 110 cases and also demonstrated a high rate of anatomical success in 98% of the cases; 97% of the patients declared vaginal sexual activity.

Even though the both methods, by laparoscopic and laparotomic route have similar satisfactory results [20], several complications such as opening the bladder or rectum with the thread-bearing needle [17] were described. As emphasized in Table 4 the risk of complications reported by authors along time varies between 0 to 22% of the cases [4], [5], [7], [11], [13], [14], [15], [16], [17], [18], [20], [21].

Similar to the data in the literature [17], [21], in these series the long-term results of the patients receiving laparoscopic modified Vecchietti's technique for vaginal agenesis showed good anatomical success (94.3%), the vaginal length achieved being  $\geq 6$  cm. The follow up period was at least one year and most of the patients had regular vaginal intercourse. The surgical duration in minimal-invasive surgery is clearly low, with operation times of less than one hour, reducing the morbidity of the patients.

Another advantage to be taken into consideration is that no foreign or allograft material is used and the original tissue was expanded into the newly created space, which allowed the development of neovagina from genuine secretory genital tissue.

2 cases of bladder injuries occurred during the dissection of vesicorectal fold due to the narrow space between bladder and rectum. The intraoperative bladder injuries were closed laparoscopically during the same surgical procedure, without negative influence on the patients. A bladder catheterization for 1 week was performed and the healing process was favourable.

Only 3 young patients (<20 years) did not appear to benefit from the procedure at all, as the final vaginal depth was less than 5 cm, which led to unsatisfying intercourse. However the sexual activity and the use of vaginal dilators in those three patients were not performed continuously, therefore two important conditions to preserve postoperative functionality of the neovagina were lacking [16], [17]. The two men complaining of penile problems are partners of those three younger patients.

Even when achieving good anatomical results, dyspareunia and vaginismus remain a major problem (15/53), the combination of the psychological impact of the disease and the applied surgery only allowed regular vaginal sexual activity (42/53) and orgasmic vaginal intercourse (25/53) in parts of the collective.

The treatment of vaginal agenesis in MRKH syndrome requires a multidisciplinary approach. The procedure should be performed by senior doctors with experience in vaginoplasty and laparoscopy, and should be followed by a good psychological support of the patients in order to obtain optimal postoperative results. Nevertheless a careful patients' selection for the treatment is required, the patient cooperation and psychological maturity being

Table 4: Vecchietti's procedure – review of literature

Author	Number of patients	Age	Type of surgery	Compl.	Vag. length (cm)	Anatomical Satisfying results	Follow-up (months)
Vecchietti [4], [11]	307	24.3	Laparotomy	8 (2.6%)	7.8	99.3%	Unkn
Hanzal [13]	9	27.3	Laparotomy	0	7.2	89%	91
Gauwerky [7]	5	20.4	Laparoscopy	0	9.8	100%	Unkn
Keckstein [14]	9	21	Laparoscopy	2 (22%)	10	100%	Unkn
Veronikis [5]	6	15–30	Laparotomy 2 Laparoscopy 4	0	9.8	83%	22
Khater [15]	6	26.3	Laparoscopy	1 (17%)	6.5	100%	6
Giacalone [16]	7	22.7	Laparoscopy	0	7	86%	12.8
Borruto [20]	76	Unkn	Laparotomy 69 Laparoscopy 7	9 (12%)	7	80%	Unkn
Fedele [17]	52	16.9	Laparoscopy	3 (5.8%)	7	94.2%	37
Brun [21]	20	21.1	Laparotomy 17 Laparoscopy 3	1 (5%)	8.7	89%	66.2
Keckstein [18]	8	21.9	Laparoscopy	0	9.6	87.5%	40.3

\*Unkn – unknown, Compl. – complication, Vag. – vaginal

important conditions for good postoperative outcomes. The patients should be aware of the importance of maintaining the neovagina postoperatively by regular sexual intercourse and the use of vaginal dilators. Therefore the treatment should start when the patients have begun their sexual activity and have reached emotional maturity.

## Conclusions

The plastic and reconstructive minimal-invasive Vecchietti method for neovagina creation in Mayer-Rokitansky-Küster-Hauser syndrome proved to be safe and effective, with good anatomical and functional results. It allows achieving a sufficient vaginal depth to provide normal function.

The possibility of assisted reproductive techniques with oocyte retrieval seems feasible.

Although good anatomical results could be achieved in nearly all patients (50/53), there was a significant lower amount of patients with regular sexual activity (42/53) or with orgasmic vaginal intercourse (25/53). Deep dyspareunia (7/53) and vaginismus (8/53) are probably due to the combination of psychological impact of disease and the surgery performed.

The adequate age for surgery seems to be between 20–30 years, because younger age could result in not practicing regular vaginal dilation or intercourse postoperatively. In order to achieve satisfactory long-term results, the neovagina must be maintained postoperatively by regular sexual intercourse or the use of vaginal dilators.

## Notes

### Competing interests

The authors declare that they have no competing interests.

## References

- Hauser GA, Schreiner WE. Das Mayer-Rokitansky-Küster-Syndrom [Mayer-Rokitansky-Kuester syndrome. Rudimentary solid bipartite uterus with solid vagina]. *Schweiz Med Wochenschr.* 1961 Mar;91:381-4.
- Sultan C, Biason-Lauber A, Philibert P. Mayer-Rokitansky-Kuster-Hauser syndrome: recent clinical and genetic findings. *Gynecol Endocrinol.* 2009 Jan;25(1):8-11. DOI: 10.1080/09513590802288291
- Morcel K, Guerrier D, Watrin T, Pellerin I, Levêque J. Le syndrome de Mayer-Rokitansky-Küster-Hauser (MRKH) : clinique et génétique [The Mayer-Rokitansky-Küster-Hauser (MRKH) syndrome: clinical description and genetics]. *J Gynecol Obstet Biol Reprod (Paris).* 2008 Oct;37(6):539-46. DOI: 10.1016/j.jgyn.2008.07.002
- Vecchietti G. Le néo-vagin dans le syndrome de Rokitansky-Küster-Hauser [The neovagina in the Rokitansky-Kuster-Hauser syndrome]. *Rev Med Suisse Romande.* 1979 Sep;99(9):593-601.
- Veronikis DK, McClure GB, Nichols DH. The Vecchietti operation for constructing a neovagina: indications, instrumentation, and techniques. *Obstet Gynecol.* 1997 Aug;90(2):301-4. DOI: 10.1016/S0029-7844(97)00231-7
- Fedele L, Bianchi S, Dorta M, Zanconato G, Raffaelli R. Laparoscopic creation of a neovagina in women with pelvic kidney. *J Am Assoc Gynecol Laparosc.* 1999 Aug;6(3):327-9.

7. Gauwerky JF, Wallwiener D, Bastert G. An endoscopically assisted technique for construction of a neovagina. *Arch Gynecol Obstet*. 1992;252(2):59-63. DOI: 10.1007/BF02389629
8. Fedele L, Busacca M, Candiani M, Vignali M. Laparoscopic creation of a neovagina in Mayer-Rokitansky-Küster-Hauser syndrome by modification of Vecchietti's operation. *Am J Obstet Gynecol*. 1994 Jul;171(1):268-9. DOI: 10.1016/0002-9378(94)90482-0
9. Brucker S, Aydeniz B, Gegusch M. Improvement of endoscopically assisted neovagina: new application instruments and traction device. *Gynecol Surg*. 2004; 1: 133-138. DOI: 10.1007/s10397-004-0017-0
10. Fedele L, Bianchi S, Tozzi L, Borruto F, Vignali M. A new laparoscopic procedure for creation of a neovagina in Mayer-Rokitansky-Küster-Hauser syndrome. *Fertil Steril*. 1996 Nov;66(5):854-7.
11. Vecchietti G. Neovagina nella sindrome di Rokitansky-Küster-Hauser [Creation of an artificial vagina in Rokitansky-Küster-Hauser syndrome]. *Attual Ostet Ginecol*. 1965 Mar-Apr;11(2):131-47.
12. Fedele L, Bianchi S, Frontino G, Fontana E, Restelli E, Bruni V. The laparoscopic Vecchietti's modified technique in Rokitansky syndrome: anatomic, functional, and sexual long-term results. *Am J Obstet Gynecol*. 2008 Apr;198(4):377.e1-6. DOI: 10.1016/j.ajog.2007.10.807
13. Hanzal E, Kölbl H, Janisch H. Morphologische und funktionelle Langzeitergebnisse nach Vecchietti-Operation zur Bildung einer Neovagina [Morphologic and functional long-term results after Vecchietti operation for the formation of a neovagina]. *Geburtshilfe Frauenheilkd*. 1991 Jul;51(7):563-8. DOI: 10.1055/s-2007-1026200
14. Keckstein J, Buck G, Sasse V, Tuttlies F, Ulrich U. Laparoscopic creation of a neovagina: modified Vecchietti method. *Endosc Surg Allied Technol*. 1995 Apr-Jun;3(2-3):93-5.
15. Khater E, Fatthy H. Laparoscopic Vecchietti vaginoplasty. *J Am Assoc Gynecol Laparosc*. 1999 May;6(2):179-82. DOI: 10.1016/S1074-3804(99)80099-1
16. Giacalone PL, Laffargue F, Faure JM, Deschamps F. Ultrasound-assisted laparoscopic creation of a neovagina by modification of Vecchietti's operation. *Obstet Gynecol*. 1999 Mar;93(3):446-8.
17. Fedele L, Bianchi S, Zanconato G, Raffaelli R. Laparoscopic creation of a neovagina in patients with Rokitansky syndrome: analysis of 52 cases. *Fertil Steril*. 2000 Aug;74(2):384-9. DOI: 10.1016/S0015-0282(00)00620-8
18. Keckstein J, Kandolf O, Rauter G, Hudelist G. Long-term outcome after laparoscopic creation of a neovagina in patients with Mayer-Rokitansky-Küster-Hauser syndrome by a modified Vecchietti procedure. *Gynecol Surg*. 2008;5(1):21-5. DOI: 10.1007/s10397-007-0323-4
19. Christensen B. Minimalinvasive Möglichkeiten zur Bildung einer Neovagina [Minimally invasive methods to create a neovagina]. *Zentralbl Gynakol*. 2002 Jun;124(6):313-6. DOI: 10.1055/s-2002-34746
20. Borruto F, Chasen ST, Chervenak FA, Fedele L. The Vecchietti procedure for surgical treatment of vaginal agenesis: comparison of laparoscopy and laparotomy. *Int J Gynaecol Obstet*. 1999 Feb;64(2):153-8. DOI: 10.1016/S0020-7292(98)00244-6
21. Brun JL, Belleannée G, Grafeille N, Aslan AF, Brun GH. Long-term results after neovagina creation in Mayer-Rokitansky-Küster-Hauser syndrome by Vecchietti's operation. *Eur J Obstet Gynecol Reprod Biol*. 2002 Jul;103(2):168-72. DOI: 10.1016/S0301-2115(02)00031-3

**Corresponding author:**

Prof. Dr. Dr. Rudy Leon De Wilde  
 University Hospital for Gynecology, Pius-Hospital  
 Oldenburg, School of Medicine and Health Sciences, Carl  
 von Ossietzky University Oldenburg, Georgstraße 12,  
 26121 Oldenburg, Germany, Phone: +49 441 229-1501,  
 Fax: +49 441 229-1525  
[rudy-leon.dewilde@pius-hospital.de](mailto:rudy-leon.dewilde@pius-hospital.de)

**Please cite as**

Cezar C, Devassy R, Larbig A, De Wilde RL. Efficacy risks of the minimal-invasive plastic and reconstructive neovagina Vecchietti technique in Mayer-Rokitansky-Küster-Hauser syndrome. *GMS Interdiscip Plast Reconstr Surg DGPW*. 2014;3:Doc13. DOI: 10.3205/iprs000054, URN: urn:nbn:de:0183-iprs0000540

**This article is freely available from**

<http://www.egms.de/en/journals/iprs/2014-3/iprs000054.shtml>

**Published:** 2014-12-10

**Copyright**

©2014 Cezar et al. This is an Open Access article distributed under the terms of the Creative Commons Attribution License (<http://creativecommons.org/licenses/by-nc-nd/3.0/deed.en>). You are free: to Share – to copy, distribute and transmit the work, provided the original author and source are credited.