

Aberrant atrial conduction *Unrecognized electrocardiographic entity*¹

Edward K. Chung

From Division of Cardiology, Department of Medicine, West Virginia University School of Medicine, Morgantown, West Virginia, U.S.A.

The bizarre configuration of the P wave of a sinus beat immediately after an atrial premature contraction, AV junctional or ventricular premature contraction, or parasystolic beat, is termed 'aberrant atrial conduction' and is analogous to aberrant ventricular conduction.

In patients whose ages ranged from 40 to 89, 120 instances (0.1%) of aberrant atrial conduction were found among 120,000 tracings. The incidence of aberrant atrial conduction after atrial premature contractions, AV junctional premature contractions, ventricular premature contractions, and parasystolic beat was, respectively, 72 (60%), 20 (16.6%), 12 (10%), and 16 (13.3%).

An aberrant atrial conduction is prone to occur after a long postectopic pause (i.e. nonconducted atrial premature contraction or a retrograde P wave of an AV junctional premature contraction or ventricular premature contraction); and it is not directly related to the coupling interval or to the length of the cardiac cycle just preceding or following this interval. Aberrant atrial conduction may rarely occur in 2 or more consecutive sinus beats.

An alteration of atrial depolarization due to a prolonged refractory period influenced by an ectopic impulse is considered to be the cause of aberrant atrial conduction. Thus, some degree of concealed atrial conduction most likely plays a role in the production of aberrant atrial conduction.

Organic heart disease was present in 97.5 per cent of cases, most commonly ischaemic and/or hypertensive (80 cases, 66.6%), and 70 per cent were 60 years old or more. Half had evidence of heart failure, 6 had digitalis intoxication, and a small number had other heart diseases.

Aberrant atrial conduction is to be differentiated from wandering atrial pacemaker, atrial fusion beats, AV junctional escape beats, coexisting multifocal premature beats, and various artefacts.

The author proposes 'aberrant atrial conduction' as a new electrocardiographic entity indicating significant organic heart disease.

Occasionally, the P wave of the sinus beat immediately after an atrial premature contraction may have a bizarre configuration which is different from the P wave of an atrial premature contraction or of sinus origin. This is termed 'aberrant atrial conduction' and is analogous to aberrant ventricular conduction (Langendorf, 1951; Massie and Walsh, 1960; Pick, 1956; Walsh, 1962). Less commonly, aberrant atrial conduction may also be seen immediately after AV junctional or ventricular premature contractions. In addition, aberrant atrial conduction rarely occurs immediately after atrial, AV junctional, or even ventricular

parasystolic beats (Chung, Walsh, and Massie, 1964; Chung, 1968).

The purpose of this paper is to describe the

TABLE I Underlying heart diseases in 120 cases

Diseases	No. of cases	Per cent
Ischaemic and/or hypertensive heart disease	80	66.6
Acute myocardial infarction	12	10.6
Old myocardial infarction	10	8.3
Acute and old myocardial infarction	4	3.3
Rheumatic heart disease	6	5.0
Chronic cor pulmonale	8	6.6
Cardiomyopathy	10	8.3
Congenital heart disease	7	5.8
Digitalis intoxication	6	5.0
Unknown	3	2.5

Received 28 June 1971.

¹ Presented in part at the 20th Annual Scientific Session of the American College of Cardiology, Washington, D.C., 3-7 February 1971.

incidence, diagnostic criteria, and clinical correlation of this heretofore unrecognized electrocardiographic finding. A total of 120 cases of aberrant atrial conduction will also be included for discussion.

Patients and methods

Studies were made of 120 patients with aberrant atrial conduction diagnosed electrocardiographically. The diagnosis was based on an alteration of the P wave configuration in one or more sinus beats immediately after any form of ectopic beat, provided that no known cause was responsible for the former. Records were reviewed and some interesting and important electrocardiographic tracings were selected for illustration. Laboratory tests included chest x-ray, blood count, and serum electrolyte determination. In some patients, pulmonary function tests and cardiac catheterization were performed. There were 78 men and 42 women whose ages ranged between 40 and 89 years. Eighty-four patients (70%) were more than 60 years old and almost all who were studied had received cardiac glycoside (mostly digoxin).

Results

Of the patients, 117 (97.5%) had some form of organic heart diseases and a half of them had a significant (functional class II or more) degree of heart failure. Eighty patients (66.6%) had evidence of ischaemic (coronary) and/or hypertensive heart disease. Specifically, 12 had evidence of acute myocardial infarction and 10 patients had evidence of old myocardial infarction. Acute as well as old myocardial infarction was found in 4 cases. Six patients had rheumatic heart disease. Cor pulmonale was found in 8 subjects, cardiomyopathy was diagnosed in 10, and congenital heart disease was encountered in 7 patients. Six patients showed evidence of digitalis intoxication. An analysis of the under-

TABLE 2 Incidence of aberrant atrial conduction in 120 cases

Preceding beat	No. of cases	Per cent
Atrial premature contractions	72	60.0
Non-conducted	36	30.0
AV junctional premature contractions	20	16.6
Ventricular premature contractions	12	10.0
Parasystole	16	13.3
Atrial	8	6.6
AV junctional	4	3.3
Ventricular	4	3.3

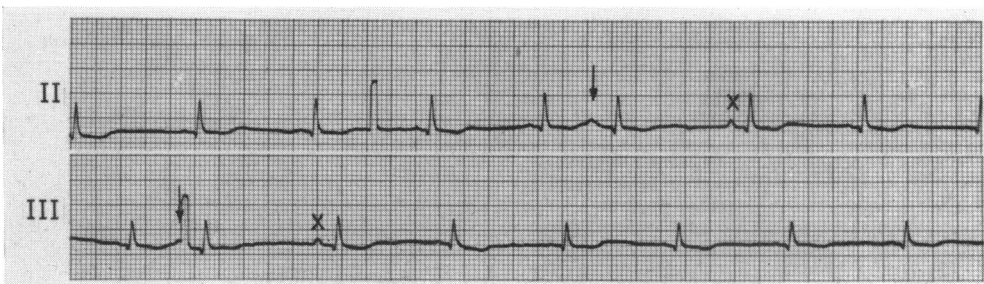
lying heart disease in 120 patients with aberrant atrial conduction is summarized in Table 1.

The present study revealed 120 instances (0.1%) of aberrant atrial conduction in a total of 120,000 electrocardiographic tracings. Aberrant atrial conduction was found immediately after ectopic beat regardless of the fundamental mechanism involved for the genesis of the latter. However, aberrant atrial conduction was much more common after atrial (72 instances: 60.0%) than AV junctional or ventricular premature contractions. Furthermore, aberrant atrial conduction was often found to occur after nonconducted atrial premature contractions (36 instances; 30%). The incidence of aberrant atrial conduction after AV junctional premature contractions, ventricular premature contraction, and parasystolic beats was 20 (16.6%), 12 (10.0%), and 16 (13.3%; 8 atrial, 4 AV junctional, and 4 ventricular parasystole) cases, respectively (Table 2).

Discussion

Aberrant atrial conduction usually involves the P wave of only one sinus beat immediately after an ectopic beat (Fig. 1 and 2). However,

FIG. 1 Sinus rhythm with atrial premature contractions (indicated by arrows) followed by aberrant atrial conduction (marked X).



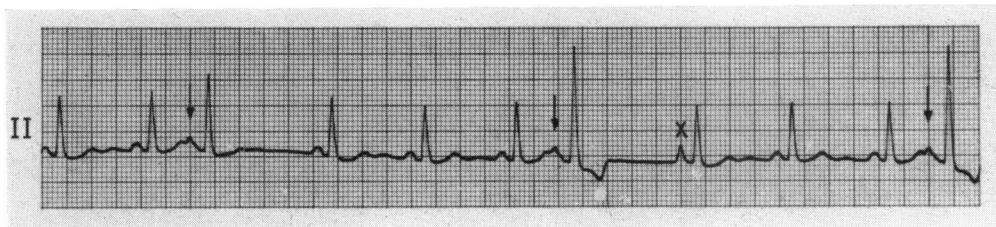


FIG. 2 Sinus rhythm with atrial premature contractions (indicated by arrows) followed by aberrant atrial conduction (marked X). Note bizarre QRS complexes in atrial premature contractions due to aberrant ventricular conduction.

on rare occasions, aberrant atrial conduction may occur in two or more consecutive sinus beats (Fig. 3). When this occurs, aberrant atrial conduction is much more conspicuous in the first sinus P wave than in the second sinus P wave (Fig. 3).

Diagnostic criteria Aberrant atrial conduction is diagnosed when an alteration of the P wave configuration in one or more sinus beats occurs immediately after an ectopic beat provided that no known cause (that is, fusion beat) is responsible for the genesis of the former (Chung, 1971).

1) Aberrant atrial conduction after atrial premature contractions

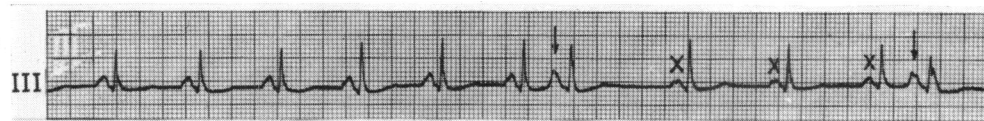
Most commonly, aberrant atrial conduction occurs immediately after atrial premature contraction (Fig. 1-3). The occurrence of aberrant atrial conduction is not directly related to the length of the cardiac cycle just preceding the coupling interval, or to the coupling interval itself, or to the returning cycle (postectopic pause). Aberrant atrial conduction is not often seen after interpolated atrial premature contractions, though it may be expected to occur more easily at this time. Conversely, aberrant atrial conduction seems to occur more frequently after a long returning cycle, such as is seen in nonconducted

(blocked) atrial premature contractions. In this case, concealed atrial conduction may play a role. When conducted and nonconducted atrial premature contractions are seen in the same electrocardiographic tracing, aberrant atrial conduction is prone to occur more commonly and more conspicuously after the nonconducted ectopic P wave. Rarely, aberrant atrial conduction may occur in two or more consecutive sinus beats after an atrial premature contraction (Fig. 3). In this circumstance, aberrant atrial conduction is more pronounced in the first sinus P wave than in the second one after the atrial premature contraction. Occasionally, aberrant atrial conduction may be associated with aberrant ventricular conduction in atrial premature contraction (Fig. 2).

2) Aberrant atrial conduction after AV junctional premature contraction

Less commonly, aberrant atrial conduction may occur after AV junctional premature contractions (Fig. 4). Occasionally, aberrant atrial conduction may occur simultaneously with aberrant ventricular conduction in the same tracing (Fig. 4). This is particularly true after interpolated AV junctional premature contractions. Aberrant atrial conduction is prone to occur after a retrograde P wave of AV junctional premature beat (Fig. 4).

FIG. 3 This rhythm strip shows sinus rhythm with occasional atrial premature contractions (indicated by arrows) followed by aberrant atrial conduction which occurs consecutively in three sinus beats (marked X). Note that the degree of aberrant atrial conduction is more conspicuous in the first and second sinus beats than the third sinus beats.



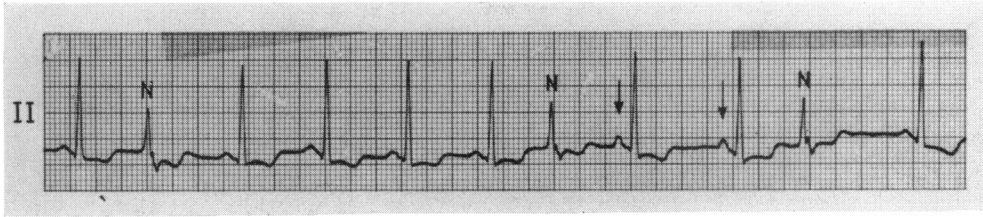


FIG. 4 Sinus rhythm and AV junctional premature contractions with aberrant ventricular conduction (marked N) followed by aberrant atrial conduction (indicated by arrows).

3) Aberrant atrial conduction after ventricular premature contractions

On rare occasions, aberrant atrial conduction may be seen after ventricular premature contractions (Fig. 5). As seen in atrial premature contractions, the occurrence of aberrant atrial conduction after ventricular premature contractions is not related to the length of the coupling interval or to the postectopic pause. In this author's experience, aberrant atrial conduction is not seen after interpolated ventricular premature contractions, though it is expected to occur more often at this time than after a full compensatory pause. Post-ventricular premature contraction aberrant atrial conduction seems to occur more commonly after a retrograde P wave (Fig. 5). Aberrant atrial conduction generally involves the first sinus P wave immediately after a ventricular premature contraction but, at times, two or more sinus P waves after a ventricular premature contraction may show consecutive aberrant atrial conduction.

4) Aberrant atrial conduction after parasystolic beats

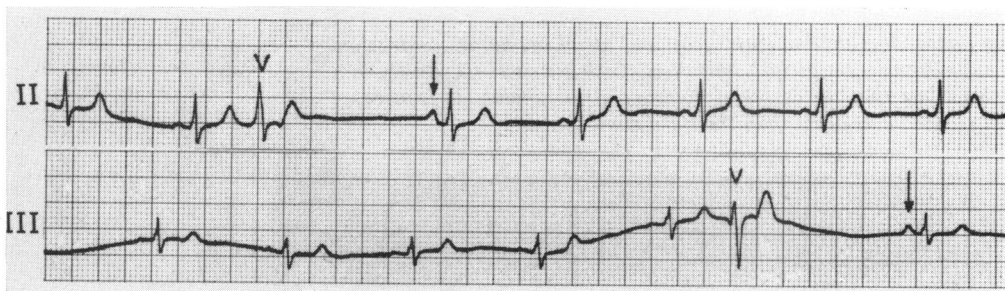
Aberrant atrial conduction after parasystolic beats is rare because parasystole itself is a relatively uncommon arrhythmia. If aberrant

atrial conduction occurs, it is more commonly seen after atrial parasystolic beats (Fig. 6). The incidence of aberrant atrial conduction after AV junctional and ventricular parasystolic beats is almost equal (Fig. 7). Aberrant atrial conduction after atrial parasystolic beats has been seen by different authors previously (Scherf, Yildiz, and De Armes, 1959), but it was not described as such. Though this finding is more likely to occur after an interpolated atrial parasystolic beat, it has not been seen by this author (Chung *et al.*, 1964; Chung, 1968) or by the others (Langendorf *et al.*, 1962).

Mechanisms The exact mechanism involved in the production of aberrant atrial conduction is not clearly understood.

Conduction via various internodal and interatrial pathways connecting the sinus node to the AV node and the sinus node to the atria, described by James (1963, 1970), had been considered a possible explanation for the bizarre P waves after various ectopic beats. However, Truex (1966) was unable to show such accessory pathways in 20 human specimens either by microdissection or histological study of serial sections. Thus, the true existence of these pathways and their electrophysiological functions remain still uncertain.

FIG. 5 Sinus rhythm with ventricular premature contractions (marked V) followed by aberrant atrial conduction (indicated by arrows). (Reproduced from Chung, 1971, Principles of Cardiac Arrhythmias. Williams and Wilkins, Baltimore.)



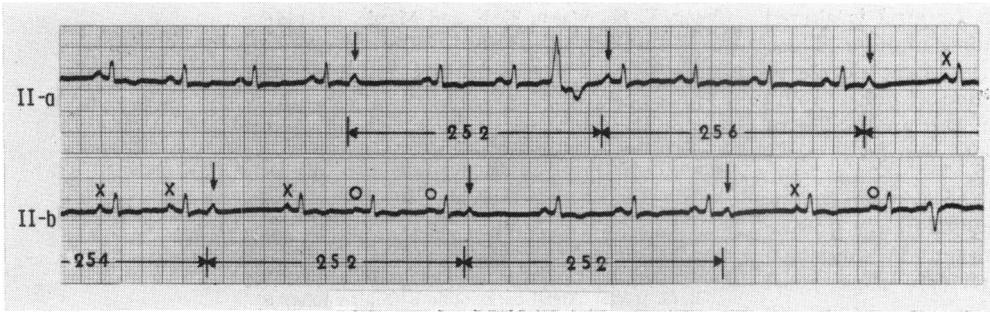


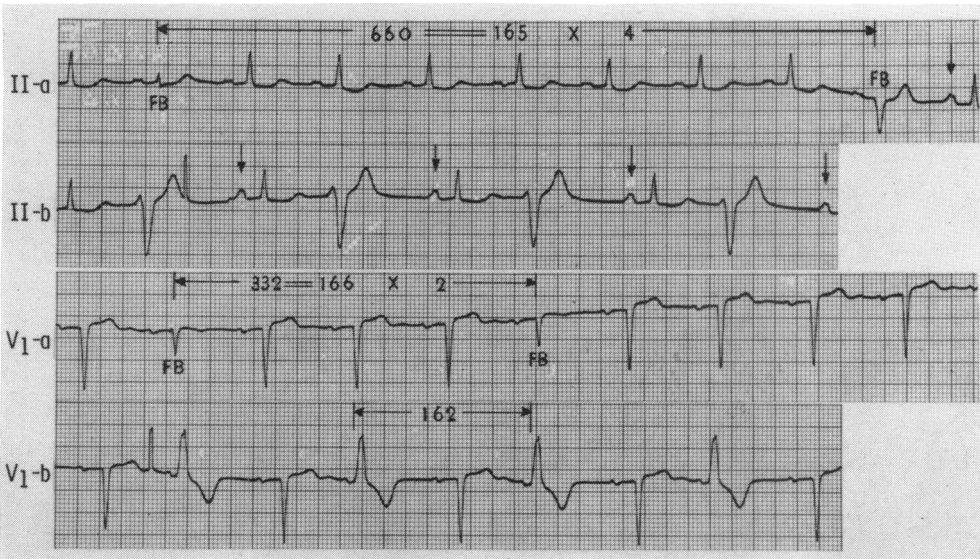
FIG. 6 Leads II-a and b are continuous. The tracing reveals sinus rhythm with atrial parasystole (indicated by arrows) and occasional ventricular premature contractions. It is interesting to note two types of aberrant atrial conduction (marked X and O) after parasystolic beats.

A shifting (wandering) pacemaker in the sinus node or in the atria immediately after various ectopic beats has also been considered for the production of the bizarre P waves. But, it is very difficult to understand why a shifting pacemaker only involves one or two beats after various ectopic beats. In addition, the beat with a bizarre P wave immediately after ectopic beats shows all diagnostic features of sinus beats except for a slight alteration of the P wave configuration. This finding makes a shifting pacemaker unlikely as an explanation of the bizarre P wave.

In the present study, the following findings were observed: (a) Aberrant atrial conduction does not seem to be related to a coupling interval; (b) aberrant atrial conduction does not seem to be related to a postectopic pause; (c) aberrant atrial conduction does not seem to be related to the fundamental mechanism involved for the production of the ectopic beats; (d) aberrant atrial conduction is prone to occur after a blocked or a retrograde ectopic P wave.

From the above observations, aberrant atrial conduction most likely occurs because

FIG. 7 Leads II-a and b, and leads VI-a and b are taken on different occasions in the same patient. The tracing shows sinus rhythm with ventricular parasystole (indicated by arrows). Note occasional ventricular fusion beats (marked FB).



the refractory period of the atria is altered immediately after an ectopic impulse. Thus, it is logical to assume that some degree of concealed atrial conduction (Chung, 1971) probably plays a role in the production of aberrant atrial conduction.

Differential diagnosis Aberrant atrial conduction must be differentiated from a shifting (wandering) atrial pacemaker, AV junctional escape beats after a postectopic pause, atrial fusion beats, coexisting multifocal premature beats, and various artefacts.

Clinical significance The clinical significance of aberrant atrial conduction is again uncertain because of its rare occurrence. However, all cases of aberrant atrial conduction observed by this author were found in patients with diseased hearts. Thus, the clinical significance of aberrant atrial conduction may not be the same as in aberrant ventricular conduction.

I wish to express my sincere appreciation to Mrs. Susan Myers for her technical assistance in the preparation of this paper.

References

- Chung, E. K. (1968). Parasystole. *Progress in Cardiovascular Diseases*, **11**, 64.
- Chung, E. K. (1971). *Principles of Cardiac Arrhythmias*. Williams and Wilkins, Baltimore.
- Chung, E. K., Walsh, T. J., and Massie, E. (1964). Atrial parasystole. *American Journal of Cardiology*, **14**, 255.
- James, T. N. (1963). The connecting pathways between the sinus node and A-V node and between the right and the left atrium in the human heart. *American Heart Journal*, **66**, 498.
- James, T. N. (1970). Cardiac conduction system: fetal and postnatal development. *American Journal of Cardiology*, **25**, 213.
- Langendorf, R. (1951). Aberrant ventricular conduction. *American Heart Journal*, **41**, 700.
- Langendorf, R., Lesser, M. E., Plotkin, P., and Levin, B. D. (1962). Atrial parasystole with interpolation; observations on prolonged sinoatrial conduction. *American Heart Journal*, **63**, 649.
- Massie, E., and Walsh, T. J. (1960). *Clinical Vectorcardiography and Electrocardiography*. Year Book Medical Publishers, Chicago.
- Pick, A. (1956). Aberrant ventricular conduction of escaped beats: preferential and accessory pathways in the A-V junction. *Circulation*, **13**, 702.
- Scherf, D., Yildiz, M., and De Armes, D. (1959). Atrial parasystole. *American Heart Journal*, **57**, 507.
- Truex, R. C. (1966). Anatomical considerations of the human atrioventricular junction. In *Mechanisms and Therapy of Cardiac Arrhythmias*, p. 333. Ed. by L. S. Dreyfus, W. Likoff, and J. H. Moyer. Grune and Stratton, New York.
- Walsh, T. J. (1962). Ventricular aberration of A-V nodal escape beats. Comments concerning the mechanism of aberration. *American Journal of Cardiology*, **10**, 217.

Requests for reprints to Professor Edward K. Chung, West Virginia University, Medical Center, Morgantown, West Virginia 26506, U.S.A.