

Idiopathic massive chylopericardium

M. Puig-Massana, M. Murtra, and J. M. Calbet

From Centro Quirúrgico San Jorge (Centre of Cardiovascular Surgery),
Via Augusta, 269-273, Barcelona 17, Spain

Isolated massive chylopericardium is an exceptional clinical entity.

A report of a new case, in an asymptomatic 12-year-old, is presented. This was treated successfully by operation, by ligation of the thoracic duct above the diaphragm, and by partial pericardiectomy.

It was Hazebrock, in 1888 (Modai *et al.*, 1970), who first described chylopericardium in a patient with tracheal stricture and ulceration, who at necropsy was found to have 20 ml of chyle in the pericardium. In 1935, Yater reported 100 cases of non-traumatic chylothorax, in which there were 3 cases of associated chylopericardium. The first case of massive chylopericardium was reported in 1954 by Groves and Effler. Since then, only 16 cases of chylopericardium have been reported (Fawal *et al.*, 1967; Glassen *et al.*, 1968; Rochu, Henry, and Jouve, 1969; Daniel and Bressie, 1969; Yoshida *et al.*, 1969; Modai *et al.*, 1970). Here we present a new case of idiopathic massive chylopericardium, treated successfully by operation.

Case report

A 12-year-old white boy was admitted to the San Jorge Clinic on 2 February 1970 for full investigations. It had been noticed, at a routine medical examination, that he had a very enlarged heart. He had not had any previous illnesses and was asymptomatic. On physical examination the patient appeared fit and normally developed for a 12-year-old. He was communicative and intelligent. His jugular venous pressure was normal. His pulse was regular, with full volume at 80/min, and all peripheral pulses were easily palpable. Blood pressure was 120/70 mmHg, without pulsus paradoxus. The apex beat was found at the fifth intercostal space and left of the midclavicular line. On chest auscultation there was only a systolic click at the left sternal edge. The heart sounds were normal and there were no murmurs. The lungs were clear. The liver and spleen were not palpable and there was no sacral or ankle oedema. The chest x-ray showed that the cardiac shadow was very enlarged, with a globular shape, suggesting a massive pericardial effusion (Fig. 1a). The electrocardiogram showed sinus rhythm at 80/min, QRS axis at 40°, and low voltage com-

plexes. On right cardiac catheterization, the pressures were normal. It was found that the actual cardiac size was normal, confirming a huge pericardial effusion. A diagnostic pericardiocentesis was then performed, obtaining fluid with a milky white appearance, which laboratory studies showed had chylous properties (Table). Hence, the diagnosis of massive chylopericardium was made. General blood tests were normal. On 19 February, another pericardiac puncture was performed obtaining 1000 ml of milky white chylous fluid. X-rays showed that over a period of two weeks the fluid had completely filled the pericardial sac (Fig. 1b, c, d). On 25 February the patient was discharged, to be readmitted on 13 March, for operation. On 16 March 1970, before operation, a lymphographic study was performed, showing a normal progression of the contrast medium until the thoracic duct emptied into the left subclavian vein. The radiological characteristics of the thoracic duct showed a normal appearance and there were no abnormalities.

After the last x-ray, 3 ml of Patent Blue dye were injected into the dorsal lymphatic ducts of both feet. The patient was then immediately transferred to the theatre. A left lateral thoracotomy was made through the sixth intercostal space. The lungs were free and no pleural effusion was found. The pericardium was bulging, due to the massive effusion, and had a whitish appearance. The pericardium was opened in front of the phrenic nerve (Fig. 2) and 900 ml of milky white chylous fluid were obtained. The pericardium was pliable, thin, and had normal characteristics. On the inside surface there were in some places small particles of a yellowish substance and tiny cysts that had not been affected by the Patent Blue dye. On the other hand, there were, in the pulmonary hilus and thoracic wall, some lymphatic ducts that were slightly dyed and had a normal appearance.

A second injection of 3 ml of Patent Blue dye was made into the dorsal lymphatic duct of the left foot. The thoracic duct was searched for behind the oesophagus and to the right of the aorta, just above the diaphragm. It had a normal appearance and was undyed. A thin polyethylene catheter was introduced into the duct, and 2 ml of

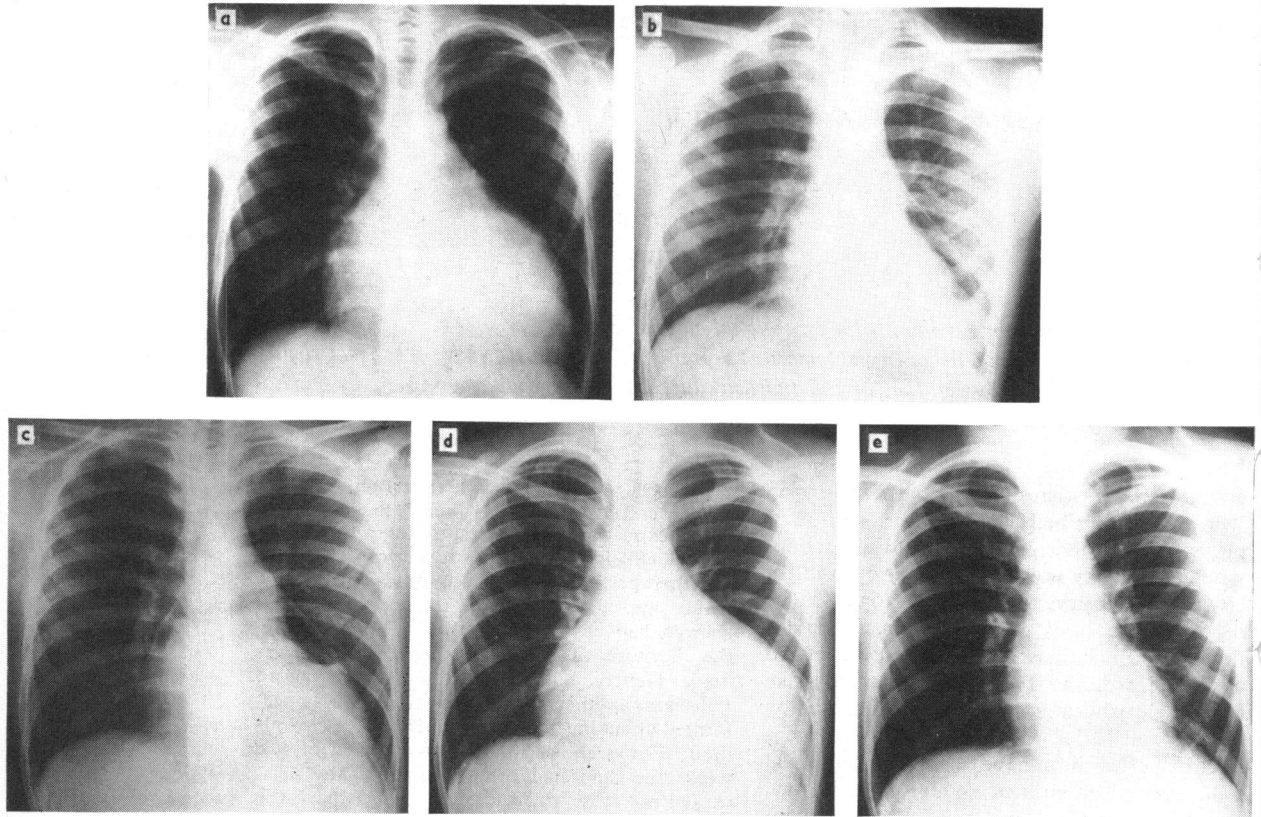


FIG. 1 Chest x-rays: (a) On admission; (b) after pericardiocentesis; (c) 3 days after pericardiocentesis; (d) 2 weeks after pericardiocentesis; and (e) 9 months postoperatively.

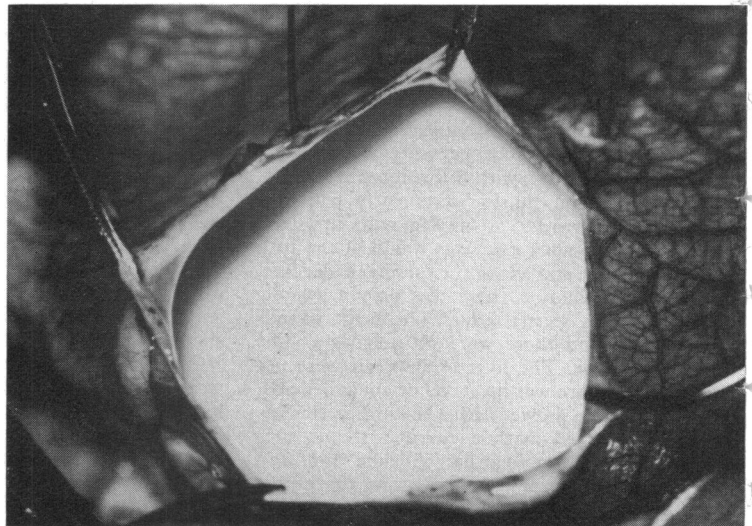
FIG. 2 Pericardium opened during operation showing chyle.

TABLE Study of pericardial fluid extracted by pericardiocentesis

Milky white appearance	—
Specific gravity	1020
pH	8
White blood cell count	1400/mm ³
Red blood cell count	5000/mm ³
Protein	6.8 g/100 ml
Cholesterol	170 mg/100 ml
Chloride	97 mEq/l.
Glucose	88 mg/100 ml
Enzymes	
Serum alanine aminotransferase	15 units/ml
Serum aspartate aminotransferase	15 units/ml

Note: Sedimentation study showed that the cells were lymphocytes with a few macrophages containing lipids. There were fat droplets and no cholesterol crystals.

Gram stain showed no organisms and culture was negative.



Patent Blue were injected. Immediately the collateral lymphatic channels and the glands became well differentiated by the dye. Many lymphatic channels followed the direction of the left pulmonary artery, entering the pericardium. The main pulmonary artery became completely dyed and also the area of the transverse sinus, in contrast with the rest of pericardium which remained unaffected. At that level the dyed chyle seeped out and accumulated in the *cul-de-sac* of the pericardium. Even so, it was not possible to see any macroscopical abnormalities. Two cm of the thoracic duct were resected and it was ligated at the level where it was cannulated. The pericardium was partially resected in front of the phrenic nerve. The chest was closed leaving a pleural drain. There were no problems postoperatively. The x-rays showed no reaccumulation of fluid in the pericardium or in the pleura, and the patient was discharged on the eighth day after operation. The patient has attended the outpatient clinic regularly and on examination has been found to be completely normal. The last examination, 9 months postoperatively, showed a fit boy who was leading a completely normal life. There was no raised jugular venous pressure, pulse was regular with full volume at 80/min, and blood pressure was 110/70 mmHg. Heart sounds were normal and there were no murmurs present. Lungs were clear. Liver and spleen were not palpable and there was no sacral or ankle oedema. Electrocardiogram showed sinus rhythm at 80/min and voltage was normal. The x-ray showed a normal cardiac shadow with no signs of any accumulation of the fluid since the operation (Fig. 1e).

Comments

Many discussions have taken place to explain chylopericardium. It could be explained by abnormal congenital communications between the pericardium and the thoracic duct, or by a reversed flow in the lymphatic channels in spite of the valves. This could take place with a high pressure that could arise in partial or total obstruction of the thoracic duct at a high level. Nevertheless, there are obstructions of the thoracic duct (produced by mediastinal tumours) without chylothorax. Bartel and Neute (1964) have suggested the possibility of an increased permeability of the lymphatic channel wall of unknown aetiology. They pointed out, also, the possibility of a loss of smooth muscle tone, either a congenital defect or on a reflex basis.

In the case presented here, the chyle, dyed by the Patent Blue given during operation directly into the thoracic duct, appeared to seep out from the level of the transverse sinus and accumulate in the pericardium, but no abnormalities were found. The lymphography showed a normal thoracic duct and failed to show any connexions between the pericar-

dium and thoracic duct or any other abnormalities. The diagnosis of chylopericardium was made after the pericardial tap, observing the characteristic milky white appearance of the chyle, that cannot be mistaken for anything else. The main differential diagnosis must be made with cholesterol pericarditis in which the fluid has an ochre colouring and contains cholesterol crystals (Brawley, Vasko, and Morrow, 1966).

The ligation of the thoracic duct at a low level in the treatment of chylopericardium has always been followed by successful results. It is advisable to associate a pericardial window or a partial pericardiectomy as well as the ligation of the dilated lymphatics, if found, in spite of the failure of such procedures as single methods of treatment.

We wish to thank Dr. F. Nogueras for performing the lymphographic studies and the Provincial Savings Bank of Barcelona, Spain, for their support of Centre San Jorge.

References

- Bartel, J., and Neute, E. (1964). Das isolierte Chyloperikard. *Cardiologia*, **45**, 251.
- Brawley, R. K., Vasko, J. S., and Morrow, A. G. (1966). Cholesterol pericarditis. *American Journal of Medicine*, **41**, 235.
- Daniel, T. G., and Bressie, J. L. (1969). Primary chylopericardium. Review and report of a case. *Journal of Thoracic and Cardiovascular Surgery*, **57**, 408.
- Fawal, I. A., Kirkland, H., Dykes, R., and Foster, G. L. (1967). Chronic primary chylopericardium. Report of a case and review of the literature. *Circulation*, **35**, 777.
- Glasser, S. P., Cheitlin, M. D., Serfas, L. S., and Sbar, S. S. (1968). Isolated massive chylopericardium. *American Heart Journal*, **75**, 663.
- Groves, L. K., and Efler, D. B. (1954). Primary chylopericardium. *New England Journal of Medicine*, **250**, 520.
- Modai, J., Binet, J.-P., Bisson, M., Langlois, J., Abastado, M., and Domart, A. (1970). Nouvelle observation de chylopéricarde isolé. *Coeur et Médecine Interne*, **9**, 161.
- Rochu, P., Henry, E., and Jouve, A. (1969). Un nouveau cas d'épanchement laiteux du péricarde. *Archives des Maladies du Cœur et des Vaisseaux*, **62**, 577.
- Yater, W. M. (1935). Non-traumatic chylothorax and chylopericardium; review and report of a case due to carcinomatous thromboangiitis obliterans of thoracic duct and upper great veins. *Annals of Internal Medicine*, **9**, 600.
- Yoshida, Y., Tomomatsu, T., Yorifuji, S., Okamoto, R., and Kono, M. (1969). Chronic primary chylopericardium. Report of a case with diagnostic interest and review of the literature. *Japanese Circulation Journal*, **33**, 725.

Requests for reprints to Dr. M. Murtra, Surgical Department, Centro Quirúrgico San Jorge (Centre of Cardiovascular Surgery), Via Augusta, 269-273 Barcelona 17, Spain.