

Electrocardiogram in chronic cor pulmonale

S. Padmavati and Veena Raizada

From the Department of Cardiology, G. B. Pant Hospital, New Delhi, India

A 14-year follow-up study of 544 patients with proven chronic cor pulmonale with 966 serial records was made. This is probably the largest series reported upon. Among significant serial changes were those in the configuration of the P and T waves which were the most labile and in the P and QRS axes which were less so. Right axis deviation of the P axis was found in 57 per cent, of the QRS axis in 79 per cent, and a qR pattern in aVR in 45 per cent. In the praecordial leads a classical right ventricular hypertrophy pattern was seen in nearly 75 per cent, incomplete right bundle-branch block in 15.4 per cent, a QS pattern in all chest leads in 17 per cent, left ventricular hypertrophy in 4.2 per cent, and combined ventricular hypertrophy in 4 per cent. The pattern of right ventricular hypertrophy was commonly a qR with R below 5 mm; Rs and R were much less common. qR and incomplete right bundle-branch block patterns interchanged freely in serial records and were sometimes present in the same record. The suggested reasons for these are a basic diastolic overload with a superimposed systolic overload, both of which are responsible for the genesis of the right ventricular hypertrophy pattern in cor pulmonale. An rS in V5-V6 was seen in 78 per cent of patients. Transient inversion of the T wave in all chest leads occurred in 23 per cent which could not be put down to digitalis or ventricular hypertrophy. These were of a nonspecific nature, and might be related to the severity of pulmonary artery hypertension, to hypoxia, and perhaps to pulmonary embolism.

It is suggested that for the diagnosis of right ventricular hypertrophy in cor pulmonale when criteria of classical right ventricular hypertrophy and incomplete right bundle-branch block are absent, associated electrocardiographic abnormalities be taken. These are a combination of rS in V5-V6, right axis deviation, qR in aVR, and P pulmonale, the last being the least important.

Though there have been several publications on the electrocardiogram in chronic cor pulmonale (Spodick, 1959; Wood, 1948; Phillips and Burch, 1963; Burch and DePasquale, 1963; Scott and Garvin, 1941), many controversial points still exist in the diagnosis of right ventricular hypertrophy in the presence of extensive lung disease. Several of these electrocardiographic features have been attributed to inflationary changes in the lungs and to changes in cardiac position. The importance of being able to detect early cardiac involvement is obvious in relation to therapy.

The records in the present series were evaluated with the following objectives.

1) To study the evolution of the electrocardiogram in chronic cor pulmonale and to formulate criteria for detection of early right ventricular hypertrophy, particularly in hearts which are not enlarged.

2) To highlight special features of right ven-

tricular hypertrophy in chronic cor pulmonale as distinct from other causes.

3) To present the electrocardiographic features in perhaps the largest series of chronic cor pulmonale cases reported so far.

Subjects and methods

The electrocardiographic features of 544 patients with a total of 966 records (including serial ones) are presented. These patients were seen at the Lady Hardinge and Govind Ballabh Pant Hospitals, New Delhi. Chronic cor pulmonale accounts for 20 per cent of all cardiac cases in this area. The lung condition responsible was chronic bronchitis and emphysema in about 76 per cent and bronchiectasis in 24 per cent of cases. Three hundred and fifty-eight patients had single and 186 serial records varying from 2 to 10 records per patient, taken over a period of 14 years from 1956 to 1969. They were all cases of chronic cor pulmonale with unequivocal right ventricular hypertrophy proved clinically, radiologically, or by cardiac catheterization, and mostly with, but a few without, congestive heart failure. Electrocardiograms were also correlated with data from 17 necropsies and 51 catheter

studies. The pattern of right ventricular hypertrophy in chronic cor pulmonale has also been compared with that in rheumatic mitral stenosis and congenital lesions for distinctive features.

Results

Standard and unipolar limb leads (Table 1) P wave (Fig. 1) Though 53 per cent of patients had normal P waves at the initial visit there were only 30 (5.8%) in this category at the end of the study. Gothic P or P pulmonale were seen in the remainder, intermittently in 145 and permanently in 100. The P pulmonale, whatever its significance, was therefore seen in nearly 95 per cent of patients at some time.

P axis Normal and right axis deviation of the P wave were seen in approximately equal numbers at the initial visit. However, subsequently 26 patients developed right axis deviation; 19 patients with right axis deviation initially also showed change of axis into the normal range and back to the right during the study.

QRS voltage A low voltage QRS was seen at the end of the study in 224 records (41%) though initially in a smaller number.

QRS axis Although about an equal number of patients showed normal and right axis deviation, initially only 100 had a persistently normal axis (18%). In 168, it changed from normal to right axis deviation, giving nearly an 80 per cent total incidence of right axis deviation. In 80 patients changes in degree of right axis deviation of a transient nature were observed. Left axis deviation was seen in 12, in 2 of whom there was associated hypertension.

T wave Two hundred and ninety-four (54%) had T inversion in leads II-III. The cause of the T inversion in lead I in 27 (5%) was put down to hypertension and left ventricular hypertrophy in 2 cases. In the remainder no cause was apparent.

Position of heart Four hundred and forty-eight (82.3%) of the patients showed a vertical or semivertical position, 30 (6.3%) showed a horizontal or semihorizontal position, 48 (8.8%) showed an intermediate, and 18 (3.3%) had an indeterminate position.

TABLE 1 Significant changes in standard and unipolar limb leads

Subject	Initial records		Final records	
	No. of cases	Per cent	No. of cases	Per cent
Normal P waves*	275	53.0	30	5.8
Gothic P wave	30	5.8	485	94.2
P pulmonale	210	40.8		
Normal P axis†	164	51.6	138	43.4
Rightward P axis (+70° and above)	154	48.4	180	56.6
Normal QRS voltage	347	63.8	320	58.9
Low voltage QRS	197	36.2	224	41.1
Normal QRS axis (-30° to 110°)	268	49.3	100	18.0
Right axis deviation (+110° to -180°)	235	43.2	432	79.0
Axis illusion (-90° to -180°)	29	5.3		
Left axis deviation (-30° to -90°)	12	2.2		
T wave changes:				
Normal T waves	223	40.9		
T inversion in lead I	27	5.0		
T inversion in lead II-III	294	54.0		
qR in aVR	224	41.2	243	44.7

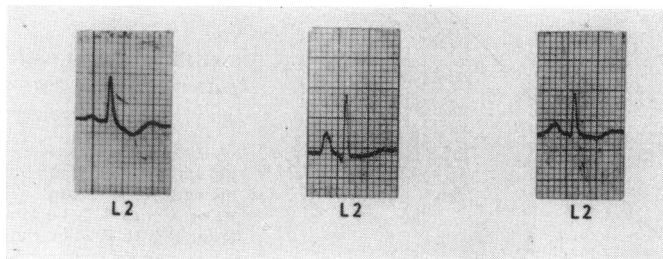
* 515 records.
† 318 records.

qR pattern in aVR A qR pattern in lead aVR was observed in 224 (41%) at the initial visit and subsequently in 19 more.

Praecordial leads (Tables 2 and 3) Right ventricular hypertrophy Classical right ventricular hypertrophy was defined in this study by the following criteria.

- 1) Increased intrinsicoid deflection (over 0.035 sec and below 0.05 sec) in right chest leads (V5R-V1).
- 2) Dominant R in V5R or V1 with R/S ratio over 1 (qR, Rs, and R patterns have been included in this category). Incomplete right bundle-branch block patterns and the pattern of QS waves in all chest leads have been considered separately and not in this group.

FIG. 1 Lead II. Left to right, 20 August 1960, normal P wave; 1 November 1967, P pulmonale during acute exacerbation; and 18 November, normal P wave after treatment.



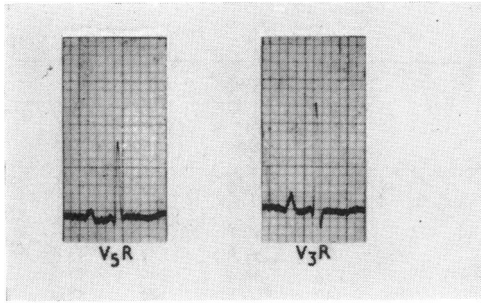


FIG. 2 qR in right chest leads – R is over 5 mm.

Right ventricular hypertrophy was observed initially in 344 (63.2%) and in serial records in 63 more. A qR pattern was seen in 300, with R above 5 mm in 88 and below 5 mm in 212 (Fig. 2 and 3). Similarly in 44 showing Rs and R patterns, R was below 5.0 mm in 30 and above that in 14. In 40 patients the right ventricular hypertrophy pattern changed from qR to Rs, and in 10 from Rs to qR in serial records. In 150 patients in whom right ventricular hypertrophy was not evident in the routine leads, the electrocardiograms were taken in one or two lower right intercostal spaces (Fig. 4). Of these, 122 (81.3%) revealed classical patterns of right ventricular hypertrophy.

Right bundle-branch block Incomplete right bundle-branch block was noted in 70 patients (12.9%) and it appeared later in 14 more in serial records. This pattern was found to occur transiently in a larger number of patients with classical right ventricular hypertrophy and the reverse was also true. It was also seen together with qR in the same record

FIG. 3 qR in right chest leads – R is below 5 mm.

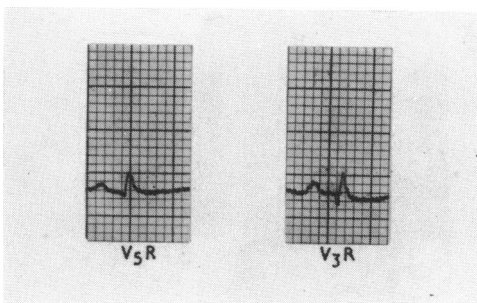


TABLE 2 Changes in praecordial leads

Subject	Initial records		Final records	
	No. of cases	Per cent	No. of cases	Per cent
Normal QRS	123	22.6	—	—
Classical right ventricular hypertrophy	344	63.2	407	74.8
Incomplete right bundle-branch block	70	12.9	84	15.4
Right bundle-branch block	4	0.4		
QS all praecordial leads	38	7.0	98	17.17
Left ventricular hypertrophy	18	3.3	23	4.2
Combined ventricular hypertrophy	21	3.9		
rs in V5–V6*	416	77.9		
Normal T waves†	102	19.43	29	5.5
T inversion in:				
Right chest leads	303	57.7	323	61.0
Left chest leads	8	1.5		
All chest leads	112	21.0	122	23.2

* 416 records.

† 525 records.

(Fig. 5). That they may represent the same physiological phenomenon is discussed later.

Complete right bundle-branch block was observed in 4 patients. Three of the 4 had strong presumptive evidence of ischaemic heart disease, while one was a case of atrial septal defect associated with chronic cor pulmonale.

A QS pattern in all chest leads was seen in 38 (7%) and 60 patients with initial normal tracings subsequently developed this pattern (Fig. 6).

Left ventricular hypertrophy and combined ventricular hypertrophy Isolated left ventricular hypertrophy was seen in 23 (4.2%). Two were cases of hypertension; in 13 (4 below and 9 above 60 years) a presumptive diagnosis of associated ischaemic heart disease had been made on clinical grounds. In the remainder, no cause was apparent. Biventricular hypertrophy was seen in 21 (Fig. 7). In these no obvious cause was evident for the left ventricular hypertrophy such as hypertension, valvular disease, or ischaemic heart disease.

TABLE 3 Right ventricular hypertrophy patterns in right praecordial leads

	No. of cases	Per cent
qR with R > 5.0 mm	88	16.2
qR with R < 5.0 mm	212	38.9
Rs or R with R > 5.0 mm	14	2.6
Rs or R with R < 5.0 mm	30	5.5

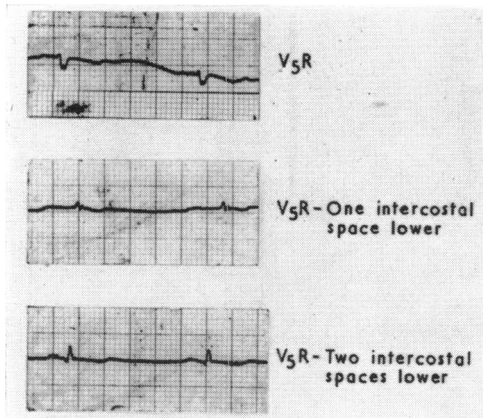
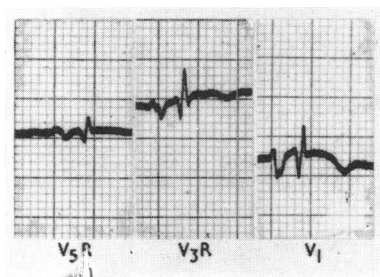


FIG. 4 Appearance of classical right ventricular hypertrophy pattern in the lower intercostal spaces. This pattern is absent in the routine V_5R .

Dominant S in V_5 - V_6 A rS pattern in leads V_5 - V_6 was seen in 78 per cent of records at the initial visit, making it an important feature of the total electrocardiographic picture.

T wave Normal T waves in all the praecordial leads were observed in only 29 patients at the end of the study. T inversion in right chest leads was seen in 61 per cent of patients. T inversion in left chest leads alone was seen in 8, 6 of whom also had voltage evidence of left ventricular hypertrophy. Inversion of T in all chest leads was seen in 122 patients (23%) at the end of the study. Of these, 8 had evidence of left ventricular hypertrophy and 3 of combined ventricular hypertrophy. In the remainder, there was no obvious cause. T waves in all the leads were extremely labile and changed sometimes from day to day (Fig. 8).

FIG. 5 Simultaneous occurrence of qR and rSR' patterns in right chest leads. Lead V_5R shows qR, while V_3R and V_1 show rSR' pattern.



P wave There was a higher percentage of normal P waves in praecordial leads (391-71.9%), and the incidence of P pulmonale in right chest leads in 140 (25.7%) was definitely lower than in standard leads.

Statistical correlation These were worked out between right axis deviation and P axis (axis $+70^\circ$), right axis deviation and right ventricular hypertrophy, qR in aVR and clockwise rotation, qR in aVR and right ventricular hypertrophy, and right axis deviation and clockwise rotation. All showed a correlation at the 5 per cent level.

Correlation of electrocardiogram with haemodynamic findings (Table 4)

Though there were only a few patients with mean pulmonary artery pressures over 50 mmHg, with increases in pulmonary artery pressure the numbers with right axis deviation and classical right ventricular hypertrophy increased while those with normal axis and QS patterns in all chest leads decreased. P pulmonale and T inversion in right chest leads (not shown in the Table) did not correlate with pulmonary artery pressure.

There was no significant correlation between mean pulmonary artery pressure and incomplete right bundle-branch block (in 16 showing incomplete right bundle-branch block, the pulmonary artery pressure range was a wide one, viz. 20 to 60 mmHg). There was a higher incidence of R over 5 mm in patients with high pulmonary artery pressures. In 14 patients showing dominant R over 5.0 mm, the mean pulmonary artery pressure was 37 mmHg, and in 28 with dominant R below 5.0 mm, the mean pulmonary artery pressure was 30 mmHg.

In 19 patients with arterial oxygen saturation below 85 per cent, classical right ventricular hypertrophy was seen in 17 (84%), while in 32 with arterial oxygen saturation above 85 per cent it was seen in 25 (81%). Hypoxia did not correlate with right ventricular hypertrophy in this study.

Correlation of electrocardiogram with findings at necropsy (Table 5)

Seventeen patients (all women) came to necropsy. All had right ventricular hypertrophy by the following criteria. (1) The heart weight exceeded the mean standard deviation for normal body weight and length (Zeek, 1942; Walker, Helm, and Scott, 1955; Phillips, 1958), (2) right ventricular thickness was 5 mm or more or 4 mm or more when dilatation was present (Scott, 1960). The heart weights

were generally low because of the poor nutritional status of the population. The right ventricular wall thickness showed a mean value of 8.9 mm, and it was below 5 mm in only one case in which there was considerable right ventricular dilatation. With increasing thickness of the right ventricular wall the incidence of right axis deviation and of 'classical' right ventricular hypertrophy increased, while that of the QS pattern in the chest leads decreased. P pulmonale showed no correlation with right ventricular thickness.

Incidence of right ventricular hypertrophy by various criteria (Table 6) A comparison was made of the incidence of right ventricular hypertrophy using three criteria (Milnor, 1957; Phillips and Burch, 1963; Sokolow and Lyon, 1949). With the criteria of Sokolow and Lyon (1949) and of Milnor (1957), the incidence was low (19 and 14.9%, respectively). With Phillips and Burch (1963) the criteria of 'fairly conclusive and strongly suggestive' the incidence was high (60%).

Incidence of associated findings (Table 7) In order to find out the features that might be pointers to right ventricular hypertrophy in the absence of the classical pattern and of right bundle-branch block, the incidence of certain electrocardiographic features, commonly seen in cor pulmonale, was estimated.

It is seen from Table 7 that the incidence of associated findings in 'classical' right ventricular hypertrophy and the more equivocal pattern (QS in all chest leads) was the same, i.e. rS pattern in V₅-V₆, right axis deviation, qR in aVR, and P pulmonale in that order. In the third group in which from all other sources right ventricular hypertrophy was present, though the electrocardiogram in the right chest leads did not show right ventricular hypertrophy, the associated abnormalities except for P pulmonale occurred in the same order. These features are further elaborated under discussion.

Discussion

P wave The incidence of P pulmonale has been variable: 13.9 per cent (Spodick, 1959), 15.5 per cent (Caird and Wilcken, 1962), 29 per cent (Chappell, 1966), 46.2 per cent (Calatayud *et al.*, 1970), and 95 per cent in the present series, which might be due to the long follow-up and severe pulmonary disease. P pulmonale has been used as indirect evidence of right ventricular hypertrophy by various authors (Winternitz, 1935; Hecht, 1937; Katz, 1946; Wood, 1948; Kilpatrick, 1951;

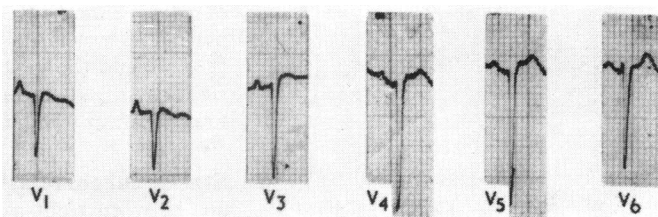
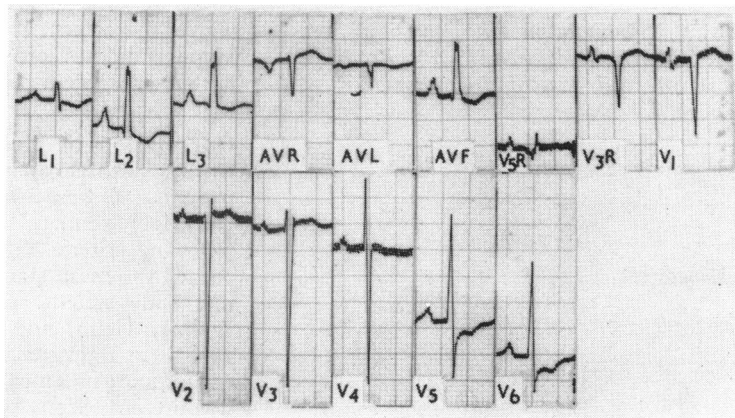


FIG. 6 Deep QS waves in chest leads. Earlier record showed normal pattern. Note the resemblance to anterior myocardial infarction.

Lepeschkin, 1951; Phillips, 1958). Others regarded it as a positional change and have ascribed it to hyperinflation, vertical position, and lowering of the diaphragm (Spodick, 1959; Caird and Wilcken, 1962; Phillips, 1958; Nordenfelt, 1941; Myers, Klein, and Stofer, 1948; Goldberger and Schwartz, 1946; Shlezer and Langendorf, 1942; Fox and Kremer, 1943). Its presence has been related to acute events, e.g. bronchial asthma with change in position. A recent study on P wave amplitude has shown a positive correlation with radiological evidence of chronic obstructive lung disease but no relation with x-ray evidence of right or left ventricular enlargement (Calatayud *et al.*, 1970).

P pulmonale in this study did not correlate with right ventricular thickness or pulmonary artery pressure. No correlation has been found in other studies (Caird and Wilcken, 1962). Though it was present in all except 30

FIG. 7 Combined ventricular hypertrophy. Accepted criteria for right and left ventricular hypertrophy are present. The patient had no disease other than chronic cor pulmonale.



out of 544 patients at some time or other in the electrocardiogram, great variations in its amplitude at short intervals were observed, which could not possibly be related to right ventricular hypertrophy. Its occurrence must be attributed largely to positional and partly to haemodynamic changes, but it cannot be designated an unequivocal criterion of right ventricular hypertrophy.

P axis The incidence of P axis over $+70^\circ$ in chronic cor pulmonale has been mostly higher in previous studies: 80 per cent by Zuckermann *et al.* (1948), 79 per cent by Caird and Wilcken (1962), 73 per cent by Spodick (1959), and 29 per cent by Chappell (1966). Right axis deviation has been attributed to definite right atrial hypertrophy (Caird and Wilcken, 1962; Zuckermann *et al.*, 1948; Coelho *et al.*, 1962), while others considered it positional and related to severity of airway obstruction, as judged by lung function tests and x-ray (Chappell, 1966; Calatayud *et al.*, 1970; Sodi-Pallares and Calder, 1956; Goldberger and Schwartz, 1946; Prineas, Tibblin, and Rose, 1968; Fowler *et al.*, 1965; Millard, 1967). In the present study rightward shift of the P axis showed significant correlation with QRS axis (5% level), suggesting that the two were related. It is further supported by the fact that in the present series the number showing shifts to the right increased in the serial records as did QRS axis with progress in the severity of disease as also found by Calatayud *et al.* (1970).

Right deviation of QRS axis The incidence of right axis deviation has varied from 46 to 85 per cent (Chappell, 1966; Wood, 1948; Kilpatrick, 1951; Coelho *et al.*, 1962; Millard, 1967; Milnor, 1957; Dines and Parkin, 1965). Right axis deviation has been suggested as a sign of right ventricular hypertrophy and of dilatation, as in acute cor pulmonale (Milnor, 1957; Einthoven, 1906, 1908; Phillips and Burch, 1963; Roman, Walsh, and Massie, 1961; Selvester and Rubin, 1965; Packard, Graettinger, and Graybiel, 1954; Oram and Davies, 1967; Goldberger, 1944). The incidence of right axis deviation was certainly very high when serial records were considered. It showed a relation to right ventricular thickness and to increase in pulmonary artery pressure. It correlated significantly with classical right ventricular hypertrophy and with clockwise rotation (at 5% level). In a comparative study of right axis deviation in 1123 cases of right ventricular hypertrophy in 3 aetiological groups, the incidence of right axis deviation was much higher

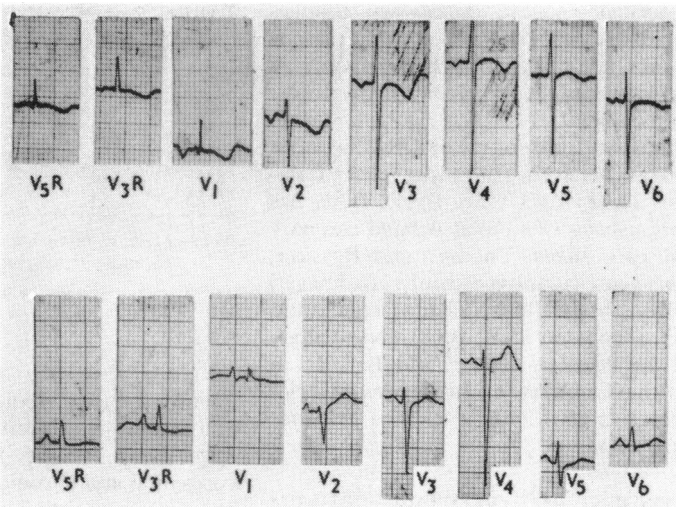


FIG. 8 *Transient diffuse T wave changes. First tracing on 12 December 1964 during acute illness; second tracing 2 January after treatment.*

in chronic cor pulmonale (53.4%) than in congenital heart disease and mitral stenosis (47.3, 20.7%, respectively) (Raizada and Padmavati, 1971). This suggests that it is perhaps more significant in this entity than in the others.

Changes in the degree of right axis deviation and its development for the first time are common in pulmonary embolism with sudden right ventricular dilatation. Necropsy studies suggest that in chronic cor pulmonale, dilatation and hypertrophy go together, making right axis deviation an important part of the electrocardiographic picture. The changes in right axis deviation seen in this series may be due to such acute episodes of pulmonary

TABLE 4 *Correlation of electrocardiographic and haemodynamic findings (percentages in brackets)*

Mean pressure (mmHg)	No. of cases	Normal axis	Right axis deviation ($+100^\circ$ to $\pm 180^\circ$)	P pulmonale	Classical right ventric. hypertrophy	QS all praecordial leads
Up to 15	3	2 (66.6)	0*	3 (100)	2 (66.6)	1
16-30	20	11 (55.0)	9 (45.0)	14 (70)	16 (80.0)	4 (20.0)
31-50	23	5 (21.73)	18 (78.26)	13 (56.5)	19 (82.6)	4 (17.4)
Over	5	0	5 (100)	5 (100)	5 (100)	

* One patient showed left axis deviation.

artery occlusion or to pulmonary changes (Oram and Davies, 1967). It appears reasonable to conclude that right axis deviation may be equated with right ventricular hypertrophy in large measure.

Left axis deviation of mean QRS has been reported as between 10–12 per cent (Calatayud *et al.*, 1970; Grant, 1956). This has been variously ascribed to associated coronary artery disease (Rees, Thomas, and Rossiter, 1964), left ventricular hypertrophy (Padmavati and Joshi, 1964; Fluck, Chandrasekar, and Gardner, 1966; Rao *et al.*, 1968), and to alteration of the electrical field around the heart in emphysema (Grant, 1956). In the present series of 12 cases (2.2%), only 2 showed evidence of hypertension.

Right ventricular hypertrophy patterns in right chest leads The dominant pattern in this series was a qR with R less than 5 mm in the majority. This interchanged freely with the rsR' in serial records and sometimes in the same record. The genesis of 'q' in cor pulmonale has been explained by various hypotheses, e.g. activation of crista supraventricularis (Zuckermann *et al.*, 1948; Sodi-Pallares and Calder, 1956; Kossmann *et al.*, 1948; Mack, Harris, and Katz, 1950), registration of left ventricle potentials through a dilated right atrium (Lepeschkin, 1951; Myers *et al.*, 1948; Goldberger and Schwartz, 1946; Wilson *et al.*, 1944), stimulation of septum from right to left (Lepeschkin, 1951), right atrial dilatation (Sodi-Pallares and Calder, 1956; Burch and DePasquale, 1963; Rosenbaum, 1950; Armstrong, 1940; East, 1940), and as representing the 's' of an rsR' pattern (Fowler and Helm, 1953). In the last it has been postulated that the initial 'r' wave due to septal activation is not recorded in VI due to spread of activity in a plane parallel to that of the lead, so that the initial 'q' really represents the 's' of the rsR' pattern. The present study supports this last view. The interchangeability of the patterns suggests that there is a basic diastolic overload pattern which reappears from time to time (perhaps due to changes in blood viscosity and other factors), on which is superimposed a moderate systolic overload picture (Mack *et al.*, 1950; Burch and Depasquale, 1963; Cabrera and Monroy, 1952; Platts, Hammond, and Stuart-Harris, 1960; Widimsky *et al.*, 1960). Complete right bundle-branch block appears not to be an important feature of isolated chronic cor pulmonale in this study.

Concentric hypertrophy patterns (Rs and R) are much less common in chronic cor pulmonale and have been previously reported to

TABLE 5 *Correlation of electrocardiogram and right ventricular wall thickness*

Thickness (mm)	No. of cases	Right axis deviation	P pulmonale	Classical right ventric. hypertrophy	QS in all praecordial leads
5–10	13	7	6	11	2
11–15	4	3	—	4	—

Note—Mean right ventricular wall thickness – 8.9 mm (range 4.7 to 15 mm).
Mean heart weight – 343.9 g (range 240–500 g).

be due to systolic overload (Cabrera and Monroy, 1952; Sodi-Pallares, Bisteni, and Herrmann, 1952), and has its corollary in lower heart weights in this condition than congenital and chronic valvular disease (Scott and Garvin, 1941; Zimmerman *et al.*, 1957). It can be further explained by comparatively moderate degrees of hypertrophy of the free wall and also by right ventricular dilatation (Wood, 1948; Mack *et al.*, 1950), which sets in side by side with hypertrophy, the so-called phenomenon of 'variable overload' (Mack *et al.*, 1950; Cabrera and Monroy, 1952). Burch and DePasquale (1963), in reviewing the genesis of right ventricular hypertrophy in cor pulmonale, stressed the greater importance of hypertrophy of the crista supraventricularis due to volume overload as compared to hypertrophy of the free wall which is a later development.

Left ventricular hypertrophy The relatively high incidence of lone left ventricular hypertrophy and combined ventricular hypertrophy could only be partially explained on the basis of associated hypertension and possible ischaemic heart disease. Left ventricular hypertrophy in chronic cor pulmonale has been explained on the basis of bronchopulmonary shunts, hypoxia, and the heart functioning as a single unit in hypertrophy (Padmavati and Joshi, 1964; Rao *et al.*, 1968; Grant, 1956; Scott and Garvin, 1941; Spain and Handler, 1946; Waltzer and Frost, 1954; Michelson, 1960; Altschule, 1962). It was not possible to isolate these factors in this study.

TABLE 6 *Incidence of right ventricular hypertrophy by various criteria*

Sokolow and Lyon (1949)	106	19.4
Milnor (1957)	81	14.9
Phillips and Burch (1963)	325	59.7

TABLE 7 Right ventricular hypertrophy patterns and associated electrocardiographic findings in chronic cor pulmonale

Groups	No. of cases	Dominant S in V ₅ V ₆		Right axis deviation		qR in aVR		P pulmonale	
		No. of cases	Per cent	No. of cases	Per cent	No. of cases	Per cent	No. of cases	Per cent
1: Classical right ventricular hypertrophy	344	295	85.7	211	61.3	178	51.7	143	41.6
2: QS all praecordial leads	38	38	100	30	78.9	25	65.8	22	57.99
3: No ventricular hypertrophy in praecordial leads	123	57	46.3	27	21.9	24	19.5	38	30.9

Note: Total percentage exceeds 100, as the features overlapped in the series.

r/S pattern in V₅-V₆ The large number of patients showing a dominant S wave in V₅-V₆ in this series confirms the impression of others that it is an important pointer to right ventricular hypertrophy, (Spodick, 1959; Selvester and Rubin, 1965; Sokolow and Lyon, 1949). Silver and Calatayud (1971), in a group of 173 patients with chronic obstructive pulmonary disease and the most impaired lung function, found that the best QRS criteria were RV₆ amplitude of 0.5 mV or less and R/S ratio in V₆ of 1 or less.

T wave changes T waves were the most labile of all the complexes in the electrocardiogram. Inversion in right chest leads has been explained on the basis of right ventricular dilatation and strain (Katz, 1946; Wood, 1948; Kilpatrick, 1951; Goldberger and Schwartz, 1946; Coelho *et al.*, 1962; Armen, Kantor, and Weiser, 1958). In this study they did not correlate with either pulmonary artery pressure or right ventricular thickness.

Generalized T wave inversion may be a non-specific phenomenon related to hypoxia or to ptosis of the heart due to emphysema (Spodick, 1959; Caird and Wilcken, 1962; Wood, 1948; Kilpatrick, 1951). It may be analogous to conditions such as anaemia and myxoedema. It has also been reported to occur in pulmonary embolism, both in right and in left chest leads (Oram and Davies, 1967). The fact that in cor pulmonale the highest incidence of such generalized T inversion was found as compared to other diseases with right ventricular hypertrophy supports such a theory (Raizada and Padmavati, 1971). T inversion in the left chest leads must be considered as due to left ventricular hypertrophy, even in the absence of voltage criteria. Such extensive T wave changes have not been reported previously, to the best of our knowledge, except from Delhi (Padmavati and Joshi, 1964; Padmavati and Pathak, 1959).

qR in aVR This pattern has been equated with right ventricular hypertrophy by many authors (Wood, 1948; Kilpatrick, 1951; Myers *et al.*, 1948; Coelho *et al.*, 1962; Phillips and Burch, 1963; Padmavati, 1970). It showed a significant correlation with classical right ventricular hypertrophy at the 5 per cent level and must be regarded as an important pointer of right ventricular hypertrophy, even in the absence of the classical pattern.

Criteria for right ventricular hypertrophy in chronic cor pulmonale The reasons for the higher percentage of positive right ventricular hypertrophy using Phillips criteria (Phillips and Burch, 1963) of 'fairly conclusive and suggestive' were because of the use of associated electrocardiographic features in the absence of the classical right ventricular hypertrophy pattern (Padmavati, 1970).

Thus, while the criteria of Sokolow and Lyon (1949) and Milnor (1957) use a dominant R wave of definite voltage as the main criterion for the diagnosis of right ventricular hypertrophy, Phillips and Burch (1963) use various associated features which may be present depending on whether the main cardiac vector is directed posteriorly or superiorly and inferiorly or anteriorly. Thus, for their 'fairly conclusive and suggestive' evidence, they use obvious right axis deviation, QS, QR, and qR patterns in V₁-V₃, and r/S ratio in V₅ below 1. Less diagnostic but suggestive are giant P pulmonale, complete right bundle-branch block, well-developed or embryonic 'r' in right chest leads, and R/S above 1 in aVR.

From the data given in this study, clockwise rotation, right axis deviation, qR in aVR, and P pulmonale in that order would also be pointers to right ventricular hypertrophy in a case of chronic cor pulmonale in which the classical pattern is absent.

It is postulated that right ventricular hypertrophy may be inferred from the associated abnormalities mentioned above in the absence of the classical patterns of right ventricular hypertrophy and/or incomplete right bundle-branch block. As P pulmonale is a variable entity as shown elsewhere in this paper it is probably the least important of these associated features.

References

- Altschule, M. D. (1962). Cor pulmonale: a disease of the whole heart. *Diseases of the Chest*, **41**, 398.
- Armen, R. N., Kantor, M., and Weiser, N. J. (1958). Pulmonary heart disease with emphasis on ECG diagnosis. *Circulation*, **17**, 164.
- Armstrong, T. G. (1940). Failure of the right ventricle. *British Heart Journal*, **2**, 201.
- Burch, G. E., and DePasquale, N. P. (1963). The ECG diagnosis of pulmonary heart disease. *American Journal of Cardiology*, **11**, 622.
- Cabrera, C. E., and Monroy, J. R. (1952). Systolic and diastolic loading of the heart. II. Electrocardiographic data. *American Heart Journal*, **43**, 669.
- Caird, F. I., and Wilcken, D. E. L. (1962). The electrocardiogram in chronic bronchitis with generalized obstructive lung disease and its relation to ventilatory function. *American Journal of Cardiology*, **10**, 5.
- Calatayud, J. B., Abod, J. M., Khoi, N. B., Stanbro, W. W., and Silver, H. M. (1970). P wave changes in chronic obstructive pulmonary disease. *American Heart Journal*, **79**, 444.
- Chappell, A. G. (1966). The ECG in chronic bronchitis and emphysema. *British Heart Journal*, **28**, 517.
- Coelho, E., Amram, S. S., Sa, A. B., Mendes, J. C. F., and Tavares, V. (1962). ECG and VCG alterations in chronic cor pulmonale. *American Journal of Cardiology*, **10**, 20.
- Dines, D. E., and Parkin, T. W. (1965). Some observations on the value of the electrocardiogram in patients with chronic cor pulmonale. *Proceedings of the Staff Meetings of the Mayo Clinic*, **40**, 745.
- East, T. (1940). Pulmonary hypertension. *British Heart Journal*, **2**, 189.
- Einthoven, W. (1906). Le telecardiogramme. *Archives Internationales de Physiologie*, **4**, 132.
- Einthoven, W. (1908). Weiteres über das Elektrokardiogramm. *Pflügers Archiv für die gesamte Physiologie*, **122**, 517.
- Fluck, D. C., Chandrasekar, R. G., and Gardner, F. V. (1966). Left ventricular hypertrophy in chronic bronchitis. *British Heart Journal*, **28**, 92.
- Fowler, N. O., Daniels, C., Scott, R. C., Faustino, B. S., and Gueron, M. (1965). The ECG in cor pulmonale with and without emphysema. *American Journal of Cardiology*, **16**, 500.
- Fowler, N. O., and Helm, R. A. (1953). The spatial QRS loop in right ventricular hypertrophy with special reference to the initial component. *Circulation*, **7**, 573.
- Fox, T. T., and Kremer, H. S. (1943). The heart in pulmonary tuberculosis: studies of the auricular complex in the electrocardiogram. *American Review of Tuberculosis and Pulmonary Diseases*, **47**, 135.
- Goldberger, E. (1944). An interpretation of axis deviation and ventricular hypertrophy. *American Heart Journal*, **28**, 621.
- Goldberger, E., and Schwartz, S. P. (1946). Electrocardiograms in chronic pulmonary disease. *American Review of Tuberculosis and Pulmonary Diseases*, **53**, 34.
- Grant, R. P. (1956). Left axis deviation: an electrocardiographic-pathologic correlation study. *Circulation*, **14**, 233.
- Hecht, H. (1937). Linkstyp und Rechtstyp im Elektrokardiogramm. *Deutsche medizinische Wochenschrift*, **63**, 441.
- Katz, L. N. (1946). *Electrocardiography*, 2nd ed. Lea and Febiger, Philadelphia.
- Kilpatrick, J. A. (1951). Electrocardiographic changes in chronic cor pulmonale. *British Heart Journal*, **13**, 309.
- Kossmann, C. E., Berger, A. R., Brumlik, J., and Briller, S. A. (1948). Analysis of causes of right axis deviation based partly on endocardial potentials of the hypertrophied right ventricle. *American Heart Journal*, **35**, 309.
- Lepeschkin, E. (1951). *Modern Electrocardiography*. Williams and Wilkins, Baltimore.
- Mack, I., Harris, R., and Katz, L. N. (1950). Acute cor pulmonale in absence of pulmonary embolism. *American Heart Journal*, **39**, 664.
- Michelson, N. (1960). Bilateral ventricular hypertrophy due to chronic pulmonary disease. *Diseases of the Chest*, **38**, 435.
- Millard, F. J. C. (1967). The electrocardiogram in chronic lung disease. *British Heart Journal*, **29**, 43.
- Milnor, W. R. (1957). Electrocardiogram and vectorcardiogram in right ventricular hypertrophy and right bundle-branch block. *Circulation*, **16**, 348.
- Myers, G. B., Klein, H. A., and Stofor, B. E. (1948). The electrocardiographic diagnosis of right ventricular hypertrophy. *American Heart Journal*, **35**, 1.
- Nordenfelt, O. (1941). Ueber Funktionelle Veränderungen der P und T Zacken im Elektrokardiogramm. *Acta Medica Scandinavica*, **119**, Suppl.
- Oram, S., and Davies, P. (1967). The electrocardiogram in cor pulmonale. *Progress in Cardiovascular Diseases*, **9**, 341.
- Packard, J. M., Graettinger, J. S., and Graybiel, A. (1954). Analysis of electrocardiograms obtained from 1000 young healthy aviators. *Circulation*, **10**, 384.
- Padmavati, S. (1970). Chronic cor pulmonale. *Cardiovascular Clinics*, **2**, 128.
- Padmavati, S., and Joshi, B. (1964). The incidence and etiology of chronic cor pulmonale in Delhi. *Diseases of the Chest*, **46**, 457.
- Padmavati, S., and Pathak, S. N. (1959). Chronic cor pulmonale in Delhi: a study of 127 cases. *Circulation*, **20**, 343.
- Phillips, J. H., and Burch, G. E. (1963). Problems in the diagnosis of cor pulmonale. *American Heart Journal*, **66**, 818.
- Phillips, R. W. (1958). The electrocardiogram in cor pulmonale secondary to pulmonary emphysema. A study of 18 cases proved by autopsy. *American Heart Journal*, **56**, 352.
- Platts, M. M., Hammond, J. D. S., and Stuart-Harris, C. H. (1960). A study of cor pulmonale in patients with chronic bronchitis. *Quarterly Journal of Medicine*, **29**, 559.
- Prineas, R. J., Tibblin, G., and Rose, G. (1968). Electrocardiographic patterns of respiratory disease in a working population. *British Heart Journal*, **30**, 859.
- Raizada, V., and Padmavati, S. (1971). ECG in RVH of varied etiology. *Journal of the Association of Physicians of India*, **19**, 349.

- Rao, S. B., Cohn, K. E., Eldridge, F. L., and Hancock, E. W. (1968). Left ventricular failure secondary to chronic pulmonary disease. *American Journal of Medicine*, **45**, 229.
- Rees, H. A., Thomas, A. J., and Rossiter, C. (1964). Recognition of coronary heart disease in the presence of pulmonary disease. *British Heart Journal*, **26**, 233.
- Roman, G. T., Walsh, T. J., and Massie, E. (1961). Right ventricular hypertrophy: correlation of electrocardiographic and anatomic findings. *American Journal of Cardiology*, **7**, 481.
- Rosenbaum, F. F. (1950). Clinical electrocardiography. In *Oxford Loose-Leaf Medicine*, Vol. II, p. 370. Ed. by H. A. Christian. Oxford University Press, London and New York.
- Scott, R. C. (1960). Correlation between electrocardiographic patterns of ventricular hypertrophy and the anatomic findings. *Circulation*, **21**, 256.
- Scott, R. W., and Garvin, C. F. (1941). Cor pulmonale - observations in fifty autopsy cases. *American Heart Journal*, **22**, 56.
- Selvester, R. H., and Rubin, H. B. (1965). New criteria for the electrocardiographic diagnosis of emphysema and cor pulmonale. *American Heart Journal*, **69**, 437.
- Shlezer, I. H., and Langendorf, R. (1942). Significance of so-called P-pulmonale pattern in the electrocardiogram. *American Journal of the Medical Sciences*, **204**, 725.
- Silver, H. M., and Calatayud, J. B. (1971). Evaluation of QRS criteria in patients with chronic obstructive pulmonary disease. *Chest*, **59**, 153.
- Sodi-Pallares, D., Bisteni, A., and Herrmann, G. R. (1952). Some views on the significance of qR and QR type complexes in right precordial leads in the absence of myocardial infarction. *American Heart Journal*, **43**, 716.
- Sodi-Pallares, D., and Calder, R. M. (1956). *New Bases of Electrocardiography*. C. V. Mosby, St. Lewis.
- Sokolow, M., and Lyon, T. P. (1949). The ventricular complex in right ventricular hypertrophy as obtained by unipolar precordial and limb leads. *American Heart Journal*, **38**, 273.
- Spain, D. M., and Handler, B. J. (1946). Chronic cor pulmonale. *Archives of Internal Medicine*, **77**, 37.
- Spodick, D. H. (1959). Electrocardiographic studies in pulmonary disease. II. Establishment of criteria for the electrocardiographic influence of diffuse lung disease. *Circulation*, **20**, 1073.
- Walker, I. C., Helm, R. A., and Scott, R. C. (1955). Right ventricular hypertrophy. I. Correlation of isolated right ventricular hypertrophy at autopsy with the electrocardiographic findings. *Circulation*, **11**, 215.
- Waltzer, I., and Frost, T. T. (1954). Cor pulmonale: a consideration of clinical and autopsy findings. *Diseases of the Chest*, **26**, 192.
- Widimsky, J., Valach, A., Dejdar, R., Fejfar, Z., Vyslonzil, Z., and Lukes, M. (1960). The electrocardiographic pattern of right ventricular hypertrophy in cor pulmonale (due to pulmonary tuberculosis). *Cardiologia*, **36**, 287.
- Wilson, F. N., Johnston, F. D., Rosenbaum, F. F., Erlanger, H., Kossman, C. E., Hecht, H., Cotrim, N., de Oliveira, R. M., Scarsi, R., and Barker, P. S. (1944). The precordial electrocardiogram. *American Heart Journal*, **27**, 19.
- Winternitz, M. (1935). Zur Pathologie des menschlichen vorhofelektrokardiogramms. *Medizinische Klinik*, **31**, 1575.
- Wood, P. (1948). Electrocardiographic appearances in acute and chronic pulmonary heart disease. *British Heart Journal*, **10**, 87.
- Zeek, P. M. (1942). Heart weight. I. The weight of the normal human heart. *Archives of Pathology*, **34**, 820.
- Zimmerman, H. A., Kay, E. B., Mackrell, J., and Sambhi, M. P. (1957). Indications and contra-indications for open cardiac surgery. *American Heart Journal*, **54**, 727.
- Zuckermann, R., Cabrera, E., Fishleder, B. L., and Sodi-Pallares, D. (1948). Electrocardiogram in chronic cor pulmonale. *American Heart Journal*, **35**, 421.

Requests for reprints to Dr. S. Padmavati, 70, Lodi Estate, New Delhi, India.