

Phonocardiogram and apex cardiogram in systolic click—late systolic murmur syndrome

E. J. Epstein and N. Coulshed

From Liverpool Regional Cardiac Centre, Sefton General Hospital, Liverpool

A series of 46 patients with a systolic click and mid-late systolic murmur has been described. All had detailed phonocardiographic and external pulse wave studies. Nine patients also had cardiac catheter studies, of whom 8 had left ventricular cineangiography. They were divided into two groups. In group 1 there were 38 patients where the systolic click and murmur were an isolated finding, and in group 2 there were 8 patients where there was associated chronic rheumatic mitral valve disease.

Group 1 patients showed considerable variation in the auscultatory findings with respiration, posture, and after amyl nitrite inhalation. On standing the click occurred earlier in systole and often blended with the first heart sound and the systolic murmur lengthened. On squatting the click became later and the systolic murmur shortened or even disappeared. Amyl nitrite also resulted in an earlier click and a longer though often quieter systolic murmur.

Left ventricular cineangiography in 6 of these patients showed mild late mitral regurgitation associated in 5 with prolapse of one of the mitral valve leaflets into the left atrium. The systolic click coincided with the time of maximal leaflet prolapse and was thought to be due to sudden tensing of the chordae tendineae. The onset of the systolic murmur coincided with the onset of mitral regurgitation.

The postural changes appear to be due to physiological changes in mitral valve function. Standing reduces left ventricular end-diastolic volume and the leaflets prolapse earlier into the left atrium since they are closer to the position where prolapse begins. Squatting has the reverse effect by increasing ventricular diastolic volume. Amyl nitrite has a similar effect to standing by reducing diastolic volume.

The apex cardiogram in 31 patients showed an unusual midsystolic dip or retraction coincident with the systolic click. The midsystolic dip and the systolic click moved directionally together with alterations in posture and after amyl nitrite inhalation. Cineangiographic studies suggested that the dip was due to sudden traction on the left ventricular wall by the chordae tendineae attached to the prolapsing leaflet. A midsystolic dip can occur independently of the systolic click or systolic murmur and is probably directly due to the mitral valve leaflet prolapse.

Group 2 patients showed minimal variation in the timing of the systolic click and systolic murmur with alterations in posture and after amyl nitrite inhalation. Six of these 8 patients had a midsystolic dip on the apex cardiogram though left ventricular cineangiography in 2 of these patients showed no evidence of mitral valve leaflet prolapse.

The syndrome is produced by mitral valve dysfunction due to voluminous mitral valve leaflets, elongated or improperly attached chordae tendineae, or abnormal ventricular or papillary muscle contraction. These abnormalities may be due to a wide variety of congenital and acquired disorders. In the majority of patients the long-term prognosis is good but sudden death can occur from cardiac dysrhythmia and there is a risk of infective endocarditis and of progression of the mitral regurgitation.

Phonocardiography and external pulse wave recordings provide useful noninvasive diagnostic information and in the majority of patients obviate the need for cardiac catheterization and ventriculography.

An extra midsystolic sound or systolic gallop rhythm was first described in 1887, by Cuffer and Barbillion, and a similar sound was also described by Potain (1900). Gallavardin (1913) reported 10 patients with midsystolic sounds and in 3 of them pleuropericardial adhesions were later found at necropsy and the sounds were attributed to this abnormality. Further reports subsequently appeared (Lian and DeParis, 1933; Thompson and Levine, 1935; Johnston, 1938). The first phonocardiographic illustration of the systolic extra sound appeared in a paper by Wiedemann (1913), and phonocardiographic studies were also reported by Lian and DeParis (1933) and Johnston (1938).

Late systolic murmurs at the apex are often associated with midsystolic sounds or systolic clicks, though in the earlier papers on systolic gallop rhythm there is little comment on their significance. Apical late systolic murmurs were thought by Griffith (1892) and Hall (1903) to be due to mitral regurgitation. However, it was later thought that late systolic murmurs at the apex without any other evidence of heart disease were not significant and that such murmurs were extracardiac in origin (Lewis, 1918; Mackenzie, 1925; Evans, 1943). McKusick (1958) thought that the late systolic murmur, particularly when associated with abnormal T waves on the electrocardiogram, was of pericardial origin.

In 1961, Reid suggested that the systolic click and late systolic murmur were arising at the mitral valve, the click being due to abrupt tensing of the chordae tendineae producing a 'chordal snap' and the systolic murmur being due to mitral regurgitation in late systole. A late systolic murmur at the apex with or without a systolic click was shown by left ventricular cineangiography to be due to mild mitral regurgitation (Humphries and McKusick, 1962; Barlow *et al.*, 1963; Segal and Likoff, 1964; Tavel, Campbell, and Zimmer, 1965). Left ventricular cineangiography also showed the regurgitation to be related to prolapse of one or both leaflets of the mitral valve (Barlow and Bosman, 1966; Criley *et al.*, 1966; Stannard *et al.*, 1967). The systolic click has been localized to the mitral valve and left atrium by intracardiac phonocardiography (Ronan, Perloff, and Harvey, 1965; Leon *et al.*, 1966).

Barlow *et al.* (1968) reviewed a large series of patients and noted obvious changes in the timing and intensity of the systolic click and systolic murmur with respiration, with changes in posture, during the Valsalva manoeuvre, and after amyl nitrite inhalation. Postural changes were also systematically investigated by Fontana *et al.* (1970).

A familial association has been found in some

patients with this syndrome (Stannard *et al.*, 1967; Barlow *et al.*, 1968; Shell *et al.*, 1969; Hunt and Sloman, 1969). Sudden death has also occasionally been reported (Hancock and Cohn, 1966; Barlow *et al.*, 1968; Shell *et al.*, 1969), and is probably related to cardiac dysrhythmia, which affects some patients with the systolic click – late systolic murmur syndrome particularly after exercise (Pocock and Barlow, 1970; Sloman, Wong, and Walker, 1972; Gooch *et al.*, 1972). More recently echocardiographic findings have been reported in patients with this disorder, which show abnormal motion of the mitral valve leaflets (Kerber, Isaef, and Hancock, 1971; Dillon *et al.*, 1971).

The purpose of this paper is to present a detailed study of the phonocardiogram and external pulse wave recordings in a series of patients with the systolic click – late systolic murmur syndrome, who have been seen at the Liverpool Regional Cardiac Centre. In addition, an attempt has been made to correlate some of the features of the left ventricular cineangiogram with changes in the apex cardiogram.

Patients and methods

Forty-six patients have been studied, and the patients were divided clinically into two groups.

Group 1 consisted of 38 patients with a systolic click and a late systolic murmur, without any other pathological murmur.

Group 2 consisted of 8 patients with systolic clicks and systolic murmurs associated with chronic rheumatic mitral valve disease.

Patients with isolated systolic clicks or isolated late systolic murmurs were not included in this study.

All had a complete history and physical examination including posteroanterior and oblique chest *x*-rays, and a twelve-lead electrocardiogram.

Auscultation was carried out in the supine position and also in the left lateral, sitting, standing, and squatting positions. Each patient had a complete phonocardiographic study including carotid, jugular, and apex cardiogram pulse wave recordings, using methods which have been previously described (Coulshed and Epstein, 1963; Epstein *et al.*, 1968). Care was taken to ensure that the external pulse wave pickup had an adequate time constant (Roberts and Jones, 1963). Phonocardiograms were also systematically carried out in 38 patients during various postural manoeuvres, which included the left lateral, sitting, standing, and squatting positions. In addition, sound records were obtained after amyl nitrite inhalation in 15 patients. Apex cardiograms were also studied during changes in posture in 18 patients and after amyl nitrite inhalation in 8 patients.

Cardiac catheter studies were carried out in 9 patients. Left ventricular cineangiography was performed in the right anterior oblique projection in 8 patients, 6 from

group 1 and 2 from group 2. Additional left anterior oblique cineangiograms were also carried out in 2 patients from group 1 and 1 patient from group 2. In one group 1 patient left ventricular cineangiography was repeated during the Valsalva manoeuvre. Coronary arteriography was performed in 2 patients from group 1.

Intracardiac sound records were obtained in 3 group 1 patients using a Telco micromanometer adapted for use with a Cambridge multichannel recorder.

Results

Group 1

Isolated systolic click and mid-late systolic murmur *Clinical findings* In group 1 there were 38 patients – 23 women and 15 men. Their ages ranged from 20 to 71 years. Nineteen were under 40 years and 19 were over 40 years of age. Seven patients were 60 years or more (4 women and 3 men).

Four patients gave a definite history and 1 patient gave a possible history of rheumatic fever.

The commonest symptoms in group 1 patients were mild effort breathlessness in 16; chest pain in 15, of whom 9 had true angina of effort; palpitations in 13, of whom 5 had bouts of paroxysmal tachycardia; fatigue in 8; syncope in 6. Ten patients were completely asymptomatic.

Associated findings of possible aetiological significance were present in 26 patients. Three patients had Marfan's syndrome; 1 had an Eisenmenger atrial septal defect; 2 had hypertension; 9 had ischaemic heart disease; 2 had hyperthyroidism; 1 had a left-sided fibrothorax; 3 had a flattened dorsal spine with a narrow anteroposterior chest diameter; 1 had multiple sclerosis; 1 had Meig's syndrome; 2 patients, a mother and daughter, were familial.

The physical signs were generally unremarkable apart from the auscultatory findings. All patients were in sinus rhythm with a good volume pulse. Cardiac enlargement was rarely found and hypertension was present in 2 patients. In 17 patients the cardiac impulse was unusual in that a transient systolic retraction of the apex beat was palpable particularly with the patient in the left lateral position. All patients had a systolic click and a mid-late systolic murmur, both of which showed variations in timing particularly with alterations in posture. The systolic murmur was usually loudest just internal to the apex and best heard in the semi-left lateral position. Five patients had intermittent late systolic whoops which were more frequently present when sitting or standing.

In 9 patients the systolic murmur had been present for 10 years or more. The murmur had been known to be present in 1 patient for 42 years. The longest direct follow-up was for a period of 14 years.

Electrocardiographic findings Seven patients had spontaneous ectopic beats, supraventricular in 1, ventricular in 5, and of both types in 1 patient. The PR interval was 200 msec in 4 patients and more than 220 msec in 1 patient. In the remainder the PR interval was less than 200 msec. Five patients gave a history suggestive of paroxysmal tachycardia though electrocardiographic documentation of an attack was available in only 1 patient.

T wave abnormalities were fairly common. The T waves were inverted in lead II in 2 patients; in lead III in 8; in lead aVF in 2; in lead aVL in 4; in leads V5–V6 in 4 patients. Diphasic T waves were present in lead II in 4 patients, and in lead aVF in 3 patients. Five patients had a pattern of 'inferior ischaemia' with inverted or flat T waves in both leads III and aVF. Four patients showed 'lateral ischaemia' with inverted or flat T waves in leads I, II, and aVL, and occasionally V6. One of these patients had previously had an acute myocardial infarction.

Slight ST segment depression was present in 5 patients in the inferolateral leads and in 1 patient in the anterolateral leads. Pathological Q waves were present in only 1 patient who had had a previous myocardial infarction.

Prominent 'U' waves were present in 19 patients particularly in leads II, III, aVF, and V4 to V6. Four patients showed the electrocardiographic pattern of anteriosuperior hemiblock and 2 of these patients had angina of effort.

Phonocardiographic findings Typical phonocardiographic records of the systolic click – late systolic murmur syndrome are shown in Fig. 1. The onset of the systolic murmur followed the systolic click in 22 patients and preceded the click in 16 patients. The systolic murmur generally stopped at the aortic component of the second sound though in 9 patients the murmur clearly extended beyond it. In 27 patients only 1 systolic click was present, in 9 patients there were 2 clicks, and in 1 patient there were 3 clicks. An early systolic sound followed the major vibrations of the first heart sound in 5 patients. An early diastolic sound 80 to 100 msec after the aortic second sound was present in 6 patients.

Postural studies Phonocardiograms were carried out during changes of posture in 34 patients. Records were obtained when lying, sitting, standing, and squatting. In general, the systolic click moved towards the first heart sound on sitting or standing and the systolic murmur became longer. Not infrequently the systolic click merged with the first heart sound and the systolic murmur became pansystolic. On squatting the systolic click moved to-

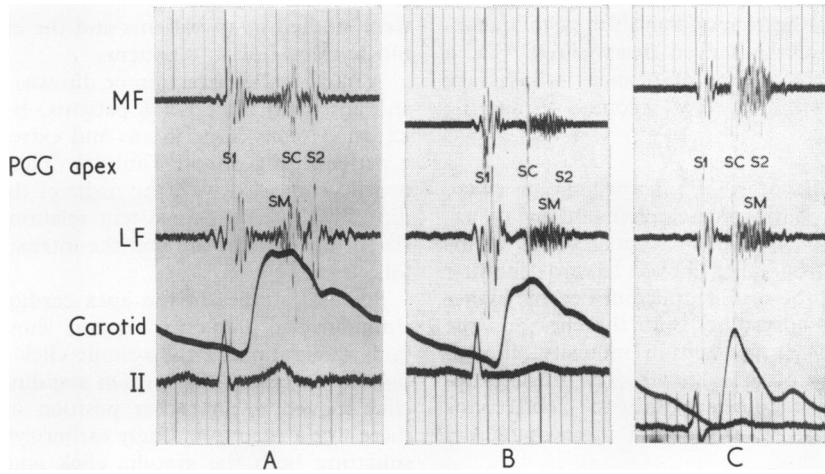


FIG. 1 Variations in the systolic murmur in 3 patients from group 1. Panel A – The systolic murmur (SM) starts well before the systolic click (SC) and ends at the aortic second sound (S2). Panel B – The systolic murmur begins with the systolic click and ends at S2. Panel C – The systolic murmur begins with the systolic click and passes beyond the aortic second sound (S2). Carotid, carotid pulse tracing; II, lead II; MF, medium frequency; LF, low frequency; and S1, first heart sound. Time lines at 40 msec intervals.

Note: The abbreviations apply to all subsequent Figures.

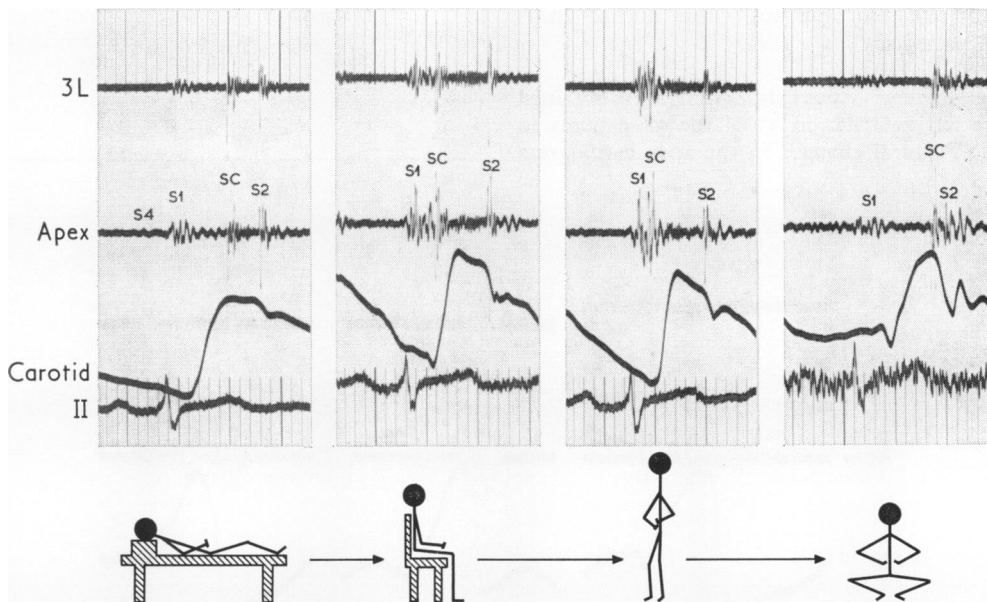


FIG. 2 Postural changes in the phonocardiogram (PCG) in a group 1 patient. Recordings made from 4 positions in rapid succession. Illustrated from left to right are: lying, sitting, standing, and squatting. The position of the patient is shown by the cartoon under each panel.

On sitting and standing the systolic click moves closer towards S1 and the systolic murmur becomes longer. On squatting the systolic click moves towards S2 and the systolic murmur virtually disappears. These changes developed rapidly over a period of a few seconds. Medium frequency tracings; 40 msec time intervals; paper speed 75 mm/sec.

wards the second heart sound and the systolic murmur became shorter or even disappeared. Fig. 2 shows a typical sequence of changes which take place rapidly within a few seconds of altering posture.

Amyl nitrite inhalation Phonocardiograms were performed after amyl nitrite inhalation in 15 patients. In general, within 15 to 20 seconds of inhalation, the systolic click moved towards the first heart sound and the systolic murmur became longer and frequently pansystolic. Both the click and the murmur usually diminished in intensity, though occasionally they became louder. The tracings returned to control conditions within 60 to 90 seconds in most instances. An example of these changes is shown in Fig. 3.

Carotid pulse tracing This was recorded in all 38 patients. The upstroke was rapid in 11 patients and followed by a sharp downslope and then a plateau. However, this did not amount to a definite abnormality and the tracings resembled those often recorded in young people with a brisk circulation and elastic arteries. In 5 patients the peak of the rapid upstroke coincided with the systolic click. The left ventricular ejection time was within normal limits in all 38 patients.

Apex cardiograms Apex cardiograms were obtained over the left ventricle in 37 of the 38 patients in group 1. Postural changes in the apex cardiogram

were studied in 17 patients and the effects of amyl nitrite inhalation in 7 patients.

A midsystolic retraction or dip was present in 31 and absent in the other 6 patients. It was small in 12; moderately large in 16; and extremely large in 3 patients (Fig. 4 and Table 1). The systolic click usually coincided with the nadir of the midsystolic dip. There was no consistent relation between the size of the systolic dip and the intensity of the systolic click.

Postural studies of the apex cardiogram, with a simultaneous phonocardiogram, showed that the midsystolic dip and the systolic click moved directionally together (Fig. 5). On standing the systolic click moved to an earlier position in systole and there was a correspondingly earlier systolic dip. On squatting both the systolic click and systolic dip moved later in systole. Amyl nitrite produced similar effects. About 20 to 30 seconds after inhalation the systolic click and midsystolic dip had moved towards the first heart sound with some reduction in the intensity of the click and a variable change in the

TABLE I

	<i>Apex cardiogram—Midsystolic dip</i>			<i>Dip absent</i>
	<i>Dip present</i>			
	<i>Small</i>	<i>Moderate</i>	<i>Large</i>	
Group 1	12	16	3	6
Group 2	3	3	0	2
Total	15	19	3	8

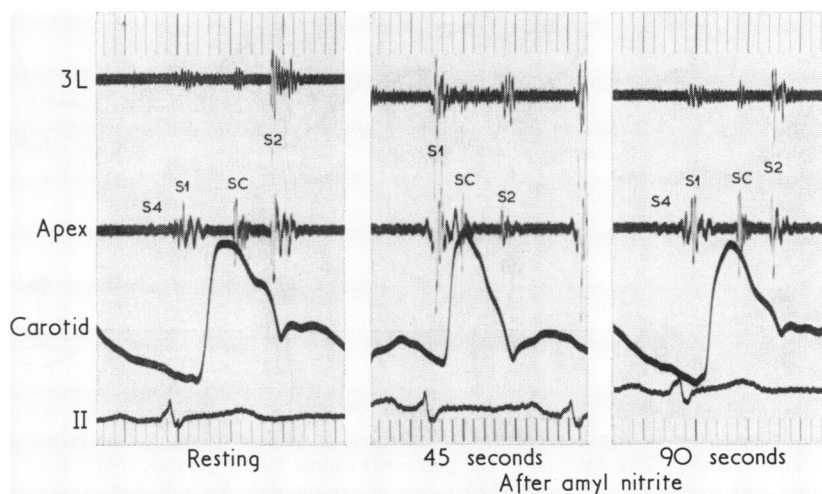


FIG. 3 *Effects of amyl nitrite inhalation in a group 1 patient. After inhalation (30 to 45 sec), the systolic click moves towards S1 and the systolic murmur becomes longer and quieter. There is a return to control conditions within 90 seconds.*

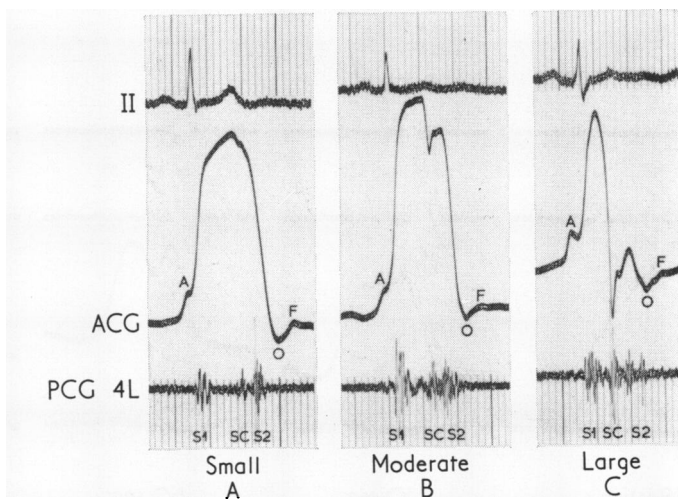


FIG. 4 Left ventricular apex cardiograms (ACG) recorded from group 1 patients illustrating three types of mid-systolic dip. Panel A – Small: A small notch is visible just beyond the summit of the systolic impulse of the apex cardiogram coincident with the systolic click on the phonocardiogram. Panel B – Moderate: There is a prominent incisura or dip in midsystole deforming the summit of the apex cardiogram. The nadir of the dip coincides with the systolic click on the simultaneous phonocardiogram. Panel C – Large: An obvious midsystolic retraction has produced a large negative deflection of the systolic impulse of the apex cardiogram. The nadir of the dip coincides with the systolic click. The systolic dip was clinically palpable at the cardiac apex in the patients illustrated in panels B and C. 'A', atrial wave of the apex cardiogram; 'O', time of mitral valve opening; 'F', peak of early diastolic rapid filling wave. Paper speed 50 mm/sec, 40 msec time lines.

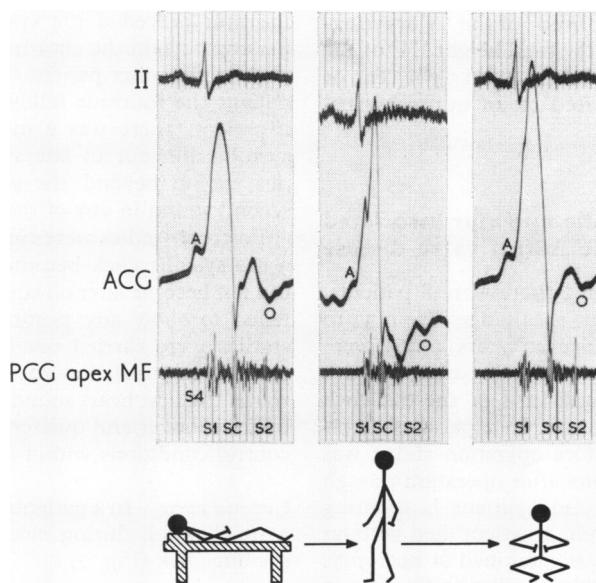


FIG. 5 Postural changes in the apex cardiogram in a group 1 patient with a large mid-systolic dip. The position is shown by the cartoon under each panel. Supine control tracing on the left. On standing (centre panel), the systolic click moves towards S1 and there is a corresponding movement of the systolic dip on the apex cardiogram. On squatting (right-hand panel), both the systolic click and the systolic dip move towards S2. Paper speed 50 mm/sec, 40 msec time lines.

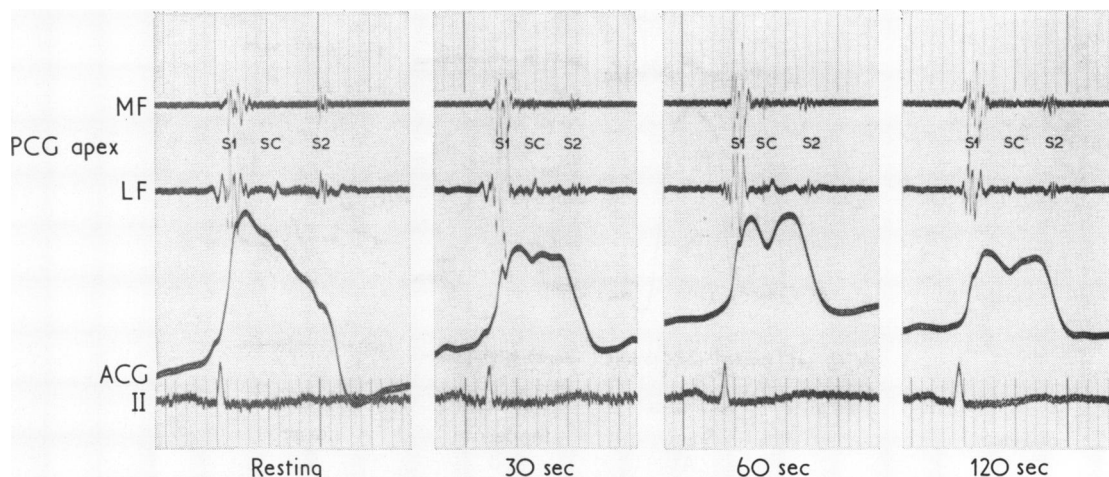


FIG. 6 Effects of amyl nitrite inhalation on the apex cardiogram in a group 1 patient. The resting control tracing shows a very small midsystolic notch coincident with a systolic click (SC). After amyl nitrite the systolic dip becomes more prominent and both the click and the dip occur earlier in systole. There is a return to control conditions within 2 to 3 minutes.

size of the systolic dip. In 4 patients the dip became smaller and in 3 the dip increased in size. Over the subsequent 90 seconds there was usually a return to control appearances (Fig. 6).

The size of the 'A' wave on the apex cardiogram was assessed from the a/H ratio (Epstein *et al.*, 1968). This is defined as the amplitude of the 'A' wave expressed as a percentage of the total height 'H' of the apex cardiogram. The a/H ratio was 15 per cent or more in 7 patients, compared to an upper normal limit of 12.5 per cent.

Group 2

Systolic click and systolic murmur associated with chronic rheumatic mitral valve disease

Clinical findings In group 2 there were 8 patients, 5 women and 3 men. Their ages ranged from 32 to 62 years. Three were under 40 years and 5 were over 40 years of age. Six of the 8 patients had a closed mitral valvotomy and in 4 of these a click was first noted after operation. In 2 patients a systolic click was present before operation and it was still present in both patients after operation though later in timing (Fig. 7). One patient is awaiting mitral valve replacement and 1 patient died without operation and the heart was examined at necropsy.

Four patients were in sinus rhythm and 4 were in atrial fibrillation. The physical signs were those of mitral valve stenosis with the additional auscultatory finding of a systolic click and systolic murmur.

Two patients also had organic tricuspid valve disease and 1 patient had mild aortic valve disease.

The electrocardiogram was unremarkable apart from obvious right ventricular hypertrophy in 1 patient with severe pulmonary arterial hypertension.

Phonocardiographic findings In 3 patients the systolic murmur was pansystolic. The onset of the murmur preceded the systolic click in 4 patients, passing beyond the click in 3 and terminating at the click in the other patient (Fig. 7). In the remaining patient the murmur followed the systolic click. In 2 patients there was a musical component to the systolic murmur in late systole. The murmur did not extend beyond the aortic component of the second sound in any of the patients.

Postural studies were carried out in 4 patients. In 3 the systolic click became earlier on standing but did not become later on squatting. The other patient failed to show any postural change. Amyl nitrite studies were carried out in 2 patients. Within 20 seconds of inhalation the systolic click moved towards the first heart sound and the systolic murmur became longer and quieter. The tracing returned to control conditions within 60 seconds.

Carotid pulse In 4 patients the carotid pulse showed a small notch during ejection coincident with the systolic click (Fig. 7).

Apex cardiogram Apex cardiograms were recorded over the left ventricle in all 8 patients. A midsystolic dip was present in 6 patients. It was very small in 3 and of moderate size in 3 patients (Table 1). The dip coincided with the systolic click. Postural studies

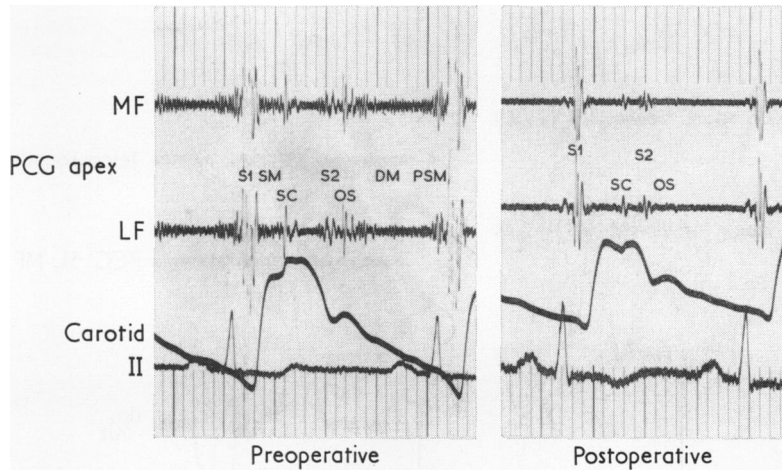


FIG. 7 Phonocardiogram tracing from a 32-year-old woman from group 2 with severe mitral stenosis. Left – Preoperation: There is a loud S_1 on opening snap (OS) and a full length mitral diastolic murmur (DM) with presystolic accentuation (PSM). There is also a systolic murmur (SM) starting with S_1 which terminates in a prominent midsystolic click (SC). Right – Post-mitral valvotomy: A low amplitude systolic murmur is visible which terminates in the systolic click which is now later in timing. A small opening snap is still present. The carotid pulse in both tracings shows a small systolic notch near the summit coincident with the systolic click.

in 2 patients failed to show any significant alteration in the timing of the systolic dip or click.

Cardiac catheter studies

Cardiac catheter studies were performed in 9 patients: 7 from group 1 and 2 from group 2.

Group 1 The left ventricular pressure pulse showed no significant alteration in pulse contour during systole and both left ventricular end-diastolic pressure and mean left atrial pressure were within normal limits. In 3 patients a Telco micromanometer was placed in the left ventricle to record intracardiac sounds and pressures and also the first derivative of pressure (dp/dt). In one patient records were also obtained from the left atrium. One of the patients with Telco micromanometer studies showed a rapid fall of left ventricular systolic pressure starting with the systolic click and associated with an unusual notch on the tracing of the first derivative of pressure (Fig. 8). A similar rapid fall in pressure was also present on the intra-aortic tracing. The systolic click was equally well recorded from within the left ventricle or the left atrium and a site of maximal intensity could not be defined.

Left ventricular cineangiography in the right anterior oblique projection was carried out in 6 of the 7 patients. One patient did not have ventriculography. Five of the 6 patients studied showed pro-

lapse of the posterior mitral leaflet, and all 6 showed mild to moderate mitral regurgitation. One of the patients with posterior leaflet prolapse also showed an unusual contraction of the inferior wall of the left ventricle analogous to that described by Ehlers *et al.* (1970). This appearance was not present on any of the other cineangiograms.

Four of the 5 patients with a prolapsing mitral leaflet had a midsystolic dip on the apex cardiogram. The patient with the largest systolic dip was the patient with the unusual contraction of the inferior wall of the left ventricle.

A further feature of the cineangiograms of the 4 patients with both a prolapsing mitral valve leaflet and a systolic dip on the apex cardiogram was a sudden inward jerk or tug on the anterior wall of the left ventricle associated with the prolapse of the mitral leaflet. The jerk occurred as the prolapsing leaflet approached its maximal excursion.

Group 2 The left ventricular pressure pulse showed no significant alteration in pulse contour during systole. The mean left atrial pressure was above 20 mmHg and there was a persistent diastolic gradient across the mitral valve in both patients studied. The pulmonary arterial pressure was above systemic arterial pressure in 1 patient. Left ventricular cineangiography showed slight thickening and restriction of movement of the mitral valve leaflets in association with mild mitral regurgitation. There

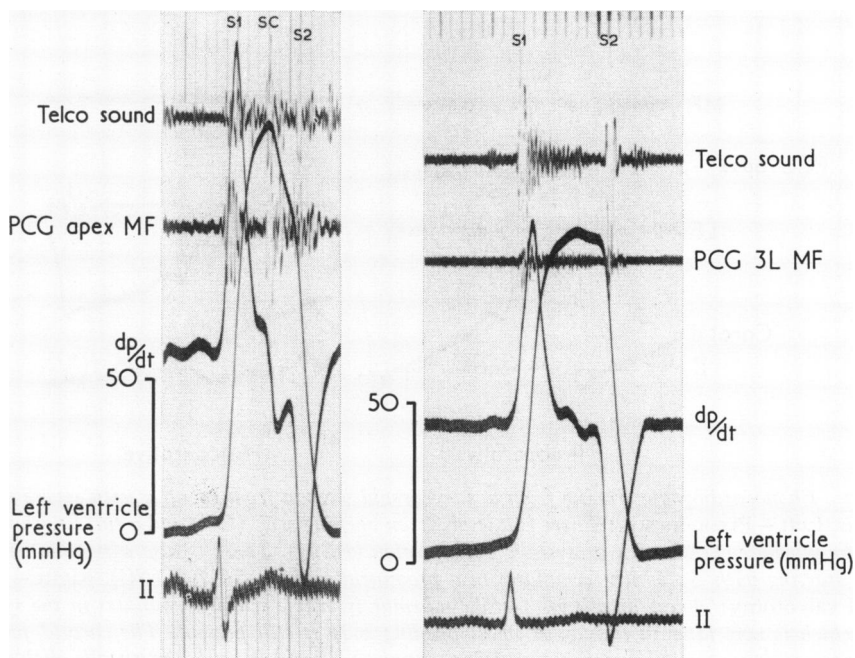


FIG. 8 Left-hand panel: Left ventricular pressure recorded with a Telco micromanometer (same patient as in Fig. 5). The first derivative of pressure (dp/dt), an intracardiac phonocardiogram (Telco sound), and an external phonocardiogram have also been recorded. The left ventricular pressure shows a sharp fall from its peak level coincident with the systolic click. There is an associated deep negative deflection on the dp/dt tracing. Right-hand panel: Left ventricular pressure and its dp/dt recorded with identical calibrations in a patient with a normal heart for comparison. The left ventricular pressure pulse shows a rounded summit without any sharp negative deflection on the dp/dt tracing.

was no leaflet prolapse visible nor was there any abnormality of left ventricular contraction. Moderate mitral valve calcification was present in 1 patient.

Discussion

Numerous studies over the past 10 years have shown that systolic clicks with or without an associated late systolic murmur are frequently due to an abnormality of the mitral valve mechanism. A lone systolic click without an accompanying systolic murmur has been related to mitral leaflet prolapse without angiographically demonstrable mitral regurgitation, and is thought to arise from sudden tensing of the attached chordae tendineae (Leon *et al.*, 1966; Criley *et al.*, 1966; Stannard *et al.*, 1967). When a late systolic murmur is also present, mitral regurgitation can usually be shown by left ventricular cineangiography (Humphries and McKusick, 1962; Barlow *et al.*, 1963; Criley *et al.*, 1966). The defect in the mitral valve apparatus may be due to many

different disorders which affect the valve leaflets, the chordae tendineae, or the papillary muscles. The principal reported causes of the systolic click – late systolic murmur syndrome are given in Table 2.

In several papers attention has been drawn to variations in the timing of the systolic click and changes in the intensity and duration of the systolic murmur with respiration and alterations in posture (Reid, 1961; Leighton *et al.*, 1966; Hancock and Cohn, 1966; Behar, Whalen, and McIntosh, 1967; Stannard *et al.*, 1967; Barlow *et al.*, 1968; Bittar and Sosa, 1968; Fontana *et al.*, 1970). This feature was primarily responsible for the view that systolic clicks and late systolic murmurs were of exocardial origin (Gallavardin, 1913; Lian and DeParis, 1933; Johnston, 1938). In addition, Gallavardin (1913) found pleuropericardial adhesions in 3 patients at necropsy, and the systolic clicks were attributed to this abnormality.

In this study the clicks generally moved earlier in systole towards the first heart sound on sitting

TABLE 2 *Aetiology of systolic click—late systolic murmur syndrome*

Connective tissue disorders	—	Marfan's syndrome Turner's syndrome Myxomatous degeneration ('floppy valve syndrome')
Rheumatic	—	(a) Isolated late sequel (b) Associated with chronic rheumatic mitral valve disease
Congenital heart disease	—	Atrial septal defect (secundum) Ostium primum defect Persistent ductus arteriosus Eisenmenger syndrome
Familial		
Cardiomyopathy	—	Hypertrophic obstructive Congestive Abnormal ventricular contraction
Papillary muscle dysfunction	—	Coronary artery disease Polyarteritis nodosa
Trauma		
Artificial chordae tendinae		

and standing and later in systole towards the second heart sound on squatting or lying. The systolic murmur became correspondingly longer or shorter in association with the movement of the systolic click (Fig. 2). In many patients the systolic click merged with the first heart sound on standing and the systolic murmur became pansystolic. Amyl nitrite inhalation also caused the systolic click and systolic murmur to begin earlier in systole though their intensities usually diminished. The systolic murmur often became pansystolic within 20 to 30 seconds of inhalation with a return to control conditions within 90 seconds (Fig. 3).

Since systolic clicks have been shown to occur at the time of maximal mitral valve leaflet prolapse (Criley *et al.*, 1966), alterations in the timing of the click must be associated with changes in the timing of leaflet prolapse.

The effects of posture on the systolic click and systolic murmur appear to be related to changes in the end-diastolic volume of the left ventricle. In the erect position the end-diastolic volume is smaller due to a decrease in systemic venous return (Tuckman and Shillingford, 1966; Rushmer, 1970). The leaflets are closer to the position where prolapse begins with a smaller end-diastolic volume and therefore leaflet prolapse occurs earlier, and the click and murmur also occur earlier. Squatting has

a reverse effect to standing by increasing venous return and slowing the heart with a consequent increase in left ventricular end-diastolic volume (Sharpey-Schafer, 1956; Nellen, Gotsman, and Schrire, 1968). In the more distended ventricle, the mitral valve apparatus is subjected to a greater amount of tension and the mitral leaflets are further from the position of prolapse. Leaflet prolapse, therefore, occurs much later in systole and the systolic click and systolic murmur occur correspondingly later (Fig. 2).

Amyl nitrite inhalation which causes the systolic click and systolic murmur to move earlier in systole also appears to act by decreasing left ventricular end-diastolic volume (Vogelpoel *et al.*, 1959).

Kesteloot and Van Houte (1965) reported one patient with a systolic click and late systolic murmur which became pansystolic during extrasystoles and shorter after the long diastole of a compensatory pause. They attributed these changes to variations in ventricular diastolic volume. Four of our patients with phonocardiographic studies of ectopic beats all showed an earlier systolic click and a longer systolic murmur with the ectopic beat with a return to control conditions during the postectopic beat (Fig. 9).

Kesteloot and Van Houte (1965) and Barlow *et al.* (1968) found that during the straining phase of the Valsalva manoeuvre the systolic murmur became longer and the systolic click moved earlier in systole, with a rapid return to control conditions after release of the strain. These changes also appeared to be related to decreased ventricular diastolic volume. We did not systematically study the effects of the Valsalva manoeuvre in our patients. However, in one patient with a prolapsing posterior mitral leaflet, left ventricular cineangiography was repeated during the straining phase of the Valsalva manoeuvre. We were not fully convinced that leaflet prolapse was earlier with the smaller diastolic volume though the prolapse may have been greater.

Fontana *et al.* (1970) have pointed out that if a patient only has a systolic click and/or a systolic murmur when sitting or standing, then left ventricular cineangiography when supine may fail to show the mechanism involved. In one study (Bittar and Sosa, 1968) cineangiography was performed on a patient before and after amyl nitrite inhalation. Greater prolapse and more obvious mitral regurgitation were found after amyl nitrite when the systolic murmur was of longer duration.

The apex cardiogram showed the presence of a midsystolic dip or retraction in 31 of the 38 patients in group 1 and in 6 of the 8 patients in group 2 (Table 1). The nadir of the systolic dip coincided with the systolic click in the majority of patients

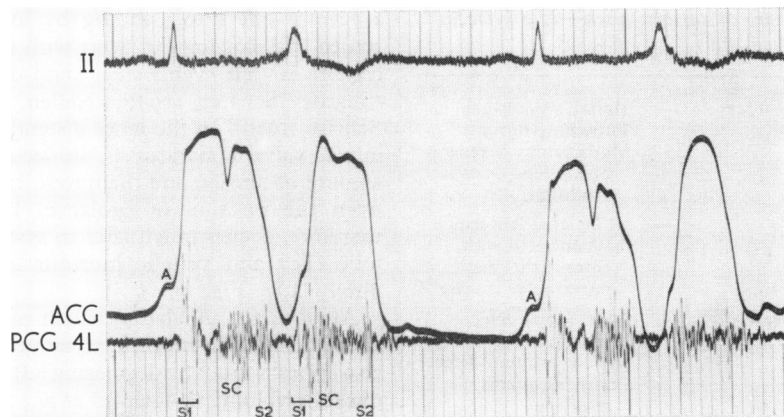


FIG. 9 A group I patient with coupled rhythm and a moderate sized midsystolic dip on the apex cardiogram. During the ectopic beats the late systolic murmur becomes pansystolic and the systolic click moves towards S1. The second complex shows that the systolic dip has also moved earlier in systole with the click. The postectopic beats shows an identical appearance to the normal sequential sinus beats.

(Fig. 4). Similar changes in the apex cardiogram were described in patients with a systolic click and late systolic murmur by Willems *et al.* (1969).

Our studies of the effects of posture and of amyl nitrite inhalation on the apex cardiogram show that the systolic dip and the systolic click move directionally together (Fig. 5 and 6).

Five patients in group I were clearly shown to have prolapsing mitral valve leaflets by left ventricular cineangiography. Four of these 5 patients had a midsystolic dip on the apex cardiogram which was of moderate size in 3 and large in 1 patient. The patient with a very large midsystolic dip showed obvious posterior leaflet prolapse on the left ventricular cineangiogram in association with abnormal contraction of the inferior wall of the left ventricle during ejection similar to that reported by Ehlers *et al.* (1970) and by Gooch *et al.* (1972). This appearance was not present on any of the other left ventricular cineangiograms. The patient without a midsystolic dip had only slight posterior mitral leaflet prolapse with a trace of mitral regurgitation on the cineangiogram.

The other feature of the cineangiograms in the 4 patients with both a prolapsing mitral valve leaflet and a midsystolic dip on the apex cardiogram was an apparent sudden inward jerk or tug on the anterior wall of the left ventricle as the prolapsing leaflet approached its maximal excursion.

The genesis of the midsystolic dip is uncertain. Left ventricular cineangiography appears to show that the prolapsing mitral leaflet is abruptly checked as it reaches its maximal excursion so that the

attached chordae tendineae suddenly become taut and exert momentary traction on the left ventricular wall through their papillary muscle attachments. An alternative explanation is that the left ventricle contracts abnormally though this was shown by cineangiography in only 1 of the 4 patients with both a prolapsing mitral valve leaflet and a midsystolic dip on the apex cardiogram. The left ventricular pressure pulse was also abnormal in this patient, in that there was a rapid early fall in left ventricular pressure from its peak level which coincided with the timing of the systolic click. The first derivative of pressure (dp/dt) also showed an unusual notch coincident with the systolic click (Fig. 8). The other patients had normal left ventricular pressure pulses. However, Gooch *et al.* (1972) found asynergistic left ventricular contraction in many of their patients with the prolapsing mitral leaflet syndrome.

We have recorded a midsystolic dip in patients with isolated systolic clicks or isolated systolic murmurs not included in this series, and Willems *et al.* (1969) reported similar observations in their series of patients. The systolic dip is therefore independent of either the click or the systolic murmur though these features are closely related to one another.

McDonald *et al.* (1971) found a prolapsing mitral leaflet on left ventriculography without an associated systolic click or systolic murmur in 5 of their 11 patients. Apex cardiograms were not recorded by these authors and it has still to be shown that a prolapsing mitral leaflet without auscultatory signs can be associated with a systolic dip on the apex cardiogram. However, our findings suggest that the

systolic dip is produced by the prolapsing mitral leaflet and that the dip may be regarded as evidence of leaflet prolapse. The absence of a systolic dip does not exclude leaflet prolapse since the apex cardiogram depends on adequate coupling between the left ventricle and the chest wall, which may be prevented by anatomical factors.

Clinical examination in group 1 patients sometimes showed the presence of a palpable transient systolic retraction of the apex beat producing a double apical impulse. This was only present in those patients who had a prominent midsystolic dip on the apex cardiogram which was a graphic illustration of the same phenomenon.

Reid (1961) and Barlow *et al.* (1968) have suggested that the systolic click is due to sudden tensing of chordae tendineae. The click has been shown to coincide with the time of maximal leaflet prolapse (Criley *et al.*, 1966) and also with the nadir of the midsystolic dip on the apex cardiogram. These findings support their hypothesis. An alternative explanation is that the systolic click is due to sudden tensing of the everted prolapsing leaflet as it reaches the end of its excursion (Lewis, 1971). This is analogous to the postulated cause of the opening snap in mitral stenosis (McCall and Price, 1967; Wooley *et al.*, 1968).

Group 2 patients showed certain differences from group 1 patients. The systolic clicks showed an inconstant relation to changes of posture and amyl nitrite inhalation, and in no patient was there transient movement of the click into late systole as commonly occurred on squatting in group 1 patients. In 1 patient the systolic murmur ended with a click in midsystole and resembled one of the patients reported by Barlow *et al.* (1968). The click became late systolic in timing in this patient after mitral valvotomy (Fig. 7). Left ventricular cineangiography showed no evidence of mitral valve leaflet prolapse in the 2 patients studied though one of these patients showed a midsystolic dip on the apex cardiogram. All group 2 patients had some thickening and fibrosis of the mitral valve leaflets with shortening of the chordae tendineae. The abnormal mitral valve may be unable to vary its function in the same manner as a mobile mitral valve so that the auscultatory features remain fairly constant.

The systolic notch on the carotid pulse tracing in 4 of the patients coincided with the systolic click (Fig. 7). Its significance is difficult to explain, but it may be related to some transient alteration in left ventricular ejection.

The clinical syndrome of the systolic click and late systolic murmur may be produced by many disorders of the mitral valve apparatus which can affect the mitral leaflets, the chordae tendineae, or the

papillary muscles (Table 2). In many instances the underlying disorder is unknown. Since the condition is usually benign there have been few necropsy studies. A voluminous posterior mitral leaflet was reported at necropsy in a man aged 39 years, with a systolic click and late systolic murmur, by Barlow *et al.* (1968). Trent *et al.* (1970) also reported a voluminous posterior mitral leaflet at necropsy in a woman of 63 years, with a late systolic murmur, but with no systolic click. Left ventricular cineangiography shortly before death had shown a prolapsing mitral leaflet and histological examination revealed myxomatous degeneration of the posterior mitral leaflet. A surgically excised mitral valve from a 44-year-old woman with a systolic click, and late systolic murmur and a prolapsing posterior mitral leaflet was reported by Davis *et al.* (1971). This valve also showed myxomatous degeneration histologically.

The mitral valve leaflets and chordae tendineae from patients with classical Marfan's syndrome usually show severe myxomatous degeneration, and this change is undoubtedly responsible for the leaflet prolapse and the associated systolic click and systolic murmur (McKusick, 1966). Similar changes may occur in Turner's syndrome.

Myxomatous changes were reported in surgically excised mitral valves from 5 patients with severe mitral regurgitation by Read, Thal, and Wendt (1965). They called the condition the 'floppy valve syndrome' and considered it a possible forme fruste of Marfan's syndrome. Similar myxomatous changes were also reported in surgically excised mitral valves from 3 patients with prolapsing mitral leaflets and associated severe mitral regurgitation by Bittar and Sosa (1968). However, none of these patients had systolic clicks associated with the systolic murmur on auscultation.

Pomerance (1969, 1972) found evidence of mucoid or myxomatous degeneration of mitral valve leaflets in a survey of the effects of age on human hearts. When the changes were severe the leaflets often showed ballooning and prolapse into the left atrium, the posterior leaflet being more frequently and severely affected. The chordae tendineae to the prolapsing leaflet were also often involved.

Burch, DePasquale, and Phillips (1968) drew attention to the left ventricular papillary muscle dysfunction secondary to ischaemic heart disease as a cause of apical late systolic murmurs. In several studies of the systolic click – late systolic murmur syndrome an association has been noted between non-ejection clicks with or without late systolic murmurs and ischaemic heart disease (Stannard *et al.*, 1967; Barlow *et al.*, 1968; Willems *et al.*, 1969; Pocock and Barlow, 1971). Two specific studies of

this association have been reported by Cheng (1970) and by Steelman *et al.* (1971). In our series, 9 patients had angina of effort associated with the systolic click-late systolic murmur syndrome, and in 2 of these patients the auscultatory findings appeared after an inferior infarction. Four of the 9 patients showed obvious spontaneous beat-to-beat variations in the timing and intensity of the systolic click and systolic murmur (Fig. 10). Presumably this reflects beat-to-beat alterations in papillary muscle function. Pocock and Barlow (1971) have also commented on the variability of the systolic click and murmur in their patients with ischaemic papillary muscle dysfunction. However, we have noticed similar findings in 2 other patients in our series without any evidence of ischaemic heart disease. This finding cannot, therefore, be regarded as pathognomonic of coronary artery disease, though it may be good evidence of papillary muscle dysfunction of different aetiology.

The presence of effort angina in a patient with a systolic click and late systolic murmur does not prove that the auscultatory findings are secondary to coronary artery disease, since ischaemic heart disease may develop independently of the disorder of the mitral valve. For example, one of our patients, a man aged 60 years, gave a 5-year history of effort angina and had electrocardiographic changes of sub-endocardial infarction. It later transpired that a systolic murmur had been present for more than 30 years. Only 3 of our 9 patients with effort angina were clearly shown to have developed the systolic click and murmur after an acute myocardial infarction.

It may also be difficult to distinguish between coronary artery disease with papillary muscle dysfunction and the 'auscultatory-electrocardiographic syndrome', where a prolapsing posterior mitral valve leaflet is associated with a characteristic posteroinferior ischaemic pattern on the electrocardiogram (Humphries and McKusick, 1962; Barlow and Bosman, 1966; Hancock and Cohn, 1966; Stannard *et al.*, 1967; Ehlers *et al.*, 1970).

In patients with an abnormal left ventricular contraction ring as described by Grossman *et al.* (1968) and by Ehlers *et al.* (1970), papillary muscle dysfunction, due to an inherited anomaly of the left ventricular myocardium, is the probable cause of the disordered mitral valve function. These patients have abnormal electrocardiograms with apparently normal coronary arteries. Only one of our patients studied by left ventricular cineangiography showed this feature and he also had an abnormal electrocardiogram.

Barlow *et al.* (1968) gave some anatomical evidence for the mitral valve origin of late systolic murmurs and clicks. Five of their patients were found to have abnormal chordae tendineae or mitral valve leaflets at operation for a persistent ductus arteriosus or an atrial septal defect, and 3 patients developed systolic clicks after the insertion of artificial nylon chordae for the repair of severe mitral regurgitation due to ruptured chordae tendineae.

In familial cases the basis for the mitral valve prolapse is unknown. A systolic click and a systolic murmur may be present in some members of a kindred with or without associated electrocardio-

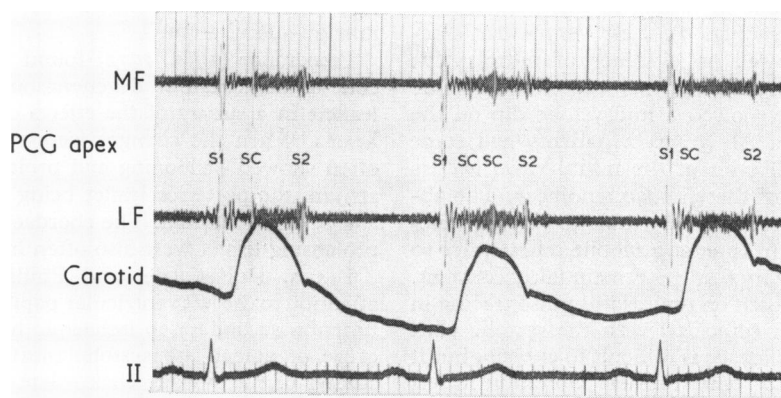


FIG. 10 *Man aged 65 years. A systolic click and systolic murmur developed after an acute posterolateral myocardial infarction. The tracing shows the conspicuous variability in the timing, intensity, and number of systolic clicks and also in the length of the systolic murmur. The systolic click was absent from some complexes (not illustrated).*

graphic changes (Shell *et al.*, 1969; Hunt and Sloman, 1969). The absence of electrocardiographic abnormalities in some patients and the failure as yet to demonstrate an abnormal left ventricular contraction by cineangiography suggest that the inherited anomaly is an abnormality of the mitral valve leaflets.

The prognosis in the systolic click – late systolic murmur syndrome will depend in the first instance upon the underlying cause of the syndrome. Patients with Marfan's syndrome are liable to dissecting aneurysms of the aorta. Those with papillary dysfunction secondary to coronary artery disease are subject to the risks of ischaemic heart disease.

There is a high incidence of supraventricular and ventricular arrhythmias and occasional instances of sudden death have been reported (Hancock and Cohn, 1966; Barlow *et al.*, 1968; Shell *et al.*, 1969). Exercise has been shown to induce or aggravate abnormalities of rhythm by Pocock and Barlow (1970), by Sloman *et al.* (1972), and by Gooch *et al.* (1972). An exercise test may, therefore, help to identify those patients who are liable to electrical instability and thus allow prophylactic treatment to prevent fatal arrhythmias.

Infective endocarditis has been reported by Facquet, Alhomme, and Raharison (1964), Linhart and Taylor (1966), LeBauer, Perloff, and Keliher (1967), Barlow *et al.* (1968), and Willems *et al.* (1969). This may aggravate the haemodynamic disturbance which is usually minimal and produce severe mitral regurgitation. Prophylaxis against infective endocarditis is therefore advisable during dental extractions and other operative procedures.

The systolic click – late systolic murmur syndrome is certainly compatible with longevity. Half our patients were over 40 years of age and 7 were 60 years or more. The oldest patient was aged 72 years. A systolic murmur had been known to be present in 9 patients for at least 10 years and in one of these patients for 42 years. The longest direct follow-up was for a period of 14 years. Only one patient showed progression from mild mitral regurgitation to severe mitral regurgitation during follow-up, and rupture of chordae tendinae is thought to be the cause of this fairly sudden change.

Shell *et al.* (1969) found, in 4 families with the syndrome, that pansystolic murmurs predominated in the older members and that the click and murmur occurred only in the middle generation of each family. These findings suggested a progression of the mitral regurgitation. Long-term follow-up studies of patients with the systolic click – late systolic murmur syndrome are necessary to assess this point.

Part of this work was subsidized by a Research Grant from the United Liverpool Hospitals. We were also in receipt of a Research Grant from the Peel Medical Trust.

We wish to thank our senior cardiographic technicians, Mrs. M. Bird and Mrs. J. Parry, for their skilled help and co-operation in carrying out the phonocardiographic studies. Sister J. Davies in charge of the catheter laboratory and her staff gave invaluable technical assistance in performing the cardiac catheter studies. We also wish to thank Dr. E. Walker for providing radiological assistance.

References

- Barlow, J. B., and Bosman, C. K. (1966). Aneurysmal protrusion of the posterior leaflet of the mitral valve. An auscultatory-electrocardiographic syndrome. *American Heart Journal*, **71**, 166.
- Barlow, J. B., Bosman, C. K., Pocock, W. A., and Marchand, P. (1968). Late systolic murmurs and non-ejection ('mid-late') systolic clicks. An analysis of 90 patients. *British Heart Journal*, **30**, 203.
- Barlow, J. B., Pocock, W. A., Marchand, P., and Denny, M. (1963). The significance of late systolic murmurs. *American Heart Journal*, **66**, 443.
- Behar, V. S., Whalen, R. E., and McIntosh, H. D. (1967). The ballooning mitral valve in patients with the 'precordial honk' or 'whoop'. *American Journal of Cardiology*, **20**, 789.
- Bittar, N., and Sosa, J. A. (1968). The billowing mitral valve leaflet. *Circulation*, **38**, 763.
- Burch, G. E., DePasquale, N. P., and Phillips, J. H. (1968). The syndrome of papillary muscle dysfunction. *American Heart Journal*, **75**, 399.
- Cheng, T. O. (1970). Late systolic murmur in coronary artery disease (abstract). *Circulation*, **42**, Suppl. III, 143.
- Coulshed, N., and Epstein, E. J. (1963). The apex cardiogram: its normal features explained by those found in heart disease. *British Heart Journal*, **25**, 697.
- Criley, J. M., Lewis, K. B., Humphries, J. O., and Ross, R. S. (1966). Prolapse of the mitral valve: clinical and cine-angiographic findings. *British Heart Journal*, **28**, 488.
- Cuffer, and Barbillion (1887). Nouvelles recherches sur le bruit de galop cardiaque. *Archives Générales de Médecine* (7th series), **1**, 129 and 301.
- Davis, R. H., Schuster, B., Knoebel, S. B., and Fisch, C. (1971). Myxomatous degeneration of the mitral valve. *American Journal of Cardiology*, **28**, 449.
- Dillon, J. C., Haine, C. L., Chang, S., and Feigenbaum, H. (1971). Use of echocardiography in patients with prolapsed mitral valve. *Circulation*, **43**, 503.
- Ehlers, K. H., Engle, M. A., Levin, A. R., Grossman, H., and Fleming, R. J. (1970). Left ventricular abnormality with late mitral insufficiency and abnormal electrocardiogram. *American Journal of Cardiology*, **26**, 333.
- Epstein, E. J., Coulshed, N., Brown, A. K., and Doukas, N. G. (1968). The 'A' wave of the apex cardiogram in aortic valve disease and cardiomyopathy. *British Heart Journal*, **30**, 591.
- Evans, W. (1943). Mitral systolic murmurs. *British Medical Journal*, **1**, 8.
- Facquet, J., Alhomme, P., and Raharison, S. (1964). Sur la signification du souffle fréquemment associé au claquement télé-systolique. *Acta Cardiologica*, **19**, 417.
- Fontana, M. E., Pence, H. L., Leighton, R. F., and Wooley, C. F. (1970). The varying clinical spectrum of the systolic click-late systolic murmur syndrome. A postural auscultatory phenomenon. *Circulation*, **41**, 807.

- Gallavardin, L. (1913). Pseudo-dédoublement du deuxième bruit du coeur-simulant le dédoublement mitral par bruit extra-cardiaque télé-systolique surajouté. *Lyon Médical*, **121**, 409.
- Gooch, A. S., Vicencio, F., Maranhao, V., and Goldberg, H. (1972). Arrhythmias and left ventricular asynergy in the prolapsing mitral leaflet syndrome. *American Journal of Cardiology*, **29**, 611.
- Griffith, J. P. C. (1892). Mid-systolic and late-systolic mitral murmurs. *American Journal of the Medical Sciences*, **104**, 285.
- Grossman, H., Fleming, R. J., Engle, M. A., Levin, A. H., and Ehlers, K. H. (1968). Angiocardiography in the apical systolic click syndrome: left ventricular abnormality, mitral insufficiency, and inversion of T waves. *Radiology*, **91**, 898.
- Hall, J. N. (1903). Late systolic mitral murmurs. *American Journal of the Medical Sciences*, **125**, 663.
- Hancock, E. W., and Cohn, K. (1966). The syndrome associated with midsystolic click and late systolic murmur. *American Journal of Medicine*, **41**, 183.
- Humphries, J. O., and McKusick, V. A. (1962). The differentiation of organic and 'innocent' systolic murmurs. *Progress in Cardiovascular Diseases*, **5**, 152.
- Hunt, D., and Sloman, G. (1969). Prolapse of the posterior leaflet of the mitral valve occurring in eleven members of a family. *American Heart Journal*, **78**, 149.
- Johnston, F. D. (1938). Extra sounds occurring in cardiac systole. *American Heart Journal*, **15**, 221.
- Kerber, R. E., Iseff, D. M., and Hancock, E. W. (1971). Echocardiographic patterns in patients with the syndrome of systolic click and late systolic murmur. *New England Journal of Medicine*, **284**, 691.
- Kesteloot, H., and Van Houste, O. (1965). On the origin of the telesystolic murmur preceded by a click. *Acta Cardiologica*, **20**, 197.
- LeBauer, E. J., Perloff, J. K., and Keliher, T. F. (1967). The isolated systolic click with bacterial endocarditis. *American Heart Journal*, **73**, 534.
- Leighton, R. F., Page, W. L., Goodwin, R. S., Molnar, W., Wooley, C. F., and Ryan, J. M. (1966). Mild mitral regurgitation: its characterization by intracardiac phonocardiography and pharmacologic responses. *American Journal of Medicine*, **41**, 168.
- Leon, D. F., Leonard, J. J., Kroetz, F. W., Page, W. L., Shaver, J. A., and Lancaster, J. F. (1966). Late systolic murmurs, clicks, and whoops arising from the mitral valve. *American Heart Journal*, **72**, 325.
- Lewis, H. P. (1971). Midsystolic clicks and coronary heart disease. *Circulation*, **44**, 493.
- Lewis, T. (1918). *The Soldier's Heart and the Effort Syndrome*. Shaw and Sons, London.
- Lian, C., and DeParis, M. (1933). Le claquement méso-systolique pleuropéricardique. *Bulletin et Mémoires de la Société Médicale des Hôpitaux de Paris*, **49**, 496.
- Linhart, J. W., and Taylor, W. J. (1966). The late apical systolic murmur. Clinical, haemodynamic and angiographic observations. *American Journal of Cardiology*, **18**, 164.
- McCall, B. W., and Price, J. L. (1967). Movement of mitral valve cusps in relation to first heart sound and opening snap in patients with mitral stenosis. *British Heart Journal*, **29**, 417.
- McDonald, A., Harris, A., Jefferson, K., Marshall, J., and McDonald, L. (1971). Association of prolapse of posterior cusp of mitral valve and atrial septal defect. *British Heart Journal*, **33**, 383.
- Mackenzie, J. (1925). *Diseases of the Heart*, 4th ed. Oxford University Press, London.
- McKusick, V. A. (1958). *Cardiovascular Sound in Health and Disease*. Williams and Wilkins, Baltimore.
- McKusick, V. A. (1966). *Heritable Disorders of Connective Tissue*, 3rd ed. C. V. Mosby, Saint Louis.
- Nellen, M., Gotsman, M. S., and Schrire, V. (1968). The influence of certain drugs and of prompt squatting on the systolic murmur in hypertrophic obstructive cardiomyopathy. *American Heart Journal*, **76**, 295.
- Pocock, W. A., and Barlow, J. B. (1970). Post exercise arrhythmias in the billowing posterior mitral leaflet syndrome. *American Heart Journal*, **80**, 740.
- Pocock, W. A., and Barlow, J. B. (1971). Etiology and electrocardiographic features of the billowing posterior mitral leaflet syndrome. *American Journal of Medicine*, **51**, 731.
- Pomerance, A. (1969). Ballooning deformity (mucoid degeneration) of atrioventricular valves. *British Heart Journal*, **31**, 343.
- Pomerance, A. (1972). Pathology and valvular heart disease. *British Heart Journal*, **34**, 437.
- Potain, C. (1900). Les bruits de galop. *Semaine des Hôpitaux de Paris*, **20**, 175.
- Read, R. C., Thal, A. P., and Wendt, V. E. (1965). Symptomatic valvular myxomatous transformation (the floppy valve syndrome): a possible forme fruste of the Marfan syndrome. *Circulation*, **32**, 897.
- Reid, J. V. O. (1961). Mid-systolic clicks. *South African Medical Journal*, **35**, 353.
- Roberts, D. V., and Jones, E. S. (1963). A new system for recording the apex-beat. *Lancet*, **1**, 1193.
- Ronan, J. A., Perloff, J. K., and Harvey, W. P. (1965). Systolic clicks and the late systolic murmur. Intracardiac phonocardiographic evidence of their mitral valve origin. *American Heart Journal*, **70**, 319.
- Rushmer, R. F. (1970). *Cardiovascular Dynamics*, 3rd ed. W. B. Saunders, Philadelphia.
- Segal, B. L., and Likoff, W. (1964). Late systolic murmur of mitral regurgitation. *American Heart Journal*, **67**, 757.
- Sharpey-Schafer, E. P. (1956). Effects of squatting on the normal and failing circulation. *British Medical Journal*, **1**, 1072.
- Shell, W. E., Walton, J. A., Clifford, M. E., and Willis, P. W. (1969). The familial occurrence of the syndrome of mid-late systolic click and late systolic murmur. *Circulation*, **39**, 327.
- Sloman, G., Wong, M., and Walker, J. (1972). Arrhythmias on exercise in patients with abnormalities of the posterior leaflet of the mitral valve. *American Heart Journal*, **83**, 312.
- Stannard, M., Sloman, J. G., Hare, W. S. C., and Goble, A. J. (1967). Prolapse of the posterior leaflet of the mitral valve: A clinical, familial, and cineangiographic study. *British Medical Journal*, **3**, 71.
- Steelman, R. B., White, R. S., Hill, J. C., Nagle, J. P., and Cheitlin, M. D. (1971). Midsystolic clicks in arteriosclerotic heart disease. A new facet in the clinical syndrome of papillary muscle dysfunction. *Circulation*, **44**, 503.
- Tavel, M. E., Campbell, R. W., and Zimmer, J. F. (1965). Late systolic murmurs and mitral regurgitation. *American Journal of Cardiology*, **15**, 719.
- Thompson, W. P., and Levine, S. A. (1935). Systolic gallop rhythm. A clinical study. *New England Journal of Medicine*, **213**, 1021.
- Trent, J. K., Adelman, A. G., Wigle, E. D., and Silver, M. D. (1970). Morphology of a prolapsed posterior mitral valve leaflet. *American Heart Journal*, **79**, 539.
- Tuckman, J., and Shillingford, J. (1966). Effect of different degrees of tilt on cardiac output, heart rate, and blood pressure in normal man. *British Heart Journal*, **28**, 32.

- Vogelpoel, L., Nellen, M., Swanepoel, A., and Schrire, V. (1959). The use of amyl nitrite in the diagnosis of systolic murmurs. *Lancet*, **2**, 810.
- Wiedemann, G. (1913). Zür Frage des Mesosystolischen Gallopp Rhythmus. *Zeitschrift für die gesamte experimentelle Medizin*, **2**, 297.
- Willems, J., Roelandt, J., De Geest, H., Kesteloot, H., and Joossens, J. V. (1969). Late systolic murmurs and systolic non-ejection clicks. *Acta Cardiologica*, **24**, 456.
- Wooley, C. F., Klassen, K. P., Leighton, R. F., Goodwin, R. S., and Ryan, J. M. (1968). Left atrial and left ventricular sound and pressure in mitral stenosis. *Circulation*, **38**, 295.

Requests for reprints to Dr. E. J. Epstein, Liverpool Regional Cardiac Centre, Sefton General Hospital, Smithdown Road, Liverpool L15 2HE.