

Perfusion lung scanning in obliterative pulmonary hypertension

A. G. Wilson, C. N. Harris, J. P. Lavender, and C. M. Oakley

From the Departments of Diagnostic Radiology and Medicine (Clinical Cardiology), Royal Postgraduate Medical School of London and Hammersmith Hospital, London

Studies were made on 21 cases of chronic obliterative pulmonary hypertension to see if lung perfusion scanning could be used to separate the cases into thromboembolic and idiopathic groups and perhaps cast further light on the pathogenesis of the latter. The signs, symptoms, and relevant investigations have been reviewed. Nineteen had right heart catheterization and 16 pulmonary angiography.

Using the lung scan pattern the cases have been divided into 3 groups. Eight had grossly abnormal scans with multiple, large, asymmetrical defects and most were thought on clinical and angiographic evidence to be suffering from chronic thromboembolic disease. In 7 considered to fall into the idiopathic category the scan was essentially normal. In the remaining 6 the scan was diffusely abnormal showing small, multiple, ill-defined defects. These findings, together with minor angiographic abnormalities, are thought to be consistent with occlusion of small arteries, and the significance of this is discussed.

A diagnosis of obliterative pulmonary hypertension is made in patients with pulmonary hypertension after the exclusion of intracardiac shunts, left atrial obstruction, and respiratory failure. These patients usually give a history of shortness of breath, exertional syncope, effort angina or fatigue, and while the clinical signs may be unequivocal sometimes the evidence for pulmonary hypertension is doubtful and only established by further investigation. In addition to chest x-ray, electrocardiogram, mitral valve echocardiogram, and respiratory function tests, these patients usually require full cardiac catheterization and pulmonary angiography.

In the majority of cases so diagnosed the obliterative pulmonary hypertension will either be secondary to chronic thromboembolism or be of the so-called idiopathic variety. Differentiation between these two major groups is attempted on the history, age, and sex of the patient and the angiographic appearances of the pulmonary vessels. Patients with idiopathic pulmonary hypertension are most commonly young women (Evans, Short, and Bedford, 1957; Fowler *et al.*, 1966; Blount, 1967). In some, the disorder follows a pregnancy apparently uncomplicated by pulmonary embolism or deep venous thrombosis (Oakley and Goodwin, 1967). In addition, a small number of idiopathic pulmonary hyper-

tensives will have a family history of the disorder (Rogge, Mishkin, and Genovese, 1966; Hood *et al.*, 1968). In contrast, patients with thromboembolic pulmonary hypertension tend to be older, of either sex, and often give a history of peripheral venous thrombosis, pleurisy, haemoptysis, frank pulmonary embolism, or infarction (Oakley and Goodwin, 1967). The electrocardiogram is similar in adult patients with idiopathic and thromboembolic pulmonary hypertension, in each of whom it shows the changes of right ventricular overload and, even though there may be major pulmonary artery occlusions the plain chest radiograph is also usually unhelpful as a means of differentiation. The characteristic disturbance of pulmonary gas exchange (Jones and Goodwin, 1965) is similar in both types of obliterative pulmonary hypertension (Nadel, Gold, and Burgess, 1968).

Pulmonary angiography is the single most important investigation as it enables division of the cases into two groups (Chrispin, Goodwin, and Steiner, 1963). Firstly, there are those with evidence of 'large vessel disease' in whom there is dilatation of the proximal pulmonary arteries and scattered obstructions and/or filling defects in arteries down to a diameter of about 2 mm. Secondly, there are those patients with 'small vessel disease' in whom the proximal pulmonary arteries are dilated, reflecting

the presence of pulmonary hypertension, but in whom the arterial tree shows neither filling defects nor obstruction. Few would doubt that the large vessel disease is caused by pulmonary thromboembolism (Goodwin, Harrison, and Wilcken, 1963; Moser *et al.*, 1965; Fleischner, 1967; Nash *et al.*, 1968). Whereas most would hold that those with small vessel disease are cases of idiopathic pulmonary hypertension, some consider that many, if not all, of the cases in this second group are in fact due to chronic pulmonary microembolism (Blount, 1967; Goodwin *et al.*, 1963; Greenspan and Steiner, 1969). We consider this point further in the discussion.

Lung perfusion scanning using labelled, macroaggregated human albumin provides another method of investigating the pulmonary circulation (Wagner *et al.*, 1964). It is generally considered to be a very safe procedure though three adverse reactions, one followed by a delayed fatality, have been described in patients with a restricted pulmonary vascular bed (Dworkin, Smith, and Bull, 1966; Vincent, Goldberg, and Desilets, 1968; Roberts, 1970). In one of these cases particle size, and in another, albumin dose, were in excess of those now generally employed. The 21 patients reported here and others with obliterative pulmonary hypertension have been scanned, sometimes on several occasions, without any untoward effect. We have reviewed the lung perfusion scan findings in cases with obliterative pulmonary hypertension for two reasons. Firstly, to see if the angiographic distinction between large and small vessel disease could be made on scan evidence alone and, secondly, to see if scanning could detect more than one population in the so-called small vessel disease group which might suggest more than one pathogenesis.

Subjects and methods

In all, 21 cases have been reviewed. These are patients discharged with a diagnosis of obliterative pulmonary hypertension who have been seen since lung scanning came into general use in late 1968. Cases with technically inadequate scans or coincidental diseases, e.g. chronic obstructive airway disease known to affect the perfusion lung scan have been excluded except for one patient (Case 13) who suffered from asthma. She had evidence of large vessel obstruction on pulmonary angiography with corresponding defects on the scan that remained relatively unchanged over eighteen months. These changes are unlike those associated with asthma (Walker and Jackson, 1969) and were thought to be unrelated.

Of the 21 cases, 19 had right heart catheterization. This, among other things, established the presence of pulmonary arterial hypertension, the latter being defined as a mean pulmonary artery pressure of more than 25 mmHg. Two patients (Cases 14 and 19) did not have a right heart catheterization but are included as they had

unequivocal clinical signs and electrocardiographic evidence of pulmonary hypertension (see Tables 3 and 5).

The clinical history, including family history, clinical examination, and electrocardiogram have been reviewed. The chest radiograph has been assessed, taken on the same day, or as close as possible to the date of the lung scan.

All cases have had one or more perfusion lung scans performed immediately after an intravenous injection of 1 mCi of ^{99m}Tc -labelled macroaggregated human albumin of particle size 25 to 75 μ administered in the upright position. Nearly all scans have been performed using a Nuclear Chicago Gamma camera (P.H.O./Gamma II with a P.H.O./Gamma III crystal of 25 cm useful diameter) and a 4000 hole, low energy collimator. Occasionally a diverging collimator of the same resolution but lower sensitivity has been used. Six views have been taken, right and left, anterior and posterior, and both laterals, scanning being discontinued once 2×10^6 counts had accumulated in any one view.

Pulmonary angiography was performed as part of the right heart catheterization in 16 of the 21 patients. Forty to 60 ml 76 per cent Urografin (diatrizoate) was injected into the main pulmonary artery or, as in one case, the right atrium and a PA cut film series exposed usually at a rate of 2 per second for 7 seconds.

Results

The cases have been divided into three groups on the basis of the isotope distribution of the perfusion lung scan.

Group 1: normal distribution

In the absence of quantitative scan data we have not attempted to assess changes in the normal, gravitationally induced, gradient of isotope distribution between upper and lower zones described in pulmonary hypertension (Steiner and Quinn, 1968). Thus, scans showing either a uniform isotope distribution or a symmetrical, gravitationally induced, gradient are considered to be normal. Seven cases fell into this category.

Group 2: multiple, large, asymmetrical defects

The scan pattern in 8 cases was of multiple, large, bilateral defects which were usually clear cut and asymmetrical. In some of this group there was evidence of lobar shrinkage and fissural visualization (Eaton *et al.*, 1969).

Group 3: multiple, small, ill-defined defects

In the remaining 6 cases the scan had multiple, bilateral, small ill-defined defects. The overall appearance of both lung fields was the same.

These groups will be considered separately and in detail, and an illustrative case history given of each.

TABLE 1 *Clinical features, electrocardiographic findings, and pulmonary artery pressures in Group 1*

Case No.	Age	Sex	Duration to date (yr) from 1st symptoms	History of thromboembolism or phlebothrombosis	Signs of pulmonary hypertension at time of scan	Electrocardiogram at time of scan	Mean pulmonary artery pressure (mmHg)
1	44	F	12	Nil	'a' wave, P2 +	Right axis deviation	42 28
2	32	F	6	Nil	'a' wave, S2 wide, P2 +, pulm. ej. click, RV +, early diastolic murmur	RA +, RV +, right axis deviation, digitalis effect	55
3	20	F	8	Nil	S2 wide, P2 +, RV +, pulm. ej. click, S4	RV +, praecordial T inversion, right axis deviation	80
4	11	F	4	Nil	'a' wave, P2 +, RV +, pulm. ej. click, S3	RV +, praecordial T inversion, right axis deviation	58
5	7	F	1	Nil	S2 wide, P2 +, RV +	RA +, RV +, right axis deviation	40
6	37	F	11	Nil	'a' wave, S2 wide, P2 +, RV +, tricuspid incomp.	RA +, RV +, praecordial T inversion, right axis deviation	65
7	45	F	1.5	Nil (venogram - ve)	'a' wave, S2 +, P2 +, RV +, pulm. ej. click	RA +, RV +, right axis deviation	67

TABLE 2 *Radiological and scan findings in Group 1*

Case No.	Initial scan	Repeat lung scan(s)	Chest radiograph	Pulmonary angiogram
1	Normal	—	PA +	—
2	Normal	15 and 18 mth later, no change	Heart +, PA +	—
3	Normal	1 mth later, no change	PA +	Large proximal vessels
4	Normal apart from single small defect	10 mth later, normal apart from another small defect	PA +	Large proximal vessels
5	Normal apart from defect against mediastinum, ? PA	—	Heart +, PA +	'Large proximal vessels uniform reduction in peripheral branches; no filling defects or occlusions'
6	Normal	—	Heart +, PA +	—
7	Normal apart from small band-like defect in right upper lobe	—	Heart slightly +, PA +	Moderately large proximal vessels

Group 1

Of the 21 cases, 7 fell into this category. Clinical details of investigations within the group are given in Tables 1 and 2. All were young to middle-aged women with a mean age of 28 years (range 7 to 45). The mean age at the onset of symptoms (shortness of breath in the 5 adults and exertional syncope in the 2 children) was 22 years (range 6 to 43). None gave either a family history suggestive of pulmonary hypertension or a past medical history suggestive of thromboembolism. It is interesting to note in view of the possible relation recorded by some workers between pregnancy and idiopathic pulmonary hypertension that symptoms in three of the older patients began 6, 8, and 10 months after an uneventful pregnancy

and delivery. The clinical signs and electrocardiograms relate to the time the scan was done and indicate moderate to severe pulmonary hypertension in all save one case (Case 1). In 3 cases the mean pulmonary artery pressure reading antedates the scan; in Case 1 by 12 and 11 years, in Case 6 by 3, and in Case 2 by 2 years. The mean pulmonary artery pressure of the group as a whole was 57 mmHg.

Qualitative assessment of the scan in the 7 cases suggested abolition of the normal gravitational gradient in 4 and preservation in 3. The scan of Case 5 had a small semilunar defect of perfusion against the mediastinum, thought to represent a large left pulmonary artery. The scans of Cases 4 and 7 were considered to be normal apart from a

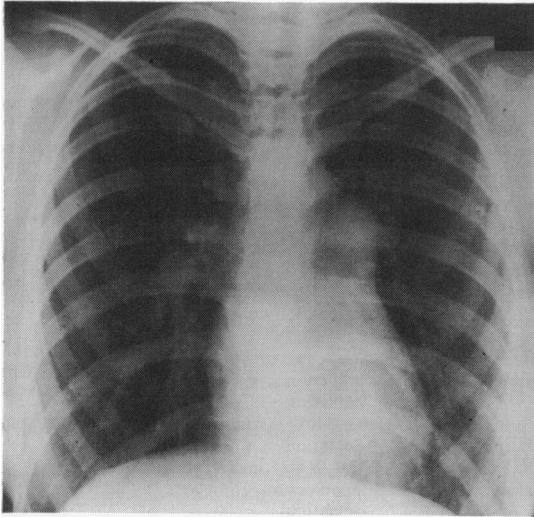


FIG. 1 Chest radiograph of Case 3 (Group 1) aged 20, showing enlargement of the main pulmonary artery, normal heart shadow, and peripheral vessels.

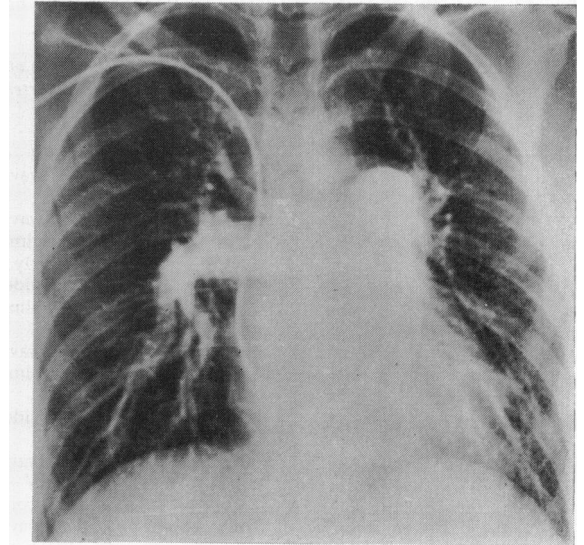


FIG. 3 Pulmonary angiogram of Case 3 (Group 1) aged 20, showing large proximal arteries but no filling defects or occlusions.




FIG. 2 Perfusion lung scan of Case 3 (Group 1) aged 20, posterior views of both lung fields showing normal distribution of isotope.

single small defect in each. On a repeat 10 months later the defect noted in Case 4 was no longer apparent though another small defect was noted at this time. Repeat scans in two other cases (Cases 2 and 3) showed no change.

Of the 7 cases, 4 had pulmonary angiograms, one of which we were unable to assess personally. All showed enlargement of the proximal pulmonary arteries without evidence of cut-off or filling defects. The angiogram we were unable to assess showed in addition 'a uniform reduction in the peripheral branches'.

Case history Case 3 is a 20-year-old housewife who was admitted in 1970. She had recurrent respiratory infections as a child and began to notice exertional dyspnoea in her early teens which prevented her from playing games at school. At the age of 13 a chest radiograph showed a large main pulmonary artery. In 1968 and 1969 she had had 2 miscarriages and had taken contraceptive pills for two months in early 1969. She did not give a history suggestive of thromboembolism and had had no effort angina or exertional syncope. Before admission exertional dyspnoea had progressed conspicuously. There was no family history of pulmonary hypertension.

On examination the heart was in sinus rhythm, rate 72 and the blood pressure was 120/80 mmHg. The jugular venous pressure was raised by 3 cm with a prominent 'a' wave. On palpation there was moderate right ventricular hypertrophy and a pulmonary artery impulse. On auscultation the pulmonary second sound was very loud, and a pulmonary ejection click and soft fourth

TABLE 3 Clinical features, electrocardiographic findings, and mean pulmonary artery pressures in Group 2

Case No.	Age	Sex	Duration to date (yr) from 1st symptom	History of thromboembolism or phlebotrombosis	Signs of pulmonary hypertension at time of scan	Electrocardiogram at time of scan	Mean pulmonary artery pressure (mmHg)
8	42	F	15	Episode of cavitating pneumonia; ? infarcts 15 years ago	P2 +	Praecordial T inversion	47 42
9	26	M	7	Haemoptyses DVT × 3	JVP raised, S2 fixed, RV +, S3, tricuspid incomp., peripheral oedema	RBBB, repolarization changes, ? digitalis effect	48
10	37	F	1	Haemoptyses	P2 +, pulm. ej. click, bruit right lower zone	Right axis deviation	32
11	67	M	3 (dead)	Haemoptyses, pleuritic pain, DVT (venogram +ve)	'a' wave, P2 +, RV +, S3, S4	RV +, praecordial T inversion, right axis deviation	53 50
12	45	M	1	Pleuritic pain, DVT (venogram +ve)	P2 +, S2 wide	Praecordial T inversion	27
13	31	F	2	Haemoptyses, pleuritic pain, leg pain	P2 +	Praecordial T inversion, right axis deviation	39 32
14	72	F	1 (dead)	Nil	JVP raised, P2 +, S2 wide, pulm. ej. click, RV +, tricuspid incomp.	RA +, RV +, right axis deviation	—
15	58	M	3.5	Nil (venogram -ve)	'a' wave, JVP raised, P2 +, S2 wide, RV +, S4	RA +, RV +, right axis deviation, repolarization changes, ? digitalis effect	72

DVT = Deep venous thrombosis.

sound were audible. The electrocardiogram showed obvious right ventricular hypertrophy with right axis deviation and T wave inversion over the praecordium. Taking growth into account the chest x-ray had not changed significantly since 1963 and showed only dilatation of the main pulmonary artery (Fig. 1). Mitral valve echocardiogram was normal and the perfusion lung scan showed uniform isotope distribution (Fig. 2).

A right heart catheterization revealed a right ventricular pressure of 112/0-8 mmHg, with a pulmonary artery pressure of 107/68 mmHg (mean 80 mmHg). Pulmonary angiography showed large proximal pulmonary arteries without evidence of filling defects or occlusions (Fig. 3).

This patient was considered to be suffering from idiopathic pulmonary hypertension and since mid 1970 has been anticoagulated. To date she remains in *status quo*.

Group 2

Of 21 cases, 8 were included in this group (Tables 3 and 4): 4 were women and 4 men, with a mean age of 47 (range 26 to 72). The mean age at the time of presentation was 43 (range 19 to 71). Out of 8, 5 gave a history strongly suggestive of pulmonary embolism or infarction or of deep venous thrombosis in the legs (Table 3). Bilateral leg venography confirmed the presence of deep vein thrombosis in 2 of the 3 cases in which it was performed, affecting the femoral vein in both and the iliac in one. The

sixth patient (Case 8) presented with an episode of cavitating pneumonia which in retrospect could well have been due to multiple pulmonary infarcts. The remaining 2 cases (14 and 15) gave no history to suggest either thromboembolism or deep vein thrombosis. It is interesting to note that the initial complaint in 7 of the 8 was exertional dyspnoea. The eighth (Case 10) complained of haemoptysis. Of the 4 women, 2 presented during pregnancy (one with haemoptysis, and the other with exertional dyspnoea) and 3 of the 4 had a history of a previous pregnancy 2, 3½, and 4 years before presentation.

All had signs and electrocardiographic evidence of mild to severe pulmonary hypertension with confirmatory catheter findings in 7 of the 8 cases. In general there was good agreement between the severity of the pulmonary hypertension as assessed clinically and the pulmonary artery pressure measured at catheterization (Table 3). The one case not catheterized (Case 14) had unequivocal signs and electrocardiographic evidence of severe pulmonary hypertension. In 2 cases the cardiac catheter antedates the clinical findings and scan by 8 and 4 years (Case 8) and 6 years (Case 9), while in the other 5 all investigations were carried out during the same admission. Case 11 and Case 13 both had two

TABLE 4 Radiological and scan findings in Group 2

Case No.	Initial lung scan	Repeat lung scan	Chest radiograph	Pulmonary angiogram
8	No uptake both lower zones; large defects in left upper zone	—	PA +, large vessels right upper zone, scanty elsewhere	Large proximal vessels and major vessel occlusions; perfusion upper zones only right upper > left upper zone
9	No uptake right middle lobe; segmental defects right upper lobe, apical right lower, left upper ($\times 2$), and left lower lobes	—	PA +, heart +	'MPA and main branches dilated; poor filling of peripheral branches both lower and left upper zones'
10	No uptake right middle lobe, lobar shrinkage right upper lobe, large confluent segmental defects left lower lobe, segmental defects left upper lobe	6 and 10 mth later, no change	PA +	Large vessel occlusions; good correlation with scan
11	No uptake right middle lobe, large defects inferiorly both lower lobes and apex left lower lobe, fissural visualization both sides	1 mth later, no change	PA +, heart +, scarring right middle zone and resolving shadow ? infarct	Large proximal vessels; large vessel occlusions; no change in 6 wk
12	Several segmental defects on right; fissural visualization and several peripheral defects on left	3 wk later, no change, 17 mth later, ? slight improvement	PA +, scanty vessels left upper zone	Large proximal vessels; intraluminal defect right upper lobe artery; reduced filling left mid zone
13	Right middle lobe shrunken with defects in right upper and right lower lobes, left lower lobe shrinkage, fissural visualization both sides	2 wk later, no change; 18 mth later improved	PA +	Large proximal vessels; major vessel occlusions correlating well with scan; no change in 7 wk
14	Single segmental defects in right upper, right middle, right lower, left upper lobes ($\times 2$), and left lower lobe, fissural visualization	—	Heart +, rt diaphragm raised	—
15	Single segmental defects in right middle lobe, apical segment right lower lobe, both upper lobes and left lower lobe	—	Heart +, PA +	Large proximal vessels and LA and RV cavity; no major vessel occlusions

catheterizations separated by 1 and 18 months, respectively.

All had grossly abnormal perfusion lung scans that showed multiple, large, bilateral, well-defined defects of perfusion (Table 4). Lobar and segmental defects were commonly seen together with peripheral scalloping. Four cases (Cases 11, 12, 13, and 14) showed in addition fissural visualization and lobar shrinkage. Four patients had one or more repeat scans at intervals varying from 2 weeks to 18 months. Only one patient (Case 13) showed any improvement in the scan appearances and this was slight after 18 months. Of 8 patients, 7 had pulmonary angiograms, 6 of which we have assessed ourselves. In 4 there were major vessel occlusions, the areas remaining perfused showing good correspondence with the scan. Of the remaining 3, Case 12 had no evidence of a major occlusion, but there was

a filling defect in a lobar artery, Case 15 showed no filling defects or occlusions, and we were unable to see the angiogram of Case 9, an abstracted report of which is included in Table 4.

Case history Case 10 is a 37-year-old woman from Hong Kong who has been in this country 4 years. Having had 2 previous pregnancies (a normal delivery aged 32 and a 12-week abortion sometime later) she presented at the age of 36 with haemoptysis when 24 weeks' pregnant. There was no shortness of breath and no symptoms to suggest venous thrombosis.

On examination the only abnormal physical signs were those of a loud pulmonary second sound, soft ejection systolic murmur and ejection click maximal at the base as well as a bruit over the right lower zone of the chest posteriorly. The chest radiograph (Fig. 4) was normal apart from an enlarged main pulmonary artery which had been noted on a mass miniature chest radiograph

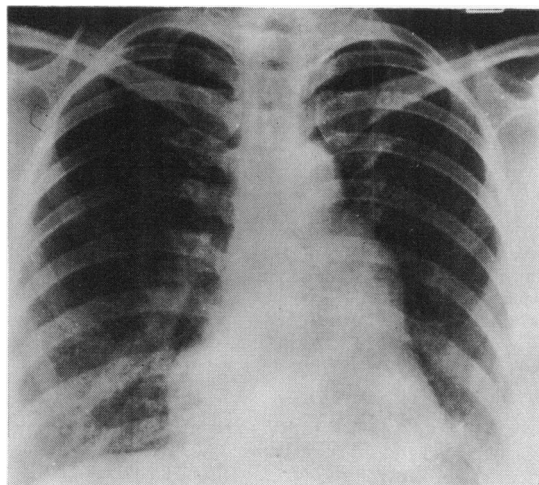


FIG. 4 Chest radiograph of Case 10 (Group 2) aged 37, showing enlargement of the main pulmonary artery, normal heart shadow, and peripheral vessels.

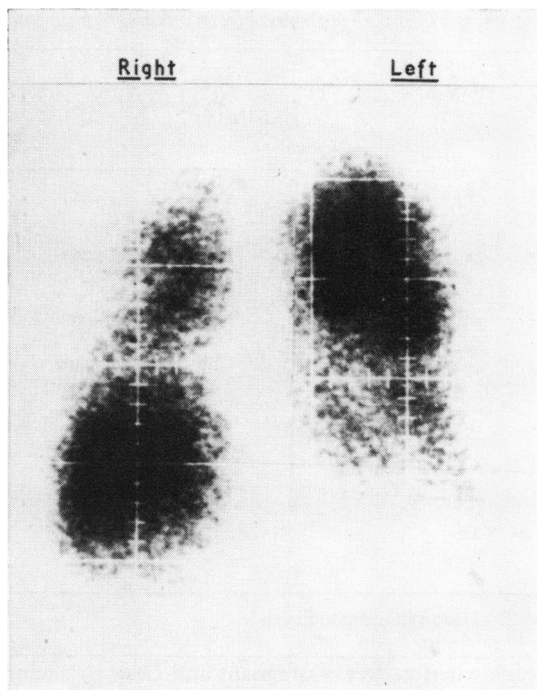


FIG. 6 Perfusion lung scan of Case 10 (Group 2) aged 37, posterior view of both lung fields, showing absent perfusion in left lower zone, reduction in both mid zones, and lobar shrinkage of the right upper lobe.

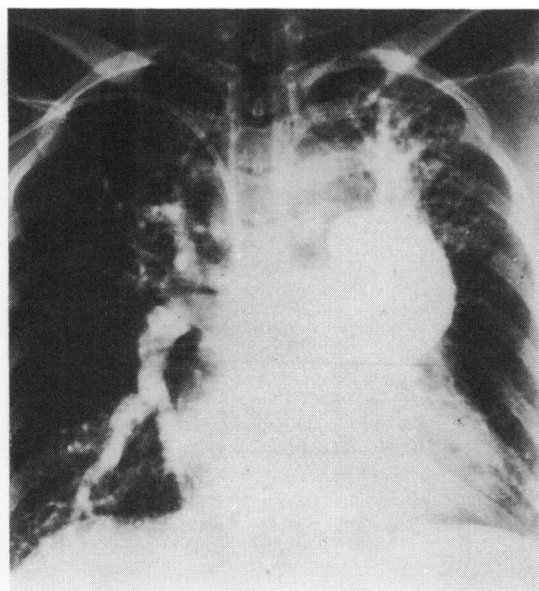


FIG. 5 Pulmonary angiogram of Case 10 (Group 2) aged 37, showing large proximal arteries and extensive major vessel occlusions, especially to the left mid and lower zones and right mid zone.

5 years before. The electrocardiogram showed right axis deviation. Cardiac catheterization was postponed 6 months until after delivery at which time the pulmonary artery pressure was 47/23 mmHg (mean 32). The pulmonary angiogram (Fig. 5) disclosed multiple large vessel occlusions; the unperfused areas correlated well with the scan which showed no uptake in the middle lobe, large confluent defects in the left lower lobe, and lobar shrinkage of the right upper lobe (Fig. 6). She has only been followed for just under a year, and during this time there has been no change in the physical findings, electrocardiogram, chest x-ray, or perfusion scan.

The presumed diagnosis is of pulmonary hypertension secondary to chronic thromboembolic disease. The abnormal chest x-ray 5 years ago suggests the process is long standing.

Group 3

Of 21 patients, 6 fell into this group. There were 2 men and 4 women with a mean age of 31 (range 16 to 49) intermediate between that of Group 1 and 2. The mean age of onset was 28 (range 15 to 37). Only 2 gave a history that suggested thromboembolism, Case 17 having presented with haemo-

TABLE 5 Clinical features, electrocardiographic findings, and mean pulmonary artery pressures in Group 3

Case No.	Age	Sex	Duration to date (yr) from first symptom	History of thromboembolism or phlebothrombosis	Signs of pulmonary hypertension at time of scan	Electrocardiogram at time of scan	Mean pulmonary artery pressure (mmHg)
16	28	M	1.5	Nil	P2+, RV+, S4	RV+, praecordial T inversion, right axis deviation	107
17	28	F	1 (dead)	Haemoptyses, venogram - ve	'a' wave, P2+, RV+ pulm. ej. click, early diastolic murmur	RA+, RV+, right axis deviation	85
18	30	M	0.5	Nil, venogram - ve	'a' wave, P2+, RV+	RA+, RV+, praecordial T inversion	73
19	49	F	17	Chest pain 20 years ago; DVT 19 years ago	S2 wide, P2+	RV+	—
20	39	F	2 (dead)	Nil	'a' wave, S2 fixed, P2+, RV+, S3 and S4	RA+, RV+, right axis deviation	58
21	16	F	1	Haemoptyses, chest infection, and anticoagulated at time	'a' wave, S2 wide, P2+, RV+, pulm. ej. click, early diastolic murmur	RV+, right axis deviation	70

DVT = Deep venous thrombosis.

ptysis when 24 weeks pregnant and Case 19 having had chest pain with her fourth and a deep venous thrombosis with her fifth pregnancy. A third patient (Case 21) had also had haemoptysis but this was during an episode of purulent bronchitis at which

time she was also anticoagulated. This same patient was the only one in the whole series with a positive family history, her father having died at the age of 36 with primary pulmonary hypertension.

All patients had signs and electrocardiographic

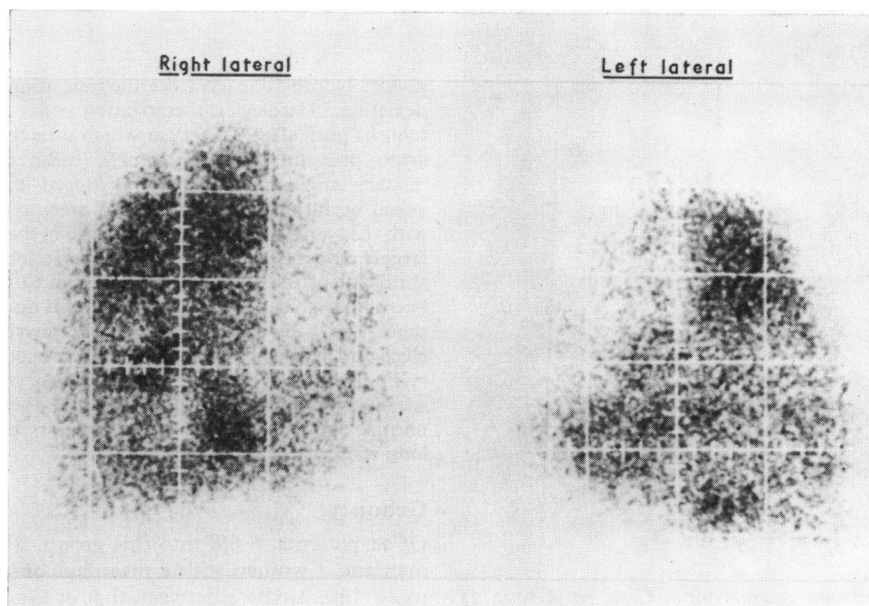


FIG. 7 Perfusion lung scan of Case 19 (Group 3) aged 49; right and left lateral views showing many small, bilateral, rounded defects.

TABLE 6 Radiological and scan findings in Group 3

Case No.	Initial lung scan	Repeat lung scan	Chest radiograph	Pulmonary angiogram
16	Many small, bilateral, ill-defined defects; much peripheral scalloping	—	Heart +, PA +	Large proximal arteries; ? patchy capillary blush; irregular distribution of small peripheral vessels; no major occlusions
17	Many small, bilateral defects both linear and rounded, best seen in lateral views	—	Heart +, PA +	Large proximal arteries, patchy capillary blush especially on contrast overfilled left side
18	Many small, bilateral, ill-defined defects; much peripheral scalloping	4th mth later, no change	PA +	Large proximal arteries small peripheral vessels with patchy capillary blush; no major occlusions
19	Many small and bilateral rounded defects best seen in lateral views	—	PA +	—
20	Poor quality scan; both laterals and left anterior views have multiple ill-defined defects, largely linear	—	PA +	Large proximal vessels; small peripheral vessels; no major occlusions
21	Many small to medium-sized ill-defined defects, both linear and rounded, peripheral scalloping	—	PA +	Large proximal arteries; no major occlusions; ? patchy capillary blush

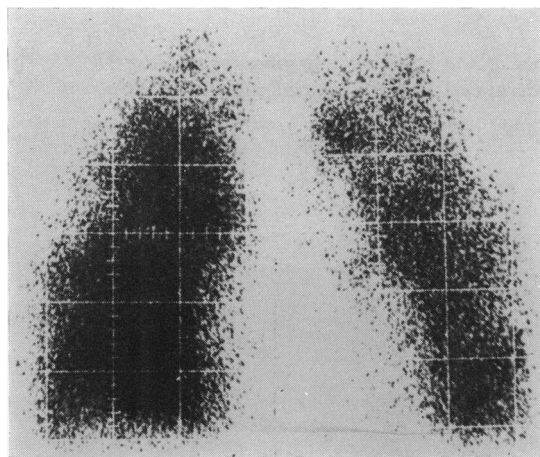


FIG. 8 Perfusion lung scan of Case 16 (Group 3) aged 28, posterior view of both lung fields showing many small, ill-defined defects, and much peripheral scalloping. The difference in overall density of the two sides is artefactual.

evidence of moderate to severe pulmonary hypertension confirmed in 5 of the 6 by a right heart catheter during the same admission. The mean pulmonary artery pressure of these 5 cases was 79 mmHg. Cardiac catheterization was attempted in Case 19 but had to be abandoned because of the development of an arrhythmia.

All had abnormal perfusion scans but one (Case

20) was technically of poor quality. The scans showed small, ill-defined, multiple, bilateral defects (Fig. 7 and 8) with pronounced peripheral scalloping in two (Cases 16 and 18). The defects were mostly rounded though a few had a linear shape. On none of the scans were there lobar or segmental defects as in Group 2 and also no evidence of fissural visualization or lobar shrinkage. Only one scan has been repeated (Case 18) and this showed no change after an interval of 4 months.

Of the 6 patients, 5 had a pulmonary angiogram performed. This showed dilatation of the proximal pulmonary vessels in every case but failed to disclose any intraluminal filling defect or major vessel occlusion. In 2 patients (Cases 17 and 18) and possibly in 2 others (Cases 16 and 21) the capillary blush between arterial and venous phases was patchy and contained filling defects in the order of 1 to 2 cm in diameter (Fig. 9). One of these (Case 16) in addition showed an irregular distribution of small vessels at the periphery consistent with the occlusion of vessels of a diameter in the order of 1 to 2 mm.

Case history Case 16 is a 28-year-old man who presented in 1970 with an 18-month history of increasing shortness of breath. He claimed to have been more short of breath on exertion than his peers since childhood. He had recently had several attacks of light-headedness on exertion but no effort angina. He gave no history to suggest thromboembolism and there was no family history of cardiac disease.

Physical examination revealed mild central cyanosis and signs of pulmonary hypertension. The jugular

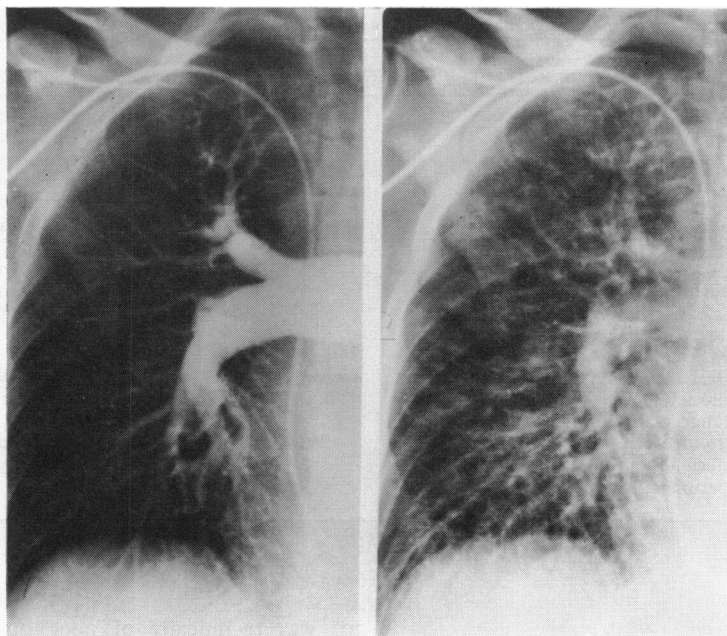


FIG. 9 Arterial (left) and capillary (right) phases of the pulmonary angiogram in Case 18 (Group 3) aged 30, showing essentially normal peripheral vessels in the arterial phase but multiple lucencies in the capillary blush.

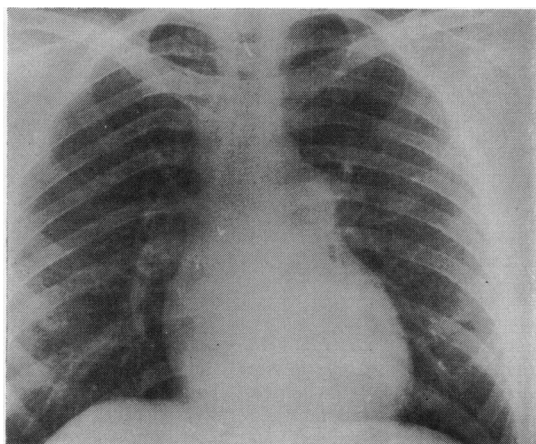


FIG. 10 Chest radiograph of Case 16 (Group 3) aged 28, showing a slightly enlarged heart and enlargement of the proximal pulmonary vessels.

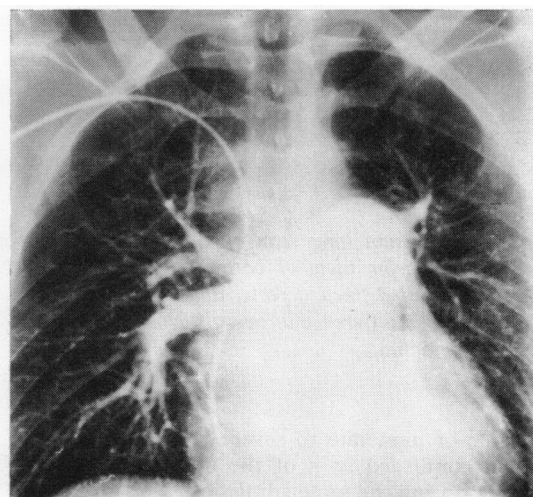


FIG. 11 Pulmonary angiogram in Case 16 (Group 3) aged 28, showing large proximal arteries and irregular distribution of small peripheral vessels, but no major occlusions.

venous pressure was raised 3 cm and there was right ventricular hypertrophy on palpation. On auscultation the pulmonary second sound was loud but closely split, there was a right-sided fourth heart sound and a soft ejection systolic murmur at the left sternal edge.

The electrocardiogram showed right axis deviation, right ventricular hypertrophy, and praecordial T wave inversion. A chest x-ray disclosed a mildly enlarged heart shadow, large proximal pulmonary vessels but an otherwise normal pulmonary vasculature (Fig. 10). The patient had a right heart catheterization at which time the pulmonary artery pressure was 144/80 (mean 107 mmHg) and the pulmonary wedge pressure 10 mmHg. At the same time a dye curve showed a small right-to-left shunt through a patent foramen ovale which was thought to account for the central cyanosis on physical examination and the raised haemoglobin (17.9 g/100 ml) and PCV (53%). A pulmonary angiogram showed dilated proximal pulmonary arteries without any evidence of major vessel occlusion or filling defects (Fig. 11). In addition, however, there was an irregular distribution of the small vessels in the periphery of the lung and a patchiness of the capillary blush due to defects with diameters in the order of 1 to 2 cm. A perfusion lung scan revealed many small ill-defined perfusion defects on both sides with a scalloped outline to the silhouette (Fig. 8).

Discussion

On the basis of the perfusion lung scan pattern we have divided the 21 cases studied into three groups; those with normal or near normal scans (Group 1), those with major defects of perfusion (Group 2), and finally a group with multiple small, ill-defined perfusion defects (Group 3). The justification for such a tripartite division is that the scan patterns from case to case did not show a continuum of change from normal to grossly abnormal but seemed to us to fall naturally into one of 3 groups within each of which the abnormalities were largely consistent in type, though varying in degree.

Patients who showed a normal or near normal distribution of isotope (Group 1) are, we think, examples of idiopathic pulmonary hypertensives, i.e. they have isolated pulmonary hypertension with an occlusive vascular pathology secondary to an unknown and obscure disease process (Blount, 1967). In line with the experience of others (Evans *et al.*, 1957; Blount, 1967; Shepherd *et al.*, 1957; Farrar, 1963) all our patients were women and tended to be young (mean age 28). Their mean age at the time of onset of symptoms was 22. None, however, has a family history of pulmonary hypertension. Such a family history has been described in an increasing number of cases over the past decade (Rogge *et al.*, 1966; Hood *et al.*, 1968). In addition, none gave a history suggestive of either peripheral venous thrombosis or of pulmonary embolism or infarction.

Pulmonary angiography was performed in 4 of the 7 cases and findings were similar to those of others in idiopathic pulmonary hypertension (Oakley and Goodwin, 1967; Rogge *et al.*, 1966; Tsagaris and Tikoff, 1968). In all it documented the dilatation of the proximal pulmonary arteries but failed to show any intraluminal filling defects or obstructions affecting arteries more than 1 to 2 mm in diameter, beyond which size vessels cannot be resolved. We have not attempted to assess subjective signs such as the degree of tortuosity of peripheral arteries or the diffuse reduction in the number of small vessels that some workers have reported. The essentially normal perfusion lung scan findings are similar to those in a limited number of published cases. Goff and Gaensler (1965) and Rogge *et al.* (1966) both report one case each and Haegelin and Murray (1968) two cases with normal lung scans, pulmonary angiograms of the 'small vessel disease' type (Chrispin *et al.*, 1963), and biopsy or necropsy evidence consistent with idiopathic pulmonary hypertension. The scan abnormalities noted in 2 cases (Cases 4 and 7) were minor and are like the defects reported in up to 15 per cent of an asymptomatic, clinically fit series (Tetalman *et al.*, 1971).

In contrast to this group are the 8 patients who showed, large, segmental, or lobar defects on the scan. These large, multiple, bilateral, and asymmetrical perfusion defects shown by scanning corresponded in most with areas supplied by blocked major arteries. There seems little doubt that the majority of these patients had suffered from pulmonary embolism which had possibly been repetitive over a period of time rather than subsequent to a single major episode. This group consisted equally of both sexes (4 women and 4 men) with a mean age of 47, 19 years more than the idiopathic group. The age at the onset of the initial symptoms was also much in excess of the idiopathic group, being 43 as opposed to 22. Of the 8 cases, 6 had a history suggestive of deep venous thrombosis and/or pulmonary embolism or infarction, and in 2 of the 3 patients who had lower limb venography, there was evidence of extensive femoral and iliac vein thrombosis. Seven of the patients had pulmonary angiograms performed. In 4 there were major vessel occlusions and in a fifth (Case 12) there was evidence of intraluminal defects without major vessel occlusion. These changes are well documented in acute pulmonary embolism (Dalen *et al.*, 1966; Stein *et al.*, 1967) and, in a smaller published series, in chronic thromboembolism (Nash *et al.*, 1968; Moser *et al.*, 1966). The scans in all 8 cases showed segmental, lobar, and crescentic defects, found in, but not specific to, pulmonary embolism (Wagner *et al.*, 1964; Poulouse, Reba, and Wagner, 1968). In 2

(Cases 9 and 15) scan and angiogram did not correlate. We were unable to see and assess the angiogram of Case 9, but according to the report there was no evidence of filling defects or occlusions. As regards Case 15 who also on angiogram showed no evidence of 'large vessel disease' it is perhaps significant that out of the whole group his scan showed the least abnormality.

Histological data are not available in any of the above cases as the 2 who died did not have necropsies and lung biopsies were not performed in the others. In any case the histology of pulmonary vessels, especially the smaller ones that would be obtained at biopsy, is often unhelpful in distinguishing between idiopathic and thromboembolic pulmonary hypertension (Fowler *et al.*, 1966; Wagenvoort, Heath, and Edwards, 1964). In both conditions, and for that matter in pulmonary hypertension secondary to congenital heart disease, findings consist of atherosclerosis, medial hypertrophy and necrosis, intimal fibrosis, and thrombus formation, together with plexiform and dilated thin-walled muscular arteries. It still seems to be a matter for speculation as to whether the intimal thickening represents old organized emboli or not. A similar uncertainty surrounds the pathogenesis of the 'thrombi' found in small muscular arteries and arterioles. While some are related to necrotic medial areas, others are clearly not and may represent emboli rather than thrombosis *in situ*. In view of the uncertain pathogenesis of these histological findings, it is not surprising that some workers (Blount, 1967; Goodwin *et al.*, 1963; Rosenberg, 1964) consider that many, if not all, cases of idiopathic pulmonary hypertension are embolic in origin. The evidence for this is not conclusive and it is difficult to see how embolism could hit all parts of the lung and yet never be accompanied by a clinical episode. In addition, some cases seem to be truly congenital in origin as persistence of the infantile structure of the elastic pulmonary arteries has been demonstrated (Rao, Moller, and Edwards, 1969) and it would be difficult to implicate thromboembolism in this instance.

Recently a group of workers from Boston have described two patterns of isotope distribution on perfusion scanning which they call fissural visualization and lobar shrinkage (Eaton *et al.*, 1969). They believe on clinical, pathological, and experimental evidence (Eaton *et al.*, 1969; James *et al.*, 1969) that this is caused by pulmonary microembolism though it has since been pointed out that other conditions can give rise to these appearances (Chandler, 1971; Gize, Dizon, and Mishkin, 1971). We, however, found no evidence of this perfusion pattern in Group 1, as might have been expected

had the cases resulted from multiple small emboli. We did, however, find fissural visualization in 4 out of 8 cases in Group 2 accompanied by segmental and lobar defects. This combination has already been described in acute pulmonary embolism and several possible explanations have been proposed (James *et al.*, 1970).

The third group of patients are those in whom the perfusion lung scan showed multiple, small, ill-defined defects. These cases showed features of both Groups 1 and 2. Two were men and 4 were women, with a mean age of 31 intermediate between Groups 1 and 2, as was the mean age (28) at the onset of symptoms. Of 6 patients, 2 gave a history that was consistent with thromboembolism, though, admittedly in one this consisted only of haemoptyses, a finding described in cases that have been considered to be idiopathic (Fowler *et al.*, 1966; Tsagaris and Tikoff, 1968). In a third case (Case 21) haemoptysis was also present but associated with a purulent bronchitis while on anticoagulants. The perfusion scan findings in all the cases and the angiographic features in 4 out of 5 are consistent with multiple perfusion defects secondary to the occlusion of medium sized arteries in the order of 1 to 2 mm in diameter. We can only speculate on the aetiology and pathogenesis in this group. Four possibilities can be put forward. One possibility is that the defects are due to thrombosis *in situ* occurring in cases of idiopathic pulmonary hypertension. This seems to be the most likely explanation in Case 21, the only patient in the whole series to give a family history of idiopathic pulmonary hypertension. A predisposition to thrombosis *in situ* is not unexpected in idiopathic pulmonary hypertension in view of the medial necrosis sometimes observed, together with the low cardiac output, partially obstructed vasculature, and occasional polycythaemia. In fact 2 cases in Group 3 were polycythaemic (Case 16, Hb 17.9 g/100 ml, and Case 18, Hb 17.6 g/100 ml), in both of whom it was thought to be secondary to a right-to-left shunt through a patent foramen ovale. It is of interest that Case 2, a patient in Group 1, was also polycythaemic (Hb 17.8 g/100 ml) but had a normal lung scan. Lesions that have been interpreted as thrombosis *in situ* are frequently described in idiopathic pulmonary hypertension (Evans *et al.*, 1957; Shepherd *et al.*, 1957; Dresdale, Schultz, and Michtom, 1951) and often occur in arteries that seem to be of the right order of size to give the angiographic and perfusion scan findings of Group 3. Against this possibility, though it is admitted that the groups are small for such a comparison, are the facts that Group 1 are all women and that the mean duration of illness to the time of scan is 6 years, whereas, there are men and women

in Group 3 and the duration of illness is shorter (mean 4 years) not longer as might be expected if they were advanced cases of idiopathic pulmonary hypertension. The second possibility is that Group 3 cases are thromboembolic in origin. However, only one patient (Case 19) gave a convincing story to support this contention, whereas the majority of cases in Group 2 did have a positive history, and also it is difficult to accept that the widespread embolization implied could be silent in the acute phase. The third possibility is that Group 3 is non-homogeneous and includes examples of thromboembolic disease (Case 19) and complicated idiopathic disease (Case 21). Finally, it may be that this group constitutes a truly separate entity. The reason for supposing this is based on the scan and angiogram findings which we feel differ significantly from those in the other two groups and are to a large extent consistent within the group itself. This casts doubt on the simple separation of cases with chronic pulmonary hypertension into 'large' and 'small vessel disease' groups. The validity and usefulness of such a tripartite division in the absence of hard aetiological evidence will depend on close correlation with the clinical features and long-term follow-up.

In conclusion we think that on the basis of perfusion lung scanning 3 groups of patients with chronic obliterative pulmonary hypertension can be differentiated. This observation suggests that there may be at least three different underlying aetiologies.

This work has been supported by a Medical Research Council Grant.

References

- Blount, S. G. (1967). Primary pulmonary hypertension. *Modern Concepts of Cardiovascular Disease*, **36**, 67.
- Chandler, H. L. (1971). Fissure sign in lung perfusion scintigrams. *Journal of Nuclear Medicine*, **12**, 326.
- Chrispin, A. R., Goodwin, J. F., and Steiner, R. E. (1963). The radiology of obliterative pulmonary hypertension and thromboembolism. *British Journal of Radiology*, **36**, 705.
- Dalen, J. E., Mathur, V. S., Evans, H., Haynes, F. W., Pur-Shahiari, A. A., Stein, P. D., and Dexter, L. (1966). Pulmonary angiography in experimental pulmonary embolism. *American Heart Journal*, **72**, 509.
- Dresdale, D. T., Schultz, M., and Michtom, R. J. (1951). Primary pulmonary hypertension. *American Journal of Medicine* **11**, 686.
- Dworkin, H. J., Smith, J. R., and Bull, F. E. (1966). Reaction after administration of macro-aggregated albumin for a lung scan. *New England Journal of Medicine*, **275**, 376.
- Eaton, S. B., James, A. E., Greene, R. E., Lyons, J. H., Potsaid, M. S., and Fleischner, F. G. (1969). New patterns of abnormal pulmonary perfusion associated with pulmonary emboli. I. Scintigraphic manifestations. *Journal of Nuclear Medicine*, **10**, 571.
- Evans, W., Short, D. S., and Bedford, D. E. (1957). Solitary pulmonary hypertension. *British Heart Journal*, **19**, 93.
- Farrar, J. F. (1963). Idiopathic pulmonary hypertension. *American Heart Journal*, **66**, 128.
- Fleischner, F. G. (1967). Recurrent pulmonary embolism and cor pulmonale. *New England Journal of Medicine*, **276**, 1213.
- Fowler, N. O., Black-Schaffer, B., Scott, R. C., and Gueron, M. (1966). Idiopathic and thromboembolic pulmonary hypertension. *American Journal of Medicine*, **40**, 331.
- Gize, R., Dizon, M., and Mishkin, F. (1971). Analysis of the fissure sign (abstract). *Journal of Nuclear Medicine*, **12**, 434.
- Goff, A. M., and Gaensler, E. A. (1965). Primary (idiopathic) pulmonary hypertension. *Medicina Thoracalis*, **22**, 530.
- Goodwin, J. F., Harrison, C. V., and Wilcken, D. E. L. (1963). Obliterative pulmonary hypertension and thromboembolism. *British Medical Journal*, **1**, 701 and 777.
- Greenspan, R. H., and Steiner, R. E. (1969). The radiological diagnosis of pulmonary thromboembolism. In *Frontiers of Pulmonary Radiology*, p. 222. Ed. by M. Simon, E. J. Potchen, and M. Le May. Grune and Stratton, New York.
- Haegelin, H. F., and Murray, J. F. (1968). Means of distinguishing pulmonary emboli and other causes of pulmonary hypertension. *Diseases of the Chest*, **53**, 138.
- Hood, W. B., Spencer, H., Lass, R. W., and Daley, R. (1968). Primary pulmonary hypertension: familial occurrence. *British Heart Journal*, **30**, 336.
- James, A. E., Eaton, S. B., Page, D. L., Potsaid, M. S., and Fleischner, F. G. (1969). An experimental model to study pulmonary microembolism. *Radiology*, **92**, 924.
- James, A. E., Eaton, S. B., Potsaid, M. S., and Fleischner, F. G. (1970). Scintigraphic patterns of large and small pulmonary emboli. *Journal of Nuclear Medicine*, **11**, 214.
- Jones, N. L., and Goodwin, J. F. (1965). Respiratory function in pulmonary thromboembolic disorders. *British Medical Journal*, **1**, 1089.
- Moser, K. M., Houk, V. N., Jones, R. C., and Hufnagel, C. C. (1965). Chronic massive thrombotic obstruction of the pulmonary arteries. *Circulation*, **32**, 377.
- Moser, K. M., Tisi, G. M., Rhodes, P. G., Landis, G. A., and Miale, A. (1966). Correlation of lung photoscans with pulmonary angiography in pulmonary embolism. *American Journal of Cardiology*, **18**, 810.
- Nadel, J. A., Gold, W. M., and Burgess, J. H. (1968). Early diagnosis of chronic pulmonary vascular obstruction. *American Journal of Medicine*, **44**, 16.
- Nash, E. S., Shapiro, S., Landau, A., and Barnard, C. N. (1968). Successful thromboembolotomy in long-standing thromboembolic pulmonary hypertension. *Thorax*, **23**, 121.
- Oakley, C. M., and Goodwin, J. F. (1967). The current status of pulmonary embolism and pulmonary vascular disease in relation to pulmonary hypertension. *Progress in Cardiovascular Diseases*, **9**, 495.
- Poulouse, K., Reba, R. C., and Wagner, H. N. (1968). Characterization of the shape and location of perfusion defects in certain pulmonary diseases. *New England Journal of Medicine*, **279**, 1020.
- Rao, B. N. S., Moller, J. H., and Edwards, J. E. (1969). Primary pulmonary hypertension in a child. Response to pharmacologic agents. *Circulation*, **40**, 583.
- Roberts, H. J. (1970). Fatal hemoptysis in pulmonary embolism probably precipitated by pulmonary scanning. *Angiology*, **21**, 270.
- Rogge, J. D., Mishkin, M. E., and Genovese, P. D. (1966). The familial occurrence of primary pulmonary hypertension. *Annals of Internal Medicine*, **65**, 672.
- Rosenberg, S. A. (1964). A study of the etiological basis of primary pulmonary hypertension. *American Heart Journal*, **68**, 484.
- Shepherd, J. T., Edwards, J. E., Burchell, H. B., Swan, H. J. C., and Wood, E. H. (1957). Clinical, physiological,

- and pathological considerations in patients with idiopathic pulmonary hypertension. *British Heart Journal*, **19**, 70.
- Stein, P. D., O'Connor, J. F., Dalen, J. E., Pur-Shahriari, A. A., Hoppin, F. G., Hammond, D. T., Haynes, F. W., Fleischner, F. G., and Dexter, L. (1967). The angiographic diagnosis of acute pulmonary embolism: evaluation of criteria. *American Heart Journal*, **73**, 730.
- Steiner, S. H., and Quinn, J. M. (1968). Cardiovascular hemodynamics. Determination from the distribution of pulmonary blood flow in seated patients. *Journal of the American Medical Association*, **203**, 850.
- Tetalman, M. R., Hoffer, P. B., Heck, L. L., Kunzmann, A., Gottschalk, A., Webber, M. M., Reznick, L., Cragin, M., and Victory, W. (1971). Appearance of the lung scan in normal individuals (abstract). *Journal of Nuclear Medicine*, **12**, 401.
- Tsagaris, T. J., and Tikoff, G. (1968). Familial primary pulmonary hypertension. *American Review of Respiratory Disease*, **97**, 127.
- Vincent, W. R., Goldberg, S. J., and Desilets, D. (1968). Fatality immediately following rapid infusion of macroaggregates of ^{99m}Tc albumin (M.A.A.) for lung scan. *Radiology*, **91**, 1181.
- Wagenvoort, C. A., Heath, D., and Edwards, J. E. (1964). *The Pathology of the Pulmonary Vasculature*. C. C. Thomas, Springfield, Illinois.
- Wagner, H. N., Sabiston, D. C., McAfee, J. G., Tow, D., and Stern, H. S. (1964). Diagnosis of massive pulmonary embolism in man by radioisotope scanning. *New England Journal of Medicine*, **271**, 377.
- Walker, R. H. S., and Jackson, J. A. (1969). Scanning of the lung. *Proceedings of the Royal Society of Medicine*, **62**, 799.

Requests for reprints to Dr. Alan G. Wilson, Department of Diagnostic Radiology, Hammersmith Hospital, Du Cane Road, London W.12.