

Long sheath technique for introduction of catheter tip manometer or endomyocardial bioptome into left or right heart

I. A. B. Brooksby, R. H. Swanton, B. S. Jenkins, and M. M. Webb-Peploe

From the Cardiac Department, St. Thomas' Hospital, London

A modification of Forman's technique is described using ultra-thin wall 'teflon' tubing as a disposable long sheath. By this method, solid constructed catheters and endomyocardial bioptomes can be passed across the atrial septum to the left ventricle without manipulation. The sheath can also be used as a modification of the Seldinger technique enabling introduction of similar catheters to the left ventricle from the right femoral artery and to the right ventricle from the right femoral vein.

The development of catheter tip manometers (Allard-Laurens Telco, Statham SF-1 and Millar micromanometers), catheter flow probes, and catheter bioptomes (Konno-Sakakibara endomyocardial bioptome) provides the cardiologist with increased scope for sophisticated studies. These instruments are, by reason of their complexity, equivalent in size to a large catheter (No. 7, 8, or 9 French Gauge) and of solid construction so that they cannot be introduced percutaneously over a wire (Seldinger, 1953). The stiffer construction of these instruments compared with conventional catheters makes their intravascular manipulation more difficult, and there is, therefore, a greater risk of intimal damage and of arrhythmias. Extensive manipulation may also contribute to the early failure of these expensive instruments.

The use of a short sheath (Desilets and Hoffman, 1965) allows percutaneous introduction of solid ended catheters but the problem of manipulation remains. In order to solve both the problem of percutaneous introduction and of accurate placement in the circulation with the minimum of manipulation the St. Thomas' long sheath technique was developed.

Method

Ultra-thin wall non radio-opaque 'teflon' medical grade tubing (Becton, Dickinson U.K. Ltd.) is used to manufacture the disposable long sheaths. The tubing size appropriate for the various probe sizes is given in Table 1.

This tubing is not made to exact internal diameter specifications and as a result there is some variation in preciseness of fit between different batches of tubing and the same size catheter probe. For the best results the size of tubing should be selected which closely fits the catheter but which is not so tight that it prevents easy insertion of the catheter into the sheath.

These long sheaths have been used in three different ways:

1) Venous transeptal route. The sheath is passed over a transeptal catheter across the interatrial septum and down through the mitral valve to the left ventricle. This route is used in patients with aortic valve disease or aortic valve replacements. Exceptions are those with a

TABLE 1 *Appropriate sizes of long sheath for standard catheters and probes*

French gauge	Catheter or probe	Appropriate long sheath		
		Description*	Interior diameter (mm)	Exterior diameter (mm)
6	Millar 5FG	UTX 085	2.16	2.56
7	Telco	UTX 106	2.70	3.10
	Millar			
	Flow probe			
8	Telco	UTX 118	3.00	3.30
	Millar			
	Flow probe			
	Small bioptome			
9	Large bioptome	UTX 125	3.18	3.58

past history of systemic emboli in whom transeptal puncture is probably contraindicated.

2) Venous right ventricular route. The sheath is passed on a suitable catheter to the right ventricle. This route is used for endomyocardial biopsy using the Konno-Sakakibara endomyocardial biptome. It is also useful when difficulty is anticipated in crossing the tricuspid valve (e.g. tricuspid prosthesis or tricuspid stenosis) and enables a twin lumen catheter to be followed by an angiocatheter without the necessity of crossing the valve twice.

3) Arterial left ventricular route. The sheath is passed on a left heart catheter retrogradely across the aortic valve to the left ventricle. This route is used in patients with mitral valve disease or with a mitral valve prosthesis in whom it may be difficult or unwise to pass a transeptal catheter down through the mitral valve to the left ventricle. The route is also used in patients in whom transeptal puncture is contraindicated.

Technique

1) Venous transeptal route

A standard Brockenbrough transeptal needle and pre-curved No. 8 'teflon' transeptal catheter are used (Brockenbrough and Braunwald, 1960). The long sheath is fitted over the 'teflon' catheter and cut to such a length that with the catheter fully advanced the distal end of the sheath lies just proximal to the side holes of the catheter (Fig. 1). A sterile 'band-aid' (Johnson and Johnson) is stuck securely round the proximal end of the sheath to form a flange (Fig. 2) to prevent any possibility of the whole sheath advancing into the patient.

The transeptal catheter and long sheath are introduced via a right long saphenous vein cut-down or by percutaneous puncture of the right femoral vein (Seldinger technique) and advanced to the superior vena cava. A Brockenbrough needle is inserted and the atrial septum is punctured immediately below the limbic ledge in the floor of the fossa ovalis (Bloomfield and Sinclair-Smith, 1965). When needle puncture has been achieved, the catheter and needle are advanced to the left atrium. The passage of the catheter across the septum is usually appreciated by the operator. The needle is then withdrawn until the tip lies just within the 'teflon' catheter. The catheter and sheath are then advanced over the needle and the passage of the sheath across the septum can also be felt by the operator. With the needle removed the catheter and sheath may be passed through the mitral valve to the left ventricle. This manoeuvre is best achieved by the insertion of a 'teflon' coated guide wire which is passed through the mitral valve. Then the catheter and sheath are advanced to the left ventricle over the wire. By using a soft ended guide wire there is less risk of perforating the atrial wall than when manipulating the rigid 'teflon' transeptal catheter.

Once the catheter and sheath are in the left ventricle, the sheath is advanced slightly over the catheter which is then withdrawn holding the sheath firmly. With the sheath in place a catheter tip micromanometer, endomyocardial biptome, or a twin lumen catheter can be

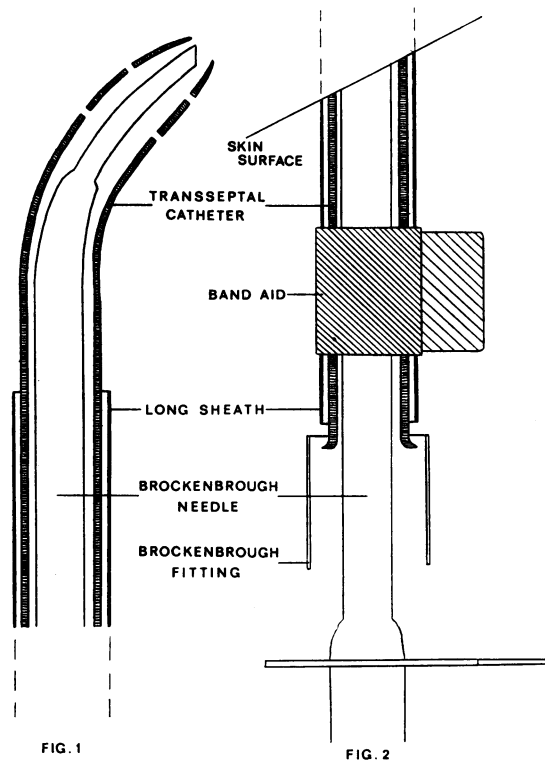


FIG. 1 Distal end of transeptal catheter, with long sheath cut just proximal to side holes.

FIG. 2 Proximal end of transeptal catheter and needle. The long sheath is fitted with a 'band-aid' as shown.

passed directly to the left ventricle down the sheath with no further manipulation (Fig. 3). It is emphasized that when exchanging catheters in the sheath, free back flow of blood must be allowed to occur down the sheath after withdrawal of the first catheter to remove any blood clot or air before advancing the new catheter. On rare occasions the sheath becomes kinked, thus preventing this free back flow of blood, but withdrawal of the sheath for a few millimetres overcomes this problem.

In those patients with low left atrial pressures in whom catheters are exchanged while the sheath remains in the left atrium, the exchange should be carried out while the patient performs a Valsalva manoeuvre. This will prevent air embolism caused by air being sucked into the left atrium down the sheath during the catheter exchange.

When it is not possible or desirable to cross the mitral valve, the transeptal catheter is replaced via the sheath by a No. 8 NIH angiocatheter. This catheter is less likely to perforate the left atrium and subsequently may be used for left atrial angiography, thus avoiding the use of an end-hole blocker.

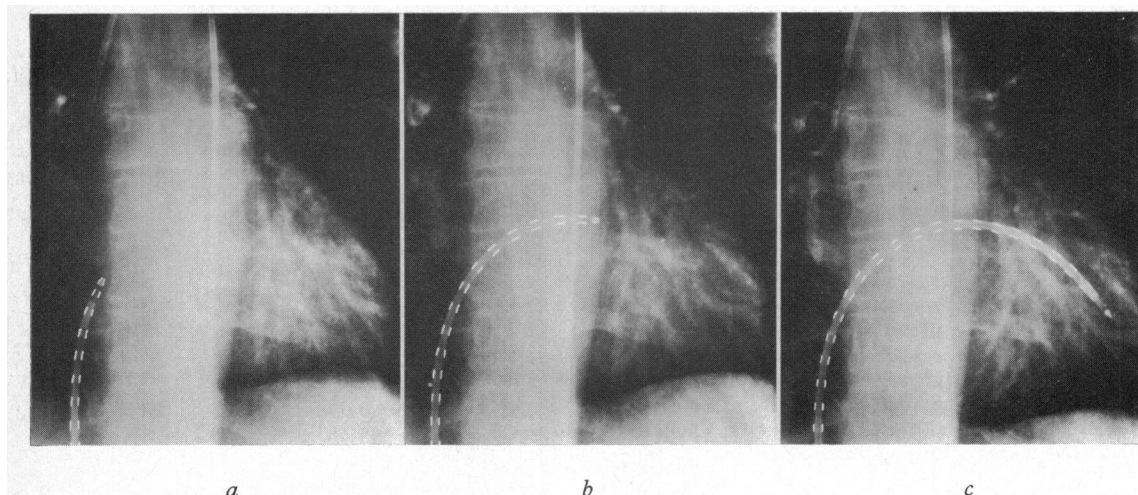


FIG. 3 Anteroposterior projections of the heart to show advancement of the Telco micro-manometer to the left ventricle through the long sheath; a) in the right atrium; b) in the left atrium; and c) in the left ventricle. The long sheath is not radio-opaque. A Judkins pigtail catheter has been advanced to the ascending aorta.

2) Venous right ventricular route

The long sheath is cut to approximately the same length as for the transeptal route. It is often possible to use the transeptal sheath described previously after it has been withdrawn from the left heart. A No. 8 NIH angi-catheter is passed to the apex of the right ventricle and the sheath advanced over the catheter. With the sheath in place, several endomyocardial biopsies may be taken without further manipulation.

3) Arterial left ventricular route

The long sheath is introduced over a Judkins pigtail catheter using the standard Seldinger technique. The sheath is cut so that its distal end is just proximal to the side holes when the catheter is fully advanced down the sheath. The sheath is fitted with a sterile 'band-aid' at its proximal end. The catheter and sheath are introduced via the right femoral artery and advanced to the left ventricle. Introducing the sheath into the artery is facilitated by blunt dissection of the subcutaneous tissues overlying the artery. The introduction of the sheath into the artery is achieved by gripping the sheath and catheter firmly and twisting slightly as both are advanced over the guide wire into the vessel. The catheter may be replaced via the sheath by a catheter tip micromanometer or endomyocardial biptome.

Results

The long sheath has been used 225 times in 187 patients (Table 2). The venous transeptal route was employed in 158 of the patients with an age range of 9 to 70. In 22 of this group, the arterial

TABLE 2 Routes by which long sheath was used

Venous transeptal	126
Venous transeptal and venous right ventricular	9
Venous transeptal and arterial left ventricular	22
Venous transeptal, arterial left ventricular, and venous right ventricular	1
Venous right ventricular	3
Venous right ventricular and arterial left ventricular	5
Arterial left ventricular	21
Total	187

route was also used, and in 10 the sheath was advanced to the right ventricle after it had been withdrawn across the atrial septum. In one patient, the venous transeptal, arterial left ventricular, and venous right ventricular routes were all used. The long sheath was passed by the arterial route alone in 21 patients (age range 17 to 66), by the venous right ventricular route alone in 3 patients (age range 9 to 68), and by both routes in 5 patients.

The majority of the patients in the series suffered from valvular heart disease, but patients with primary myocardial disease, congenital heart disease, and ischaemic heart disease were also studied (Table 3).

1) Venous transeptal route

Of the 158 transeptal catheterizations attempted, it was not possible to introduce the sheath to the left

TABLE 3 *Diagnosis and routes of using long sheath*

	Arterial	Venous	Transseptal
Valvular heart disease	39	7	134
Primary myocardial disease	6	7	12
Congenital heart disease	3	3	7
Ischaemic heart disease	1	1	5
Total	49	18	158

atrium in 5 patients (3.2%). Of these 5, needle puncture only was achieved in 1 patient. The 'teflon' catheter passed to the left atrium in the other 4 but the sheath could not be advanced across the interatrial septum. In 153 patients, the sheath crossed the septum and the left ventricle was entered in 124. In 21 patients, no attempt was made to cross the mitral valve either because of severe mitral valve disease or the presence of a mitral valve prosthesis. In 8 patients (5%) it was not possible to reach the left ventricle, most cases because of the combination of a large left atrium and mitral stenosis. In this series, if the left ventricle could not be entered by this route, an arterial sheath was used. In the 124 studies in which the sheath was advanced to the left ventricle, a catheter tip micromanometer was passed via the sheath to the left ventricle in 107 (86%) - 62 Telco and 45 Millar. The endomyocardial biopome was used in 3 patients, and in all instances a No. 8 NIH angiocatheter was used for angiography. In one patient the sheath was displaced back to the right atrium while the micromanometer was being advanced. A No. 8 twin lumen catheter for simultaneous left atrial and ventricular pressures was introduced via the sheath in 23 studies (18.5%).

2) Venous right ventricular route

The long sheath was used in 18 studies to gain access to the right ventricle. In 10 of these, the sheath had been withdrawn across the atrial septum after transseptal catheterization of the left heart. The sheath was advanced to a suitable position at the apex of the right ventricle over a No. 8 NIH angiocatheter. In 14 patients, the endomyocardial biopome was used via this sheath and in the other 4 either a twin lumen catheter or micromanometer was substituted. In 2 patients the sheath recoiled into the right atrium while the biopome was being introduced, but was easily repositioned again over the No. 8 NIH angiocatheter.

3) Arterial left ventricular route

The arterial sheath was introduced over a Judkins pigtail catheter in all 49 patients, either a No. 7 or No. 8 French gauge, and in 48 of these a catheter

tip micromanometer (22 Telco and 26 Millar) was substituted and passed via the sheath to the left ventricle. In one patient the iliac arteries were tortuous and though the sheath passed to the left ventricle, the Telco micromanometer could not be advanced down the sheath beyond the bifurcation of the aorta.

Complications

The majority of the complications in this series are not peculiar to the sheath technique.

There have been 6 episodes of systemic embolism in the 188 patients (3.2%), all of whom had cerebral emboli. Two of these occurred while using an arterial sheath; one while passing the catheter round the aortic arch and the other while attempting to cross a calcified stenotic aortic valve. Four cerebral emboli occurred during transseptal catheterization, one occurring before any catheters had been exchanged via the sheath and one due to the accumulation of blood clot in the side holes of a micromanometer. One patient had a disturbance of consciousness after exchange of catheters down the sheath to the left atrium; the left atrial pressure was low and the episode was probably caused by an air embolus. Four of the patients with cerebral emboli made a complete recovery but one patient has a mild residual visual defect and one a moderate residual speech disturbance.

There were 5 cases of haemopericardium in a total of 158 transseptal catheterizations. In 2 patients this was an incidental finding at the time of surgery. Three patients (1.9%) required percutaneous pericardial aspiration but none required open thoracotomy. In one of these cases, the 'teflon' transseptal catheter was left *in situ* in the left ventricle and it slowly traversed the ventricular wall. After this incident, the transseptal catheter is always replaced by a No. 8 NIH angiocatheter once the left ventricle is entered.

There were two local vascular complications in the series (1.3%). One patient with severe varicose veins developed a deep venous thrombosis in the right leg after catheterization and had a small pulmonary embolus 10 days later. The other patient, a small woman with a low cardiac output, suffered a right femoral artery occlusion and was treated successfully by a right femoral artery thrombectomy. One death occurred in this series; a patient who had severe ventricular arrhythmias during the catheter procedure and died in ventricular fibrillation. Necropsy revealed evidence of rheumatic heart disease and ischaemic heart disease only, so that this patient's death cannot be attributed to the use of the long sheath.

Discussion

A method of introducing pressure, flow, and biopsy probes easily and safely into the correct position in the circulation without manipulation is described. This technique uses disposable ultra-thin wall 'teflon' tubing fitted over standard catheters and is a modification of Forman's technique (Forman, Laurens, and Servelle, 1962). In Forman's description, a Ross needle and Lehman catheter were used for the transseptal puncture and the sheath described, made of either 'polythene' or 'teflon', had a much thicker wall. To facilitate its passage across the atrial septum, Forman recommended tapering the tip by drawing it out using heat. The thicker wall of this sheath resulted in its being much stiffer than the one described in the present series. For this reason, Forman and other workers who have used this technique (Mendel, 1968) made no attempt to enter the left ventricle with the sheath but exchanged the needle and transseptal catheter for the micromanometer as soon as the sheath had entered the left atrium. As Forman *et al.* stated, this resulted on several occasions in the recoil of the sheath into the right atrium. It has the further disadvantage that once the micromanometer or endomyocardial biop-tome has reached the left atrium, it must then be manipulated down through the mitral valve. In Forman's experience, entry into the left ventricle was prevented by severe mitral regurgitation on a number of occasions.

In the present series, a standard Brockenbrough transseptal needle and catheter was used. If the interatrial septum is punctured in the floor of the fossa ovalis, the catheter and sheath pass easily to the left atrium, and in only 5 (3.2%) was it not possible to place the sheath in the left atrium. In 124 out of 132 patients, the left ventricle was entered by this route and in only 8 was it impossible (6%). The passage of the catheter and sheath through the mitral valve is very much easier and safer if a 'teflon' coated guide wire is passed to the left ventricle across the mitral valve and the catheter and sheath advanced over the wire. The stiff 'teflon' transseptal catheter is replaced by a blunt ended catheter to avoid perforation of the left atrial or ventricular wall. Free back flow of blood must be allowed to occur down the sheath to remove all blood clot and air when exchanging catheters. Failure to do this probably caused air embolism in one patient.

A further use of this ultra-thin wall 'teflon' tubing, not previously described, is for introducing the micromanometer or endomyocardial biop-tome into the left ventricle by the arterial route or into the right ventricle by the venous route. The arterial route is used when the transseptal route is

contraindicated or where it has not been possible to cross the mitral valve. In all cases in this series it was possible to pass the sheath to the left ventricle but in one case the Telco micromanometer would not pass up the sheath beyond a tortuous iliac artery. In 2 cases a mild hemiplegia occurred, possibly unrelated to the use of the sheath, and there was one case of femoral artery occlusion. If possible the use of the arterial sheath is avoided in patients with a very low cardiac output or small arteries. The catheter tip micromanometer passes easily to the left ventricle down the sheath without risk of damaging the intima or catheter tip and can then be replaced by a catheter suitable for angiography.

The incidence of complications is similar to the American Heart Association's co-operative study on cardiac catheterization (Braunwald and Swan, 1968). In our series, 1.9 per cent of transseptal catheterizations required percutaneous pericardial aspiration compared with 1.2 per cent of the American series. In this preliminary series, the incidence of femoral artery thrombosis (2%) is not greatly increased by the use of the long sheath (1.1% in the American series). Similarly, there was only one case of deep vein thrombosis and pulmonary embolism (0.5%) compared with 0.3%.

This technique has proved invaluable in assessing left ventricular function using catheter tip manometers. It has also largely overcome the difficulties and hazards of manipulating the endomyocardial biop-tome into the right or left ventricle.

We would like to thank Dr. D. Mendel whose use of thin wall 'teflon' tubing to make short arterial sheaths, suggested its use as described in this paper.

References

- Bloomfield, D. A., and Sinclair-Smith, B. C. (1965). The limbic ledge. A landmark for transseptal left heart catheterization. *Circulation*, **31**, 103.
- Braunwald, E., and Swan, H. J. C. (1968). Cooperative study on cardiac catheterization. *Circulation*, **37**, Suppl. No. 3.
- Brockenbrough, E. C., and Braunwald, E. (1960). A new technic for left ventricular angiocardiography and transseptal left heart catheterization. *American Journal of Cardiology*, **6**, 1062.
- Desllets, D. T., and Hoffman, R. (1965). A new method of percutaneous catheterization. *Radiology*, **85**, 147.
- Forman, J., Laurens, P., and Servelle, M. (1962). Le cathétérisme des cavités gauches au micromanomètre par voie transseptale. *Archives des Maladies du Coeur et des Vaisseaux*, **55**, 601.
- Mendel, D. (1968). *A Practice of Cardiac Catheterisation*. Blackwell Scientific Publications, Oxford and Edinburgh.
- Seldinger, S. I. (1953). Catheter replacement of the needle in percutaneous arteriography. *Acta Radiologica*, **39**, 368.

Requests for reprints to Dr. M. M. Webb-Peploe, Cardiac Department, St. Thomas' Hospital, London SE1 7EH.