

# Shrinking pleuritis with atelectasis

L DERNEVIK, P GATZINSKY, E HULTMAN, K SELIN, G WILLIAM-OLSSON,  
L ZETTERGREN

*From the Departments of Thoracic and Cardiovascular Surgery, X-ray and Pathology, University of Göteborg, Sahlgrenska sjukhuset, Göteborg, Sweden*

**ABSTRACT** During a 10-year period 28 patients with shrinking pleuritis with atelectasis (SPA) were observed and operated upon. This lesion has been given different names in the literature, for instance rounded atelectasis, pleuroma, pulmonary pseudotumour, and lung folding. All patients except two were operated upon because of a diagnosis of pulmonary tumour. However, at operation no tumour was found. The aetiology and pathogenesis of SPA are discussed on the basis of X-ray, operative, and histopathological findings.

In 1966 Blesovsky<sup>1</sup> described three patients who were operated upon because of suspected pulmonary tumour. At operation no tumour was found but a thick fibrous membrane covered part of the lung. The underlying parenchyma was atelectatic but when the membrane was stripped off, the lung expanded completely and looked normal. Similar cases were described by Hanke<sup>2</sup> in 1971 and Kretzschmar<sup>3</sup> in 1975. They collected seven and five cases respectively and called the lesion rounded atelectasis. Other reports have since been published.<sup>4-10</sup> The diagnosis in the reported cases was made by X-ray and was not always verified by operation or histopathological examination. Radiologically, the lesion is characterised by a rounded or lobulated mass under the visceral pleura with adjacent pleural thickening and with vessels and bronchi curling into it like a "comet tail" (figs 1-3). In many cases the radiological findings are sufficiently typical to allow the diagnosis to be made with confidence. The aim of this paper is to present a series of patients with this lesion, which we have called shrinking pleuritis with atelectasis (SPA), and to discuss its aetiology and pathogenesis.

## Patients

During the years 1970-80, 26 patients were operated upon at the Department of Thoracic and Cardiovascular Surgery at Sahlgrenska Hospital in Gothenburg because of suspected pulmonary malignancy. At operation, however, no tumour was present.

Address for reprint requests: L Dernevik, Department of Thoracic and Cardiovascular Surgery, Sahlgrenska sjukhuset, 413 45 Göteborg, Sweden.

Only atelectatic lung tissue was found, covered by a thick fibrotic visceral pleura. In two other patients a similar lesion was discovered at operation for hiatal hernia. The series thus comprises 28 patients. All patients except one were male. The age distribution is given in fig 4 and the locations of the lesions are summarised in table 1.

Fourteen patients were asymptomatic. In 12 a radiographic opacity was found during a routine

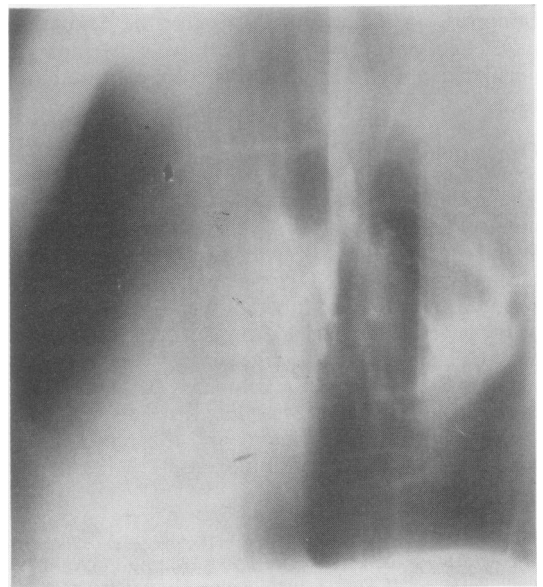


Fig 1 Lateral tomogram demonstrating the typical features of shrinking pleuritis with atelectasis—a sharply defined mass with vessels curling into its border and adjacent pleural thickening.

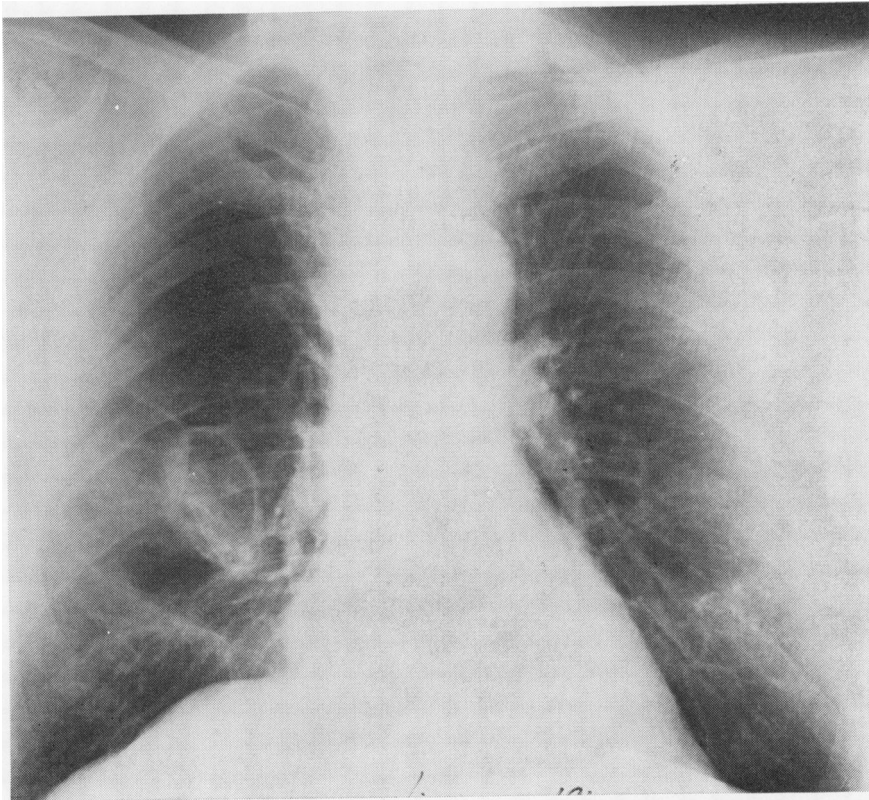


Fig 2 Chest radiograph showing a cyst-like lesion in the right lung. Same patient as fig 1.

Table 1 Location of shrinking pleuritis with atelectasis

Location	Number
Left upper lobe	3 (2 in lingula)
Right middle lobe	3
Left lower lobe	8
Right lower lobe	14

health check and two were found during operation for hiatal hernia. The remaining patients had various pulmonary symptoms. Cough was found in eight patients and was usually non-productive. Two patients presented with haemoptysis and two with fatigue and dyspnoea. The duration of symptoms before operation usually varied from two to six months but three patients had had symptoms for two or three years. Twenty-five patients were smokers. Eighteen of them had a history of occupational exposure to asbestos. In addition three non-smoking patients were exposed to asbestos. Other substances, such as chemicals, textile fibres, glass fibres, silicone, and stone dust, were found only occasionally (fig 5). No patient had a history of tuberculosis.

Preoperative chest radiographs were re-examined

in all patients except one, with special reference to signs of rounded atelectasis as described by Hanke and Kretzschmar<sup>6</sup> and Schneider *et al.*<sup>7</sup> Antero-posterior and lateral views and in 12 cases lateral tomograms, were available.

### Results

The three most typical radiological signs of SPA are a rounded parenchymal lesion, pleural plaques, and "comet tail" (table 2). In 17 cases all three signs were present, in five cases one or two signs could be recognised, and in six cases none of them were present. Two of the latter patients were operated upon for hiatal hernia, three had diffuse pulmonary infiltration, and one had lower lobe atelectasis.

Eighteen patients were referred for operation immediately after investigations at the lung clinic. In eight patients the lesions were observed from two to 44 months before operation (mean 11 months). In most cases no radiographic change was noted during the observation period. In one case, however, a change in the lesion was demonstrated. This patient was a 62-year-old shipyard worker with massive exposure to asbestos. He was also a heavy smoker. The patient was examined as part of a

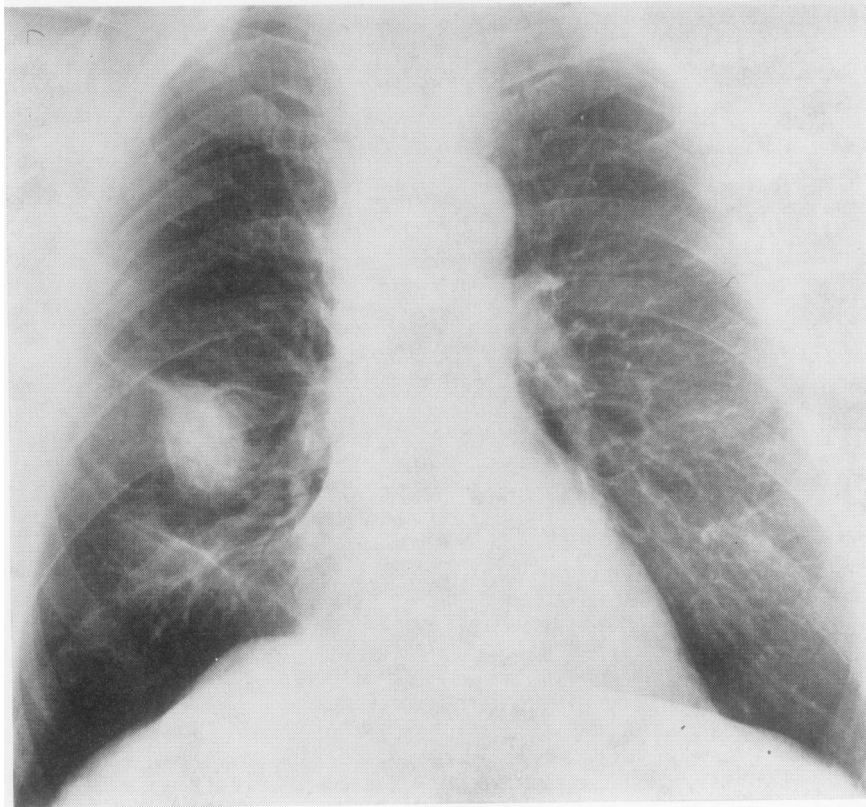


Fig 3 Same patient as figs 1 and 2 10 months later. The lesion has become compact and round simulating a lung tumour.

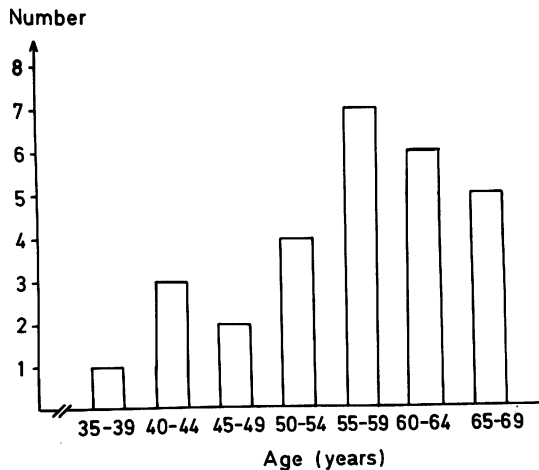


Fig 4 Distribution of patients according to age.

routine health examination and had no symptoms. The radiograph showed marked pleural thickening and a cyst-like lesion in the middle lobe (fig 2). There were wide vessels curling into the lower pole of the lesion. The findings did not suggest a

Table 2 Features indicating shrinking pleuritis with atelectasis

	Number of patients
Rounded lesion	21
Pleural plaques	18
"Comet tail"	18

tumour. A new radiograph taken two months later showed a dense oblong opacity. The vessels had the same appearance as before. A further radiograph (fig 3), eight months after the second one, showed the lesion to be compact and round. In view of the possibility of tumour the patient was referred for operation. This revealed a folding of the lung in the middle lobe, together with several pleural plaques. There was no pleural fluid and the process was completely localised.

Cytological examination of sputum, bronchoscopy, and mediastinoscopy were performed as standard investigations in all patients in whom a tumour was suspected. One patient had a false positive cytological finding (Papanicolaou class IV) but in all other patients these investigations were negative. Lung function tests (VC, FEV<sub>1</sub>, and FEV<sub>1</sub>) were performed in all patients. Two had

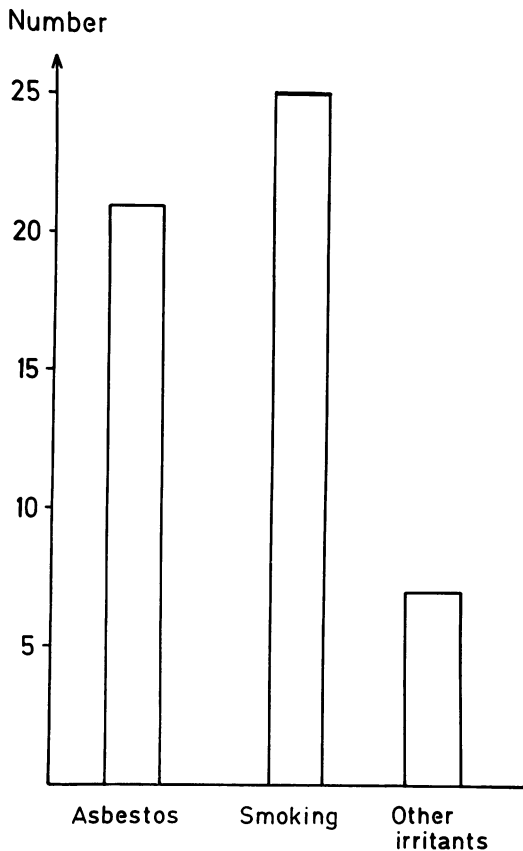


Fig 5 Number of patients exposed to asbestos, smoking, and other irritant factors.

subnormal values, reflecting slight restriction, but in all others the values were within normal limits.

#### OPERATIVE FINDINGS AND TREATMENT

The standard procedure was decortication and this was performed in 27 patients. At operation the lung was usually free from adhesions to the chest wall and acute pleurisy was never found. Twenty of the patients had plaques on the parietal pleura, often close to the parenchymal lesion. This consisted of a subpleural palpable mass covered with a localised greyish-white coating. It was usually limited to an area about the size of the palm of the hand but in three cases it covered the whole lobe. The surrounding pulmonary tissue was sometimes emphysematous.

At decortication it was found that the coating consisted of several layers of fibrous tissue causing folding and atelectasis of the underlying lung tissue. When all the layers of the coating were removed, the

atelectatic part of the lung could be expanded and the normal appearance was restored. In one case a large atelectatic part of the lower lobe could not be expanded after decortication and lobectomy was performed.

#### HISTOPATHOLOGY

Microscopic examination of the material from seven of the patients showed fibrous thickening of the visceral pleura in all cases. The connective tissue was almost acellular and in two cases partly hyalinised. In one of these cases the pleural lesion had the appearance of a pleural plaque (fig 6). In most cases a slight or moderate infiltration of inflammatory cells was noted in the pleura. In four cases, numerous fibrous fascicles were seen reaching from the thickened pleura down into the pulmonary parenchyma perpendicular to the surface (fig 7). They showed a parallel arrangement and followed pre-existing fibrous septa and fissures. The parenchyma under the thickened pleura was in all cases atelectatic. Slight interstitial fibrosis and scattered lymphocytes

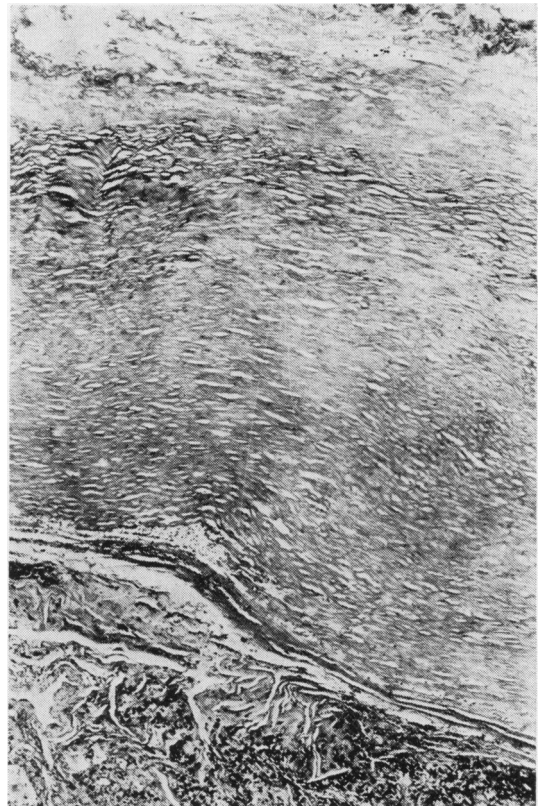


Fig 6 Visceral pleural plaque consisting of almost acellular hyalinised collagenous connective tissue. H and E  $\times 30$ .

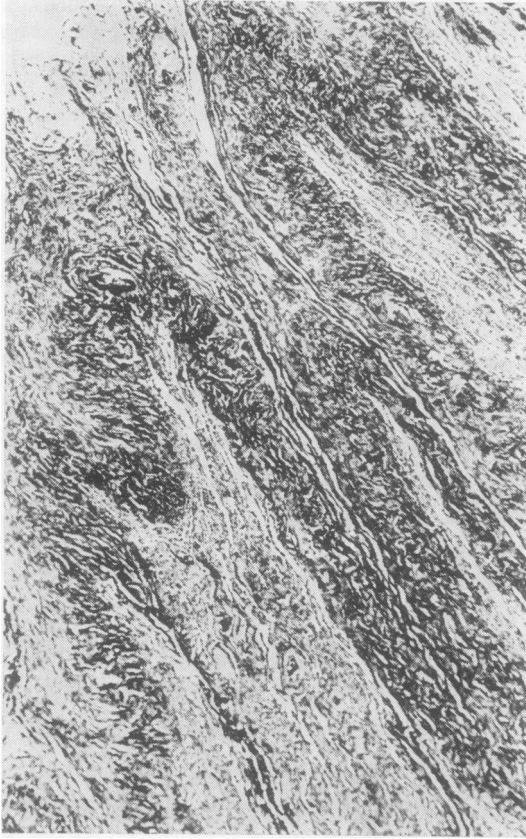

Fig 7 Fibrous fascicles are seen reaching from the thickened pleura (top left) into the atelectatic pulmonary parenchyma. The tissue is infiltrated by inflammatory cells. *H and E*  $\times 30$ .

and plasma cells were seen. The pulmonary vessels were sclerotic (fig 8). In two cases corpora amylacea were noted in the alveoli, in one of them in great numbers. In the boundary between the fibrotic pleura and the parenchyma carbon pigment with a varying admixture of small, double refringent particles (silica) was observed. In four cases asbestos bodies were noted, both in the pigmented area and deeper in the parenchyma. The asbestos bodies were numerous in one of these cases and sparse in two. In the fourth case asbestos bodies were found only occasionally. Particles of silica and carbon were also present deeper in the lung parenchyma.

#### FOLLOW-UP

There were no operative deaths and the postoperative course was uneventful in all patients except one who sustained a small myocardial infarction. Follow-up chest radiographs were obtained from 17 patients

at intervals ranging from four to 37 months (mean 18 months). No recurrences have been observed.

#### Discussion

The aetiology and pathogenesis of SPA are still not clear. Hanke<sup>2</sup> suggested that the changes were caused by the mechanical influence of a pleural effusion. However, few patients in published reports have actually been shown to have had a pleural effusion before the discovery of the parenchymal lesion. We have observed pleural fluid before operation in only four out of 14 patients with symptoms. In three of these patients the effusion was found on the same side as the atelectasis and in one patient on the contralateral side. The quantity of fluid was only small. In none of the patients without symptoms was any effusion observed on the radiograph or at operation.

In our opinion, this lesion starts as a local process in the visceral pleura. It seems that the main aetio-

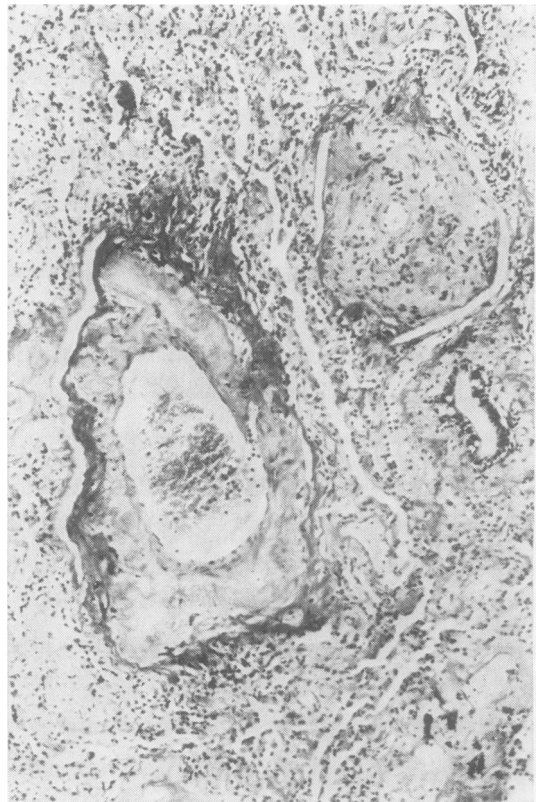


Fig 8 Atelectatic pulmonary tissue with sclerotic thick-walled vessels. *H and E*  $\times 70$ .

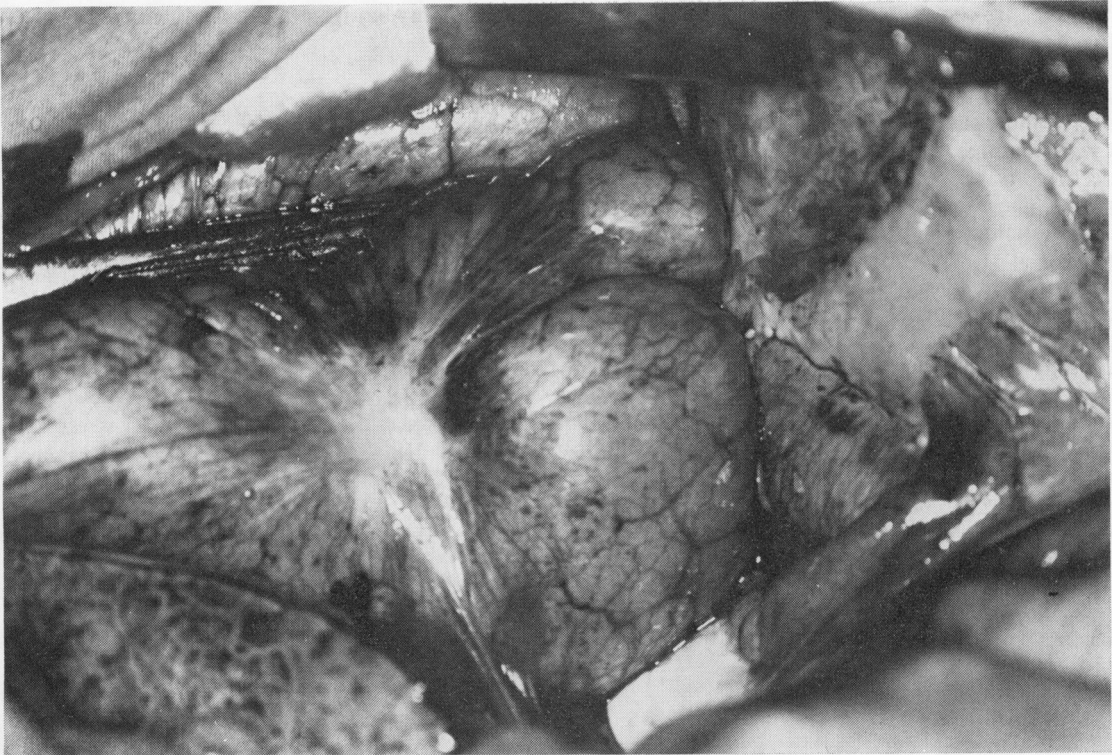


Fig 9 A case with very localised pleural shrinkage compressing the underlying lung. To the right a parietal plaque is seen on the diaphragm.

logical factor is the irritant effect of asbestos, alone or in combination with other irritants, such as silica or smoking. This irritation causes a local reaction with formation of a thick pleural fibrotic coating over a limited area of the lung. Subsequent shrinkage of this coating leads to folding of the lung surface. It seems that the development of new layers of the coating proceeds in parallel with shrinkage of the older ones. The result of this pleural shrinkage is the development of atelectasis of the underlying pulmonary parenchyma. The perpendicular septa noted on microscopical examination may also shrink, giving the collapsed area a rounded form. The fibrous coating on the visceral pleura may be aetiologically analogous to the parietal pleural plaque. This theory is supported by their very frequent coexistence and the fact that the visceral coating in two cases had a plaque-like appearance (fig 9). For these reasons we have called this lesion shrinking pleuritis with atelectasis.

In one patient we observed pathological changes in the lung which we believe to be a very early stage of this lesion. This was a 61-year-old man with a history of asbestos exposure many years earlier who had a thoracotomy because of hiatal

hernia. On the costal surface of the left lower lobe there was a localised greyish-white fibrotic coating with a similar appearance to that of patients with SPA. There was no pleural fluid. Slight folding of the lobe was seen when the fibrous coating on the lung surface had been dissected away and it was apparent that some shrinkage of the lung tissue had already occurred. When the coating was removed the lung parenchyma beneath it expanded completely. At biopsy asbestos bodies were found in the pulmonary parenchyma while the coating itself showed non-specific inflammation. This observation seems to contradict the earlier theory that the lesion starts with copious amounts of fluid folding the lung.

The diagnosis of SPA can be made from the typical radiographic appearance in many cases. In some cases, however, this is not possible. In 11 of the patients in this series, including the hiatal hernia patients, the radiographic features were not typical. In some of these the diagnosis could probably have been made with oblique views and tomograms if we had been more aware of the existence of this condition at the time. Nowadays computed tomography may be of assistance in diagnosis.

There are no published data concerning lung function in patients suffering from SPA. The tests of lung function in our patients gave somewhat surprising results. Vital capacity and forced expiratory volume were normal in all patients except two. Even in three patients in whom the atelectasis occupied a large part of a lobe, normal values were found. There may thus be a functional derangement of ventilation which cannot be detected by spirometry.

At present there is no generally accepted policy on the management of SPA. We consider that in patients in whom the diagnosis can be made with certainty the interference with lung function is too trivial to justify operation. However, these patients should be followed up regularly because very little is known about the natural history of the condition and no long-term observations appear to have been published. When the diagnosis of SPA is not certain the patient requires operation. Decortication is then an adequate procedure. The postoperative follow-up showed satisfactory results with this simple procedure in our patients. In really advanced cases, when the normal appearance of the atelectatic

part cannot be restored, a limited resection is justified.

#### References

- <sup>1</sup> Blesovsky A. The folded lung. *Br J Dis Chest* 1966;**60**: 19-22.
- <sup>2</sup> Hanke R. Rundatelektasen (Kugel- und Walzenatelektasen). *Roefo* 1971;**114**:164-83.
- <sup>3</sup> Kretzschmar R. Über atelaktatische Pseudotumoren der Lunge. *Roefo* 1975;**122**:19-29.
- <sup>4</sup> Bénard Y, Mandard JC, Evrard C, Leménager J. Opacité ronde pseudotumorale par atélectasie (A propos d'une observation). *Rev Fr Mal Respir* 1973;**1**:1171-7.
- <sup>5</sup> Brune J, Bosly A, Bory R, Perinetti M, Wiesendanger T, Galy P. Condensations parenchymateuses pulmonaires arrondies post-pleuretiques mecanisme physiopathologique. *Lyon Médical* 1974;**231**:605-9.
- <sup>6</sup> Hanke R, Kretzschmar R. Round atelectasis. *Seminars in roentgenology* 1980;**15**:2, 174-182.
- <sup>7</sup> Schneider HJ, Felson B, Gonzalez LL. Rounded atelectasis. *AJR* 1980;**134**:225-32.
- <sup>8</sup> Sinner WN. Pleuroma—a cancer-mimicking atelectatic pseudotumor of the lung. *Roefo* 1980;**133**:578-85.
- <sup>9</sup> Hillerdal G, Hemmingsson A. Pulmonary pseudotumours and asbestos. *Acta Radiol (Diagn) (Stockh)* 1980;**21**: 615-20.
- <sup>10</sup> Payne CR, Jaques P, Kerr IH. Lung folding simulating peripheral pulmonary neoplasm (Blesovsky's syndrome). *Thorax* 1980;**35**:936-40.