

Pulmonary veins in high-altitude residents: a morphometric study

CA WAGENVOORT, N WAGENVOORT

From the Department of Pathology, University of Amsterdam Wilhelmina Gasthuis, Amsterdam

ABSTRACT The thickness of the media of pulmonary veins and arteries was morphometrically assessed in 12 normal adults resident at altitudes over 3000 m and 12 resident at sea level. The pulmonary veins in the latter group were very thin walled. The average thickness of the pulmonary venous media in the group of highlanders was significantly thicker but this appeared to be due to prominent medial hypertrophy in seven individuals, five others having normal or near-normal pulmonary veins. In six of the 12 highlanders bundles of longitudinal smooth muscle cells occurred in the venous intima. There was close correlation between the thickness of the venous and that of the arterial media, suggesting an individual reactivity with a simultaneous response of all pulmonary vascular smooth muscle to high-altitude hypoxia. Hypertrophy of the media of pulmonary veins is likely to be an expression of venoconstriction and narrowing of the venous lumen may be enhanced by the development of longitudinal smooth muscle cells in the intima. Possibly venoconstriction is one of the factors responsible for high-altitude pulmonary oedema.

The effect of hypoxia resulting from low barometric pressures at high altitude on the muscular pulmonary arteries is well known. Many reports have shown that in residents of regions above 3000 m the small pulmonary arteries often show medial hypertrophy with muscularisation of normally non-muscular arterioles, while the larger muscular arteries are hardly or not at all affected.^{1,2,3} Moreover, the development of bundles or layers of longitudinal smooth muscle cells within the intima of these small arteries is a characteristic feature. In fact, these lesions are not limited to high-altitude residents but are also observed in other states of hypoxia such as chronic bronchitis.

The pulmonary veins and venules in similar conditions have received much less attention, although occasional studies⁴ have shown that they are not exempt from the effect of hypoxia. So far pulmonary veins have rarely been subjected to morphometric analysis. One reason is that the thinness of the walls of veins often results in their collapse, producing an irregular circumference in the histological sections that makes measurements unreliable. In the present study we avoided this difficulty by selecting only those pulmonary veins and venules that had a circular or oval cross-section in the histological sections.

The aim of this study was to provide a more reliable evaluation of the pulmonary venous response to hypoxia by comparing lung tissue of high-altitude residents with that of individuals born and living at sea level.

Methods

Lung tissue from 12 high-altitude residents and from 12 living at sea level was used. All were within the age group 20-50 years. All the subjects died from causes unrelated to heart or lung disease, nearly all being accident victims. Heart and lungs at necropsy were normal, except for a varying degree of right ventricular hypertrophy in the high-altitude group.

Of the 12 individuals who had lived at high altitudes, seven were residents of the Andes, six from Peru and one from Bolivia, all living at altitudes of 4000-4800 m. Five had been living in Leadville, Colorado, at an altitude of 3300 m. The sea-level group comprised people who had lived in The Netherlands.

Histological sections, 7 μ m thick, cut from the paraffin-embedded blocks of lung tissue, were stained by haematoxylin and eosin and Lawson's elastic-van-Gieson stain. We used collapsed lung tissue without attempting to inflate the lungs or to inject the blood vessels, to avoid differences between high-altitude and sea-level groups that could be attributed to artefact.

All pulmonary veins and venules within the histological sections stained for elastin were screened but we included in the morphometric analysis only those veins and venules that could clearly be identified as such because of their structure and localisation. Only the veins and venules which had a round or oval circumference within the histological section were included. From each upper and lower lobe of one lung, usually the left, 25 veins

Address for correspondence: Professor CA Wagenvoort, Department of Pathology, Academisch Ziekenhuis, Eerste Helmersstraat 104, 1054 EG Amsterdam, The Netherlands.

meeting these requirements were measured, so that 50 veins were used in each lung.

We measured the thickness of the media on either side of the artery, using the average of the two values as the medial thickness. The latter value was expressed as a percentage of the external vascular diameter.

Although our primary concern was with the veins, we decided to measure the pulmonary arteries and arterioles as well, to see whether a pulmonary venous response was parallel to an arterial response. In each case 50 arteries, 25 from the upper and 25 from the lower lobe, were measured in the same way as the veins.

Results

The results of the morphometric analysis of the pulmonary veins are shown in the table. In the sea-level group the media was thin and the average medial thickness (2.6%) showed little variation, with a range from 2.1% to 3.1% of the external diameter. There were no differences between veins in the upper and lower lobes. There was a very slight but constant increase in medial thickness with age (fig 1). By the use of linear regression, a straight line was fitted relating the medial thickness of the veins in the total lung (*v*) to the age of the individuals (*a*), giving the equation $v = 0.024 a + 1.74$; the correlation coefficient $r = 0.81$ ($p < 0.01$). The regression coefficient (0.024) differs from zero at the 1% level of significance (Student's *t* test). Minimal-to-mild intimal fibrosis was occasionally present in pulmonary veins, particularly in the older individuals, but longitudinal smooth muscle bundles or layers were never observed. The pulmonary arteries in the sea-level group were thin walled. The average medial thickness was 4.7% of the external arterial diameter, with a range from 3.6% to 5.5%. The intima was normal except for mild intimal fibrosis in some individuals between 30 and 50 years of age.

Mean medial thickness of pulmonary veins and muscular pulmonary arteries in residents of sea-level and high-altitude regions

Subject No	Sex	Age	Pulmonary veins			Muscular pulmonary arteries	
			Upper lobe	lower lobe	total lung		
<i>Sea-level</i>							
1	M	20	2.1	2.7	2.3	5.2	
2	M	24	2.2	2.5	2.3	4.2	
3	M	26	2.5	2.5	2.5	4.5	
4	M	28	2.4	2.6	2.5	5.5	
5	F	30	2.3	2.0	2.1	5.3	
6	F	33	2.7	2.2	2.4	3.6	
7	M	37	2.9	2.6	2.7	4.9	
8	F	41	2.4	2.8	2.6	5.2	
9	M	43	2.9	3.3	3.1	4.6	
10	F	46	2.8	2.7	2.8	4.1	
11	M	49	2.8	3.1	3.0	3.8	
12	M	50	2.9	2.8	2.8	5.0	
Mean (± SD)			2.6 ± 0.1	2.6 ± 0.1	2.6 ± 0.1	4.7 ± 0.4	
<i>High-altitude*</i>							
1	F	21	2.6	2.3	2.4	3.6	a
2	M	21	4.8	6.5	5.7	9.8	a
3	M	25	4.3	4.6	4.5	6.9	b
4	M	29	3.0	3.3	3.2	5.6	c
5	M	35	5.6	4.4	5.0	8.4	a
6	M	38	2.9	3.3	3.2	8.6	c
7	M	40	4.3	4.9	4.6	6.8	a
8	M	42	2.3	2.3	2.3	4.3	c
9	F	42	4.1	3.8	3.9	5.3	c
10	F	48	3.4	3.3	3.3	4.2	c
11	M	49	4.3	4.2	4.3	5.7	a
12	M	50	4.1	4.1	4.1	6.8	c
Mean (± SD)			3.8 ± 0.9	3.9 ± 1.2	3.9 ± 1.0	6.3 ± 1.9	

*The highlanders were from Leadville, Colorado (a), and the Andes of Bolivia (b) and Peru (c).

In the high-altitude group the pulmonary venous media showed a much greater variation in thickness than in the sea-level residents. In two of the 12 the media was very thin and entirely within the normal range (2.3% and 2.4%) and in three others it was slightly thickened

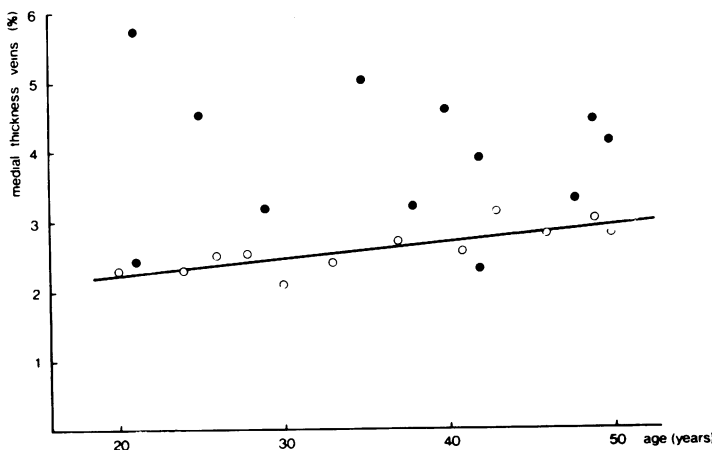


Fig 1 Medial thickness of pulmonary veins, expressed as percentage of external diameter, plotted against age in 12 normal residents of high-altitude regions (●) and 12 normal sea-level residents (○).

(3.2–3.3%) but in seven cases there was prominent pulmonary venous medial hypertrophy (3.9–5.7%). This was associated with arterialisations of the vein, its wall having acquired an internal and external elastic lamina as in a muscular pulmonary artery (fig 2).

According to Wilcoxon's test for two independent samples, the difference between the mean medial thicknesses of the high-altitude group (3.9%) and the sea-level group (2.6%) was statistically significant ($p < 0.002$). This difference, however, depends on only seven of the high-altitude individuals (fig 1). There was no difference between the medial thicknesses of the veins in the upper and the lower lobes.

Some intimal fibrosis was present, particularly in the older individuals. In six of the high-altitude group longitudinal smooth muscle bundles or layers were observed in the venous intima (fig 3). These bundles occurred particularly in veins of a diameter below $150 \mu\text{m}$ and sometimes resulted in narrowing of the venous lumen. Their occurrence was unrelated to age.

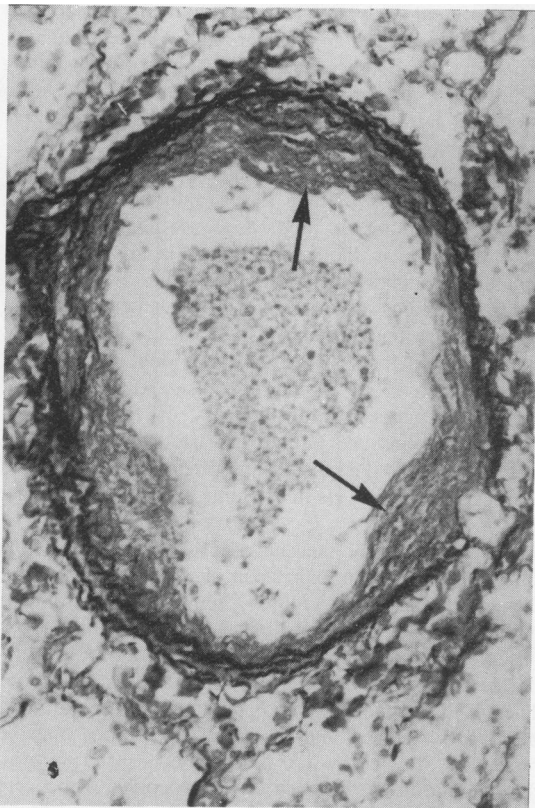


Fig 2 Pulmonary vein in a boy aged 16 years from a high-altitude region, showing medial hypertrophy with arterialisations: some bundles of longitudinal smooth muscle cells (arrows) lie within a mildly fibrotic intima. (Elastic-van Gieson, $\times 200$.)

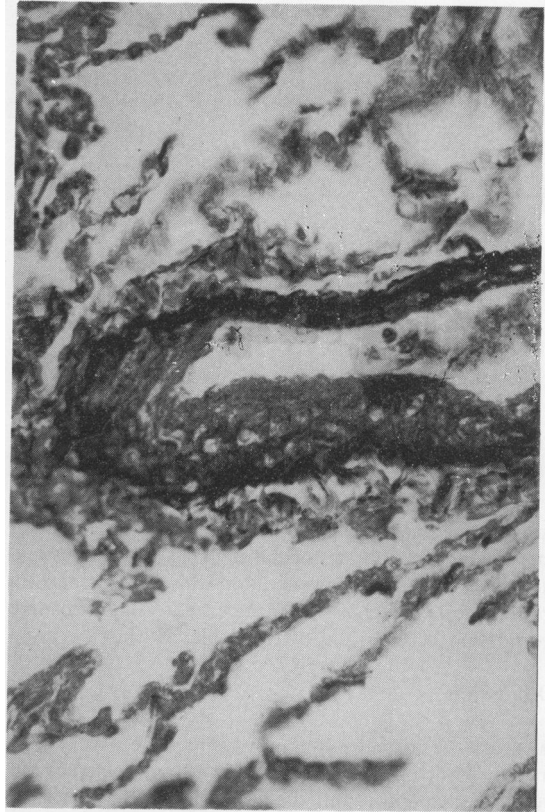


Fig 3 Pulmonary venule in a man aged 50 years from a high-altitude region: bundles of longitudinal smooth muscle cells have caused narrowing of the lumen. (Elastic-van Gieson, $\times 400$.)

In six of the high-altitude group the medial thickness of the pulmonary arteries was greater than in the sea-level group, ranging from 6.8% to 9.8%. This was particularly apparent in small arteries with a diameter of $100 \mu\text{m}$ or less. In addition, there was muscularisation of normally non-muscular arterioles. The larger muscular arteries were usually normal. By contrast, in six other cases the average medial thickness was roughly within normal limits (3.6–5.7%). Despite this, the mean arterial medial thickness for the whole group (6.3%) was distinctly greater than that of the sea-level group (4.7%). According to Wilcoxon's test for two independent samples, this difference is statistically significant ($p < 0.015$).

When we compared the thickness of the venous media and that of the arterial media in individual cases, there appeared to be a correlation between the two values. In fig 4 we have plotted the medial thickness of both veins and arteries, though on different scales to make the results comparable. This figure shows that there is wide variation in the reaction to high-altitude hypoxia, and that if there is a positive reaction it occurs simultaneously and generally

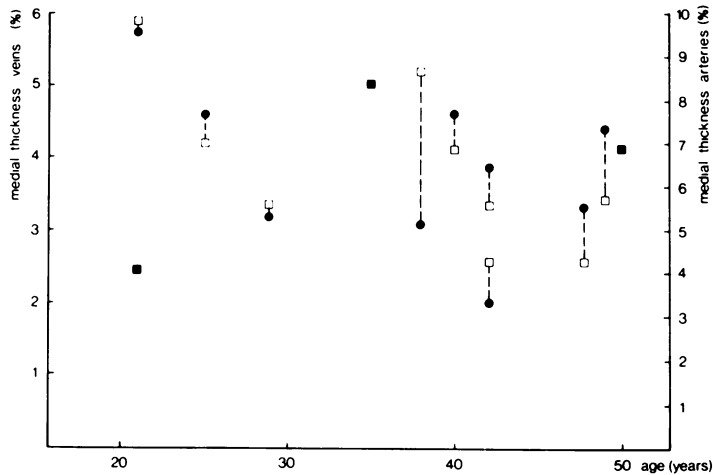


Fig 4 Medial thickness, expressed as percentage of external diameter, of pulmonary veins (●) and pulmonary arteries (□) plotted against age in 12 normal high-altitude residents (overlap of the two symbols indicated by ■). Different scales for veins and arteries have been used for better comparison.

to the same extent in veins and arteries. The correlation coefficient between the medial thicknesses of veins and arteries is 0.76. For 12 observations this is different from zero at the 1% level of significance, indicating a positive correlation between the two variables (Fisher's *z* test).

Discussion

At sea level normal pulmonary veins have a very thin media. While no differences could be shown between the veins in the upper and the lower lobes, there was a significant though slight increase in their medial thickness with age.

Hypoxia produces vasoconstriction and subsequently medial hypertrophy in small muscular pulmonary arteries as well as the development of bundles of longitudinal smooth muscle in their intima. These changes may occur in any state of hypoxia—for instance, in patients with chronic bronchitis, the Pickwickian syndrome, or kyphoscoliosis as well as in otherwise normal individuals who experience the hypoxia of high altitudes.^{1,2,5}

Clearly there is individual variation in the extent of the reaction of the pulmonary vascular bed to high-altitude hypoxia. This applies to cattle⁶ as well as to people.⁷ In an earlier study² we found that some highlanders had an increased medial thickness in their pulmonary arteries, while others had normal arteries.

Haemodynamic studies in cattle have suggested that hypoxia may also cause constriction of pulmonary veins.⁸ Naeye⁹ reported an increase in smooth muscle in the media of pulmonary veins of cattle at high altitude. Dingemans and Wagenvoort¹⁰ reported very prominent changes not only in pulmonary arteries but also in pulmonary veins in rats exposed to hypoxia. We observed not only medial hypertrophy but also longitudinal smooth muscle bundles in the intima of pulmonary veins in patients suffering from chronic bronchitis and

emphysema or Pickwickian syndrome as well as in individuals from high-altitude regions.⁴

Our present study, in which morphometry was applied to pulmonary veins of highlanders and sea-level residents, shows that the average medial thickness of the veins is significantly greater in the former group. The medial thickness, however, varies greatly: in some cases it is greatly increased but in others it is within normal limits. This may explain why Heath and associates¹¹ found no venous alterations in their cases, although evaluation without morphometric methods is not reliable. Intimal smooth muscle in the intima, found in six cases, was generally associated with a thick media.

These findings support the assumption that pulmonary venous constriction occurs in response to high-altitude hypoxia as well as indicating individual variation in reactivity. Here we would emphasise the significant correlation between the thickness of the media in pulmonary veins and pulmonary arteries in individual cases: apparently the vascular smooth muscle of veins and arteries generally reacts in the same way and to the same extent.

If we may assume that increase of pulmonary venous smooth muscle is an expression of venous constriction, then our results may throw light on high-altitude pulmonary oedema. The pathogenesis of this condition is obscure, and probably various factors contribute to its development.^{12,13} One factor is almost certainly genetic. There is individual variation in proneness to high-altitude pulmonary oedema and the same individuals may be repeatedly affected by it.¹² Most patients suffering from this condition have been young people who were otherwise healthy.

It is tempting to suggest that our findings of a concomitant increase of medial smooth muscle in veins and arteries may be associated with such an individual hyperreactivity of lung vessels, since in some cases the

medial thickness of the vessels is appreciably increased while in others it is entirely within normal limits.

The suggestion that venoconstriction may be found among the factors concerned in the mechanism of high-altitude pulmonary oedema has been proposed before.¹⁴ It usually has been dismissed, however, because the wedge pressure in high-altitude pulmonary hypertension is normal.^{15,16} These patients, however, were generally given oxygen or transported to lower altitudes before cardiac catheterisation was performed, and this may have produced dilatation of previously constricted vessels. Moreover, in pulmonary veno-occlusive disease the wedge pressure is often normal, although there is little doubt that the small pulmonary veins are narrowed.

If narrowing or obstruction of small pulmonary veins by constriction or by contraction of longitudinal smooth muscle bundles plays a part in the origin of high-altitude pulmonary oedema, we might expect that those individuals with a greater-than-normal amount of smooth muscle in their veins would be particularly susceptible. The extremely thin pulmonary venous media of most people living at sea level is unlikely to react vigorously to hypoxia soon after arrival at high altitude. Perhaps significantly, high-altitude pulmonary oedema occurs particularly frequently in highland residents who spend some time at sea level and then return to their mountainous homeland. They could well have temporarily lost their acclimatisation while still retaining their excess pulmonary venous muscle.

We are grateful to Professor J Arias-Stella of Lima, Peru; Dr G Saccomanno of Grand Junction, Colorado, USA; and Dr E Valdivia of Madison, Wisconsin, USA, for making lung tissue from high-altitude residents available to us. We also thank Professor J Strackee of Amsterdam for his help with the statistical evaluation.

References

- ¹ Arias-Stella J, Saldana M. The terminal portion of the pulmonary arterial tree in people native to high altitudes. *Circulation* 1963;**28**:915–25.
- ² Wagenvoort CA, Wagenvoort N. Hypoxic pulmonary vascular lesions in man at high altitude and in patients with chronic respiratory disease. *Pathol Microbiol* 1973;**39**:276–82.
- ³ Heath D, Williams DR. *Man at high altitude*. Edinburgh: Churchill Livingstone, 1977:80.
- ⁴ Wagenvoort CA, Wagenvoort N. Pulmonary venous changes in chronic hypoxia. *Virchows Arch A* 1976;**372**:51–6.
- ⁵ Hasleton PS, Heath D, Brewer DB. Hypertensive pulmonary vascular disease in states of chronic hypoxia. *J Pathol Bacteriol* 1968;**95**:431–40.
- ⁶ Weir, EK, Tucker A, Reeves JT, Will DH, Grover RF. The genetic factor influencing pulmonary hypertension in cattle at high altitude. *Cardiovasc Res* 1974;**8**:745–9.
- ⁷ Grover RF. Pulmonary circulation in animals and man at high altitude. *Ann N Y Acad Sci* 1965;**127**:632–4.
- ⁸ Kuida H, Tsagaris TJ, Hecht HH. Evidence for pulmonary venoconstriction in brisket disease. *Circ Res* 1963;**12**:182–9.
- ⁹ Naeye RL. Pulmonary vascular changes with chronic unilateral pulmonary hypoxia. *Circ Res* 1965;**17**:160–7.
- ¹⁰ Dingemans KP, Wagenvoort CA. Pulmonary arteries and veins in experimental hypoxia. An ultrastructural study. *Am J Pathol* 1978;**93**:353–68.
- ¹¹ Heath D, Smith P, Rios Dalenz J, Williams D, Harris P. Small pulmonary arteries in some natives in La Paz, Bolivia. *Thorax* 1981;**36**:599–604.
- ¹² Hultgren HN, Spickard WB, Hellriegel J, Houston CS. High altitude pulmonary edema. *Medicine* 1961;**40**:289–313.
- ¹³ Reeves JT, Grover RF. High-altitude pulmonary hypertension and pulmonary edema. In: *Progress in cardiology*. Philadelphia: Lea and Febiger, 1975:99–118.
- ¹⁴ Fred HL, Schmidt AM, Bates T, Hecht HH. Acute pulmonary edema of altitude. Clinical and physiologic observations. *Circulation* 1962;**25**:929–37.
- ¹⁵ Penalzoza D, Sime F. Circulatory dynamics during high altitude pulmonary edema. *Am J Cardiol* 1969;**23**:369–77.
- ¹⁶ Roy SB, Guleria JS, Khanna PK, Manchanda SC, Pande JN, Subba PS. Haemodynamic studies in high altitude pulmonary oedema. *Br Heart J* 1969;**31**:52–8.