

RESEARCH ARTICLE

Open Access



Outcomes of total hip arthroplasty in patients with primary immune thrombocytopenia

Seung-Jae Lim[†], Ingwon Yeo[†], Chan-Woo Park, Young-Wan Moon and Youn-Soo Park^{*}

Abstract

Background: Immune thrombocytopenia (ITP) is an immune-mediated acquired disease that is characterized by a decrease in the platelet count and an increased risk of bleeding. There is little information in the literature about the results of major joint replacement surgery in patients with ITP. The aim of this study was to report on the results of total hip arthroplasty (THA) in patients with primary ITP.

Methods: We retrospectively identified 15 THAs performed in 11 patients with primary ITP. The study group was matched (1:2) to a non-ITP control group of 30 THAs in 22 patients. According to the perioperative hematologic evaluation, blood management interventions were performed. All procedures were performed by a single surgeon and all patients received cementless components with ceramic-on-ceramic bearing. Mean duration of follow-up was 7.1 years (range, 2–13).

Results: No significant differences were found between the two groups with regard to mean operative time, intraoperative blood loss, amount of closed suction drainage, length of hospital stay, and readmission rate. However, the proportion of patients requiring transfusion of packed red blood cells and/or platelet concentrate was higher in the ITP group when compared to the non-ITP group. Mean Harris hip score improved from 49.5 points preoperatively to 93.4 points at the final follow-up and no hips were revised for loosening or osteolysis in the ITP group. No significant differences were found between the two groups with respect to mean postoperative Harris hip scores and complication rates.

Conclusions: Our study showed encouraging clinical and radiographic results of THA in patients with ITP without increased risk of adverse events compared to those in patients without ITP. On the basis of these findings, we suggest that modern cementless THA might be a viable treatment for achieving functional improvement in patients with ITP and end-stage hip disease.

Keywords: Total hip arthroplasty, Immune thrombocytopenia, Transfusion, Outcomes

Background

Immune thrombocytopenia (ITP) is an immune-mediated acquired disease characterized by a transient or persistent decrease in platelet count and an increased risk of bleeding [1–3]. According to the International Working Group (IWG) criteria, primary ITP is defined as an autoimmune disorder characterized by isolated thrombocytopenia (peripheral blood platelet count of

$<100 \times 10^9/L$) in the absence of other causes or disorders that might be associated with thrombocytopenia [1]. Corticosteroids are widely accepted as the most appropriate first-line treatment for ITP patients [2, 3], and in such patients, the prevalence of steroid-induced avascular necrosis lies between 9 % and 40 % with the femoral head being the most commonly affected site [4]. Furthermore, the prevalence of osteoarthritis of the hip is increasing [5, 6], and thus, the number of elderly ITP patients requiring total hip arthroplasty (THA) can be expected to rise.

* Correspondence: ysp3504@skku.edu

[†]Equal contributors

Department of Orthopedic Surgery, Samsung Medical Center, Sungkyunkwan University School of Medicine, 81 Irwon-ro, Gangnam-gu, Seoul 135-710, South Korea

Patients with ITP undergoing surgery are at increased risk of adverse perioperative events, particularly if blood or blood product transfusions are required preoperatively, or if the surgical procedure is performed on an emergency basis [7]. Furthermore, because greater perioperative blood loss may be expected in patients with ITP undergoing THA, and because of the additional risk of periprosthetic infection, special medical management is required to minimize complications in patients with ITP undergoing THA. However, little information is available in the literature concerning the results of major joint replacement surgery in patients with ITP, being limited to isolated English and non-English language case reports [8–10]. Accordingly, questions remain as to whether patients with ITP can safely undergo THA, as these patients may be at increased risk of surgical complications and mortality [7, 11].

Therefore, the primary aim of this study was to report on the clinical and radiographic outcomes of THA in patients with primary ITP, and the secondary aim was to determine whether patients with and without ITP differ with respect to early postoperative outcomes, Harris hip scores, and radiographic results.

Methods

We retrospectively reviewed the medical records of 11 consecutive patients with primary ITP who underwent 15 cementless THAs between 2001 and 2011 at our institution. Primary ITP was diagnosed according to the IWG criteria [1] after thorough hematologic evaluation, including consultation with a hematologist. All THA candidates underwent complete blood count screening. In patients with a low platelet count ($<100 \times 10^9/L$) the following investigations were performed: reticulocyte counts, estimation of red blood cell and thrombocyte indices, bone marrow cytology (if thrombocytopenia had persisted for >6 months), thyroid stimulating hormone (TSH), aspartate aminotransferase (AST), alanine aminotransferase (ALT), gamma-glutamyl transpeptidase (GGT), creatinine, blood urea nitrogen (BUN), lactate dehydrogenase (LDH), bilirubin, Coombs test, antiphospholipid antibodies, immunoglobulin subclass analysis, von Willebrand antigen and ristocetin cofactor, and serologic tests for hepatitis B and C, human immunodeficiency virus (HIV), Epstein-Barr virus (EBV), and cytomegalovirus (CMV). Two of the eleven patients were diagnosed with ITP as a result of the preoperative hematologic evaluation. The other nine had already been diagnosed with chronic ITP and had been previously managed by a hematologist. None of the patients with ITP were lost to follow-up, and all were included in this study. This study protocol was approved by the Review Board of Samsung Medical Center. Written informed consent for participation in the study was obtained from all patients.

Of the 11 patients (15 hips), 2 (2 hips) were male and 9 (13 hips) were female and they had an overall mean age of 49.3 years (range, 35–68 years) at the time of THA. The mean time elapsed between ITP diagnosis and surgery was 4.3 years (range, 0–13 years), and mean body mass index (BMI) was 24.2 kg/m^2 (range, $17.2\text{--}28.6 \text{ kg/m}^2$). Twelve hips (8 patients) were replaced because of osteonecrosis of the femoral head, and 3 hips (3 patients) were replaced because of osteoarthritis. The mean American Society of Anesthesiologists (ASA) score was 1.7 (range, 1–3), and mean follow-up was 7.1 years (range, 2–13 years).

The 11 patients with ITP (15 hips) were matched (1:2) with 22 patients without ITP (30 hips) with respect to: patient age (± 1 year), sex, preoperative diagnosis (osteonecrosis or osteoarthritis), and operating surgeon. Demographic data of the ITP and non-ITP groups are summarized in Table 1. No significant differences were evident between the two groups with respect to age, sex, BMI, etiology of THA, ASA scores, type of anesthesia, or follow-up period ($p > 0.05$ for all).

In the ITP group, preoperative mean serum hemoglobin was 11.7 g/dL (range, $7.7\text{--}15.1 \text{ g/dL}$) and mean platelet count was $92.7 \times 10^9/L$ (range, $34 \times 10^9/L\text{--}149 \times 10^9/L$). At time of surgery, mean platelet count was more than $100 \times 10^9/L$ in 4 patients (5 hips) and less than this in 7 patients (10 hips). Packed red blood cells (pRBCs), platelet concentrate (PC), and intravenous immunoglobulin (IVIG) were transfused preoperatively based on the results of hematological studies and hematologic consultations (Table 2). During the study period, we used the same transfusion thresholds for both pRBCs and PC and/or IVIG. A hemoglobin level of 8 g/dL was the transfusion threshold for pRBCs [12, 13]. A platelet count of less than $80 \times 10^9/L$ was the threshold for PC transfusion and/or IVIG administration [14]. In the non-ITP control group, mean preoperative serum hemoglobin was 12.6 g/dL (range, $10.9\text{--}15.6 \text{ g/dL}$) and mean platelet count was $286 \times 10^9/L$ (range, $111 \times 10^9/L\text{--}357 \times 10^9/L$). No patient in the non-ITP group required a blood transfusion preoperatively. No significant difference was found between the two groups in preoperative serum hemoglobin level ($p = 0.211$), but preoperative platelet count was significantly lower in the ITP group ($p = 0.001$) than that in the non-ITP group.

Operative treatment

All the operations were performed by a single surgeon in the lateral position through an anterolateral approach. Cementless components were used in all hips in both groups. In the ITP group, the acetabular components used were as follows; Bencox[®] cups (Corentec, Seoul, Korea; $n = 7$), Duraloc[®] Option cups (DePuy/J&J, Warsaw, IN, USA; $n = 6$), and SPH[®] Contact cups (Lima, Udine, Italy;

Table 1 Demographics of the ITP and non-ITP groups

	ITP Group	Non-ITP Group	<i>p</i> value
Number of patients (hips)	11 (15)	22 (30)	
Mean age (years)	49.3 (35–68)	49.0 (35–68)	0.317
Sex (male/female)	2/13	4/26	1.000
Mean body mass index (kg/m ²)	24.2 (17.2–28.6)	24.7 (18.9–31.3)	0.460
Etiology			1.000
Osteonecrosis	12	24	
Osteoarthritis	3	6	
Mean ASA score	1.7 (1–3)	1.4 (1–3)	0.160
Type of anesthesia			0.331
General	7	9	
Spinal	8	21	
Mean duration of follow-up (years)	7.1 (2–13)	7.2 (2–13)	0.285

ITP immune thrombocytopenia, ASA American Society of Anesthesiologists

n = 2). The femoral components used were Bencox[®] stems (Corentec, Seoul, Korea; *n* = 7), S-ROM[®] stems (DePuy/J&J, Warsaw, IN, USA; *n* = 6), and C2[®] stems (Lima, Udin, Italy; *n* = 2). In all 22 hips, an alumina ceramic head and liner (Bilox[®] Forte, CeramTec AG, Plochingen, Germany; *n* = 11 and BioloX[®] Delta, CeramTec AG, Plochingen, Germany; *n* = 4) were used (Fig. 1). Twenty-eight millimeter heads were used in 10 hips, 32 mm in 4 hips, and 36 mm in 1 hip. In the non-ITP group, the acetabular components used were as follows; Bencox[®] cups (Corentec, Seoul, Korea; *n* = 9), Duraloc[®] Option cups (DePuy/J&J, Warsaw, IN, USA; *n* = 17),

and SPH[®] Contact cups (Lima, Udin, Italy; *n* = 4). The femoral components used were Bencox[®] stems (Corentec, Seoul, Korea; *n* = 9), S-ROM[®] stems (DePuy/J&J, Warsaw, IN, USA; *n* = 17), and C2[®] stems (Lima, Udin, Italy; *n* = 4). In all 30 hips, an alumina ceramic head and liner (BioloX[®] Forte, CeramTec AG, Plochingen, Germany; *n* = 21 and BioloX[®] Delta, CeramTec AG, Plochingen, Germany; *n* = 9) were used. Twenty-eight millimeter heads were used in 18 hips, 32 mm in 11 hips, and 36 mm in 1 hip. Intra-operative blood loss was estimated by measuring the volume of blood in the suction bottle, by weighing mops and gauze pieces used during surgery, and by visual

Table 2 Perioperative Transfusions in the ITP Group

Case	Diagnosis	ASA	PLT (x10 ⁹ /l)	Hb (g/dL)	Preoperative transfusion (units)	Postoperative transfusion (units)
1	ON	1	83	10.5	-	PC, 4, pRBC 2
2	ON	2	98	11.3	-	PC 6, pRBC 2
3	ON	3	52	7.7	PC 6, pRBC 2	PC 6, pRBC 4
4	OA	1	72	13.4	PC 8	-
5	OA	2	65	10.9	IVIG	PC 8, pRBC 2
6	OA	2	71	13.4	PC 15	
7	ON	3	55	11.7	IVIG, PC 12	
8	ON	2	99	13.1	-	pRBC 2
9	ON	2	131	14.1	-	PC 8
10	ON	1	131	15.1	-	-
11	ON	2	61	12.7	IVIG, PC 8	pRBC 2
12	ON	1	34	11.8	IVIG, PC 12	PC 8, pRBC 3
13	ON	2	143	9.4	-	
14	ON	1	149	10.0	-	pRBC 2
15	ON	1	146	10.8	-	-
Mean		1.7	92.7	11.7	-	-

ASA American Society of Anesthesiologists, PLT platelet, Hb haemoglobin, ON osteonecrosis, OA osteoarthritis, PC platelet concentrate, pRBC packed red blood cell, IVIG intravenous immunoglobulin

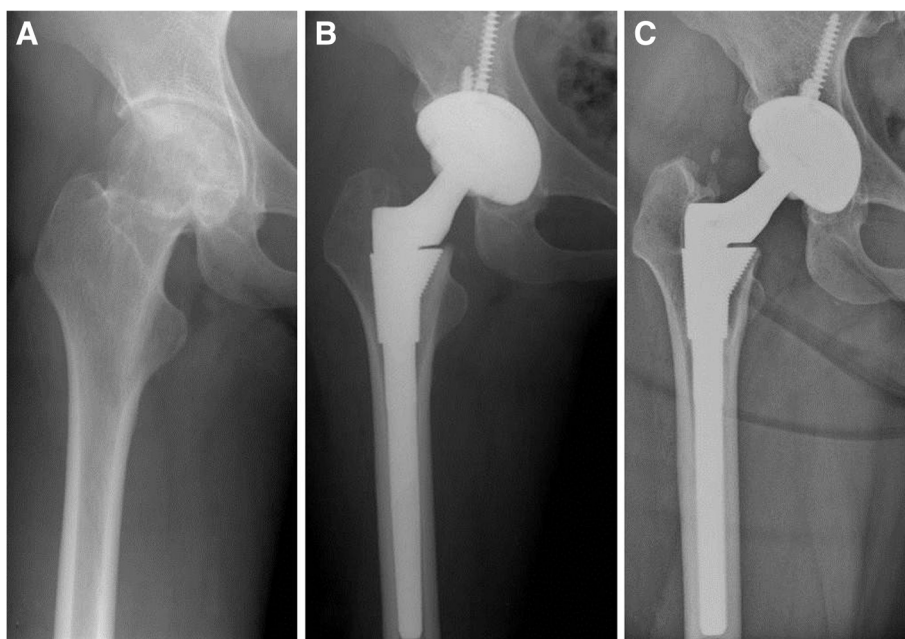


Fig. 1 **a** Pre-operative radiograph showed osteonecrosis of the femoral head in patient with primary immune thrombocytopenia. **b** Preoperative transfusions of six units of platelet concentrate and two units of packed red blood cells were performed. Postoperatively, six units of platelet concentrates and four units of packed red blood cells were transfused. Post-operative radiograph of cementless total hip arthroplasty performed with ceramic-on-ceramic bearing. **c** Twelve-year follow-up radiograph showed a well-fixed prosthesis with no osteolysis

estimation of loss in the operative field. Hemostatic agents such as tranexamic acid or fibrin sealant were not used during the study period. Closed suction drains were routinely used in all patients.

Postoperative treatment

Both groups received the same postoperative management, except that routine hematological tests were performed more frequently in the ITP group. Drains were removed 48 h after the operation and the drainage volume was recorded as the post-operative blood loss. Mechanical compression devices alone were used for deep vein thrombosis (DVT) prophylaxis in both groups without additional pharmacological thromboprophylaxis because the prevalence of venous thromboembolism in Korean patients without chemoprophylaxis had been reported to be low at that time [15]. Antibiotic prophylaxis was administered to all patients starting 1 hour before surgery, continuing until 3 days after surgery. Postoperatively, hematological studies were performed in all patients until hemoglobin and platelet levels reached and remained at or above preoperative levels. Transfusions were performed based on the results of hematological studies and amounts of blood collected via suction drains. The transfusion thresholds were hemoglobin levels of 8 g/dL for pRBCs, and platelet count of $80 \times 10^9/L$ for PC for the entire postoperative period. All patients received the same postoperative rehabilitation.

All were allowed to stand on the second or third post-operative day and to progress to partial weight bearing with crutches as tolerated. Patients were allowed full weight-bearing after 4 to 6 weeks.

Assessments

A single independent observer, who had not participated in the operations, retrieved the following clinical data by reviewing archived records: operative times, intraoperative estimated blood losses, closed suction drainage amounts, postoperative blood product transfusions (pRBC and PC), durations of hospital stay, readmission rates, and complications. All patients were examined clinically at latest follow-up visits. Harris hip scores [16] were used to assess pain levels and function. Radiographic assessments were performed immediately after surgery, and then at 6 weeks, 3 and 6 months, and at 1 year postoperatively, and then at 1 year or 2 year intervals until final follow-up visits. Radiographic evaluations were performed by the same independent observer. The 6 week postoperative radiographs were used as references for radiographic evaluations of component stability, wear, osteolysis, and loosening [17]. The stability of fixation of femoral and acetabular components were classified as previously described [18, 19].

Statistical analysis

Statistical analyses were performed using IBM SPSS Statistics version 22.0 (IBM Corp., Somers, NY, USA). The

paired t test or the Wilcoxon matched pairs test was used to analyze continuous variables, and McNemar's chi square test was used to analyze dichotomous values. Statistical significance was accepted for p values < 0.05.

Results

No significant differences were found between the ITP and non-ITP groups with respect to mean operative time, intraoperative estimated blood loss, closed suction drainage amount, duration of hospital stay, or readmission rates ($p > 0.05$ for all). However, the two groups differed in terms of postoperative blood management interventions. The pRBC transfusion rate was higher in the ITP group ($p = 0.003$), and the PC transfusion rate and total number of units of PC transfused were higher in the ITP group ($p = 0.001$ for both). On the other hand, the total number of units of pRBC transfused were not significantly different between the two groups ($p = 0.054$),

In the ITP group, the mean Harris hip score improved from 49.5 points (range, 37–61 points) to 93.4 points (range, 90–100 points) at final follow-up. No significant intergroup differences in postoperative Harris hip scores were seen between groups ($p = 0.163$). In the ITP group, no femoral or acetabular component showed radiographic evidence of mechanical loosening, and no component had been revised at final follow-up. Furthermore, no osteolysis was observed, and no significant differences were found

between the two groups with respect to component stability, osteolysis, or revision ($p = 1.000$ for all).

In the ITP group, no hip developed wound complications, deep infection or symptomatic venous thromboembolism during follow-up, and no death occurred. Furthermore, no ceramic fracture or squeaking was encountered. Complication rates were identical in the two groups ($p = 1.000$).

Clinical and radiographic outcome data for both groups are summarized in Table 3.

Discussion

Several previous studies demonstrated significantly higher overall complication rates after a range of procedures among patients with ITP, who were found to have considerably higher risks of acute renal failure, postoperative bleeding, septicemia, and pneumonia [7, 11]. Thus, at the onset of this study, we postulated that major joint replacement surgery in patients with ITP might be associated with higher risks of perioperative bleeding, wound complications or periprosthetic infection. However, only limited information was available about the outcomes of major orthopedic surgery in patients with ITP [8–10]. Nezu et al. described the case of a 42-year-old with refractory ITP who underwent hip replacement under the cover of vinca alkaloids and colchicine after their platelet count was not sufficiently elevated by first or second line therapy

Table 3 Outcome data of the ITP and non-ITP groups

	ITP Group (N = 15)	Non-ITP Group (N = 30)	p value
Mean operative time (minutes)	68.8 (49–104)	61.3 (43–104)	0.550
Mean intraoperative estimated blood loss (mL)	401 (100–1030)	375 (200–850)	0.115
Mean amount of suction drainage (mL)	526 (150–1040)	545 (220–980)	0.394
Number of patients transfused postoperatively			
pRBC (%)	8 (53.3)	4 (13.3)	0.003
PC (%)	6 (40.0)	0 (0.0)	0.001
Mean number of units transfused postoperatively			
pRBC	1.27 (0–4)	0.35 (0–4)	0.054
PC	2.67 (0–8)	0	0.001
Mean length of hospital stay (days)	9.5 (7–14)	9.2 (7–14)	0.445
Readmission rate (%)	0	0	1.000
Mean postoperative Harris hip score (points)	93.4 (90–100)	94.9 (92–100)	0.163
Number of patients experiencing post-operative complications			
Component loosening	0	0	1.000
Osteolysis	0	0	1.000
Wound hematoma	0	0	1.000
Wound infection	0	0	1.000
Deep infection	0	0	1.000
Venous thromboembolism	0	0	1.000
Death	0	0	1.000

ITP immune thrombocytopenia, pRBC packed red blood cells, PC platelet concentrate

[8]. Kim et al. described a series of five patients who underwent total hip replacement for osteonecrosis of femoral head associated with underlying ITP [9]. Singhal et al. report the case of a 61-year-old with refractory ITP who underwent total knee replacement [10]. However, no case-control studies have been reported to date concerning on patients with ITP who have undergone THA, and no specific guidelines have been issued regarding the perioperative management of such patients. Therefore, in the present study, we retrospectively analyzed the clinical and radiographic results of THA in this patient population. In particular, we analyzed operative times, intraoperative estimated blood losses, closed suction drainage amounts, postoperative blood product transfusions, hospital stay durations, re-admission rates, and complications.

Most reports of the surgical treatment of patients with ITP describe their management in the context of abdominal surgery [11], which is generally characterized by excellent intra-operative hemostasis. However, during THA, difficult to control intraoperative and postoperative bone bleeding is inevitable, and greater perioperative blood loss can be expected. Nevertheless, in the present study, perioperative blood losses, as determined by intraoperative estimated blood losses and closed suction drainage amounts, were not significantly different in the ITP and non-ITP groups. We believe that this favorable outcome might have resulted from relatively short operative times and thorough perioperative blood management interventions. All patients with ITP received preoperative transfusions/IVIg treatment if found to be at high bleeding risk. The transfusion threshold for pRBCs was a hemoglobin level of 8 g/dL, and for PC transfusion and/or IVIg administration was a platelet count of $80 \times 10^9/L$ over the entire perioperative period. Furthermore, we used mechanical compression devices only alone for DVT prophylaxis, without additional pharmacological thromboprophylaxis. These blood management strategies were associated with excellent immediate postoperative clinical courses and hospital stays similar to those observed in the control group. However, an updated meta-analysis of randomized trials showed that a restrictive transfusion strategy using a hemoglobin transfusion trigger of < 7 g/dL results in a significant reduction in acute coronary syndrome, pulmonary edema, rebleeding, infections, and total mortality, compared with a more liberal strategy [20]. Thus, if more restrictive transfusion strategies had been used in the present study, some of the patients in both groups might not have needed the transfusions following THA. In addition, new cost-effective blood management tools, such as tranexamic acid or fibrin sealant, could be a promising approach to reduce bleeding and consequently lead to lower transfusion rates after total joint arthroplasty in these patient populations [21, 22].

We found that the mean Harris hip score was 93.4 points (range, 90 to 100 points) at a mean follow-up of 7.1 years (range, 2–13 years) following cementless ceramic-on-ceramic THA in patients with ITP. No abnormal radiographic changes such as loosening or osteolysis were observed at last follow-up, and no component required revision. The excellent clinical and radiographic outcomes achieved in the present study might be due to the use of ceramic-on-ceramic articulation combined with modern cementless THA prostheses, which corroborates the findings of recent clinical studies [23, 24].

Several limitations of the present study warrant consideration. First, the study is limited by its retrospective nature and by the small number of patients over a long period of enrollment. These limitations might make it difficult to accurately assess what the outcomes are of this patient population. However, these limitations were unavoidable owing to the rarity of ITP and the consequent low number of patients with this condition who undergo THA. Second, follow-up durations varied widely. While all patients were followed for a minimum of 2 years some were followed for as much as 13 years, and the average follow-up was 7.1 years. Third, the variety of implants used might have acted as a confounding factor. Nevertheless, our study is unique in that it involves a consecutive series of ITP patients treated using modern cementless components in combination with ceramic-on-ceramic bearings by a single surgeon at a single institution. Fourth, contemporary blood management strategies including the use of tranexamic acid or fibrin sealant, and more restrictive blood transfusion strategies were not used during the study period and could further influence the results.

Conclusion

The present study describes encouraging early postoperative outcomes of THA in patients with ITP, with no increase in the risk of adverse events as compared with THA in patients without ITP. In addition, excellent clinical and radiographic results were obtained for all fifteen cementless THAs performed in eleven ITP patients. Based on these findings, we believe that modern cementless THA offers a viable means of achieving functional improvements in patients with ITP and end-stage hip disease without markedly increased perioperative risk. In addition, we hope that our findings provide a reference for surgeons who undertake major surgical interventions in patients with ITP.

Abbreviations

ALT: Alanine aminotransferase; ASA: American society of anesthesiologists; AST: Aspartate aminotransferase; AVN: Avascular necrosis of the femoral head; BUN: Blood urea nitrogen; CMV: Cytomegalovirus; DVT: Deep vein thrombosis; EBV: Epstein-Barr virus; GGT: Gamma-glutamyl transpeptidase;

HIV: Human immunodeficiency virus; Hb: Hemoglobin; ITP: Immune thrombocytopenia; IVIG: Intravenous immunoglobulin; LDH: Lactate dehydrogenase; OA: Osteoarthritis; PC: Platelet concentrate; PLT: Platelet; pRBC: Packed red blood cell; THA: Total hip arthroplasty; TSH: Thyroid stimulating hormone.

Competing interests

The authors declare that they have no competing interests.

Authors' contributions

YSP and YWM carried out in the design of the study and led the co-ordination of the study. SJL and IGY wrote this manuscript and participated in coordination. CWP collected the clinical data. All authors read and approved the final manuscript.

Authors' information

Not applicable.

Acknowledgements

We would like to thank all patients who accepted this clinical follow-up.

Received: 21 January 2015 Accepted: 28 September 2015

Published online: 05 October 2015

References

- Rodeghiero F, Stasi R, Gernsheimer T, Michel M, Provan D, Arnold DM, et al. Standardization of terminology, definitions and outcome criteria in immune thrombocytopenic purpura of adults and children: report from an international working group. *Blood*. 2009;113:2386–93.
- Provan D, Stasi R, Newland AC, Blanchette VS, Bolton-Maggs P, Bussell JB, et al. International consensus report on the investigation and management of primary immune thrombocytopenia. *Blood*. 2009;115:168–86.
- Neuner C, Lim W, Crowther M, Cohen A, Solberg Jr L, Crowther MA, et al. The American Society of Hematology 2011 evidence-based practice guideline for immune thrombocytopenia. *Blood*. 2011;117:4190–207.
- Weinstein RS. Clinical practice: glucocorticoid-induced bone disease. *N Engl J Med*. 2011;365:62–70.
- Ibrahim T, Bloch B, Esler CN, Abrams KR, Harper WM. Temporal trends in primary total hip and knee arthroplasty surgery: results from a UK regional joint register, 1991–2004. *Ann R Coll Surg Engl*. 2010;92:231–5.
- Kurtz SM, Ong KL, Lau E, Bozic KJ. Impact of the economic downturn on total joint replacement demand in the United States: updated projections to 2021. *J Bone Joint Surg Am*. 2014;96:624–30.
- Chang CC, Chang HC, Wu CH, Chang CY, Liao CC, Chen TL. Adverse postoperative outcomes in surgical patients with immune thrombocytopenia. *British J Surg*. 2013;100:684–92.
- Nezu M, Oh H, Cho R, Sato H, Ikegami T, Yokota A, et al. The combination therapy with vinca-alkaloid slow infusion and cholecalciferol was effective to refractory idiopathic thrombocytopenic purpura. The patient could receive femoral head replacement in safety. *Rinsho Ketsueki*. 1996;37(2):158–60.
- Kim YS, Chung JW, Sung BY, Woo YK, Kwon SY. Total hip replacement arthroplasty in patient with idiopathic thrombocytopenic purpura: clinical experience of perioperative management. *J Korean Hip Soc*. 2008;20:15–8.
- Singhal R, Gudimetla V, Stewart A, Luscombe KL, Charalambous CP. Perioperative care of a patient with refractory idiopathic thrombocytopenic purpura undergoing total knee arthroplasty. *Knee Surg Relat Res*. 2012;24:245–8.
- Kojouri K, Vesely SK, Terrell DR, George JN. Splenectomy for adult patients with idiopathic thrombocytopenic purpura: a systematic review to assess long-term platelet count responses, prediction of response, and surgical complications. *Blood*. 2014;104:2623–34.
- Carson JL, Duff A, Berlin JA, Lawrence VA, Poses RM, Huber EC, et al. Perioperative blood transfusion and postoperative mortality. *JAMA*. 1998;279:199–205.
- Foss NB, Kristensen MT, Jensen PS, Palm H, Krashennikoff M, Kehlet H. The effects of liberal versus restrictive transfusion thresholds on ambulation after hip fracture surgery. *Transfusion*. 2009;49:227–34.
- British Committee for Standards in Haematology General Haematology Task Force. Guidelines for the investigation and management of idiopathic thrombocytopenic purpura in adults, children and in pregnancy. *Br J Haematol*. 2003;120:574–96.
- Kim YH, Oh SH, Kim JS. Incidence and natural history of deep-vein thrombosis after total hip arthroplasty. A prospective and randomised clinical study. *J Bone Joint Surg Br*. 2003;85:661–5.
- Harris WH. Traumatic arthritis of the hip after dislocation and acetabular fractures: treatment by mold arthroplasty. An end-result study using a new method of result evaluation. *J Bone and Joint Surg Am*. 1969;51:737–55.
- Martell JM, Pierson 3rd RH, Jacobs JJ, Rosenberg AG, Maley M, Galante JO. Primary total hip reconstruction with a titanium fiber-coated prosthesis inserted without cement. *J Bone Joint Surg Am*. 1993;75:554–71.
- Engh CA, Bobyn JD, Glassman AH. Porous-coated hip replacement. The factors governing bone ingrowth, stress shielding, and clinical results. *J Bone Joint Surg Br*. 1987;69(69):45–55.
- Latimer HA, Lachiewicz PF. Porous-coated acetabular components with screw fixation. Five to ten-year results. *J Bone Joint Surg Am*. 1996;78:975–81.
- Salpeter SR, Buckley JS, Chatterjee S. Impact of more restrictive blood transfusion strategies on clinical outcomes: a meta-analysis and systematic review. *Am J Med*. 2014;127:124–31.
- Ponnusamy KE, Kim TJ, Khanuja HS. Perioperative blood transfusions in orthopaedic surgery. *J Bone Joint Surg Am*. 2014;96:1836–44.
- Randelli F, Banci L, Ragone V, Pavesi M, Randelli G. Effectiveness of fibrin sealant after cementless total hip replacement: a double-blind randomized controlled trial. *Int J Immunopathol Pharmacol*. 2013;26:189–97.
- Petsatodis GE, Papadopoulos PP, Papavasiliou KA, Hatzokos IG, Agathangelidis FG, Christodoulou AG. Primary cementless total hip arthroplasty with an alumina ceramic-on-ceramic bearing: results after a minimum of twenty years of follow-up. *J Bone Joint Surg Am*. 2010;92:639–44.
- Sugano N, Takao M, Sakai T, Nishii T, Miki H, Ohzono K. Eleven- to 14-year follow-up results of cementless total hip arthroplasty using a third-generation alumina ceramic-on-ceramic bearing. *J Arthroplasty*. 2012;27:736–41.

doi:10.1186/s12891-015-0742-8

Cite this article as: Lim et al.: Outcomes of total hip arthroplasty in patients with primary immune thrombocytopenia. *BMC Musculoskeletal Disorders* 2015 **16**.

Submit your next manuscript to BioMed Central and take full advantage of:

- Convenient online submission
- Thorough peer review
- No space constraints or color figure charges
- Immediate publication on acceptance
- Inclusion in PubMed, CAS, Scopus and Google Scholar
- Research which is freely available for redistribution

Submit your manuscript at
www.biomedcentral.com/submit

