

Role of lung scanning in assessing the resectability of bronchial carcinoma

DA ELLIS, T HAWKINS, GJ GIBSON, S NARIMAN

From the Cardiothoracic Centre and Department of Medical Physics, Freeman Hospital, Newcastle upon Tyne

ABSTRACT Ventilation and perfusion lung scans were performed in 58 patients before operation for bronchial carcinoma to determine in which patients the lung scan was most useful for assessing mediastinal spread and resectability of the tumour. Perfusion of the affected lung was less with larger and more centrally situated tumours. Perfusion was also less for left-sided than for right-sided tumours but this is explained by the normal differential perfusion of the right and left lungs. The lung scan was unhelpful in predicting resectability of peripheral tumours, but with central tumours if perfusion of the affected lung was less than 25% of the total perfusion the lesion was likely to be non-resectable because of spread to the mediastinum. Airways obstruction was present in 67% of the patients but did not interfere with the interpretation of the scans. In most cases ventilation scans provided no additional information, and the use of krypton-81m as a sensitive indicator of regional ventilation did not improve on the predictive value of the perfusion scan.

The various radionuclide lung scan appearances in bronchial carcinoma have been reported previously in detail.¹⁻⁵ Tumours with a mean diameter of over 2 cm usually give rise to a defect of perfusion closely matched by a defect of ventilation.⁶ Defects of perfusion may also occur at the site of a tumour which is not visible on the plain chest radiograph.⁶ Defects which are larger than the size of the lesion judged radiographically are said to indicate an increased likelihood of tumour spread to the mediastinum⁶⁻¹² or to large pulmonary blood vessels.⁴ Occasionally an apparent total absence of perfusion or ventilation, or both, is seen on one side^{4,8,12} and this is not necessarily associated with major bronchial obstruction. The mechanisms of unexpectedly large defects of perfusion and ventilation are only partly understood but may include compression or invasion of large or medium-sized pulmonary arteries or veins, obstructive emphysema, reflex vasoconstriction due to local hypoxia, and other postulated reflex mechanisms secondary to the presence of the tumour.¹⁻⁵

Despite awareness of these appearances and attempts to predict resectability,⁶⁻¹² lung scanning has not been generally accepted as part of the routine assessment of patients with bronchial carcinoma. We have studied its use in such patients, to determine the circumstances in which the technique can help to indicate resectability and to compare the value of different scanning methods.

We have compared the value of perfusion scanning with that of ventilation scanning using both xenon-133 and krypton-81m. Ventilation scanning using krypton has the advantage of permitting multiple views. These views, obtained during tidal breathing, mainly reflect regional ventilation and can be compared directly with similar views obtained with the technetium-99m perfusion scan. Xenon ventilation scans were included since this is the standard technique and is widely available.

Methods

Fifty-eight patients referred to a regional cardiothoracic centre for consideration of surgical treatment of bronchial carcinoma were studied. All were considered to have technically resectable tumours on the basis of clinical, radiographic, and bronchoscopic assessment; but the results of the lung scans were not available to the surgeon before

Address for reprint requests: Dr GJ Gibson, Regional Cardiothoracic Centre, Freeman Hospital, Newcastle upon Tyne NE7 7DN.

operation. There were 46 men and 12 women and all except two were smokers or ex-smokers. Perfusion and ventilation scans were performed with a Technicare Sigma 410 gamma camera and data were collected on a Link Systems "Dyanne" computer. A ventilation study was performed in the supine position, 185 MBq of xenon-133 being delivered from a closed spirometer system. A single posteroanterior image was obtained after full inspiration and a second image after equilibration by rebreathing for four minutes. Images were then obtained during washout at one, three, and six minutes. Perfusion scans were performed by the intravenous injection of 37 MBq of technetium-99m microspheres in the supine posture. With the patient in the horizontal position four views were obtained (anteroposterior, posteroanterior, right lateral, and left lateral). Krypton ventilation images were obtained with the patient in the same postures, producing corresponding views. The gas was delivered through a disposable face mask.¹³ The interference contribution of the lower-energy gamma ray (^{99m}Tc 140 keV) to the higher-energy gamma ray (^{81m}Kr 190 keV) counting window was less than 5%. The krypton gas supply was removed between each position so that the opposite interference was close to zero. For the analysis each lung was outlined and an appropriate correction was made for background count. The percentage contribution of the affected lung to the total number of counts was calculated by taking the mean of anteroposterior and posteroanterior views for technetium and krypton and the posteroanterior view for xenon inhalation and equilibrium views. Small defects therefore give a value for the contribution of the affected lung tending towards 50% and large defects give a value tending towards zero. It is theoretically possible that a reduction in function of one part of a lung would be compensated for by above-normal perfusion or ventilation of the unaffected part of the lung and, if this occurred, it would reduce the sensitivity of indices based on the total hemithorax. We explored the importance of this mechanism by comparing perfusion and ventilation of the "normal" half of the affected hemithorax with the corresponding half of the unaffected hemithorax, arguing that if such compensatory changes occurred a greater number of counts would be recorded from the affected side. Asymmetry resulting from the position of the heart precludes valid comparison between right and left lower quadrants, but we were able to compare right and left upper quadrants in this way in 14 patients with defects confined to one or other lower zone. Since there were no consistent differences between perfusion or ventilation of the upper quadrants of affected and unaffected lungs in these patients we

concluded that measurements relating to a complete hemithorax are valid indices of the effects of the tumour in that lung.

Posteroanterior and lateral radiographs were read by three trained observers, who agreed on the position and size of the primary tumour, the presence of lobar collapse, and evidence of hilar or mediastinal lymphadenopathy. Peripheral tumours were classified as small (<4 cm mean diameter) or large (\geq 4 cm mean diameter). Central tumours were defined as those not distinct from the hilar structures on posteroanterior and lateral radiographs. Tumours causing lobar collapse were considered as a separate group since a relatively small tumour obstructing a lobar bronchus could produce a disproportionately large scan defect. The significance of differences was tested by unpaired *t* tests for comparison of means.

Results

We initially present the results of the perfusion scans in relation to the operative findings and outcome; comparisons of the different scan techniques are made subsequently.

Resectability and operative findings

There were 17 small peripheral tumours, 19 large peripheral tumours, 12 tumours associated with lobar collapse, and 10 central tumours. The relationship of the radiographic appearance to the per-

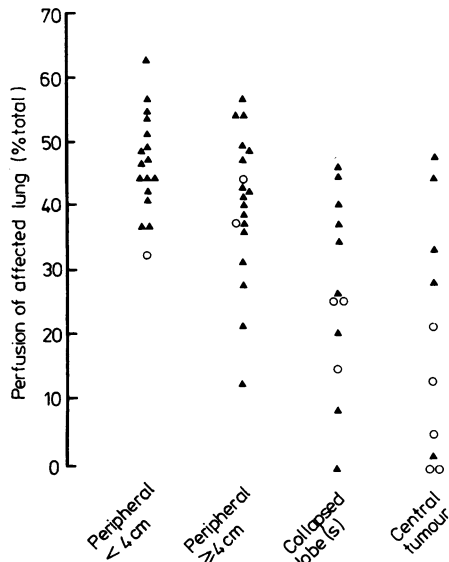
Table 1 Radiographic appearances and perfusion scans

Chest radiograph	No of cases	Mean (\pm SD) perfusion p of affected lung (% total)
Peripheral tumour		
< 4 cm	17	47.4 \pm 7.8
\geq 4 cm	19	40.9 \pm 11.3
Collapsed lobe(s)	12	27.6 \pm 14.6
Central tumour	10	19.9 \pm 18.5

* *p* = < 0.01; ** *p* = < 0.001.

Table 2 Radiographic appearances and perfusion scans of right and left lung tumours

Chest radiograph	Right lung		Left lung	
	No	Mean perfusion (% total)	No	Mean perfusion (% total)
Peripheral				
< 4 cm	10	50.1	7	43.4
\geq 4 cm	12	46.1	7	32.1
Collapsed lobe(s)	6	36.4	6	18.7
Central tumour	5	31.6	5	8.3



Lung perfusion and radiographic features of 58 patients undergoing surgery for bronchial carcinoma. ▲—resected tumour; ○—non-resectable tumour.

the affected lung, only one had a resectable tumour, while all four with greater than 25% perfusion had a resection. In every case found to be non-resectable there was spread of tumour to mediastinal lymph nodes; in addition, there were two instances of spread to the pericardium and four of spread to the chest wall. Enlarged hilar lymph nodes were found in 18 cases and enlarged mediastinal nodes in 25, but tumour was confirmed histologically in only 10 (56%) and 17 (68%) respectively. Histologically proved spread to mediastinal lymph nodes occurred in nine out of the 12 cases (75%) where perfusion of the affected lung was under 25% of the total but in only eight out of the 46 (17%) where perfusion was over 25% of the total. None of the patients in whom perfusion was less than 25% had a tumour that was resectable by lobectomy but one patient with no perfusion at all in the affected lung had an apparently successful resection by pneumonectomy.

Survival

All survivors have been followed for a minimum of 24 months. After exclusion of the four perioperative deaths, only four out of 10 patients (40%) in whom perfusion of the affected lung was less than 25% of the total survived 12 months, compared with 25 out of 44 patients (57%) in whom perfusion was greater than 25%. The figures at 24 months were 1/10 (10%) and 19/44 (43%) respectively. The differences are largely accounted for by the fact that in only half of the 12 patients with perfusion less than 25% of the total was resection possible, compared with 89% where perfusion was greater than 25% (table 3). Of the 34 deaths occurring up to 24 months, only one was not directly related to the original tumour and this occurred in a patient with perfusion greater than 25% of the total.

Comparison of perfusion scan with xenon and krypton ventilation scans

Defects of perfusion were usually accompanied by corresponding defects of ventilation, although per-

fusion scan is shown in tables 1 and 2 and the figure. There was a significantly lower mean value for perfusion of the affected lung with more centrally placed tumours. Left-lung tumours produced larger defects than did right-lung tumours. The relationship to resection is shown in the figure and the operative findings are shown in table 3. Of the 36 peripheral tumours, only three were found to be non-resectable; none of these was associated with a large perfusion defect. Of the 12 tumours causing collapsed lobes, three were non-resectable. Although these three patients had moderately large perfusion defects a further four with equally large or larger defects had successful resection. A clearer separation was seen with centrally placed tumours. Of the six patients with less than 25% perfusion in

Table 3 Operative findings in relation to perfusion scan

Size of defect	Perfusion of affected lung (% total)	No of cases	No of tumours resected			No of tumours not resectable
			Confined to lung	Hilar nodes only	Mediastinal nodes	
Large	0-5	5	1	0	2	2
	6-15	3	0	1	0	2
	16-24	4	0	1	1	2
	25-34	7	2	2	0	3
	35-44	18	13	1	3	1
Small	45-54	17	13	3	0	1
	55+	4	2	2	0	0
Total		58	31	10	6	11

fusion defects were often slightly larger. The contribution of the affected lung agreed within 10% for all techniques (technetium perfusion, krypton ventilation, xenon inhalation, and xenon equilibrium) in 35 of the 47 patients for whom full data were available. In 12 there was a discrepancy of more than 10% between the perfusion scan and one or more ventilation scans, and in 10 of these the perfusion of the affected lung was less than the ventilation. Four of these 12, including the two patients with the largest discrepancy, had non-resectable tumours.

Influence of airways obstructions

Thirty-nine patients had spirometric evidence of airways obstruction ($FEV_1/VC < 70\%$), the FEV_1 varying from 1.0 to 3.5 l (34–105%). Nineteen of these patients showed delayed washout of xenon, including seven with a generalised patchy abnormality of ventilation and perfusion. Airways obstruction was not severe in these seven (FEV_1 53–79% predicted); none had very large perfusion defects related to the tumour (perfusion 37–48.5% total), and none of the tumours was found to be non-resectable. A further two patients showed isolated scan defects unrelated to the tumour (see below). The remaining twenty cases of airways obstruction showed none of the above features.

Unexpected isolated lung scan defects

In eight cases there was an unexplained defect of ventilation (six patients) or perfusion or both (7 patients) apparently unrelated to the tumour and without a matching radiological opacity. Two of these patients had severe airways obstruction. In five the unexpected defect was in the "healthy" lung and on subsequent study six months after operation the defect was no longer visible in three of these.

Discussion

Interpretation of any data that are used to predict the resectability of bronchial carcinoma depends critically on the criteria used by individual surgeons to decide whether or not potentially curative surgery is technically possible. In the United Kingdom routine preoperative mediastinoscopy is not widely practised and the finding at thoracotomy of some affected mediastinal lymph nodes does not necessarily imply that the tumour cannot be resected. Surgical practice varies but in general, provided that the intrapulmonary tumour can be separated from the mediastinum with ease, the surgeon may proceed to resect enlarged mediastinal lymph nodes from the subcarinal, paratracheal, and para-aortic areas in an attempt to clear the tumour completely. Such an

attitude is supported by the fact that not all enlarged firm lymph nodes contain metastatic tumour.¹⁴ Mean survival is less when mediastinal lymph nodes are affected, but reported five-year survival rates vary from below 10%^{15,16} to 20–30%.^{17,18} In common with previous reports^{6,9,10,12} our results show that large defects of perfusion are associated with an increased likelihood of tumour spread to the mediastinum. In our patients the ability of the lung scan to distinguish between resectable and non-resectable tumours improved with more centrally placed tumours so that, for lesions radiologically in continuity with the hilum, perfusion of the affected lung of less than 25% of the total made successful resection unlikely. The separation was less good when lobar collapse occurred and in the case of peripheral tumours the lung scan was unhelpful in predicting resectability. Our findings contrast with those of Secker Walker and colleagues^{6–8}; in 46 cases where tumours appeared operable on clinical grounds they found that if perfusion of the affected lung was less than one-third of the total the tumour proved to be non-resectable in every case except one. In our series 10 of 18 patients with perfusion of less than one-third of the total had apparently successful resections. Other authors have not assessed lung perfusion quantitatively but have expressed the size of the defect in relation to the size of the lesion on radiographs.^{9,10,12} Their experience was that when perfusion defects were larger than the size of the radiological opacity the tumour was more likely to be non-resectable. Maynard *et al* in a study of 24 patients found 10 with larger-than-expected perfusion defects, of whom nine had non-resectable tumours.⁹ A further nine patients with normal scans, or with scan defects matching the radiological opacity, also had non-resectable tumours, however; and the overall resection rate for the series was only 6/24 (25%). On the other hand, Pistelli *et al* found 25 of 37 patients with unexpectedly large perfusion defects but only seven tumours proved to be non-resectable, and there were no additional non-resectable tumours.¹² Macumber and Calvin found mediastinal lymph node spread in 22 of 38 cases with perfusion defects larger than the mass lesion apparent from radiographs but did not state the number of tumours which were resectable.¹⁰ When our data were analysed in a similar manner, 16 out of 32 patients with larger-than-expected perfusion defects had mediastinal lymph node spread and nine tumours were not resectable. These results are similar to those of Pistelli *et al*¹² and Macumber and Calvin.¹⁰ The different results obtained by Maynard *et al*⁹ are likely to have been influenced by selection of patients. Our findings on lymph node spread, resectability, and survival agree closely with those of

Svanberg,¹⁹ who used bronchspirometry to determine regional loss of ventilation and perfusion.

We have noted a difference in the size of perfusion defects with left and right lung tumours. While it may not be valid for anatomical reasons to compare central tumours and those associated with lobar collapse, when peripheral resectable tumours were compared the mean value for perfusion for right lung lesions was 49% (n = 19) and for left lung tumours 38% (n = 14) (p = <0.001). In normal subjects the differential function of the lungs is 53% right v 47% left.²⁰ After correction for this the mean values for perfusion in these patients were right lung 46% and left 41% (p > 0.05). We conclude that there is no significant difference in the size of the perfusion defects produced by tumours of the right and left lungs after correction for lung size. Ideally it might be possible to set different limits on the size of the perfusion defect for each lung to determine the likelihood of resectability but the numbers in this series do not allow us to propose values for these limits.

Comparison of the perfusion scan with both xenon and krypton ventilation scans showed that the perfusion scan is a more sensitive indicator of mediastinal tumour spread, and this is in agreement with the observations of Secker Walker *et al.*⁸ Delayed washout of xenon from the lung distal to the tumour was seen in 10 cases but the ventilation scan itself rarely provided further helpful information. Where there was a large discrepancy between ventilation and perfusion, with a perfusion defect larger than the ventilation defect, the tumour was more likely to be non-resectable. This might be accounted for by direct invasion or compression of the blood vessels of the affected lung but we have not been able to confirm this.

The presence of generalised airways obstruction did not impair the usefulness of the lung scan. Airways obstruction was moderate to severe in 28 patients, including the seven with generalised abnormality of ventilation and perfusion; but in only one patient with a small peripheral tumour was the tumour defect not clearly identified. Because of the selection criteria patients with severe airways obstruction and large tumours were unlikely to be included in this study. The cause of unexpected solitary lung scan defects is not clear but some were only temporary, which suggests that localised transient airways obstruction—for example, by secretions—may have been responsible. There was no clinical evidence of pulmonary embolism in any case. The coincidence of such defects on both ventilation and perfusion scans in five cases excludes artefact as the cause.

The overall resection rate for the series is similar

to previous experience,²¹ with eleven out of 58 (19%) not resectable because of tumour spread. If a cut-off of 25% perfusion had been applied to central tumours six patients in this series would not have had operations, only one of whom would have been denied a potentially successful outcome. This would have reduced the non-resection rate to six out of 52 or 11%.

In conclusion, we suggest that for determining the likely resectability of bronchial carcinoma lung scanning is most useful for centrally placed tumours. These are usually the most difficult to assess by other means. The perfusion scan alone appears to be more useful and sensitive than ventilation scanning. In patients who are otherwise fit for surgery the presence of generalised airways obstruction does not hinder interpretation of the scan. The addition of lung scanning to the preoperative evaluation of selected patients with bronchial carcinoma should help to reduce the number of patients undergoing unrewarding thoracotomy.

We are grateful to Mr R Dobson, Mr CJ Hilton, Mr A Hedley Brown, and the late Mr WC Barnsley for allowing us to study patients under their care; to Dr MD Sumerling for reading radiographs; and to Mrs H Brown, Mrs Y Ferguson, Mrs J Harris, and Mr S Hughes for technical assistance.

References

- Wagner HN, Lopez-Majano V, Tow DE, Langan JK. Radioisotope scanning of lungs in early diagnosis of bronchogenic carcinoma. *Lancet* 1965;ii:344.
- Hatch HB, Maxfield WS, Ochsner JL. Radioisotope lung scanning in bronchogenic carcinoma. *J Thorac Cardiovasc Surg* 1965;50:634-9.
- Garnett ES, Goddard BA, Fraser HS, MacLeod WM. Lung perfusion patterns in carcinoma of bronchus. *Br Med J* 1968;ii:209-10.
- Vassallo CL, Gee JBL, Wholey MH, Vester JW. Lung scanning in hilar bronchogenic carcinoma. *Am Rev Respir Dis* 1968;97:851-8.
- Fraser HS, MacLeod WM, Garnett ES, Goddard BA. Lung scanning in the preoperative assessment of carcinoma of the bronchus. *Am Rev Respir Dis* 1970;101:349-58.
- Secker Walker RH, Provan JL, Jackson JA, Goodwin J. Lung scanning in carcinoma of the bronchus. *Thorax* 1971;26:23-32.
- Secker Walker RH, Provan JL. Scintillation scanning of lungs in preoperative assessment of carcinoma of bronchus. *Br Med J* 1969;iii:327-30.
- Secker Walker RH, Alderson PO, Wilhelm J, Hill RL, Markham J, Kinzie J. Ventilation-perfusion scanning in carcinoma of the bronchus. *Chest* 1974;65:660-3.
- Maynard CD, Miller RP, Heaphy LJ, Whitley JE. Pulmonary scanning in bronchogenic carcinoma. *Radiology* 1969;92:903-7.

- ¹⁰ Macumber HH, Calvin JW. Perfusion lung scan patterns in 100 patients with bronchogenic carcinoma. *J Thorac Cardiovasc Surg* 1976;**72**:299-302.
- ¹¹ Lipscomb DJ, Pride NB. Ventilation and perfusion scans in the preoperative assessment of bronchial carcinoma. *Thorax* 1977;**32**:720-5.
- ¹² Pistelli G, Angeletti CA, Janni A, *et al.* Perfusion lung scans in the preoperative assessment of pulmonary function in bronchial carcinoma. *J Nucl Med Allied Sci* 1977;**21**:173-82.
- ¹³ Fazio F, Jones T. Assessment of regional ventilation by continuous inhalation of radioactive Kr-81m. *Br Med J* 1975;**iii**:673-6.
- ¹⁴ Nohl HC. An investigation into the lymphatic and vascular spread of carcinoma of the bronchus. *Thorax* 1956;**11**:172-85.
- ¹⁵ Bergh NP, Scherstén T. Bronchogenic carcinoma. A follow-up study of a surgically treated series with special reference to the prognostic significance of lymph node metastases. *Acta Chir Scand* 1965;suppl:347.
- ¹⁶ Sarin CL, Nohl-Oser HC. Mediastinoscopy: A clinical evaluation of 400 consecutive cases. *Thorax* 1969;**24**:585-8.
- ¹⁷ Ramsey HE, Cahan WG, Beattie EJ, Humphrey C. The importance of radical lobectomy in lung cancer. *J Thorac Cardiovasc Surg* 1969;**58**:225-30.
- ¹⁸ Pearson FG, Nelems JM, Henderson RD, Delarue NC. The role of mediastinoscopy in the selection of treatment for bronchial carcinoma with involvement of superior mediastinal lymph nodes. *J Thorac Cardiovasc Surg* 1972;**64**:382-90.
- ¹⁹ Svanberg L. Regional functional decrease in bronchial carcinoma. *Ann Thorac Surg* 1972;**13**:170-80.
- ²⁰ Svanberg L. Influence of posture on the lung volumes, ventilation and circulation in normals: a spirometric-bronchspirometric investigation. *Scand J Clin Lab Invest* 1957;suppl:25.
- ²¹ Belcher JR, Anderson R. Surgical treatment of carcinoma of the bronchus. *Br Med J* 1965;**i**:948-54.