

What happens to patients with pulmonary aspergilloma? Analysis of 23 cases

PAUL RAFFERTY, BEVERLEY-ANN BIGGS, GRAHAM K CROMPTON, IAN WB GRANT

From the Respiratory Unit, Northern General Hospital, Edinburgh

ABSTRACT The problems associated with pulmonary aspergilloma were assessed retrospectively in 23 patients presenting from 1953 to 1982. Haemoptysis occurred in over half the patients and in two it was fatal. Invasive aspergillosis occurred in five patients, a higher proportion than in earlier reports, and two of these died. Amphotericin B in combination with either flucytosine or natamycin and, more recently, ketoconazole have proved useful in the treatment of this condition.

Species of aspergillus fungi are found throughout the world in decaying vegetation and soil, and its spores are ubiquitous in rural and urban environments. The first report of pulmonary aspergillosis in man appeared in 1842¹ and several patterns of the disease have since been recognised,² ranging from colonisation of damaged lung tissue by the fungus to invasive or necrotising pulmonary aspergillosis.³ The most distinctive lesion is the aspergilloma,⁴ which forms when the fungus grows on the wall of a lung cavity and mycelium and debris become detached to form a concretion of amorphous material containing tangled septate hyphae and altered blood elements.

The natural history of pulmonary aspergilloma is poorly documented and there is no general agreement on the best form of management. This report analyses the treatment and outcome of all cases seen at the Northern General Hospital, Edinburgh, during the past 30 years.

Patients

Twenty-three patients with aspergilloma were studied in the period 1953-82. The criteria for a diagnosis of aspergilloma consisted of the classical radiological sign of an intracavitary mass with a surrounding crescent of air and either a positive result in the aspergillus precipitin test, a sputum culture positive for aspergillus, or (in most cases) both.

The patients ranged in age from 40 to 81 years,

with a mean of 59 years. There were 11 men and 12 women and the follow-up period varied from four months to 30 years, with a mean of 4.5 years.

Results

PREDISPOSING CONDITIONS

The commonest predisposing condition was pulmonary tuberculosis, which accounted for over two-thirds of the cases; other conditions included ankylosing spondylitis, rheumatoid arthritis, ulcerative colitis, pulmonary sarcoidosis, postradiation fibrosis, lung abscess and bronchiectasis (table 1). Because of the nature and extent of the pulmonary lesions in these diseases, the lungs were often severely damaged by fibrosis and bronchiectasis before the development of the aspergilloma.

SYMPTOMS AND SIGNS

Patients most frequently presented with a productive cough, often accompanied by haemoptysis and weight loss (table 2). Half complained of dyspnoea but in most, if not all, this was related to underlying lung disease. In over half the cases finger clubbing was present.

INVESTIGATIONS

All patients had radiological evidence of an intracavitary mass separated from the surrounding wall by a crescent of air. This was often better demonstrated by tomography than by a plain posteroanterior film. Single lesions occurred with similar frequency in the two lungs. These were situated in the upper lobes in all but four patients; multiple lesions were present in six.

Address for reprint requests: Dr Paul Rafferty, Respiratory Unit, Northern General Hospital, Edinburgh EH5 3BD.

Accepted 5 April 1983

Table 1 *Predisposing conditions in 23 cases of pulmonary aspergilloma*

| | No (%) of patients |
|-------------------------|--------------------|
| Tuberculosis* | 15 (65) |
| Ankylosing spondylitis | 2 (9) |
| Sarcoidosis | 1 (4) |
| Rheumatoid arthritis | 1 (4) |
| Ulcerative colitis† | 2 (8) |
| Postradiation fibrosis‡ | 1 (4) |
| Lung abscess | 1 (4) |
| Bronchiectasis | 1 (4) |

*One patient with tuberculosis later developed sarcoidosis and a bronchial carcinoma, which was successfully treated with radiotherapy.

†One patient with ulcerative colitis also developed ankylosing spondylitis.

‡The patient with postradiation fibrosis had received radiotherapy for a malignant thymoma associated with myasthenia gravis.

Table 2 *Clinical features in 23 cases of pulmonary aspergilloma*

| | No (%) of patients |
|------------------|--------------------|
| Productive cough | 19 (83) |
| Haemoptysis | 12 (52) |
| Dyspnoea | 12 (52) |
| Weight loss | 9 (39) |
| Fever | 3 (13) |
| Finger clubbing | 14 (61) |

Sputum samples were obtained from 22 of the 23 patients and *Aspergillus fumigatus* was cultured from 20. In two cases *A niger*, *A terreus*, and *A flavus* were cultured in addition to *A fumigatus*. Serum from all 23 patients was tested for *A fumigatus* precipitins and a positive result was obtained in 20. Of the three patients with a negative result in the precipitin test, two were on long-term corticosteroid treatment and *A fumigatus* was cultured from the sputum; the third developed a mycetoma with a species of *Penicillium* and will be the subject of a later communication.

Skinprick tests were carried out in 16 patients with a 5% solution of an aqueous extract of *A fumigatus* (Bencard); 13 showed positive reactions, with a wheal of more than 3 mm in diameter. A non-specific finding was a raised gammaglobulin level in over half the patients tested.

COMPLICATIONS

Haemoptysis occurred in 12 patients. Nine experienced recurrent haemoptysis that was slight (less than 150 ml in 24 hours) and subsided spontaneously. Three patients had major haemoptysis (more than 500 ml in 24 hours). One died at home; another, considered unfit for surgery, died within six hours of admission to hospital; and the third apparently responded to injections of vitamin K after he had been found to have a reduced prothrombin con-

centration. Only one of these patients had a previous history of haemoptysis.

Invasive pulmonary aspergillosis developed in five patients. This diagnosis was made when progressive pulmonary shadowing was noted in the absence of bacterial infection and mycelial elements were present in the sputum. In four of these patients an aspergilloma was known to be present before the development of this complication. In the other patient an aspergilloma was noted within the wider area of consolidation at the time of presentation. Three patients recovered after specific antifungal treatment and two died within 24 hours of admission. Postmortem examination confirmed the diagnosis in both patients, one of whom had evidence of systemic spread of the disease.

A more common but less specific complication, which occurred in 17 patients, was recurrent cough productive of dark green purulent sputum. Although many patients had underlying lung disease to account for this, *A fumigatus* was the predominant organism found on culture of the sputum in over half of these cases. Three patients developed terminal respiratory failure as a result of underlying chronic lung disease and one as a consequence of myasthenia gravis (table 1).

TREATMENT AND OUTCOME

The treatment of the 23 patients varied widely and included antibacterial drugs, antifungal drugs, and surgery (table 3). Antifungal treatment included, either singly or in combination, natamycin by inhalation, clotrimazole, and ketoconazole by mouth and amphotericin, flucytosine (5FC), and econazole by intravenous infusion. None of these treatment regimens reduced the size of the aspergilloma, but in some cases they relieved troublesome cough and haemoptysis. The mortality in treated and untreated patients was similar. Patients with purulent sputum were often given antibacterial chemotherapy initially, but if *A fumigatus* was found to be the predominant pathogen treatment with a specific antifungal agent was usually substituted. In one of two patients with haemoptysis who were treated with ampicillin for suspected bacterial infection the aspergilloma temporarily disappeared, and in the other it became smaller. In one patient treated with prednisolone there was symptomatic improvement and a reduction in size of the aspergilloma.

Specific antifungal chemotherapy was given to eight patients without invasive aspergillosis on account of purulent sputum or haemoptysis associated with a heavy growth of *A fumigatus* in the sputum. The symptoms resolved in six of these patients, but in all eight the aspergilloma remained unchanged. Five patients with invasive aspergillosis

Table 3 Treatment and outcome in 23 cases of pulmonary aspergilloma

| Treatment | No of patients | Indication | Response to treatment | Effect on aspergilloma | Outcome |
|-------------------------------|----------------|------------------------|------------------------|------------------------|--|
| <i>Antifungal</i> | | | | | |
| Clotrimazole | 3 | Cough, sputum | Improvement in 2 | Unchanged | 1 died (invasive aspergillosis) 1 died (unrelated cause) 1 lost to follow-up |
| Natamycin inhalation | 1 | Cough, sputum | Symptoms resolved | Unchanged | Died (unrelated cause) |
| Natamycin, penicillin | 1 | Cough, sputum | Symptoms resolved | Unchanged | Lost to follow-up |
| Natamycin, prednisolone | 1 | Cough, sputum | Symptoms resolved | Unchanged | Died (unrelated cause) |
| Natamycin, amphotericin | 1 | Invasive aspergillosis | Symptoms resolved | Smaller | Died (haemoptysis) |
| Amphotericin, flucytosine | 1 | Invasive aspergillosis | Symptoms resolved | Unchanged | Alive |
| Flucytosine | 1 | Cough, sputum | Symptoms persisted | Unchanged | Died (unrelated cause) |
| Ketoconazole (+ prednisolone) | 1 | Invasive aspergillosis | Symptoms resolved | Unchanged | Alive |
| Ketoconazole | 1 | Haemoptysis | Symptoms resolved | Unchanged | Alive |
| Econazole | 1 | Invasive aspergillosis | Deteriorated rapidly | Unchanged | Died (invasive aspergillosis) |
| <i>Surgical</i> | | | | | |
| Local resection | 1 | Haemoptysis | Chronic empyema | Resected | Alive |
| Right upper lobectomy | 1 | Haemoptysis | Bronchopleural fistula | Resected | Died (postoperative respiratory failure) |
| <i>Non-specific</i> | | | | | |
| Prednisolone | 1 | Haemoptysis | Symptoms resolved | Smaller | Alive |
| Antibacterial drugs only | 3 | Cough, sputum | Symptoms resolved | Lysis in 1 | 1 died (haemoptysis) 2 died (unrelated causes) |
| Vitamin K | 1 | Haemoptysis | Symptoms resolved | Unchanged | Alive |
| None | 4 | Asymptomatic | | Unchanged | 1 alive 1 lost to follow-up 2 died (unrelated causes) |

were also treated with antifungal drugs. In all three survivors the chemotherapy included amphotericin or ketoconazole.

Two patients were treated surgically, both for recurrent haemoptysis. The first developed a chronic empyema and the second died from respiratory failure in the postoperative period, having developed a bronchopleural fistula.

In the whole group of 23 patients five deaths were directly attributable to the aspergilloma. Two of these were due to invasive aspergillosis and two to massive haemoptysis, and one followed surgery for recurrent haemoptysis. Three patients died from respiratory failure, two from bronchial carcinoma, one from intestinal malabsorption, and two at home from unknown causes. Seven are currently alive and the remaining three have been lost to follow-up.

Discussion

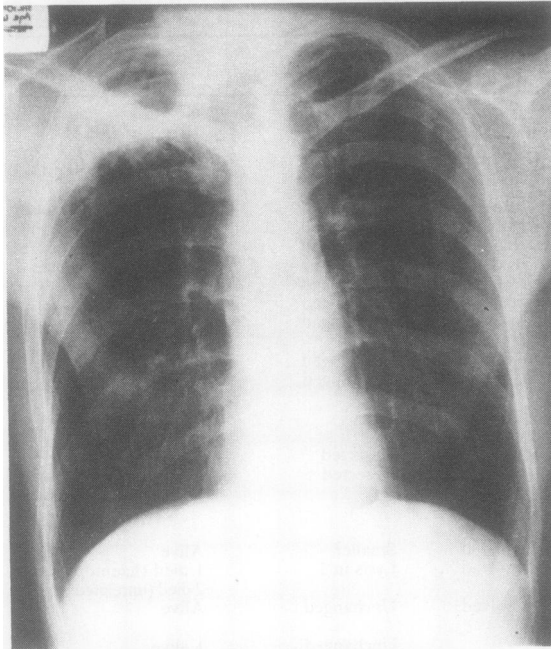
The reasons why the natural history of intracavitary aspergilloma is poorly documented are that it is an uncommon disease and that the outcome is so often related to underlying non-specific pulmonary pathology. The most common predisposing condition in our patients was tuberculosis. This is in keeping with the findings of the British Tuberculosis Association, which in 1968 reported the develop-

ment of an aspergilloma in 15% of persisting (sputum-negative) cavities larger than 2.5 cm, the highest incidence being found in cavities of 7–11 years' duration.⁵

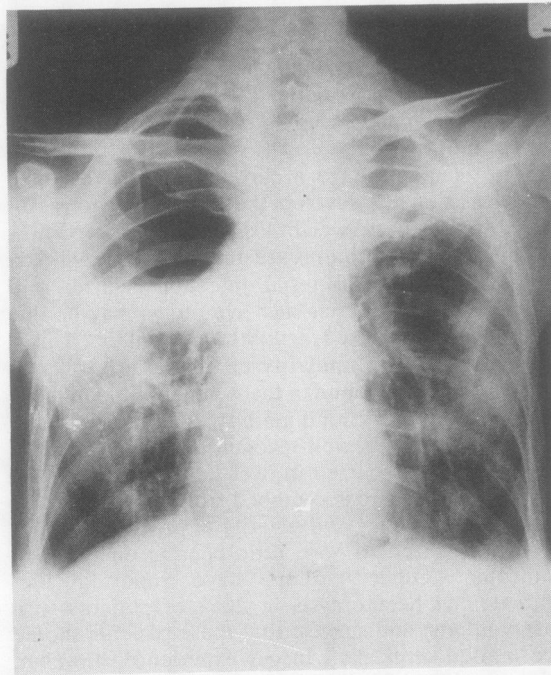
Most patients have a chronic productive cough and occasionally develop the systemic features of fever, malaise, and weight loss. It is difficult to know whether these symptoms are due to the aspergilloma or to coexisting bacterial infection. Davies and Somner suggested that such symptoms may be due to a hypersensitivity reaction to aspergillus.⁶ This is supported by the similarity of the pattern of cytoplasmic antibodies found in these patients and in those with allergic bronchopulmonary aspergillosis.⁷

Haemoptysis, a well-recognized complication of aspergilloma, occurred in over half of our patients. Of these, only two succumbed from massive bleeding. The frequency and severity of previous haemoptysis appeared to have little bearing on the final outcome. Other authors have reported life-threatening haemoptysis in 20% of patients with aspergilloma and suggest that these patients should be treated surgically.⁸ In our experience, however, this is seldom feasible because most patients with aspergilloma have severely damaged lungs and poor pulmonary function.

A more disturbing complication is that of invasive pulmonary aspergillosis (fig). This occurred in five of



a



b

(a) Pulmonary aspergilloma in the right upper lobe. (b) Subsequent development of invasive aspergillosis in the same patient.

our patients, two of whom died. This condition is usually found in debilitated or immunosuppressed patients. Four of our patients were in this category: two were receiving corticosteroid treatment and one had chronic empyema and the other ulcerative colitis. These findings are at variance with the experience of other workers,⁹ who suggest that the risk of aspergilloma progressing to invasive pulmonary disease is negligible.

There is no general agreement on the management of pulmonary aspergilloma per se. The first surgical resection was reported in 1948¹⁰ and for many years surgery was regarded as the treatment of choice for symptomatic disease, especially in the United States. More recently this view has been questioned.⁹ Analysis of the data from 140 pulmonary resections for aspergilloma revealed an overall mortality of 7%. Major postoperative complications such as bronchopleural fistulas, resistant air space problems, empyema, and haemorrhage occurred in 22% of cases. The two patients in our own series who were treated surgically fared badly. One died and the other was left with chronic empyema.

Antifungal treatment in this series varied considerably from case to case and did not affect the size of the aspergilloma or mortality. Our experience, however, confirmed the potential value of amphotericin combined in some cases with flucytosine, and possibly of ketoconazole, in the treatment of secondary invasive aspergillosis. Ketoconazole is an oral antifungal agent in the imidazole group, which has been shown to be effective in various superficial fungal infections and some systemic ones. Borelli *et al* have reported that two patients with pulmonary aspergilloma failed to respond to treatment with ketoconazole;¹¹ but we used it successfully in one patient with invasive aspergillosis, and in another patient symptomatic improvement coincided with the virtual elimination of *A fumigatus* from the sputum.

This study exemplifies the unsystematic approach to the treatment of pulmonary aspergilloma during the past three decades, and the high mortality rate underlines the inadequacy of both medical and surgical treatment. There is very little evidence that either form of treatment influences the prognosis, except on the rare occasions when the risk of fatal haemoptysis can be eliminated by resection of the aspergilloma or when secondary invasive pulmonary aspergillosis, a more common complication than is generally recognised, can be controlled by intensive antifungal chemotherapy.

References

- ¹ Bennet JH. On the parasitic vegetable structures found

- growing in living animals. *Trans R Soc Edinb* 1842;**15**:277.
- ² Turner-Warwick M. *Aspergillus fumigatus* and lung disease. *Postgrad Med J* 1979;**55**:642-4.
- ³ Kennedy WPU, Malone DN, Blyth W. Necrotising pulmonary aspergillosis. *Thorax* 1970;**25**:691.
- ⁴ Campbell MJ, Clayton YM. Bronchopulmonary aspergillosis: a correlation of the clinical and laboratory findings in 272 patients investigated for bronchopulmonary aspergillosis. *Am Rev Respir Dis* 1964;**89**:186-96.
- ⁵ Research Committee of the British Tuberculosis Association. *Aspergillus* in persistent lung cavities after tuberculosis. *Tubercle* 1968;**49**:1.
- ⁶ Davies D, Somner AR. Pulmonary aspergillomas treated with corticosteroids. *Thorax* 1972;**27**:156-62.
- ⁷ Assem ESK, Turner-Warwick M. Cytophilic antibodies in bronchopulmonary aspergillosis, aspergilloma and cytogenic pulmonary eosinophilia. *Clin Exp Immunol* 1976;**26**:67.
- ⁸ Karas A, Hankins JR, Attar S, Miller JE, McLaughlin JS. Pulmonary aspergillosis: an analysis of 41 patients. *Ann Thorac Surg* 1976;**22**:1-7.
- ⁹ Varkey B, Rose HD. Pulmonary aspergilloma: a rational approach to treatment. *Am J Med* 1976;**61**:626-31.
- ¹⁰ Gerstl B, Weidman WH, Newman AV. Pulmonary aspergillosis: a report on 2 cases. *Ann Intern Med* 1948;**26**:661.
- ¹¹ Borelli D, Fuentes J, Leiderman E, *et al.* Ketoconazole, an oral antifungal: laboratory and clinical assessment of imidazole drugs. *Postgrad Med J* 1979;**55**:657-61.