

Correspondence

Bilateral pneumothoraces and pleural effusions in rheumatoid lung disease

SIR,—I read with interest the report by Dr O Ayzenberg and his colleagues entitled "Bilateral pneumothoraces and pleural effusions complicating rheumatoid lung disease" (February 1983, p 159).

We encountered this situation in a 60 year old woman with long standing seropositive nodular rheumatoid arthritis admitted to hospital in March 1982. She developed a dry cough a few weeks before this event and in the week before admission experienced two distinct nocturnal episodes of "life threatening breathlessness" without chest pain.

The chest radiograph confirmed the diagnosis but neither lung could be re-expanded with prolonged underwater sealed drainage (fig). The necrotising nodular rheumatoid pleuritis (confirmed at surgery and later at necropsy) was too severe and extensive to permit visceral decortication and promote satisfactory expansion of the underlying lung. The patient died three months later from staphylococcal septicaemia, bilateral empyemas, and persistent broncho-pleural fistulae.

At least three other cases have now been described^{1 2} (including that of Ayzenberg *et al*), all in men (ages 48, 58, 62) with nodular pleural rheumatoid disease. Two had chronic deforming arthritis, subcutaneous nodules, pulmonary fibrosis, and recurrent unilateral pneumothoraces antedating the bilateral event. In contrast, the youngest had a very short arthritic history with radiographic changes only of periarticular osteoporosis. All required bilateral pleurectomy following the failure of underwater seal drainage. This procedure was successful in the two with relatively low

titres of circulating rheumatoid factor but failed in the patient with a high latex titre (1/1280) similar to ours.

The presence of eosinophilia has been associated with aggressive extra-articular rheumatoid pleuropulmonary disease and pneumothorax,² but neither of the two who died showed eosinophilia during their illnesses. The persistent presence of rheumatoid factor in high titre may carry prognostic significance in this unusual situation, as it does for articular disease.³

WV EVANS

Respiratory Physiology Department
Ipswich Hospital
Ipswich IP4 5PD

¹ Rubin EH, Gordon M, Thelmo WL. Nodular pleuropulmonary rheumatoid disease. *Am J Med* 1967;42:567-81.

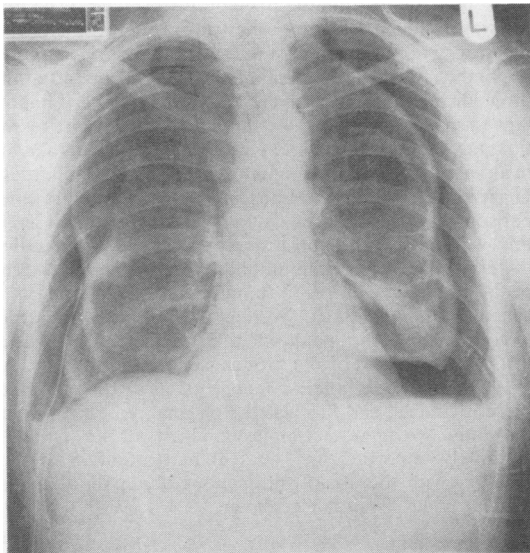
² Crisp AJ, Armstrong RD, Grahame R, Dussek JE. Rheumatoid lung disease, pneumothorax and eosinophilia. *Ann Rheum Dis* 1982;41:137-40.

³ Duthie JJR, Brown PE, Truelove LH, Baragar FD, Lawrie AJ. Course and prognosis in rheumatoid arthritis: a further report. *Ann Rheum Dis* 1964;23:193.

SIR,—We read with interest the case report by Dr O Ayzenberg and colleagues describing a patient with simultaneous bilateral pneumothoraces and pleural effusions complicating rheumatoid lung disease (February 1983, p 159). The authors claimed that theirs was the first documentation of the simultaneous occurrence of these complications. However Crisp *et al* have reported a similar case with bilateral pneumothoraces and small pleural effusions.¹ We would like to call attention to a third such patient, in whom the pneumothorax on one side appeared five days after it was noted on the other.

A 71 year old retired welder was admitted to our hospital complaining of dyspnoea that had lasted for three days. He had a long history of severe rheumatoid arthritis with subcutaneous nodules and a high titre of serum rheumatoid factor (1/1280). The arthritis was clinically stable at the time of admission. The chest radiograph on admission showed bilateral pleural effusions and a large right sided pneumothorax. A right tube thoracostomy was immediately performed. A left thoracentesis was then carried out, yielding 1200 ml of a cloudy yellow green fluid (protein 4.6 g/dl, lactate dehydrogenase 2842 units/l, glucose <20 mg/100 ml (1.1 mmol/l)). Culture of the fluid and cytological examination gave negative results. Chest radiographs taken immediately after the thoracentesis and three days later showed no evidence of a left pneumothorax. Five days after admission a left sided spontaneous pneumothorax appeared, estimated at 15%. A left sided tube thoracostomy was performed. Re-expansion of both lungs was difficult and delayed. Tetracycline pleural sclerosis was eventually performed with satisfactory results.

Bilateral hydropneumothorax complicating rheumatoid lung disease may thus be metachronous as well as synchronous. In either case, this is an exceedingly rare complication of rheumatoid lung disease. Re-expansion of



Chest radiograph after prolonged bilateral underwater sealed drainage in a 60 year old woman with longstanding rheumatoid arthritis.

the lung in this setting may be difficult, as noted by Ayzenberg *et al* and others.¹⁻³

JL STAUFFER
Pulmonary Disease Section
Fresno Veterans Administration

JE CARBONE
Pulmonary Function and Exercise Laboratories
Fresno Veterans Administration Medical Center
2615 East Clinton Avenue
Fresno, California 93703, USA

- ¹ Crisp AJ, Armstrong RD, Grahame R, Dussek JE. Rheumatoid lung disease, pneumothorax, and eosinophilia. *Ann Rheum Dis* 1982;41:137-40.
- ² Rubin EH, Gordon M, Thelmo WL. Nodular pleuropulmonary rheumatoid disease: report of two cases and review of literature. *Am J Med* 1967;42:567-81.
- ³ Yarborough JW, Sealy WC, Miller JA. Thoracic surgical problems associated with rheumatoid arthritis. *J Thorac Cardiovasc Surg* 1975;69:347-54.

Premedication for fiberoptic bronchoscopy

SIR.—I would like to comment on the study of premedication for fiberoptic bronchoscopy by Dr PJ Rees and others (August 1983 p 624). The authors reveal their dissatisfaction with current premedication techniques both before and after their study, an opinion which is hardly surprising given their handling of the premedication drugs.

Firstly, experience derived from surgical anaesthetic practice may not be directly relevant in the context of short procedures such as bronchoscopy. Thus it cannot be assumed that the antitussive action of papaveretum, effective during anaesthetic induction and continuous tracheal intubation, will be reproduced during a procedure in which a bronchoscope is manipulated into upper airways and is continually manoeuvred within them. Further, as topical analgesia is always used, the antitussive and analgesic properties of papaveretum are necessarily of little significance. Furthermore, although papaveretum has a sedative action, it is not a good anxiolytic,¹ a more relevant consideration for short, invasive procedures, particularly when undertaken on an outpatient basis. Diazepam is a good anxiolytic and, in combination with atropine, it provides useful amnesia. The authors have, however, continued to use the intramuscular route, which results in an unpredictable action, slower than the oral route, by which it has been largely superseded when diazepam is used by anaesthetists.¹ The authors have compounded these errors by allowing an inadequate interval between administration of the premedication and the bronchoscopic procedure. Diazepam if given orally would have an effect after 20-40 minutes with a peak at 60 minutes²; and if given intramuscularly the effect would be even slower, if it was effective at all. Intramuscular papaveretum has a time of onset of 15-30 minutes and a peak at 45-90 minutes.¹ These times are considerably in excess of those allowed by the authors and go a long way to explain the non-significant differences between the premedication methods described and why the patients' assessments were less favourable than the bronchoscopists'. To be effective as a premedication regi-

men the drugs used must reach the peak of their desirable properties at the time of the bronchoscopy and they must possess properties which are appropriate for the procedure; both features were largely absent in the study of Dr Rees and his colleagues.

The message that does come across is that topical analgesia of the upper airways is of prime importance during bronchoscopy. This is indicated by the patients' unpleasant memories of the procedure, and suggests considerable shortcomings in this aspect of fiberoptic bronchoscopy. Unless this is adequately controlled, assessments of premedication techniques will be misleading. When it is adequately controlled the use of premedication other than atropine as a sialogogue may be unnecessary.³

GFA BENFIELD
East Birmingham Hospital
Birmingham B9 5ST

- ¹ Gray TC, Nunn JF, Utting JE. *General anaesthesia*. Vol 1. 4th ed. London: Butterworth, 1980:257-79.
- ² Vickers MD, Wood-Smith FG, Stewart HC. *Drugs in anaesthetic practice*. 5th ed. London: Butterworth, 1981:84-6.
- ³ Pearce SJ. Fiberoptic bronchoscopy: is sedation necessary? *Br Med J* 1980;281:779-80.

**This letter was sent to the authors, who reply below.

SIR.—Dr Benfield questions the use of papaveretum and diazepam in the way we used them in our study of premedication. The drugs were chosen because they are widely used in this context; for instance, intramuscular papaveretum and intramuscular diazepam were the two preparations used with an anticholinergic agent in a series of transbronchial biopsies from the Brompton Hospital.¹ Papaveretum was used in two other large studies totalling over 700 patients from the Brompton Hospital.^{2,3} The timing was designed to achieve the start of the peak effect of the drug at about the time of the start of the bronchoscopy. Inevitably, there are often unexpected delays after the premedication has been given, and we feel that it is important to make sure that the effect has not been lost by the time the procedure is done. From our reading we take the peak narcotic effect of opiates to be 30-60 minutes.⁴ Diazepam was given intramuscularly so that a blind comparison with papaveretum could be used. It is often used in this way for fiberoptic bronchoscopy and we disagree that the effect would not occur until later than 60 minutes. The peak blood level after intramuscular administration is achieved by 30 minutes.⁵ We feel therefore that the drugs were reaching the peak of their desirable properties through the period of the bronchoscopy.

We share Dr Benfield's feeling of dissatisfaction with these regimens, and this was the original reason for doing the study. We agree that topical analgesia of the airways is extremely important and we feel that attention to this, together with the use of intravenous diazepam as necessary, provides a suitable regimen.

PJ REES
JG HAY
JR WEBB
Guy's Hospital Medical School
London SE1 9RT