

# Bronchography via the fiberoptic bronchoscope

CDR FLOWER, JM SHNEERSON

*From the Departments of Radiology and Chest Medicine, Papworth Hospital, Cambridge*

**ABSTRACT** We have reviewed the results of 167 consecutive bronchograms carried out through the fiberoptic bronchoscope at the end of the bronchoscopic examination. Additional diagnostic information was obtained in 61 (37%) of the patients. Bronchiectasis was the most common finding and was particularly frequent in older patients with haemoptysis and a normal chest radiograph, in those with a chronic productive cough with a normal chest radiograph, and in a heterogeneous group with persistent lobar shadowing. The relative ease with which good quality bronchograms can be obtained via the fiberoptic bronchoscope has led us to discard more conventional methods except in children.

During the last 20 years there has been a general decline in the use of bronchography. This has resulted from a variety of factors, most important of which are the decline in incidence of bronchiectasis and the advent of fiberoptic bronchoscopy, coupled with the opinion that bronchography rarely provides useful information not otherwise obtainable by more specific and less disagreeable and hazardous methods. The widely differing use of bronchography<sup>1–3</sup> suggests that there is no clearcut agreement as to which patients will benefit from the procedure. With the advent of fiberoptic bronchoscopy there is no need for the two techniques to be mutually exclusive,<sup>4</sup> for the bronchoscope provides excellent, safe access to the whole bronchial tree for radio-opaque contrast media. We have reviewed the results of performing bronchography as an addition to fiberoptic bronchoscopy and have attempted to assess its clinical usefulness.

## Methods

Details of 167 consecutive bronchograms performed at Papworth Hospital from 1977 to 1981 have been analysed. The patients' ages ranged from 13 to 79 years (mean 50.1 years). One hundred males and 67 females underwent bronchography. All our bronchoscopic examinations using the fiberoptic bronchoscope are performed in the department of radiology on a tilting table with table top movement. All patients are sedated, usually with papaveretum

Address for reprint requests: Dr JM Shneerson, Papworth Hospital, Papworth Everard, Cambridge CB3 8RE.

*Accepted 21 November 1983*

and hyoscine. Bronchoscopy is performed with the patients supine. For bronchography the contrast medium is introduced through the fiberoptic bronchoscope (Olympus model 4B2 or Pentax model FB-15A) at the end of the bronchoscopic examination. Fluoroscopy is always used with an overhead tube and adequate collimation. A polyethylene cannula 100 cm long, F 4.8 gauge, and an internal diameter of 1.0 mm is passed through the suction channel of the bronchoscope and placed into the appropriate bronchus under direct vision. The contrast medium (aqueous propylidone) is then instilled with the patient tilted head up at an angle of 15° to the horizontal and with the examined side dependent in the lateral oblique position. Further aliquots of contrast medium are instilled according to requirements. If a bilateral bronchogram is required or if a lobe is inadequately filled, the tip of the bronchoscope and inner catheter are manipulated into the appropriate bronchus under fluoroscopic control (direct vision having now been lost because of the contrast medium).

About 30 ml of contrast medium is required to opacify the whole bronchial tree. Correspondingly less is required for a unilateral or lobar study. Bilateral bronchograms were obtained in 50 cases, unilateral bronchograms in 83, and selective lobar bronchograms in 34 (table 1). Only two bronchograms were not of diagnostic quality. The additional time required for bronchography was about 15 minutes. There were no important complications. All patients were given physiotherapy immediately after the procedure and spent the ensuing night in hospital. The patients' response to the procedure was variable, but those who found it disagreeable

Table 1 Clinical groups and extent of bronchography

Clinical and radiographic group	No of patients	Bronchogram		
		Lobar	Unilateral	Bilateral
All	167	34	83	50
Haemoptysis with normal chest radiograph	40	2	17	21
Chronic productive cough with normal chest radiograph	12	0	6	6
Chronic non-productive cough with normal chest radiograph	3	0	0	3
Persistent lobar shadowing	88	32	47	9
Bronchiectasis suspected on clinical or radiographic grounds or both	8	0	3	5
Sarcoidosis	7	0	1	6
Miscellaneous	9	0	9	0

had usually tolerated the preceding bronchoscopy poorly. Undoubtedly the best tolerated procedures were performed by an operator experienced in the manipulation of catheters under fluoroscopic control, and these bronchograms were of better quality than the others. The clinical usefulness of the information obtained was assessed with reference to the case notes and the subsequent management of the patient.

## Results

On the basis of clinical and chest radiographic criteria the problems requiring investigation were found to divide the 167 patients into seven groups (table 1).

The group with persistent lobar shadowing was heterogeneous and included lobar and segmental consolidation and irregular or cavitary shadows confined to one lobe. The patients with sarcoidosis were examined because of clinical suspicion that they might have bronchial stenoses. Bronchoscopy,

as distinct from bronchography, was indicated in all but 15 of the 167 patients studied. The 15 patients in whom bronchography was the primary requirement comprised five with chronic productive cough and a normal chest radiograph, one with lobar consolidation, one with pulmonary sarcoidosis, six with radiographic changes suggestive of bronchiectasis, and two in the miscellaneous group. With one exception (see below), patients with haemoptysis and a normal chest radiograph in whom a tumour was seen at bronchoscopy did not have bronchography.

The bronchographic findings are summarised in table 2. Useful additional information was obtained by bronchography in 61 patients (37%). Of the 40 patients with the single symptom of haemoptysis and a normal chest radiograph, six had unexpected bronchiectasis and one had a subsegmental tuberculous stricture. In one of the patients a bronchial carcinoma was seen bronchoscopically and bronchography was performed as an adjunct to surgical management. Four other patients showed the

Table 2 Bronchographic findings

Clinical and radiographic group	No of patients	Normal bronchograms	Abnormal bronchograms				Useful additional information obtained by bronchography
			Bronchiectasis	Benign stricture	Bronchial carcinoma	Other abnormality	
All	167	84	38	9	11	25	61
Haemoptysis with normal chest radiograph	40	28	6*	1*	1	4	7
Chronic productive cough with normal chest radiograph	12	7	5*	0	0	0	5
Chronic non-productive cough with normal chest radiograph	3	2	0	0	0	1*	1
Persistent lobar shadowing	88	40	19 (14*)	4*	8	17 (15*)	33
Bronchiectasis suspected on clinical or radiographic grounds or both	8	0	8*	0	0	0	8
Sarcoidosis	7	3	0	4*	0	0	4
Miscellaneous	9	4	0	0	2	3*	3

\*Patients in whom useful additional information was obtained by bronchography.

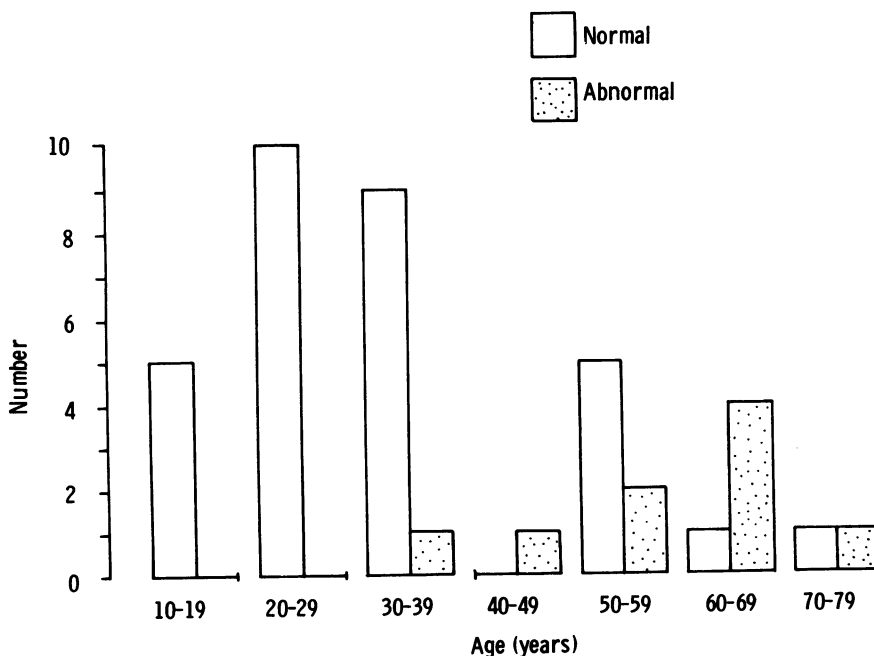
changes usually associated with chronic bronchitis (dilated ducts of mucus glands, retained secretions, and peripheral pooling<sup>3</sup>). Of the 12 patients with chronic productive cough and a normal chest radiograph, five had unexpected bronchiectasis. Of the three patients with a chronic non-productive cough and a normal chest radiograph, one had the bronchographic changes usually associated with chronic bronchitis. Of the 88 patients with lobar shadowing, 19 had bronchiectasis; in 14 of these it was unsuspected and did not follow a recognised chest infection. Four patients had benign bronchial stenoses and eight patients had stenoses due to bronchial carcinomas. Of the 17 patients with other bronchographic abnormalities, two had changes of chronic bronchitis whose demonstration was not held to be clinically useful, eight had distorted bronchi due to loss of acinar tissue as a result of pneumonia, and seven patients had either an unsuspected cavity demonstrated or patent bronchi shown adjacent to a known cavity. In all patients suspected of having bronchiectasis the diagnosis was confirmed and the extent of disease was demonstrated. Three of the seven patients with sarcoidosis were shown to have more widespread subsegmental stenoses than had been seen at bronchoscopy and in one an appreciable but unsuspected subsegmental stenosis was

demonstrated. In the miscellaneous group abnormal bronchograms were held to be useful in three patients (one with Macleod's syndrome and two with unexplained pleural effusions).

Bronchographic findings that did not provide useful additional diagnostic information (table 2) include bronchial widening and distortion, which was probably due to a recent infection ("reversible bronchiectasis"<sup>6</sup>) (five patients), changes suggestive of chronic bronchitis (seven patients), and tumour "mapping" in cases of bronchial carcinomas before surgery (11 patients). "Mapping" was also undertaken in four patients with benign strictures.

## Discussion

Bronchography in patients with haemoptysis and a normal chest radiograph is generally believed to yield little important clinical information,<sup>7</sup> although there is a lack of evidence to substantiate this impression. In a review of 196 patients undergoing bronchography for haemoptysis,<sup>8</sup> 92 patients had a normal chest radiograph and in these patients bronchiectasis was demonstrated in two patients and benign bronchial occlusions in two patients. This incidence of bronchiectasis (2%) compares with a 15% incidence in our series of 40 patients who had



*Relationship between age and bronchographic findings in patients with haemoptysis and a normal chest radiograph.*

both a normal chest radiograph and no bronchoscopic evidence of tumour. Although there seems little doubt that the yield is low, we believe that the necessity for bronchoscopy combined with the ease of concomitant bronchography makes the latter a useful adjunct in the subsequent management of those patients found to have bronchiectasis. The minimal yield in patients under the age of 40 years (fig) who have a normal chest radiograph and haemoptysis as their only symptom suggests that bronchography is not worth performing in young adults unless there are additional clinical features of bronchiectasis.

Patients with chronic productive cough but with no haemoptysis and a normal chest radiograph provide an important and difficult problem if there is no recognised cause for their presumed chronic bronchitis. Although the number of such patients submitted for combined bronchoscopy and bronchography in our series is small, the yield of bronchiectasis (five of 12 patients) was surprisingly high, and its demonstration provided considerable help in subsequent management. The radiographic demonstration of changes associated with chronic bronchitis, however, seldom affects management.

It is now our practice to perform bilateral bronchograms if possible in all patients suspected of having bronchiectasis because of either haemoptysis or a chronic productive cough in whom no abnormality is seen at bronchoscopy. The relatively large number of unilateral bronchograms in this series reflects our early and perhaps less confident use of the technique. Our findings substantiate the generally held view that bronchography in addition to bronchoscopy is not a useful method for the diagnosis of bronchial carcinoma if the chest radiograph is normal. Those of our patients in whom a tumour was found at bronchoscopy did not have a bronchogram.

At our hospital most patients with a solitary peripheral pulmonary mass in whom a tissue diagnosis is required are submitted to percutaneous needle biopsy. Those patients with more proximal tumours who are submitted to bronchoscopy do not have bronchograms and are therefore excluded from our series. Patients with persistent pulmonary shadowing in whom a tumour was seen at bronchoscopy do not normally have a bronchogram and are therefore excluded from this review. In eight patients with a bronchial carcinoma and four patients with a benign stricture, however, broncho-

graphy was undertaken to provide an anatomical demonstration of the lesion. Such "mapping" was used especially when the carcinoma or stenosis was at segmental level, and it might also be useful before surgery when a congenital bronchial anomaly is noted at bronchoscopy.

Patients with persistent pulmonary shadowing, particularly when this is associated with some loss of lung volume, form a heterogeneous but important and fairly large group requiring bronchoscopy. In this group we were surprised by the incidence of bronchiectasis (16%), which was not felt to be of the reversible postpneumonic type on clinical and radiographic grounds. The demonstration of bronchial distortion, usually due to loss of parenchymal lung tissue, in a further 20% of patients in this group is less surprising. Our findings in patients with sarcoidosis support the view that bronchial stenoses are perhaps more frequent and widespread than previously believed.<sup>9</sup>

We gratefully acknowledge the assistance of Dr JE Stark and of all the consultants in the chest medicine and surgical units at Papworth Hospital who have allowed us to study their patients. We would also like to thank Mrs A Brodie for typing the manuscript.

## References

- <sup>1</sup> Sagel SS. *Special procedures in chest radiology*. Philadelphia: Saunders, 1976;69-83.
- <sup>2</sup> Strickland B. Radiological examination of the thorax. In: Emerson P, ed. *Thoracic medicine*. London: Butterworths, 1981;130.
- <sup>3</sup> Pinet F, Amiel M, Rubet A, Froment JC. *Selective bronchography and bronchial brushing*. Berlin: Springer-Verlag, 1979.
- <sup>4</sup> Jenkins P, Dick R, Clarke SW. Selective bronchography using the fiberoptic bronchoscope. *Br J Dis Chest* 1982;**76**:88-90.
- <sup>5</sup> Simon G. Radiological changes in chronic bronchitis. *Br J Radiol* 1959;**32**:292-4.
- <sup>6</sup> Nelson SW, Christoforidos A. Reversible bronchiectasis. *Radiology* 1958;**71**:375-82.
- <sup>7</sup> Fraser RG, Pare JAP. *Diagnosis of diseases of the chest*. Philadelphia: Saunders, 1977;1:211-3.
- <sup>8</sup> Forrest JV, Sagel SS, Omell GH. Bronchography in patients with haemoptysis. *Am J Roentgenol* 1976;**126**:597-600.
- <sup>9</sup> Hadfield JWM, Page RC, Flower CDR, Stark JE. Localised airway narrowing in sarcoidosis. *Thorax* 1982;**37**:443-7.