

# Penicillium allergic alveolitis: faulty installation of central heating

RJ FERGUSSON, LJR MILNE, GK CROMPTON

From the Respiratory Unit, Northern General Hospital; and the Mycology Unit, Western General Hospital, Edinburgh

**ABSTRACT** A married couple presented with an illness typical of allergic alveolitis. A careful search of their home revealed a leak in the central heating system with a heavy fungal growth on wet flooring and linoleum. Two species of *Penicillium*, *P chrysogenum* and *P cyclopium*, were isolated from floorboards, linoleum, and settle plates. Antibodies against both these fungi were demonstrated in the serum of both patients by an enzyme linked immunosorbent assay (ELISA). Allergic alveolitis caused by *P chrysogenum* and *P cyclopium* has not been described previously.

The inhalation of many organic dusts is known to cause allergic reaction in the alveoli. Diagnosis of extrinsic allergic alveolitis is sometimes difficult and depends on the recognition of a characteristic clinical illness in a patient exposed to an antigen and the detection of specific antibodies to that antigen.

We describe a married couple who developed features of extrinsic allergic alveolitis after exposure to fungal antigens in their home. Serological tests showed circulating antibodies against *Penicillium chrysogenum* and *P cyclopium*, two fungi which have not been reported as causes of allergic alveolitis.

## Case reports

A previously fit young married couple were admitted to hospital in March 1981 with almost identical symptoms. The husband (case 1) was a 28 year old sales representative for a cosmetic firm. He gave a five week history of influenza like symptoms including malaise, myalgia, headaches, and night sweats and had lost 10 kg in weight over this period. He had exertional dyspnoea and a cough productive of small amounts of mucoid sputum. These symptoms had not responded to oxytetracycline.

His wife (case 2), aged 27 years, was admitted on the same day and had had similar symptoms for four weeks. She had lost 4 kg in weight and had not improved during treatment with oxytetracycline and erythromycin. The couple had an 8 month old

daughter, who was also admitted to hospital and who remained well throughout her parents' illnesses.

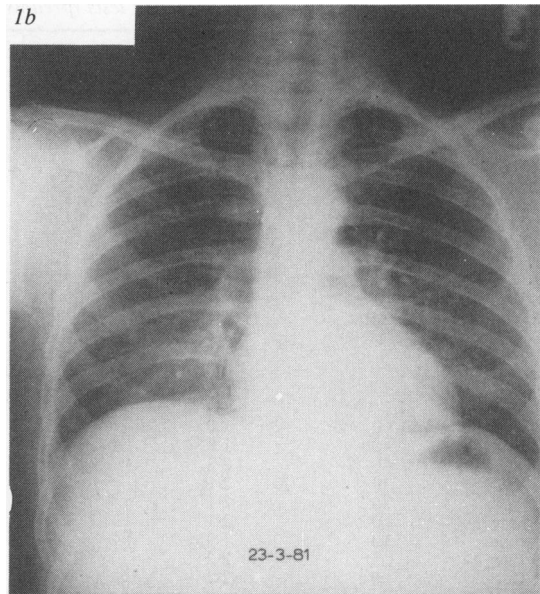
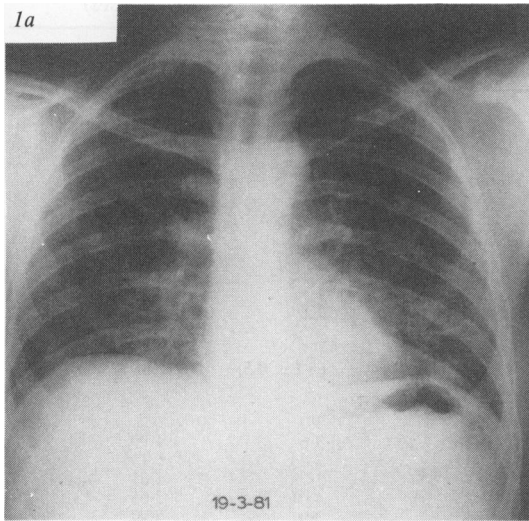
On examination both patients looked well, although the wife was breathless after minimal exertion and had an unproductive cough. Inspiratory crackles were audible over the lung bases in both patients. Chest radiographs (figs 1a and 2a) showed diffuse, ill defined shadowing, predominantly affecting the lower zones. Both had raised total white cell counts with neutrophilia (case 1:  $18.6 \times 10^9/l$  with 74% neutrophils; case 2:  $19.8 \times 10^9/l$  with 86% neutrophils).

Treatment with erythromycin and tetracycline was continued and both patients improved within 24 hours of admission. Chest radiographs three days later (figs 1b and 2b) showed almost complete clearing of the pulmonary shadowing. The neutrophil counts became normal and no rises in serial titres of antibodies to the common respiratory viruses were detected.

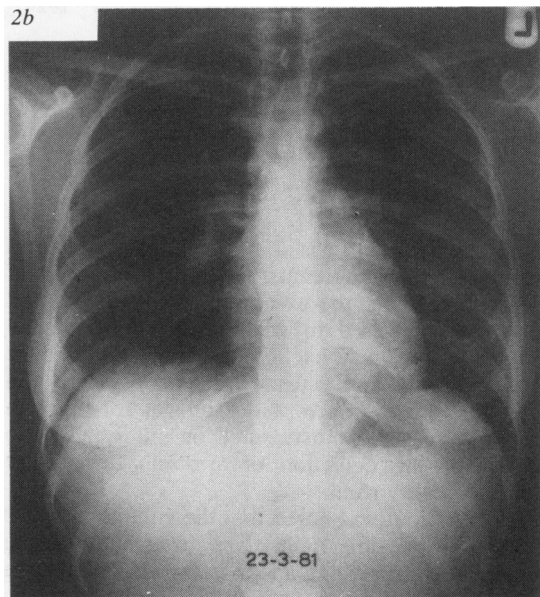
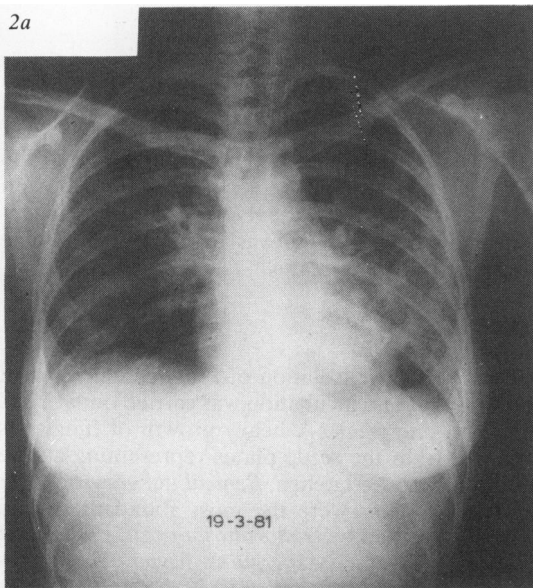
Within 24 hours of discharge, however, dyspnoea, fever, and cough recurred and both patients were readmitted after seven days (on 30 March). The wife was extremely ill with a temperature of  $38.4^\circ\text{C}$ , tachycardia of 120 beats per minute, and grossly abnormal blood gases ( $\text{Po}_2$  5.5 kPa,  $\text{Pco}_2$  4.4 kPa,  $\text{H}^+$  35 nmol/l breathing air). Her husband was less ill although febrile ( $37.6^\circ\text{C}$ ) and breathless on the slightest exertion. Both had basal crackles. Pulmonary function tests (table 1) showed restrictive defects. Neutrophilia had recurred (case 1: WBC  $17.0 \times 10^9/l$  with 82% neutrophils; case 2: WBC  $19.9 \times 10^9/l$  with 84% neutrophils) and chest radiographs of both patients had become abnormal again.

Address for reprint requests: Dr GK Crompton, Respiratory Unit, Northern General Hospital, Edinburgh EH5 2DQ.

Accepted 29 November 1983



**Fig 1** Case 1: Chest radiograph (a) on admission and (b) after four days in hospital.



**Fig 2** Case 2: Chest radiograph (a) on admission and (b) after four days in hospital.

radiographs of both patients had become abnormal again.

Allergic alveolitis was assumed to be the most likely diagnosis and both were treated with prednisolone 40 mg daily (started on 1 April). Rapid improvement followed (table 1), but the wife was left with slight impairment of pulmonary function. After a stay in hospital of 14 days they returned

home and afterwards remained well. Their prednisolone treatment was gradually withdrawn over 10–12 weeks. They are now off treatment and free from symptoms and both have normal chest radiographs.

Repeated careful questioning of both patients failed to elucidate an antigen source. They had no pets. Conventional gas fired central heating had

Table 1 Results of serial pulmonary function tests (prednisolone treatment started on 1 April 1981 in both cases)

Date (1981)	Prednisolone (mg/day)	FEV <sub>1</sub> (l)	FVC (l)	FEV <sub>1</sub> /FVC (%)	TLC (l)	TLCO (mmol min <sup>-1</sup> kPa <sup>-1</sup> )
<b>CASE 1</b>						
Predicted normal		(4.2 ± 0.5)	(5.0 ± 0.6)	(81.7)	(6.9 ± 0.9)	(11.6 ± 1.7)
30 March (on readmission) 0						
6 April	40	1.85	2.2	84	4.88	4.99
8 "	40	3.2	4.2	75	6.12	7.62
10 "	40	3.75	4.65	81	6.3	6.72
16 "	30	4.3	5.2	82	6.86	8.18
20 "	30	4.4	5.3	83	7.5	8.29
20 "	20	4.65	5.5	85	7.3	9.9
15 May	10	4.3	5.4	80	7.3	8.43
12 June	0	4.6	5.7	81	7.1	8.58
<b>CASE 2</b>						
Predicted normal		(2.8 ± 0.4)	(3.3 ± 0.4)	(85 ± 5)	(5.1 ± 0.5)	(9.1 ± 1.2)
31 March (on readmission) 0						
7 April	40	1.0	1.35	74	3.0	?
10 "	40	1.85	2.2	84	3.6	4.99
16 "	40	2.2	2.6	85	3.84	5.1
16 "	30	2.1	2.4	87	3.78	4.61
20 "	20	2.1	2.4	87	4.01	5.65
15 May	10	2.1	2.45	86	3.9	5.97
11 June	10	1.95	2.3	85	4.12	4.42
10 July	5	2.2	2.5	88	4.0	4.5
11 Dec	0	2.2	2.6	85	4.5	6.6

FVC—forced vital capacity; TLC—total lung capacity; TLCO—transfer factor.

Conversion: SI to traditional units—TLCO: 1 mmol min<sup>-1</sup> kPa<sup>-1</sup> = 2.99 ml/min/mm Hg.

been installed in their home eight months before their illnesses. Their house was, however, visited during their second admission, in an attempt to locate a possible antigen.

### Domiciliary visit

The patients' home was a stone built, mid-terrace, single story dwelling constructed about the turn of the century. With the exception of the kitchen, all rooms were entered directly from the entrance hall at the front of the house. Examination of the house interior revealed no unusual contents, pets, etc, and there was no evidence of dry or wet rot—though there was a slight musty smell on entering. Settle plates for the detection of airborne fungi were placed in every room.

In the attic it was noted that the volume of water in the expansion tank was constantly being replenished, suggesting a leak in the central heating system. On removal of the floor coverings of the entrance hall, a large area of wet, mouldy floor was exposed. Inspection of the underlying construction revealed a jet of water escaping under pressure from an improperly soldered capillary fitting in one of the main supply pipes. The floor joists and floor boards were saturated but seepage through to the carpet had been prevented by linoleum (fig 3). The under surface of the linoleum and the wet wood which was not directly exposed to the jet of water showed obvious fungal colonisation. Swabs from the sur-

faces, the settle plates, and samples of the colonised linoleum were taken back to the laboratory for mycological investigation.

The leaking pipe was promptly repaired and the damaged flooring was replaced and treated with fungicide before the patients' return home. Detection of airborne moulds was repeated at this time with identical settle plates.

### Mycology

All plates for the isolation of fungi contained malt peptone agar and incubation was carried out at 22°C for up to one week. A heavy growth of fungi was obtained from the settle plates representing all the rooms except the kitchen. *Penicillium chrysogenum* and *P cyclopium* were the most abundant species present, followed by *Dimorphospora* sp, *Epicoccum* sp, *Mucor* sp, and *Aspergillus flavus*. The swabs taken from the colonised wooden surfaces grew the first four species. Direct observation of the under surface of the linoleum showed a predominance of *Penicillium* species and this was confirmed in the growth obtained from samples taken from typical areas. *P chrysogenum*, *P cyclopium*, *Dimorphospora* sp, *Epicoccum* sp and *Paecilomyces* sp were isolated. Since the first four of these species were common to all three types of sample, these were selected for the production of antigenic material. Individual species were inoculated into Sabouraud broth in Roux bottles and incubated for six weeks at 22°C. The



Fig 3 *The patients' hall with wet flooring and mouldy linoleum (photograph taken 24 hours after the leak was discovered).*

culture filtrates were dialysed against running water for 24 hours, concentrated with polyethylene glycol 6000, and finally freeze dried before being reconstituted for skin testing and serological studies.

There was an appreciable reduction in air borne fungi detected by settle plates placed in the house after repairs to the piping and flooring had been completed.

**Serology**

Double diffusion agar plates failed to demonstrate

the presence of precipitating antibodies to the four fungal antigens when these were tested at various concentrations. No attempt was made to concentrate the sera. The serum of both patients was then examined for fungal precipitins with an enzyme linked immunosorbent assay (ELISA). Flat bottomed polystyrene microplates were coated with the fungal antigens extracted from *P chrysogenum*, *P cyclopium*, *Dimorphospora* sp, and *Epicoccum* sp. Serum samples from both patients were titred from 1/128 to 1/1024 by serial dilution. Pooled normal human sera from 10 healthy donors were used as a

Table 2 *ELISA (enzyme linked immunosorbent assay) results: average optical density (OD<sub>400</sub>) values for both patients' serum and those of "normal" serum from healthy blood donors at increasing serum dilutions*

CASE 1		Serum dilution			
		1/128	1/245	1/512	1/1024
<i>Penicillium chrysogenum</i>	Patient	0.242	0.205	0.190	0.153
	Normal	0.118	0.091	0.050	0.033
<i>P cyclopium</i>	Patient	0.338	0.294	0.218	0.151
	Normal	0.350	0.201	0.123	0.050
<i>Dimorphospora</i> sp	Patient	0.146	0.119	0.066	0.046
	Normal	0.226	0.127	0.070	0.054
<i>Epicoccum</i> sp	Patient	0.091	0.065	0.043	0.037
	Normal	0.125	0.090	0.080	0.045
CASE 2					
<i>P chrysogenum</i>	Patient	0.484	0.413	0.389	0.215
	Normal	0.092	0.070	0.048	0.030
<i>P cyclopium</i>	Patient	0.427	0.256	0.246	0.151
	Normal	0.280	0.191	0.108	0.074
<i>Dimorphospora</i> sp	Patient	0.178	0.117	0.085	0.062
	Normal	0.143	0.110	0.065	0.038
<i>Epicoccum</i> sp	Patient	0.084	0.074	0.033	0.023
	Normal	0.056	0.044	0.025	0.017

control in the appropriate dilution on each plate. All tests were performed in duplicate. The optical density results from the ELISA assays are shown in table 2. Serum from both patients showed evidence of circulating antibodies to both species of *Penicillium*, especially at high serum dilutions. The optical density values from the assays involving *Dimorphospora* sp and *Epicoccum* sp did not differ significantly from the values obtained for the pooled normal sera.

Skinprick tests were performed using the same four fungal antigens and controls. Both patients showed a strong early (20 minute) reaction to *P chrysogenum* and the wife had a similar early reaction to *P cyclopium*. No reactions were seen to *Dimorphospora* sp or *Epicoccum* sp. There were no late (4–6 hour) reactions to any antigens. A group of eight normal subjects (four atopic, four non-atopic) had negative skin test responses to the same *Penicillium* antigens.

### Discussion

Allergic alveolitis due to a *Penicillium* species (*P casei*) was first described<sup>1</sup> in subjects who washed mould from cheese. Suberosis<sup>2</sup> is a similar illness seen in workers in the cork industry and is due to the inhalation of *P frequentans*, which can contaminate cork dust. Solley and Hyatt<sup>3</sup> described an entomologist with allergic alveolitis who was exposed to several species of fungi at his work, including *Penicillium* sp, as well as to mists generated by reservoir type humidifiers. He had serological evidence of an immune response to *Penicillium* sp and humidifier water antigens. Responses to inhalation provocation tests with both groups of antigens were positive.

Our patients had clinical illnesses typical of allergic alveolitis, which appeared to be provoked by an agent, or agents, in their home. Careful search of their house revealed a leak in the central heating system, which had led to a heavy fungal growth on wet flooring and linoleum. Settle plates from all but one room produced heavy fungal growths, suggesting high air borne spore concentrations. Four species of fungi were isolated from floor boards, linoleum, and settle plates. Circulating antibodies against two of these (*P chrysogenum* and *P cyclopium*) were demonstrated in both patients by an

enzyme linked immunosorbent assay and both patients had positive early skinprick test reactions to antigens prepared from these fungi. We believe therefore that these fungi are most likely to be the allergens responsible for the disease, which did not recur after the leak had been repaired and contaminated flooring had been replaced before the patients' return home.

The ELISA technique has been used in the diagnosis of fungal infections<sup>4</sup> and more recently to detect antibodies to pigeon antigens in pigeon breeders.<sup>5</sup> It appears to be more sensitive in the detection of fungal antibodies than passive haemagglutination.<sup>4</sup> Although circulating antibodies present in other forms of extrinsic allergic alveolitis are also found in a proportion of exposed but unaffected individuals, we believe that the positive results obtained in the present cases add some support to the suggestion that *Penicillium* hypersensitivity is the most likely cause of our patients' illness. The diagnosis was not initially made because of the simultaneous development of respiratory symptoms in the two patients, associated with pyrexia and leucocytosis, which suggested infection rather than allergy. *Penicillium* species are common fungi to which most of us are repeatedly exposed and allergic alveolitis caused by inhalation of large numbers of fungal spores may be more common than we believe.

### References

- <sup>1</sup> Deweck AL, Gutersohn J, Butikofen E. La maladie des laveurs de fromage ("Käsewascherkeit"): une forme particulière du syndrome du poumon du fermier. *Schweiz Med Wochenschr* 1969;**99**:872–6.
- <sup>2</sup> Aliva R, Lacey J. The role of *Penicillium frequentans* in suberosis; respiratory disease in workers in the cork industry. *Clin Allergy* 1974;**4**:109–117.
- <sup>3</sup> Solley GO, Hyatt RE. Hypersensitivity pneumonitis induced by *Penicillium* species. *J Allergy Clin Immunol* 1980;**65**:65–70.
- <sup>4</sup> Carlsson HE, Lindberg AA. Application of enzyme immunoassay for diagnosis of bacterial and mycotic infections. *Scand J Immunol* 1978;**8**, suppl 7: 97–110.
- <sup>5</sup> Andersen P, Christensen KM, Jensen BE, et al. Antibodies to pigeon antigens in pigeon breeders. Detection of antibodies by an enzyme-linked immunosorbent assay. *Eur J Respir Dis* 1982;**63**:113–21.