

Silicosis in barium miners

A SEATON, VA RUCKLEY, J ADDISON, W RHIND BROWN

From the Institute of Occupational Medicine, Edinburgh, and the Medical Boarding Centre (Respiratory Diseases), Department of Health and Social Security, Glasgow

ABSTRACT Four men who mined barytes in Scotland and who developed pneumoconiosis are described. Three developed progressive massive fibrosis, from which two died; and one developed a nodular simple pneumoconiosis after leaving the industry. The radiological and pathological features of the men's lungs were those of silicosis and high proportions of quartz were found in two of them post mortem. The quartz was inhaled from rocks associated with the barytes in the mines. The features of silicosis in barium miners are contrasted with the benign pneumoconiosis, baritosis, that occurs in workers exposed to crushed and ground insoluble barium salts. Diagnostic difficulties arise when silicosis develops in workers mining minerals known to cause a separate and benign pneumoconiosis. These difficulties are compounded when, as not infrequently happens, the silicotic lesions develop or progress after exposure to quartz has ceased.

Most of the world's barium comes from the United States, Germany, and the Soviet Union, though some is still mined in Eire, the Midlands of England, and Scotland. In the past it has been mined, sometimes as a byproduct of coal or fluorspar mining, in Northumberland and Derbyshire. Some increased production has occurred recently in Scotland in relation to its use in drilling muds for the North Sea oil industry. The benign pneumoconiosis baritosis is well described in workers who crush and grind barium compounds.¹⁻³ Barium miners, however, may be exposed to minerals other than the barytes (barium sulphate) or witherite (barium carbonate) that they are producing. If these minerals include quartz, the miners are at risk of silicosis.

We have recently had the opportunity of examining the records and chest radiographs of some barium miners from two now defunct Scottish barium mines. All men were receiving pneumoconiosis disablement benefit from the Department of Health and Social Security, who made their records available to us. We were also able to make detailed examinations of the lungs of two of these men.

Subjects

Patient 1 started work as a dairy farmhand in 1920. From 1925 to 1952 he worked in a barytes mine in

Ayrshire, Scotland, tunnelling, mining, and drilling. He smoked up to 40 cigarettes daily. In 1952 he suffered multiple injuries and a chest radiograph showed stage B progressive massive fibrosis on a background of simple pneumoconiosis, category 3/3r. He transferred to light surface work until 1961, when he had to retire because of increasing respiratory disability and the onset of right sided heart failure. The lesions of progressive massive fibrosis on his chest radiographs enlarged progressively and became associated with bullous emphysema (fig 1). Tubercle bacilli were never isolated from his sputum. He died in 1980, aged 74, of cardiorespiratory failure and his lungs were obtained by the former Glasgow Pneumoconiosis Medical Panel.

Patient 2 worked from 1931 to 1937 edging blaes bricks and from 1937 to 1945 mixing cement on building sites (interrupted by six years' war service). From 1945 to 1950 and from 1972 to 1977 he was a labourer in a steel works, but from 1956 to 1967 he worked as a shot firer in an Ayrshire barytes mine. He was a lifelong non-smoker. In 1971 he had a chest radiograph that showed some category 0/1 simple pneumoconiosis only, but by 1974 these changes had progressed to progressive massive fibrosis. Tuberculosis was suspected (and chemotherapy prescribed) but not confirmed bacteriologically. The fibrosis increased in size and density, contracting the upper zones and being associated with extensive lower zone emphysema (fig 2). In 1980 he was admitted to hospital in cardiorespiratory failure and with a pneumothorax. He recovered but shortly after discharge developed another pneumothorax, which caused his

Address for reprint requests: Dr A Seaton, Institute of Occupational Medicine, 8 Roxburgh Place, Edinburgh EH8 9SU.

Accepted 13 January 1986

death. His lungs were obtained by the former Pneumoconiosis Medical Panel, Glasgow.

Patient 3 was a barytes miner from 1923 to 1946. He worked on the surface screens of a coalmine from 1914 to 1923 and from 1946 to 1965. He smoked 15–20 cigarettes daily and suffered from shortness of breath attributed to airflow obstruction. Chest radiographs taken from 1959 to 1968 showed simple pneumoconiosis of the nodular r type characteristic of silicosis, without any progression to progressive massive fibrosis over this period but out of proportion to any changes that might be expected in someone exposed to coal dust on surface screens. He died in 1969 of myocardial infarction, aged 68. Necropsy showed typical silicotic lesions in his lungs, with relatively sparse pigmented coal macules (fig 3).

Patient 4 worked as a coalminer from 1914 to 1924 and in barium mines from 1924 to 1958. He then worked at the surface of a barium mine until 1963. He smoked 20 cigarettes daily. He suffered from chronic cough and sputum and latterly developed angina and renal failure, from which he died in 1978. A chest radiograph taken in 1958 showed category 1/0 simple pneumoconiosis of nodular r type. This had progressed to progressive massive fibrosis associated with bullous emphysema by the time of his final illness (fig 4).

Methods

The lungs of patients 1 and 2 had been inflated and

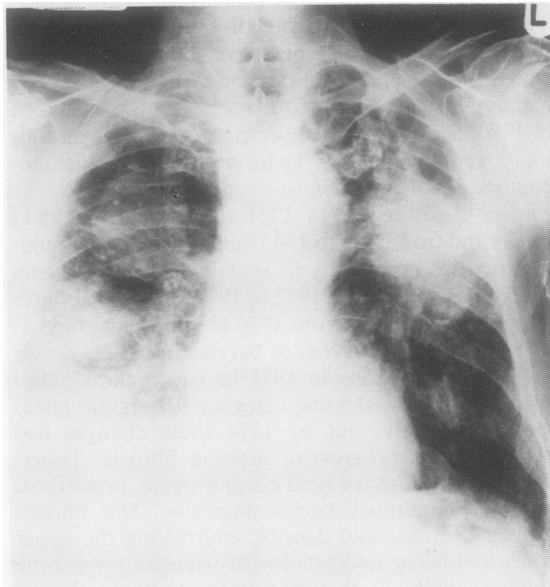


Fig 1 Posteroanterior radiograph of patient 1 showing bilateral massive fibrosis with associated bullous emphysema; pleural thickening is present in the right lower zone.

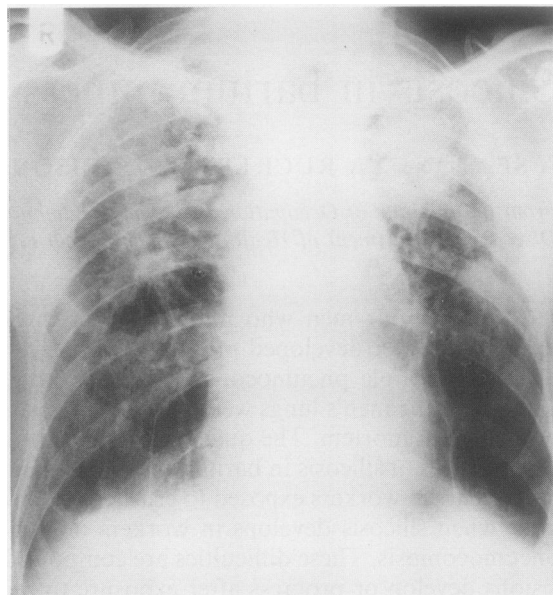


Fig 2 Posteroanterior radiograph of patient 2 showing bilateral upper zone progressive massive fibrosis with lower zone emphysema.

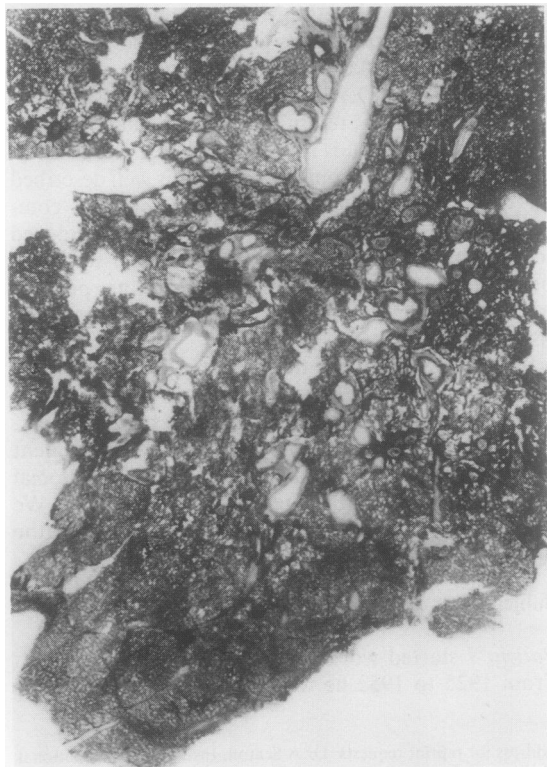

Fig 3 Part of whole lung slice from patient 3 showing silicotic nodules. Some soft coal macules are also present at the base.

fixed in formaldehyde. Material for microscopic examination was taken from both lungs of each subject, stained by haematoxylin and eosin, by Van-Gieson's method for collagen and by the method of Gordon and Sweet for reticulin. Gough-Wentworth sections were made from a representative slice of each lung.

Two samples of fibrotic material were taken from one lung of each pair for dust analysis. One sample was digested in 6N hydrochloric acid. The recovered dust was dried, weighed, and incinerated at 350°C. The resulting ash was analysed by infrared spectrophotometry for determination of quartz, kaolinite, and mica content, and was then examined qualitatively by x ray diffractometry. The other sample was incinerated in low temperature oxygen plasma and the ash examined by x ray diffractometry.

Results

PATHOLOGY

Patient 1 There was considerable visceral pleural thickening over the upper half of both lungs, the extensive smooth, greyish plaque showing rib impressions. Figure 5 shows a Gough-Wentworth section of the left lung. The apices of both lobes are replaced by large circumscribed fibrotic lesions that show central necrosis. In addition, small numbers of fibrotic nodules, 1–3 mm in size, are scattered throughout the lung but with a tendency to concentrate round the massive fibrosis. Basal panacinar emphysema, showing little

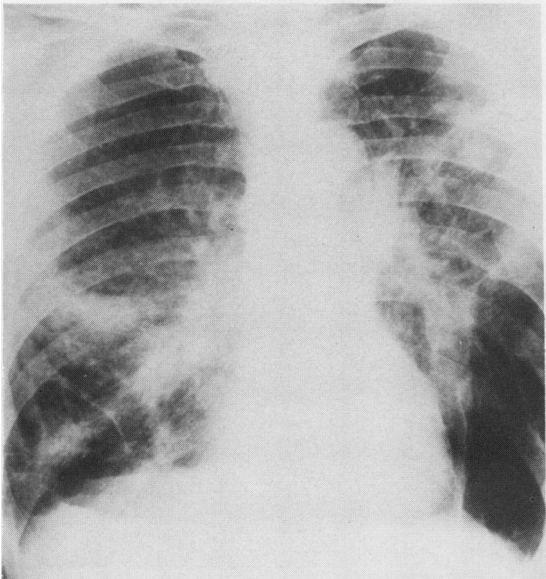


Fig 4 Posteroanterior radiograph of patient 4 showing bilateral progressive massive fibrosis and bullous emphysema.

pigmentation, and apical bullae are also present. The microscopic appearances were consistent with silicosis.

Patient 2 The lungs showed massive fibrosis occupying the apices of both lobes of the left lung and extending out from the hilum into the upper lobe of the right lung. The lesions incorporated small patent vessels and bronchi, and there was no obvious necrosis. As in the lungs of the other patient, a few small fibrotic lesions were also present. Both lung bases showed panacinar emphysema, which was also quite extensive and associated with bullae in the right middle lobe. Histological examination again showed a silicotic reaction.

DUST ANALYSES

The results of infrared analysis of material from the fibrotic lesions are shown in the table.

The lung sample from patient 1 contained a mineral assemblage which, apart from the high quartz content, was similar to that found in some coal-workers' lungs. In addition, the x ray diffraction analysis of the low temperature ash sample indicated the presence of bassanite ($\text{CaSO}_4 \cdot \frac{1}{2}\text{H}_2\text{O}$) and hydroxyapatite ($\text{Ca}_5(\text{PO}_4)_3(\text{OH})$). The bassanite may have

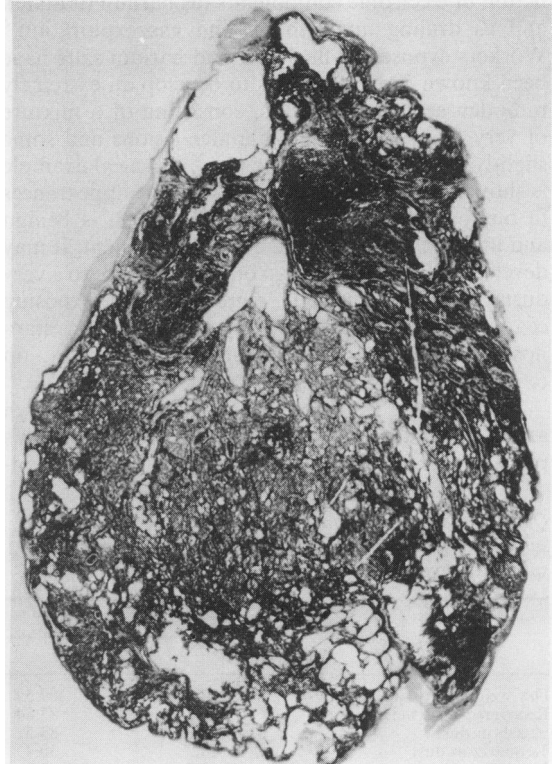


Fig 5 Whole lung slice of patient 1 showing upper lobe to be replaced by massive fibrosis.

been gypsum ($\text{CaSO}_4 \cdot \text{H}_2\text{O}$) altered during low temperature ashing. No barium or barium mineral was found.

The lung sample from patient 2 showed a greater total amount of dust with an even higher quartz content, accounting for 30% of the total dust. The proportions of kaolinite and mica were small and more than half the ash content of the dust was not identified by infrared analysis. The x ray diffraction investigation confirmed the high quartz content and also indicated the presence of a large proportion of orthoclase ($\text{KA1 Si}_3\text{O}_8$), with some plagioclase ($\text{NaAlSi}_3\text{O}_8$). These would probably account for most of the material that remained unidentified by infrared analysis. The x ray diffraction traces of the dust removed by acid digestion and by low temperature ashing were identical. Again, no barium minerals were identified.

Discussion

Barium is usually mined as barytes and occasionally as witherite. These minerals, after crushing and washing, have multiple uses in, for example, manufacture of paints, paper, ceramics, glass, and rubber; production of electronic components (as barium titanate); and as drilling muds in oil and gas exploration.⁴ Workers exposed to finely ground barium salts have been known for many years to develop an extremely radiodense pneumoconiosis, consisting of a mixture of very fine punctate and annular lesions and some slightly larger nodular lesions.¹⁻³ A typical example is shown in figure 6 to contrast with the appearances in our patients. This condition, baritosis, is benign and unassociated with functional impairment. It may develop within a year or two of first exposure to a very dusty environment, but regresses after exposure ceases.³ In these features it closely resembles stannosis, the benign pneumoconiosis caused by tin oxide.^{5,6}

The striking radiodensity is related to the high atomic weight of barium, while the benign course is probably due to the extreme insolubility and non-

toxic nature of the sulphate and carbonate salts; experimental studies have confirmed the lack of a fibrotic response to inhaled barium sulphate.⁷ In striking contrast to the benign picture of baritosis, the patients we describe had a severe—in two cases fatal—form of pneumoconiosis. Three developed massive fibrosis and one had a progressive simple silicosis. The pathological findings confirmed the presence of silicosis and the lung analyses showed quartz to have been the cause. The complete absence of barium in the lungs was interesting, and suggests that much of the barium that is inhaled is not taken into the pulmonary tissues but remains in alveolar macrophages and is eventually removed by the mucociliary mechanism. Otherwise some barium would be expected to have been retained within the fibrotic masses. Detailed examination of the radiological appearances of baritosis (fig 6) suggests that most of the barium may well have been intra-alveolar in these patients.

Miners of many minerals are exposed to a risk of silicosis from quartz inhalation. In the case of patient 1, while the seam he worked in was said to be free of quartz, the associated rocks are described as beds of hard, limy quartzose sandstone⁸; in addition, rock debris and boulder clay would have been cut for filling worked out parts of the mine. Thus we may reasonably suppose that the dust he breathed in the mine contained quartz. In the case of patient 2, the seam in which he worked was known to contain varying

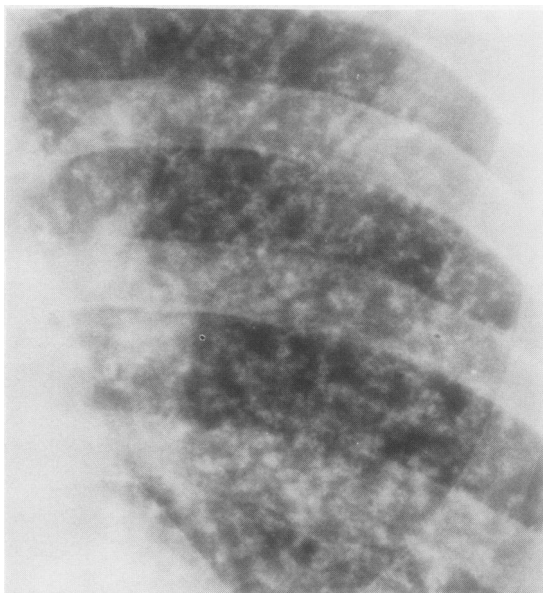


Fig 6 Close up view of radiograph of a man with baritosis, showing fine nodular and small ring shadows suggestive of intra-alveolar and intrabronchiolar deposition of dust.

Quartz, kaolinite, and mica content of ash recovered from samples of massive fibrosis and analysed by infrared spectrophotometry

	Patient No	
	1	2
Dry weight of tissue (mg)	229.15	409.59
Recovered dust weight (mg)	10.85	83.84
% ash in dust	79.8	83.5
% quartz in dust	23.2	30.4
% kaolinite in dust	7.7	2.1
% mica in dust	28.5	4.7

amounts of quartz and his work as a shot firer would have ensured that he was exposed to it. The orthoclase and plagioclase in his lungs were presumably derived either from work with rocks associated with the barytes or from dust in the brick works.

Silicosis is a progressive disease. The small nodular lesions tend to increase in size and conglomerate to form the larger masses of progressive massive fibrosis. These processes may occur even after dust exposure has ceased, as in the case of patient 2, whose chest film was within normal limits when he left the industry. Similarly, in the case of patient 1, although he was exposed to coal dust after he left the barium mines, the pneumoconiosis he developed was silicosis and it first appeared after exposure to quartz had ceased. This appearance and progression of silicosis after retirement from the relevant jobs is little appreciated by chest physicians and may cause diagnostic confusion. Even in the much less progressive condition coalworkers' pneumoconiosis, progressive massive fibrosis still occurs not infrequently after men have retired, although the small nodular opacities do not alter.⁹

These four patients serve as a reminder that workers exposed to a mineral may suffer different effects depending on whether they are mining it or inhaling the crushed and ground material. Workers mining almost any material may be at risk of silicosis if quartz dust is present in the air they breathe. This is true whether the mineral sought is itself benign, such as tin⁶ or barium, mildly fibrogenic, such as coal,¹⁰ or highly toxic, such as asbestos.¹¹ The first report of pneumoconiosis in a barium miner, by Fiori in 1926,³ was probably of a case of silicosis. Since then all reports save one have been of benign baritosis.¹² It is important to remember that miners are often exposed to quartz and at risk of silicosis.

We thank Drs NE Cunningham and LH Kissen, consultant pathologists at Crosshouse Hospital, Kilmar-

nock, for notifying our department of the cases and Dr Peter Greenfield, Chief Medical Adviser (Social Security) at the Department of Health and Social Security, for permitting WRB to participate. We are also grateful to Mr RH Porteous for his technical help.

References

- 1 Pendergrass EP, Greening RR. Baritosis: report of a case. *AMA Arch Ind Hyg Occ Med* 1953;7:44-8.
- 2 Léi-Valensi P, Drif M, Dat A, Hadjadj G. A propos de 57 observations de barytose pulmonaire (résultats et une enquête systématique dans une usine de baryte). *J Fr Med Chir Thorac* 1966;20:443-54.
- 3 Doig AT. Baritosis: a benign pneumoconiosis. *Thorax* 1976;31:30-9.
- 4 Collins RS. *Barium minerals*. London: HMSO, 1972. (Mineral dossier No 2: Mineral Resources Consultative Committee.)
- 5 Robertson AJ, Whittaker PH. Radiological changes in pneumoconiosis due to tin oxide. *J Fac Radiol* 1954;6:224-33.
- 6 Robertson AJ, Rivers D, Nagelschmidt G, Duncomb P. Stannosis: benign pneumoconiosis due to tin oxide. *Lancet* 1961;ii:1089-93.
- 7 Huston J, Wallach DP, Cunningham GJ. Pulmonary reactions to barium sulphate in rats. *Arch Pathol* 1952;54:430-8.
- 8 MacGregor AG, MacGregor M, Robertson T. *Barytes in Central Scotland. Geological survey of Great Britain: Scotland*. London: Department of Scientific and Industrial Research, 1941. (Wartime pamphlet No 38.)
- 9 Maclaren WM, Soutar CA. Progressive massive fibrosis and simple pneumoconiosis in ex-miners. *Br J Ind Med* 1985;42:734-40.
- 10 Seaton A, Dick JA, Dodgson J, Jacobsen M. Quartz and pneumoconiosis in coalminers. *Lancet* 1981;ii:1272-5.
- 11 McNulty JC. Asbestos mining at Wittenoon, Western Australia. In: *First Australian Pneumoconiosis Conference*. Sydney: Joint Coal Board, 1968:447-74.
- 12 Parkes WR. *Occupational lung disorders*. 2nd ed. London: Butterworths, 1982:120.