

# Anesthesia Experience for Open Gastrostomy With Ultrasound-Guided Unilateral Subcostal Transversus Abdominis Plane Block in a High Risk Elderly Patient: A Case Report

Ae Ryoung Lee<sup>1</sup>; Yun Suk Choe<sup>1,\*</sup>

<sup>1</sup>Department of Anesthesiology and Pain Medicine, Jeju National University Hospital, Jeju National University, Jeju, South Korea

\*Corresponding author: Yun Suk Choe, Department of Anesthesiology and Pain Medicine, Jeju National University Hospital, Jeju National University, P.O. Box: 690-767, Jeju, South Korea. Tel: +82-647171810, Fax: +82-647172042, E-mail: solafide5@jejunuh.co.kr

Received: November 4, 2014; Revised: January 29, 2015; Accepted: February 25, 2015

**Introduction:** Many papers have reported that TAP block provides effective postoperative analgesia, but the sole use of TAP block for surgical anesthesia has been rarely reported.

**Case Presentation:** Therefore, we presented an 80-year-old male undergoing ultrasound-guided unilateral subcostal TAP block providing surgical anesthesia for open gastrostomy. Left subcostal TAP block was performed using the method described by Hebbard with the M-Turbo<sup>®</sup> ultrasound system and a linear probe placing immediately inferior and parallel to the costal margin. Using a 100-mm long, 23 G short-bevel needle in-plane technique, 20 mL of 0.25% levobupivacaine was injected on the TAP. A sensory block from T7 to T11 was established and the satisfaction score was 7-8.

**Conclusions:** Open gastrostomy was successfully performed under subcostal TAP block with small dose fentanyl supplementation. The subcostal TAP block is considered a useful anesthetic choice in surgery for high risk patients.

**Keywords:** Gastrostomy; Nerve Block; Abdominal Muscles

## 1. Introduction

The choice of anesthetic technique in elderly high risk patients should be determined by evaluating their clinical status and invasiveness of surgery. For open gastrostomy, a small vertical incision in upper abdomen is performed and the seromuscular layers from the anterior abdominal wall to stomach are manipulated. Open gastrostomy induces localized pain on incision site, mainly somatic component.

Recently, the role of regional anesthetic techniques has been increased according to widely spread of minimally invasive surgical procedures. Transversus Abdominis Plane (TAP) block involves infiltration of local anesthetic in the plane between the internal oblique and transversus abdominis muscles. Many previous papers already reported that TAP block provides effective postoperative analgesia following various abdominal surgeries (1), but the sole use of TAP block for surgical anesthesia has been rarely reported (2). Therefore, we presented a case of ultrasound-guided unilateral subcostal TAP block providing surgical anesthesia for open gastrostomy.

## 2. Case Presentation

An 80-year-old male (164 cm, 47.9 kg) was admitted to our hospital due to dysphagia and frequent aspiration pneu-

monia. On admission, oxygen saturation was low (SpO<sub>2</sub> 85 - 88%) and arterial blood gas analysis revealed PH 7.507, PCO<sub>2</sub> 32.6 mmHg, PO<sub>2</sub> 46.8 mmHg, HCO<sub>3</sub> 26.9 mmol/L and oxygen saturation 84.5%. He received 3 L/min oxygen via tracheostomy cannula and subsequently treated with antibiotics for the treatment of pneumonia. He was scheduled for an open gastrostomy to provide nutritional support. However, percutaneous endoscopic gastrostomy was not suitable for him, because he received subtotal gastrectomy and colon transposition ten year ago.

He had hypertension, diabetes mellitus, CAG and PCI due to ischemic heart disease, spinal stenosis and a history of cerebral infarction. He was hemodynamically stable and except for raised blood sugar in the range of 12.7 - 19.4 mmol/L C-reactive protein (CRP) of 2.23 and erythrocyte sedimentation rate (ESR) of 117, all other routine blood investigations including complete blood cell count, coagulation profiles and biochemical assays had normal findings. Electrocardiography (ECG) showed anterolateral ischemia and echocardiography report showed an ejection fraction of 35% and hypokinesia on anterolateral wall. Chest x-ray showed peribronchial infiltration in the right upper and both lower lung zone suggesting aspiration pneumonia and bronchiolitis. His medications included aspirin, clopidogrel, amiloride, furosemide and insulin.

After obtaining a written informed consent about subcostal TAP block, the patient was placed in the supine position. An aseptic skin preparation was performed and left subcostal TAP block was performed using the method described by Hebbard (3), using the M-Turbo® ultrasound system (Sonosite, Bothell, WA, USA) with a high-frequency linear array transducer (HFL38x, 13 - 6 MHz). The ultrasound probe was covered with a protective plastic sheath and placed over the anterior abdominal wall immediately inferior and parallel to the costal margin. The external oblique, internal oblique and transversus abdominis muscles were identified and the TAP was noted between inner two muscle layers. Local infiltration was performed with 1 - 2 mL of 2% lidocaine at the needle entry site. A 100-mm long, 23 G short-bevel needle (Stimuplex, B. Braun, Melsungen, Germany) was advanced using an in-plane technique from an initial anteromedial position at skin entry, to a more posterolateral position in the TAP. Test injection with 1 mL of 0.9% normal saline was performed to confirm the needle location. After aspiration to avoid intravascular placement, 20 mL of 0.25% levobupivacaine (Chirocaine®, AstraZeneca) was injected on the TAP while observing the expansion of intermuscular plane by the injectate. Successful injection was confirmed by an echo-lucent lens-shaped space between the two muscles (Figure 1). After 20 min, the sensory block levels were assessed using a cold swab and pinprick and was established from T7 to T11.

The patient received 6 L/min oxygen supply via tracheostomy cannula. A 5 cm vertical incision was performed at left upper quadrant and carried into the peritoneal cavity. Before peritoneal manipulation, patient's pain score remained 0 - 1. Peritoneal adhesions due to previous abdominal operation induced intensive bowel

manipulation, so the patient complained abdominal discomfort and two times of 25 µg fentanyl were administered intravenously. The duration of operation was 30 min and there were no surgical complications. Intraoperative vital signs were stable. Patient remained pain free in the postanesthetic care unit and discharged to the ward and gastrostomy feeding commenced 24 hours after the procedure. Satisfaction scores were evaluated the next day using a scale of 0 - 10 and were 7 - 8.

### 3. Discussion

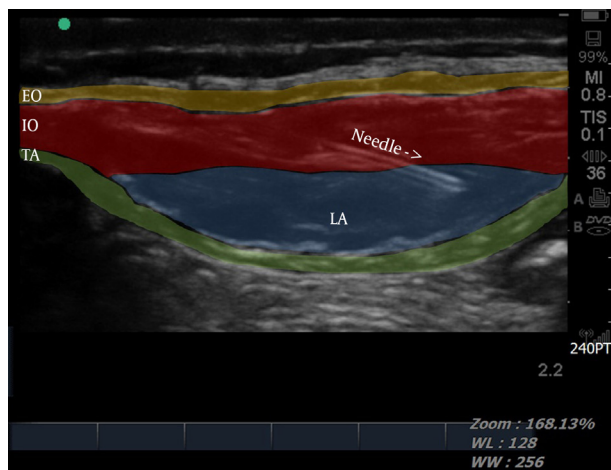
TAP block was first described by Rafi (4) and works on thoracolumbar sensory afferent nerves (T6-L1), which innervates the anterior abdominal wall. Posterior (conventional) and subcostal approach was the most commonly used technique of TAP block. Comparing the sensory block extent between the two TAP blocks, the subcostal TAP block was associated with higher level (T8) than the posterior TAP block (T10) (5). Therefore, the subcostal TAP block is more appropriate for patients having incision above the umbilicus.

To date, TAP block has been demonstrated as successful as an adjunct for postoperative analgesia following various abdominal surgeries such as appendectomy (6), hysterectomy (7), caesarean section (8) and cholecystectomy (9). The use of real-time ultrasound permits precise and reliable deposition of local anesthetics within the target plane and improves the efficacy of TAP block. Recently, some cases reported the use of TAP block for surgical anesthesia (1, 2). Hasan et al. (2) reported five case series that open gastrostomy was successfully performed under bilateral subcostal TAP block. Among them, only one patient needed local anesthetic injection on the superior end of the surgical incision. In their cases, upper midline incision was performed for open gastrostomy, but our patient received vertical incision on left upper quadrant abdomen, so unilateral subcostal TAP block was enough for surgical anesthesia.

Open gastrostomy may be required to provide nutritional support when percutaneous endoscopic gastrostomy is not possible. Patients undergoing open gastrostomy commonly have neuromuscular disorders, cerebrovascular accident or compromised respiratory function due to frequent aspiration. They might have increased risk of bleeding due to anticoagulation and increased susceptibility of sedative drugs or anesthetic agent, inducing spinal hematoma, aspiration pneumonia or malignant hyperthermia. In our case, the patient received aspirin and clopidogrel due to ischemic heart disease and cerebrovascular accident and diagnosed aspiration pneumonia due to frequent aspiration.

Some literatures reported that open gastrostomy was successfully performed under local anesthesia (10). Nevertheless, our surgeon considered the possibility of peritoneal adhesion, because the patient had undergone subtotal gastrectomy and colon transposition, so he

**Figure 1.** An Ultrasound of Abdominal Muscles and Fascia After Injection of 20 mL of Local Anesthetic



SC: subcutaneous tissue, EOM: external oblique muscle, IOM: internal oblique muscle, TAM: transversus abdominal muscle.

planned larger incision than usual and worried that the local anesthesia might not be enough. Sivapurapu et al. (11) reported that TAP block provided a longer duration and better quality of analgesia with lesser sedation and decreased incidence of post-operative nausea and vomiting (PONV), compared with local infiltration into surgical incision in gynecology surgeries. In a systematic review about incisional local anesthesia after abdominal operations, Moiniche et al. (12) concluded that incisional local anesthesia was not an effective method for postoperative analgesia. The authors deduced that the transversus abdominis neurofascial plane might act as a depot for local anesthetics, whereas surgical incision might increase blood supply and lead to faster local anesthetic absorption and metabolism (11, 12). Because TAP block acts only on the nerves supplying the anterior abdominal wall and thereby subdues the parietal component pain only. Thereby our patient received intravenous fentanyl for abdominal discomfort when the stomach was manipulated. Except that, he did not need any local anesthetic supplementation during the operation and did not need any other analgesic support after the end of operation.

In conclusion, this case demonstrated that open gastrostomy was successfully performed under subcostal TAP block with small dose fentanyl supplementation. Open gastrostomy is usually performed in elderly and high risk patients who pose several anesthetic risks, so we recommend to consider subcostal TAP block as a useful anesthetic choice in surgery of high risk patients.

### Acknowledgements

We would like to express our thanks to Jeju National University Hospital which gave us the opportunity to do this and helped us to submit the manuscript.

### Authors' Contributions

Ae Ryoung Lee: case presentation, collecting and interpretation of review data; Yun Suk Choe: editing the manuscript.

### Funding/Support

This study was only supported by our departmental sources.

### References

1. Johns N, O'Neill S, Ventham NT, Barron F, Brady RR, Daniel T. Clinical effectiveness of transversus abdominis plane (TAP) block in abdominal surgery: a systematic review and meta-analysis. *Colorectal Dis.* 2012;**14**(10):e635–42.
2. Hasan MS, Ling KU, Vijayan R, Mamat M, Chin KF. Open gastrostomy under ultrasound-guided bilateral oblique subcostal transversus abdominis plane block: a case series. *Eur J Anaesthesiol.* 2011;**28**(12):888–9.
3. Hebbard P. Subcostal transversus abdominis plane block under ultrasound guidance. *Anesth Analg.* 2008;**106**(2):674–5.
4. Rafi AN. Abdominal field block: a new approach via the lumbar triangle. *Anaesthesia.* 2001;**56**(10):1024–6.
5. Lee TH, Barrington MJ, Tran TM, Wong D, Hebbard PD. Comparison of extent of sensory block following posterior and subcostal approaches to ultrasound-guided transversus abdominis plane block. *Anaesth Intensive Care.* 2010;**38**(3):452–60.
6. Niraj G, Searle A, Mathews M, Misra V, Baban M, Kiani S, et al. Analgesic efficacy of ultrasound-guided transversus abdominis plane block in patients undergoing open appendectomy. *Br J Anaesth.* 2009;**103**(4):601–5.
7. Atim A, Bilgin F, Kilickaya O, Purtuloglu T, Alanbay I, Orhan ME, et al. The efficacy of ultrasound-guided transversus abdominis plane block in patients undergoing hysterectomy. *Anaesth Intensive Care.* 2011;**39**(4):630–4.
8. Belavy D, Cowlshaw PJ, Howes M, Phillips F. Ultrasound-guided transversus abdominis plane block for analgesia after Caesarean delivery. *Br J Anaesth.* 2009;**103**(5):726–30.
9. Mukhtar K, Singh S. Transversus abdominis plane block for laparoscopic surgery. *Br J Anaesth.* 2009;**102**(1):143–4.
10. Sharma A, Bach JR, Swan KG. Open gastrostomy under local anesthesia for patients with neuromuscular disorders. *Am Surg.* 2010;**76**(4):369–71.
11. Sivapurapu V, Vasudevan A, Gupta S, Badhe AS. Comparison of analgesic efficacy of transversus abdominis plane block with direct infiltration of local anesthetic into surgical incision in lower abdominal gynecological surgeries. *J Anaesthesiol Clin Pharmacol.* 2013;**29**(1):71–5.
12. Moiniche S, Mikkelsen S, Wetterslev J, Dahl JB. A qualitative systematic review of incisional local anaesthesia for postoperative pain relief after abdominal operations. *Br J Anaesth.* 1998;**81**(3):377–83.