

An Abdominal Wall Desmoid Tumour Mimicking Cesarean Scar Endometriomas: A Case Report and Review of the Literature

BIROL VURAL¹, FISUN VURAL², BAHAR MÜEZZINOĞLU³

ABSTRACT

Abdominal wall desmoid tumours (DT) are rare, slow-growing benign muscular-aponeurotic fibrous tumours with the tendency to locally invade and recur. They constitute 0.03% of all neoplasms and high infiltration and recurrence rate, but there is no metastatic potential. Although surgery is the primary treatment modality, the optimal treatment remains unclear. Abdominal wall endometriosis is also an unusual disease, and preoperative clinical diagnosis is not always easy. The preoperative radiologic imaging modalities may not aid all the time. Herein, we report an abdominal mass presenting as cyclic pain. Forty-two years old woman who gave birth by cesarean section admitted the complaints of painful abdominal mass (78x45 mm in size) under her cesarean incision scar. She had severe pain, particularly during menstruation. The clinical and radiological imaging findings mimicking endometrioma. We performed wide surgical excision of mass with a 1 cm tumor-free margin with the diagnosis of a benign mesenchymal tumor in the frozen section. The postoperative course was uneventful and recovered without any complication and recurrence three years after surgery. This report presents a case of abdominal wall desmoid tumor mimicking endometrioma. In this paper, shortcomings in diagnosis, abdominal wall endometriomas, and DTs were discussed in the view of literature.

Keywords: Abdominal wall masses, Benign mesenchymal tumor, Cesarean section, Endometriosis

CASE REPORT

A 42-year-old woman who gave birth by cesarean section admitted to our clinic with the complaints of gradually increasing painful abdominal mass under her cesarean incision scar. She had a cesarean section operation ten years ago without known postoperative complication. She had severe pain, particularly during menstruation. A 7 cm (~) (in diameter), solid, painful and semi-mobile mass on the left side of cesarean section incision was detected by abdominal physical examination. Ultrasonographic examination revealed 78.2x45 mm in diameter slightly lobulated, hypoechoic solid mass with heterogeneous internal echo [Table/Fig-1]. Colour Doppler ultrasonography showed vascular flow within the mass. Dynamic contrast-enhanced abdominal computerized tomography scan showed a 7 cm in diameter, homogenous abdominal wall mass at the level of the pelvis.

We performed wide surgical excision of 9 x 5 cm in diameter solid mass with a 1 cm tumour-free margin. Fascial defect was closed with no:1 prolene suture without mesh needs. The tumour was a dense, bright beige-yellow in Colour and located in the left rectus sheath [Table/Fig-2]. The intraoperative frozen section showed a benign mesenchymal tumour.

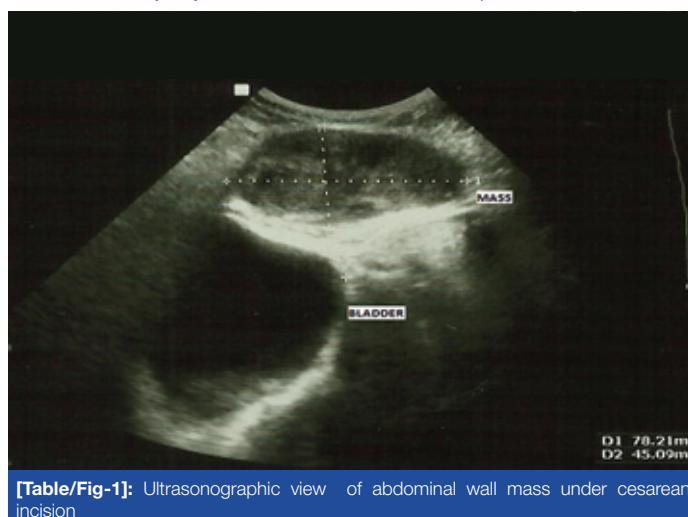
Macroscopically, excised material measured 9x5x5 cm and weighed 107 g. When sectioned it was beige, homogeneous and firm in consistency. On microscopic examination, interlacing bundles of collagenous tissue were noted [Table/Fig-3]. The lesion was not highly cellular. The cells were monotonous, bipolar and spindle shaped. The nuclei were sharp-edged, and chromatin was fine. There were no nuclear hyperchromasia and cellular pleomorphism. Mitotic activity was little (1/ 10 high power field). In the periphery, infiltration into the striated muscle and adipose tissue was noted [Table/Fig-4]. The lesion was 1 mm close to the surgical margin. Immunohistochemistry for the hormonal receptors ER/PR were negative. Endothelial marker CD34 was confined to vascular structures. Ki-67 proliferation index was 1%. The pathologic diagnosis was desmoid type fibromatosis.

The postoperative course was uneventful and recovered without any complications or functional defects. It has been three years after surgery without tumour recurrence.

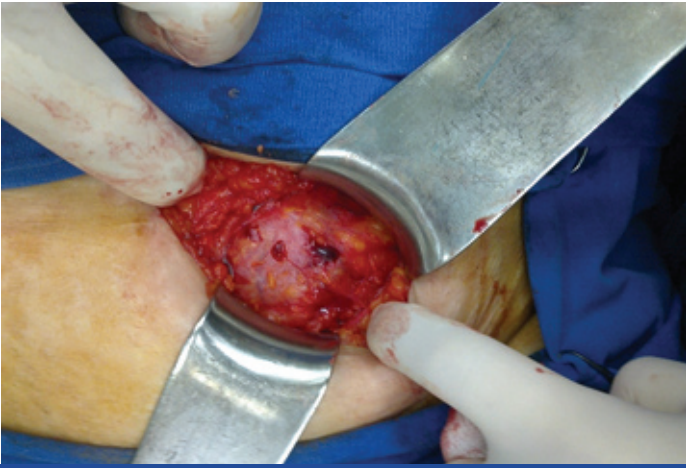DISCUSSION

Desmoid tumours (DT) are rare slow growing stromal, benign muscular-aponeurotic fibrous tumours with a strong tendency to invade locally and to recur [1]. They usually arise in the mesentery, omentum or retroperitoneum, while the abdominal wall is very rare [2]. Although the majority of the cases are sporadic tumours, some occur in the setting of Gardner syndrome (familial colorectal polyposis that is characterized by multiple polyps in the colon together with tumours outside the colon such as osteomas, thyroid cancer, epidermoid cysts, fibromas). These tumours usually tend to occur in women in their 30's but can occur in anyone at any age, and there is no significant racial or ethnic distribution. They constitute 3% of all soft tissue tumours and 0.03% of all neoplasms [1].

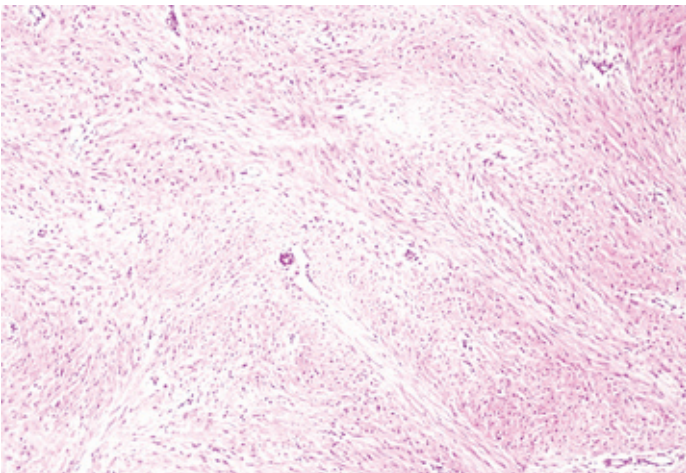
Abdominal wall endometriomas (AWE) may develop in prior surgical scars. The majority of the cases have been reported after obstetric



[Table/Fig-1]: Ultrasonographic view of abdominal wall mass under cesarean incision



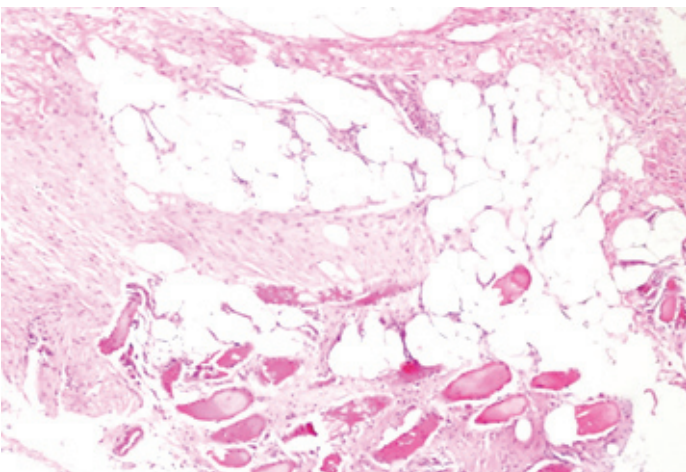
[Table/Fig-2]: The view of a dense, bright beige-yellow (desmoid) tumour in the left rectus sheath



[Table/Fig-3]: Interlacing fascicles of collagenous tissue with bland spindle cells (H&E x100)

and gynaecologic surgeries such as cesarean delivery, hysterotomy, hysterectomy, episiotomy, and tubal ligations. The prevalence of scar endometriosis after the hysterotomy and cesarean section is 1.08-2% and 0.03-0.4% respectively. However, the literature shows few reports after appendectomy procedure and in the laparoscopic trocar or amniocentesis needle tract [3]. Moreover, the spontaneous occurrence has been reported [4].

Endometriosis involving the abdominal wall is an unusual phenomenon, and preoperative clinical diagnosis is not always easy. Therefore, abdominal wall endometrioma should be noted in the differential diagnosis of the abdominal wall masses in women [5,6]. In this case, women with cyclic lower abdominal pain and painful



[Table/Fig-4]: The fascicular tumour infiltrating into the striated muscle and fat tissue (H&E x100)

abdominal mass under cesarean scar tissue was considered to be abdominal wall endometrioma, but the postoperative pathological diagnosis was reported to be DT. Therefore, we aimed to the discussion of differential diagnosis and reviewed the literature about abdominal wall endometrioma and DT. DT are rare tumours with ~3.7 new cases occurring per one million individuals each year. They usually occur in reproductive age women, familial adenomatous polyposis and occasionally with surgical trauma. Primarily located abdominally or intraabdominally. The increase in tumour volume during pregnancy and rare occurrence after postmenopausal period suggest the role of estrogen stimulation in tumour growth [7].

Abdominal wall DT is a very rare condition mimicking cesarean section scar endometrioma. The infra-umbilical rectus sheath is the commonest site of abdominal wall desmoids. Prior surgery, pregnancy, and hormone replacement are the risk factors for DT [8]. In the presented case, previous cesarean section and reproductive hormonal changes may be possible risk factors for DT. On the other hand, painful abdominal mass (cyclic) and previous cesarean operation might lead to difficulties in the differential diagnosis of abdominal wall endometrioma.

Kamechian et al., evaluated their clinic's abdominal wall endometriomas (AWE). All the patients in their study had symptoms of abdominal mass sensation. The 80% of the women experienced pain, among whom 46.7% experienced cyclic pain [9]. The occurrence rate of cyclic painful mass was as 20% in the other case reports [10]. The distribution of abdominal masses were AWE (63.3%), abdominal wall tumour (13.3%), incisional hernia (10%), suture granuloma (6.7%), and inguinal hernia (3.3%) and desmoid tumour (3.3%) [9].

Accurate preoperative diagnosis may be difficult and requires a high index of suspicion for the presence of endometrioma. The diagnosis of AWE is a challenge for a surgeon since many diseases mimicking the condition, such as desmoid tumour, fibrosis, suture granuloma, fat necrosis, nodular fasciitis and primary or metastatic malignancies lesions. The preoperative work-up include ultrasonography, computed tomography, and magnetic resonance imaging and fine-needle aspiration [6,9,11]. The fine needle aspiration was not performed in our case.

Microscopic examination of the pathologist should also pay attention to the differential diagnosis of DT is fibrosarcoma and benign fibrous lesions. "Malignant spindle cell tumours" have long fascicles and infiltrative borders. However, characteristic features of malignancy namely herring bone pattern, higher cellularity, nuclear hyperchromasia, pleomorphism and increased mitotic activity are lacking in fibromatosis. "Reactive fibroblastic proliferations" have cells closely resembling fibromatosis. Areas of variable growth pattern, haemorrhage or haemosiderin deposition are distinguishing factors for reactive processes [12].

Huang et al., performed a retrospective analysis of 151 patients who underwent a macroscopically complete resection of DT, and local recurrence rate in this study population was found to be 20.5% [12]. Bertani et al., described a recurrence-free follow-up period of 55 months in 14 patients with disease-free margins of >1 cm [13]. The goal of surgery is to attempt to obtain tumour-free margins while preserving function and cosmesis. Close follow-up is done after surgery. If surgery can not be performed or missing or tumour recurs, other treatment alternatives like radiation, radiofrequency, hormonal therapy, and chemotherapy should be considered [1,8]. In this study, despite tumour was completely resected with a 1 cm tumour-free margin, DT cells were observed less than one millimeter from the surgical margins. However, no recurrence was noted and as an extensive mass resection, the fascial defect was not encountered after 38 months follow-up.

CONCLUSION

In female patients presenting a painful tumour of the lower abdominal wall especially after previous obstetrical or gynaecological surgeries, an endometriotic tumour as well as DT should be considered. Although the ultrasound and other imaging methods and fine-needle aspiration cytology are the preoperative diagnostic procedures, the definite diagnosis relies on histopathology. The treatment of the DT is the wide surgical excision. Moreover, apart from other abdominal masses, DT need close follow-up due to the risk of recurrence.

CONSENT AND COMPETING INTEREST

Written informed consent was obtained from the patient for publication of this case report. We declare that there is no competing interests.

REFERENCES

- [1] Koshariya M, Shukla S, Khan Z, et al. Giant DT of the Anterior Abdominal Wall in a Young Female: A Case Report. *Case Rep Surg.* 2013;2013:780862. DOI: 10.1155/2013/780862.
- [2] Kumar ASS, Padmini R, Veena G, Murugesan N. Extragastrintestinal Stromal Tumour of The Abdominal Wall-A Case Report. *Journal of Clinical and Diagnostic Research.* 2013;7(12):2970-2. DOI: 10.7860/JCDR/2013/7863.3812.
- [3] Goel P, Sood SS, Romilla DA. Cesarean scar endometriosis - Report of two cases. *Indian J Med Sci.* 2005;59(11):495-98. DOI: 10.4103/0019-5359.18967.
- [4] Ideyi SC, Schein M, Niazi M, Gerst PH. Spontaneous endometriosis of the abdominal wall. *Dig Surg.* 2003;20:246-48.
- [5] Heller DS, Fitzhugh VA. Abdominal wall endometriosis: a rarely anticipated diagnosis: a 16-year experience and brief literature review. *J Reprod Med.* 2014;59(3-4):110-12.
- [6] Celik M, Bulbuloglu E, Buyukbese MA, Cetinkaya A. Abdominal wall endometrioma: localizing in rectus abdominus sheath. *Turk J Med Sci.* 2004;34:341-43.
- [7] Ma JH, Ma ZH, Dong XF, Yin H, Zhao YF. Abdominal wall DTs: A case report. *Oncol Lett.* 2013;5(6):1976-78. DOI: 10.3892/ol.2013.1297.
- [8] Krentel H, Tchatchian G, De Wilde RL. DT of the anterior abdominal wall in female patients: comparison with endometriosis. *Case Rep Med.* 2012;2012:725498. DOI: 10.1155/2012/725498
- [9] Khamechian T, Alizargar J, Mazoochi T. 5-Year data analysis of patients following abdominal wall endometrioma surgery. *BMC Womens Health.* 2014;14(1):151. DOI: 10.1186/s12905-014-0151-4.
- [10] Patil NJ, Kumar V, Gupta A. Scar Endometriosis-A sequel of cesarean section. *Journal of Clinical and Diagnostic Research.* 2014;8(4):9-10. DOI: 10.7860/JCDR/2014/7554.4267.
- [11] Nissotakis C, Zouros E, Revelos K, Sakorafas GH. Abdominal wall endometrioma: a case report and review of the literature. *AORN J.* 2010;91(6):730-42. DOI: 10.1016/j.aorn.2010.01.014.
- [12] Huang K, Fu H, Shi YQ, Zhou Y, Du CY. Prognostic factors for extra-abdominal and abdominal wall desmoids: a 20-year experience at a single institution. *Journal of Surgical Oncology.* 2009;100(7):563-69. DOI: 10.1002/jso.21384
- [13] Bertani E, Chiappa A, Testori A, et al. DTs of the anterior abdominal wall: results from a monocentric surgical experience and review of the literature. *Annals of Surgical Oncology.* 2009;16(6):1642-9. DOI: 10.1245/s10434-009-0439-z.

PARTICULARS OF CONTRIBUTORS:

1. Professor, Department of Obstetrics and Gynecology, Kocaeli University School of Medicine, Kocaeli, Turkey.
2. Specialist, Department of Obstetrics and Gynecology, Haydarpasa Numune Teaching Hospital, Istanbul, Turkey.
3. Professor, Department of Pathology, Kocaeli University School of Medicine, Kocaeli, Turkey.

NAME, ADDRESS, E-MAIL ID OF THE CORRESPONDING AUTHOR:

Dr. Birol Vural,
Orhan Mah. Bagtepe Sok. Erenkaya Park Evleri. A2-2 Bagçesme / Izmit (41100)- Kocaeli – Turkey.
E-mail: vuralbirol@yahoo.com.tr

Date of Submission: **Apr 18, 2015**
Date of Peer Review: **Jun 23, 2015**
Date of Acceptance: **Jul 21, 2015**
Date of Publishing: **Sep 01, 2015**

FINANCIAL OR OTHER COMPETING INTERESTS: None.