

Successful Treatment with Pazopanib for Multiple Lung Metastases of Inguinal Epithelioid Sarcoma: A Case Report

Sanae Irimura Kazumasa Nishimoto Kazutaka Kikuta
Robert Nakayama Michiro Susa Keisuke Horiuchi Masaya Nakamura
Morio Matsumoto Hideo Morioka

Department of Orthopaedic Surgery, Keio University School of Medicine, Tokyo, Japan

Key Words

Epithelioid sarcoma · Treatment · Multikinase inhibitor · Pazopanib

Abstract

Epithelioid sarcoma is a rare soft tissue sarcoma and usually resistant to chemotherapy. It has high rates of local recurrence and distant metastasis, and the prognosis after metastasis is poor. We report a case of multiple lung metastases of an epithelioid sarcoma originating in the inguinal area that we treated with the multikinase inhibitor pazopanib. The patient was a 38-year-old male who began to experience discomfort in his left inguinal area. Magnetic resonance imaging showed a tumor extended from the medial aspect of the wing of the left ilium along the iliopsoas muscle to its site of insertion on the femur. The histopathological diagnosis with a biopsy was proximal-type epithelioid sarcoma. Although a positron emission tomography examination showed fluorodeoxyglucose accumulation in the left inguinal tumor, there was no distant metastasis. Wide resection by a combined iliac resection procedure was performed. Twelve months after surgery, computed tomography revealed multiple nodules and a diagnosis of bilateral multiple lung metastases was made. Treatment with pazopanib 800 mg was started. After 2.5 months of treatment, a clear reduction in the size of the pulmonary metastases was shown. Thirty months after the start of pazopanib treatment, most of the metastases have disappeared, and no development of new lesions has been seen. Therefore, it appeared that pazopanib was capable of serving as one of the choices of therapeutic agents that should be taken into consideration for the treatment of advanced epithelioid sarcoma.

© 2015 The Author(s)
Published by S. Karger AG, Basel

Introduction

Epithelioid sarcoma is a rare soft tissue sarcoma of unknown origin, and it is said to have high rates of local recurrence and distant metastasis [1]. Epithelioid sarcoma is usually resistant to chemotherapy, and the prognosis after metastasis is poor [2]. We report a case of multiple lung metastases of an epithelioid sarcoma originating in the inguinal area that we treated with the multikinase inhibitor pazopanib.

Case Report

The patient was a 38-year-old male who began to experience discomfort in his left inguinal area at around 2010, and since around November 2010, he had difficulty walking. He was told that magnetic resonance imaging (MRI) during a thorough examination by his previous physician in July 2011 revealed a mass in his left iliopsoas muscle, and he was examined in our department for the first time in August 2011. The physical findings during the initial examination revealed that both flexion and extension were limited. MRI showed a tumor mass measuring approximately 11 × 5 × 5 cm that extended from the medial aspect of the wing of the left ilium along the iliopsoas muscle to its site of insertion on the femur. The same site was isointense on T1-weighted images (fig. 1a) and heterogeneous hyperintense on T2-weighted images (fig. 2b), and it was gadolinium enhanced (fig. 1c, d). The tumor was in contact with the ilium, but there was no clear bone invasion. Although left inguinal lymph node enlargement was observed, it was considered to be a reactive lesion. Bone scintigraphy and chest computed tomography (CT) showed no evidence of metastasis, and although a positron emission tomography examination showed fluorodeoxyglucose accumulation in the left inguinal tumor, there was no distant metastasis. Based on the above findings, a malignant soft tissue tumor was suspected. An incisional biopsy was performed for the purpose of making a definitive diagnosis. Histopathologic findings of the biopsy showed round/polygonal tumor cells in a solid or diffuse pattern with moderate amounts of eosinophilic cytoplasm and rhabdoid characteristics (fig. 2a). Immunohistochemical stains were positive for pan-keratin (fig. 2b) and epithelial membrane antigen (EMA) (fig. 2c). As a result, the histopathological diagnosis was proximal-type epithelioid sarcoma. A blood examination also revealed an elevated carbohydrate antigen 125 value (62 U/ml). In October 2011, a wide resection by a combined iliac resection procedure was performed, and the resection margin was negative. The postoperative course was favorable, and approximately 2 weeks postoperatively, the patient began partial weight-bearing on the affected limb. In October 2012, CT revealed multiple nodules, some accompanied by cavitation, in both lung fields, and a diagnosis of bilateral multiple lung metastases was made (fig. 3a). Treatment with pazopanib 800 mg was started in January 2013. A CT examination approximately 2.5 months after the start of pazopanib treatment showed a clear reduction in the size of the pulmonary metastases (fig. 3b), and to date, 30 months after the start of pazopanib treatment, most of the metastases have disappeared and shrunken, and no development of new lesions has been seen (fig. 3c). Side effects, including diarrhea, general fatigue, and stomatitis, have been observed, but they have all been grade 1 or less.

Discussion

Epithelioid sarcoma was first reported by Enzinger [3] in 1970 as a rare mesenchymal cell sarcoma that had a predilection for the extremities and showed a tendency toward epithelial differentiation. Later, in 1997, a more malignant subtype that developed at proximal sites, such as the trunk, was reported by Guillou et al. [4], and since then that type has been classified as proximal-type epithelioid sarcoma, and the former type as distal ('conventional or classic')-type epithelioid sarcoma. The incidence of proximal-type epithelioid sarcomas is said to be approximately half of the distal type, making them very rare, and they are more common in males and tend to occur between 20 and 65 years of age, i.e. an older age bracket than the distal type [5, 6]. As the distal type, the proximal type is also said to be resistant to chemotherapy, but it has an even poorer prognosis than the distal type [5, 6]. Hasegawa et al. [7] reviewed 20 cases of proximal-type epithelioid sarcoma and reported that there had been postoperative recurrence in 65% and distant metastasis in 75%, and that 65% experienced a tumor death.

The multikinase inhibitor pazopanib is the first molecularly targeted drug to be approved for the treatment of soft tissue sarcoma [8]. Although a significant prolongation of overall survival time was not detected in a previously performed international collaborative phase III trial whose subjects were 369 patients with advanced soft tissue sarcoma (PAL-ETTE study), a significant prolongation of progression-free survival of approximately 13 weeks was reported, and it has attracted attention as a new treatment method for advanced soft tissue sarcoma [9]. At present, effective chemotherapy for soft tissue sarcomas is limited, and the advent of pazopanib has made it possible to provide a new treatment option.

The therapeutic efficacy of pazopanib according to the histological type of soft tissue sarcomas is unknown at this stage, and further investigation will be necessary in the future. Lung metastasis developed postoperatively in our own case, which was a case of proximal-type epithelioid sarcoma. A reduction in size or disappearance of the pulmonary metastases was observed after pazopanib administration. It appeared that pazopanib was capable of serving as one of the choices of therapeutic agents that should be taken into consideration for the treatment of epithelioid sarcoma.

Statement of Ethics

Informed consent was obtained from the patient for publication of this case report and any accompanying images.

Disclosure Statement

Sanae Irimura, Kazumasa Nishimoto, Kazutaka Kikuta, Robert Nakayama, Michiro Susa, Keisuke Horiuchi, Masaya Nakamura, and Morio Matsumoto have no conflict of interest directly relevant to the content of this article. Hideo Morioka reports grants, personal fees from GSK and Novartis Pharma.

References

- 1 Armah HB, Parwani AV: Epithelioid sarcoma. *Arch Pathol Lab Med* 2009;133:814–819.
- 2 Baratti D, Pennacchioli E, Casali PG, Bertulli R, Lozza L, Olmi P, Collini P, Radaelli S, Fiore M, Gronchi A: Epithelioid sarcoma: prognostic factors and survival in a series of patients treated at a single institution. *Ann Surg Oncol* 2007;14:3542–3551.
- 3 Enzinger FM: Epithelioid sarcoma: a sarcoma simulating a granuloma or a carcinoma. *Cancer* 1970;26:1029–1041.
- 4 Guillou L, Wadden C, Coindre JM, Krausz T, Fletcher CD: 'Proximal-type' epithelioid sarcoma, a distinctive aggressive neoplasm showing rhabdoid features: clinicopathologic, immunohistochemical, and ultrastructural study of a series. *Am J Surg Pathol* 1997;21:130–146.
- 5 Rekhi B, Gorad BD, Chinoy RF: Clinicopathological features with outcomes of a series of conventional and proximal-type epithelioid sarcomas, diagnosed over a period of 10 years at a tertiary cancer hospital in India. *Virchows Arch* 2008;453:141–153.
- 6 Chbani L, Guillou L, Terrier P, Decouvlaere AV, Grégoire F, Terrier-Lacombe MJ, Ranchère D, Robin YM, Collin F, Fréneaux P, Coindre JM: Epithelioid sarcoma: a clinicopathologic and immunohistochemical analysis of 106 cases from the French sarcoma group. *Am J Clin Pathol* 2009;131:222–227.
- 7 Hasegawa T, Matsuno Y, Shimoda T, Umeda T, Yokoyama R, Hirohashi S: Proximal-type epithelioid sarcoma: a clinicopathologic study of 20 cases. *Mod Pathol* 2001;14:655–663.
- 8 Ranieri G, Mammì M, Donato Di Paola E, Russo E, Gallelli L, Citraro R, Gadaleta CD, Marech I, Ammendola M, De Sarro G: Pazopanib a tyrosine kinase inhibitor with strong anti-angiogenetic activity: a new treatment for metastatic soft tissue sarcoma. *Crit Rev Oncol Hematol* 2014;89:322–329.
- 9 van der Graaf WT, Blay JY, Chawla SP, Kim DW, Bui-Nguyen B, Casali PG, Schöffski P, Aglietta M, Staddon AP, Beppu Y, Le Cesne A, Gelderblom H, Judson IR, Araki N, Ouali M, Marreaud S, Hodge R, Dewji MR, Coens C, Demetri GD, Fletcher CD, Dei Tos AP, Hohenberger P; EORTC Soft Tissue and Bone Sarcoma Group; PALETTE study group: Pazopanib for metastatic soft-tissue sarcoma (PALETTE): a randomised, double-blind, placebo-controlled phase 3 trial. *Lancet* 2012;379:1879–1886.

Irimura et al.: Successful Treatment with Pazopanib for Multiple Lung Metastases of Inguinal Epithelioid Sarcoma: A Case Report

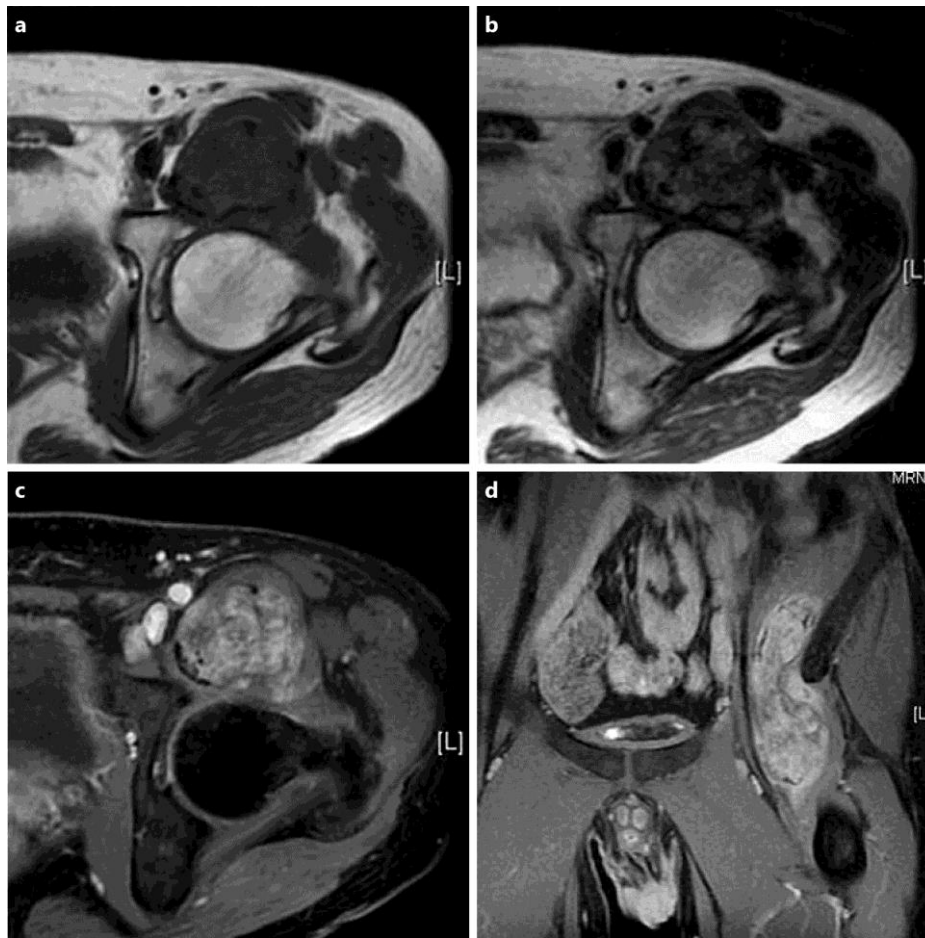


Fig. 1. MRI showed a tumor extended from the medial aspect of the wing of the left ilium along the iliopsoas muscle to its site of insertion on the femur. The tumor was isointense on T1-weighted images (a) and heterogeneous hyperintense on T2-weighted images (b), and it was gadolinium enhanced (c, d).

Irimura et al.: Successful Treatment with Pazopanib for Multiple Lung Metastases of Inguinal Epithelioid Sarcoma: A Case Report

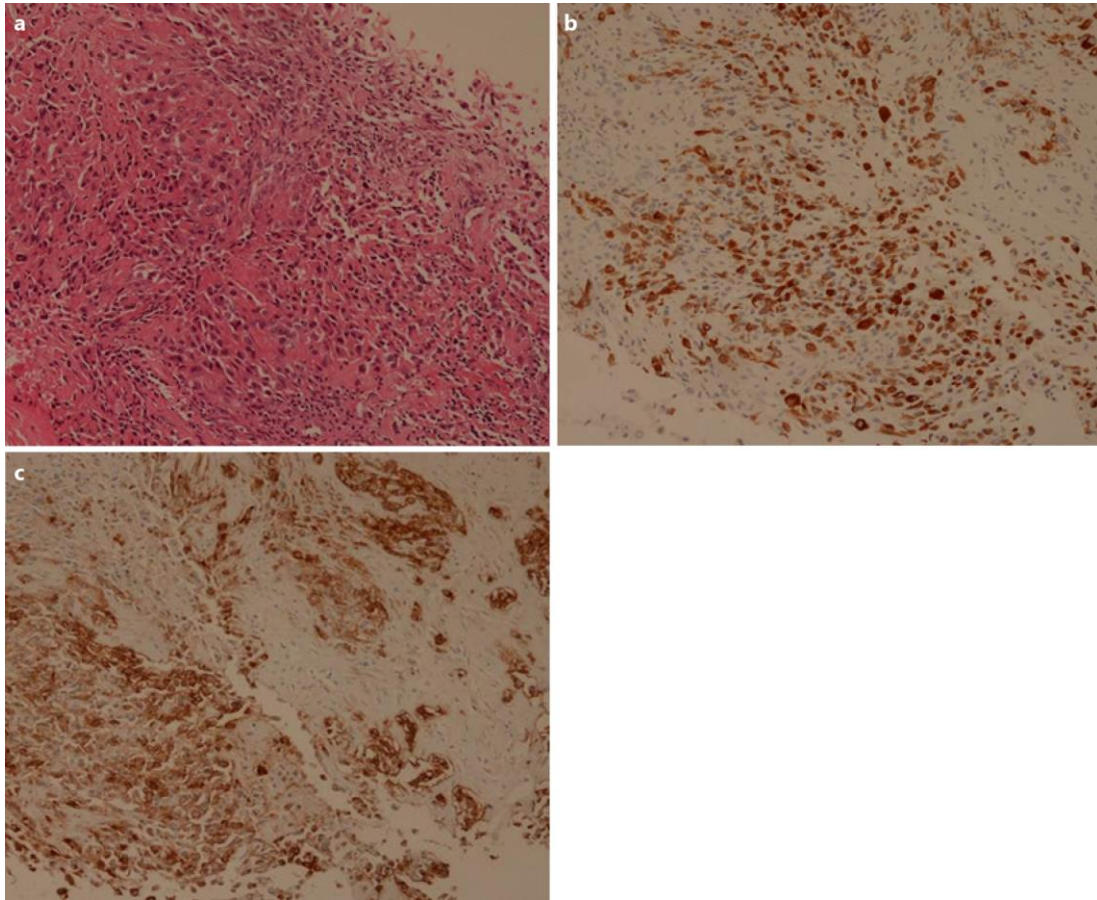


Fig. 2. Histopathologic findings showed round/polygonal tumor cells in a solid or diffuse pattern with moderate amounts of eosinophilic cytoplasm and rhabdoid characteristics (a). Immunohistochemical stains were positive for pan-keratin (b) and EMA (c).

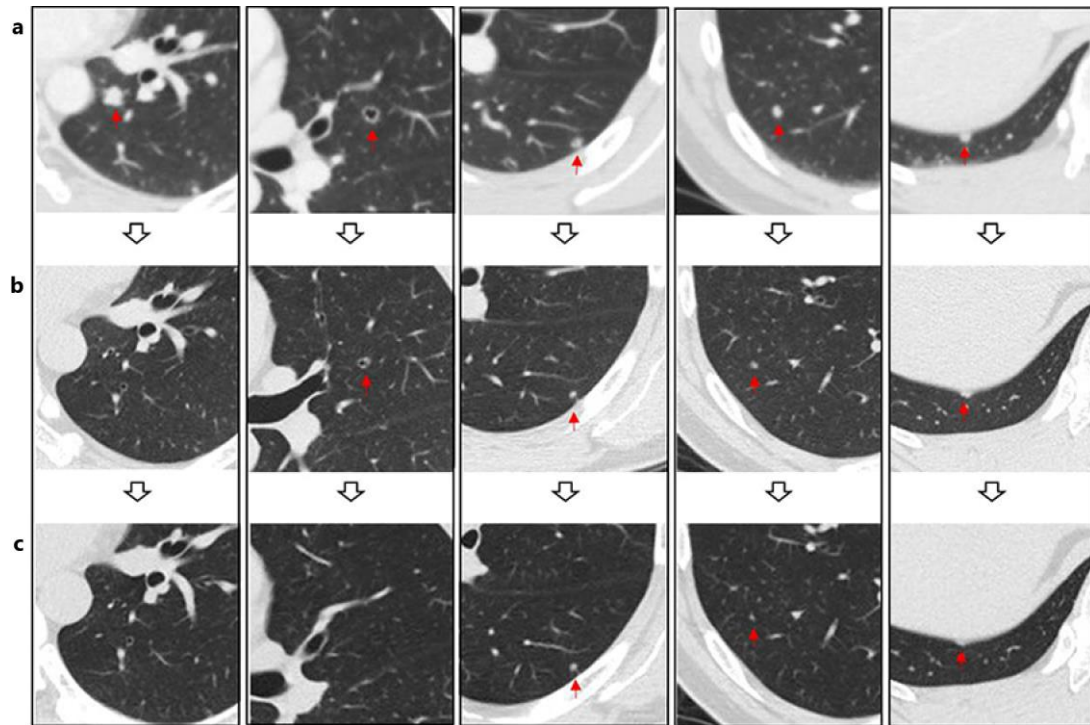


Fig. 3. CT revealed multiple nodules, some accompanied by cavitation, in both lung fields (a). CT examination approximately 2.5 months after the start of pazopanib treatment showed a clear reduction in the size of the pulmonary metastases (b). 30 months after the start of pazopanib treatment, most of the metastases have disappeared and shrunken (c).