

Evaluation of c-erbB-2 overexpression and Her-2/*neu* gene copy number heterogeneity in Barrett's adenocarcinoma

Axel Walch^{a,*}, Karin Bink^b, Peter Gais^a, Stefan Stangl^a, Peter Hutzler^a, Michaela Aubele^a, James Mueller^c, Heinz Höfler^{a,b} and Martin Werner^b

^a GSF-National Research Center for Environment and Health, Institute of Pathology, Neuherberg, Germany

^b Technical University Munich, Institute of Pathology, Munich, Germany

^c Technical University Munich, Department of Surgery, Munich, Germany

Received 3 December 1999

Accepted 14 March 2000

Amplification of the Her-2/*neu* gene is accompanied by overexpression of its cell surface receptor product, c-erbB-2 protein. To investigate the degree of intratumoural heterogeneity we applied immunohistochemistry in primary Barrett's adenocarcinoma (BCA) ($n = 6$) and dysplasia adjacent to the carcinoma ($n = 4$). In addition, fluorescence *in situ* hybridisation (FISH) was performed in primary BCA ($n = 5$) and dysplastic areas ($n = 4$). For an objective evaluation digital image analysis and laser scanning microscopy were used. Five of six BCA showed a marked intratumoural heterogeneous staining pattern ranging from areas in which the tumour cells were negative or faintly positive to tumour areas with a strong staining of the entire membrane. Among the two dysplastic areas also a heterogeneous staining pattern was observed. FISH analysis revealed marked heterogeneity of intratumoural gene copy number changes in all BCA showing populations with different fractions of cells with polysomy, low level amplification and high level amplification. One dysplasia showed a minor population with Her-2/*neu* signal clusters. In conclusion, we observed marked intratumoural heterogeneity of c-erbB-2 protein overexpression and Her-2/*neu* gene copy number in the majority of

the primary BCA analyzed. Digital image analysis and laser scanning microscopy were helpful in quantifying the variations in protein expression and DNA copy number in individual tumour cells. The observed heterogeneity could hamper the exact diagnostic determination of the c-erbB-2 status in small biopsies and possibly influence the effectiveness of a potential c-erbB-2 targeting therapy.

Figures on <http://www.esacp.org/acp/2000/20-1/walch.htm>.

Keywords: Intratumoural heterogeneity, Her-2/*neu*, c-erbB-2, fluorescence *in situ* hybridization, immunohistochemistry, laser scanning microscopy, digital image analysis, Barrett's adenocarcinoma, dysplasia

1. Introduction

One of the best characterized oncogenes is Her-2/*neu* (erbB-2) which encodes a 185,000 molecular weight transmembrane tyrosine kinase (c-erbB-2). When the Her-2/*neu* oncogene is activated by gene amplification c-erbB-2 protein is overexpressed [3,4]. The most common methods for the demonstration of Her-2/*neu* oncogene activation in tumour cells are immunohistochemistry (IHC) which shows protein expression at the cell membrane, and fluorescence *in situ* hybridization (FISH) for the detection of increased DNA copy numbers in tumour cell nuclei [3].

A variety of human tumours show c-erbB-2 overexpression or Her-2/*neu* gene amplification, among these are carcinomas of breast, lung, bladder and colon [4]. In some tumour types c-erbB-2 overexpression has been correlated with poor prognosis [3] or a lack of response to chemotherapy [3,4]. Barrett's adenocarcinoma (BCA) of the esophagus has been reported to display increased c-erbB-2 expression in up to 26% of cases by immunohistochemistry [1,7]. On the DNA-level, we previously demonstrated amplification of the long arm of chromosome 17 including the Her-2/*neu* locus in 30% of BCA [5].

It is not known whether individual cases of BCA have homogeneous c-erbB-2 overexpression and Her-

*Corresponding author: Dr. med. Axel Walch, GSF-Forschungszentrum für Umwelt und Gesundheit, Institut für Pathologie, Ingolstädter Landstraße 1, D-85764 Oberschleißheim, Germany. Tel.: +49 89 31872739; Fax: +49 89 31873349; E-mail: Walch@gsf.de.

2/neu gene amplification or if these findings show a more heterogeneous pattern with varying degrees of positivity throughout the tumour. Marked heterogeneity could have an impact on the diagnostic determination of c-erbB-2 status in small biopsies and could influence the effectiveness of potential c-erbB-2 targeting therapy. The aim of the present study was therefore to evaluate the pattern of c-erbB-2 expression in different areas of BCA by immunohistochemistry. The results were correlated with the results of FISH for the Her-2/neu oncogene in some of the cases.

2. Material and methods

2.1. Tissue samples

All analyses were performed on archival material from formalin-fixed (4% buffered formalin) and paraffin-embedded tissue obtained from six patients with primary Barrett's adenocarcinoma (BCA) of the distal esophagus. All patients underwent an esophagectomy without preoperative radiotherapy or chemotherapy. Serial sections were cut for immunohistochemistry (5 μm) and fluorescence *in situ* hybridization (10 μm). The first and the last section of each series was stained with H&E. Corresponding areas on sequential sections were investigated by both methods.

2.2. Immunohistochemistry (IHC)

The sections for immunohistochemistry were deparaffinized and rehydrated. Antigen retrieval was performed by heating the sections in a microwave oven for 30 min at 750 W. During heating the sections were immersed in a citric buffer (pH 6.0). After cooling the sections to room temperature, endogenous peroxidase activity was blocked by incubation with 3% hydrogen peroxidase in methanol for 15 min. The sections were then incubated for 15 min with phosphate buffered saline containing 10% serum at 37°C. Anti-c-erbB-2 antibody (DAKO, Glostrup, Denmark) was applied at a dilution of 1 : 400 and incubated for 1 h at 25°C followed by detection with a DAKO ChemMate™ detection kit containing peroxidase and DAB, according to the manufacturer's recommendations. Finally, the slides were counterstained with hematoxylin, dehydrated and coverslipped. To ensure the sensitivity of the reaction, a case of invasive ductal breast carcinoma with known overexpression of c-erbB-2 was used as positive control.

2.3. Fluorescence *in situ* hybridization (FISH)

For FISH analysis a PathVysion Her-2/neu DNA probe kit (Vysis, Inc.; Downers Grove, United Kingdom) was used according to the manufacturer's recommendations. The kit consists of directly labelled fluorescent DNA probes specific for the HER-2/neu gene locus (17q11.2–q12) and a DNA probe specific for the alpha satellite DNA sequence at the centromeric region of chromosome 17 (17p11.1–q11.1). Tissue pretreatment was performed as previously described [6]. Counterstaining of nuclei was performed using TO-PRO™-3 iodide (Molecular Probes, Eugene, USA). Nuclei from normal squamous epithelium or lymphocytes deposited separately on the same slide were used as controls of hybridisation efficiency and specificity.

2.4. Evaluation of immunohistochemical staining

2.4.1. Visual evaluation

c-erbB-2 protein overexpression was evaluated by two experienced pathologists (M.W., A.W.) according to a score system recommended by the DAKO HercepTest™. Briefly, complete lack of staining, or membranous staining in less than 10% of the tumour cells was scored as "0". If faint or barely perceptible membranous staining was detected in more than 10% of the tumour cells, or cells showed only partial membranous staining they were scored as "1+". A score of "2+" was defined as weak to moderate staining of the entire membrane in more than 10% of the tumour cells. Finally, strong staining of the entire membrane in more than 10% of the tumour cells was score as "3+".

2.4.2. Evaluation by digital image analysis

Using an Orthoplan microscope (Leica, Bensheim, Germany, objective 25 \times , numerical aperture 0.55) equipped with a color TV camera (JVC KY-F30, 3-CCD, 640 \times 480 pixels, Tokyo, Japan) and a SAMBA 2005 image analysis system (Système d'Analyses Microscopique a Balayage Automatique, UNILOG, Meylan, France) images were taken with a grid measuring 500 μm^2 over the entire tumour areas by the investigator (P.G.). The features of the neoplastic cells were calculated with software developed in our own laboratory. The integrated optical density (IOD), mean optical density (MOD), standard deviation (STDV) and range of the marked tumour areas were calculated after performing a shading correction. The measurements were made in the blue channel of the RGB TV-signal which was adjusted to correspond to the staining of the slides.

2.5. Evaluation of FISH signals

2.5.1. Visual evaluation

Each of the cases was visually evaluated by two experienced investigators (A.W., K.B.) using a fluorescence microscope. The criteria established by Hopman et al. were followed for signal enumeration [2]. The Her-2/neu gene locus was classified as amplified if there were more than twice as much red Her-2/neu signals than green centromere 17 signals (ratio > 2, low level amplification). More than two red signals accompanied by the same number of green signals was considered to be indicative of polysomy of chromosome 17. Her-2/neu clusters were defined as an accumulation of usually more than 10 signals, reflecting a high level gene amplification. In those cells the precise number of signals could not be counted due to coalescent signal clusters. The tumours were classified as “no amplification”, “low-level amplification” or “high-level amplification” of Her-2/neu gene copy number depending on the most prevalent cell population. The results were compared with those obtained by laser scanning microscopy.

2.5.2. Evaluation by laser scanning microscopy

Using a confocal laser scanning microscope (Zeiss LSM 510) 15–20 randomly selected fields (objective 63 \times) within carcinomatous and dysplastic areas were scanned in steps of 0.5 μ m. Cells were selected for scoring according to morphological criteria using TO-PROTM-3 iodide staining. To avoid misinterpretation due to insufficient hybridization, cells were counted only if at least one bright centromere signal and one Her-2/neu signal were present. Signals from all neoplastic cell nuclei within the 15–20 randomly selected high-power fields were counted, and the above-mentioned criteria were followed for classification.

3. Results

Figures on <http://www.esacp.org/acp/2000/20-1/walch.htm>.

3.1. C-erbB-2 protein overexpression

Figure 1 shows the corresponding frequency distribution of staining intensity for e-erbB-2 oncoprotein of

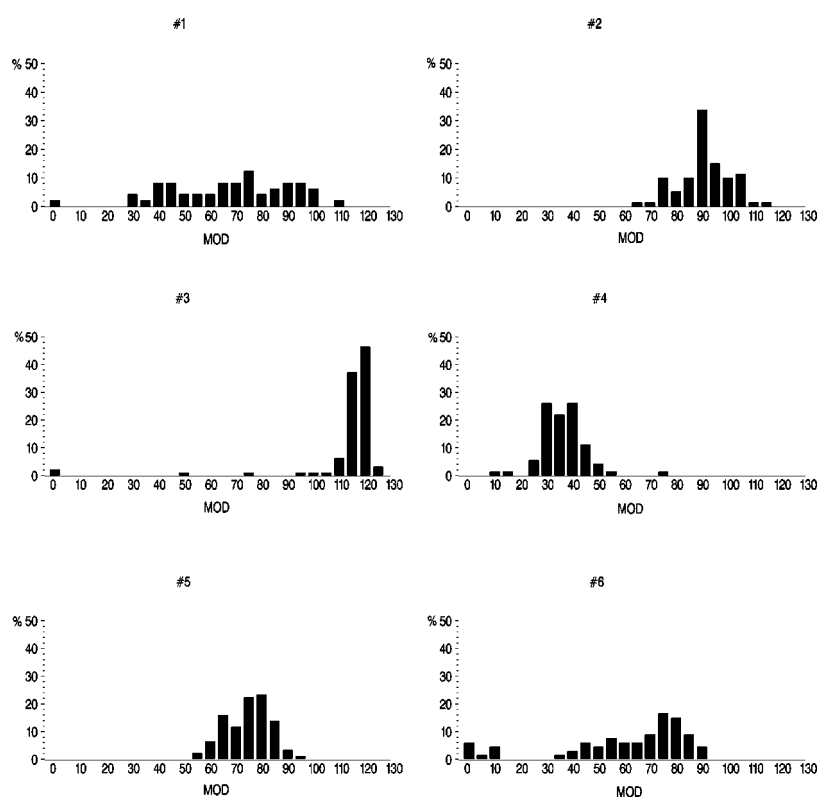


Fig. 1. The frequency distribution of staining intensity of c-erbB-2 protein of the six cases of BCA. The mean values of these distributions are summarized in Table 1. Note that the level of heterogeneity (width of the intensity profiles on this intensity scale) is different in the six cases and the absolute c-erbB-2 overexpression varies from case to case.

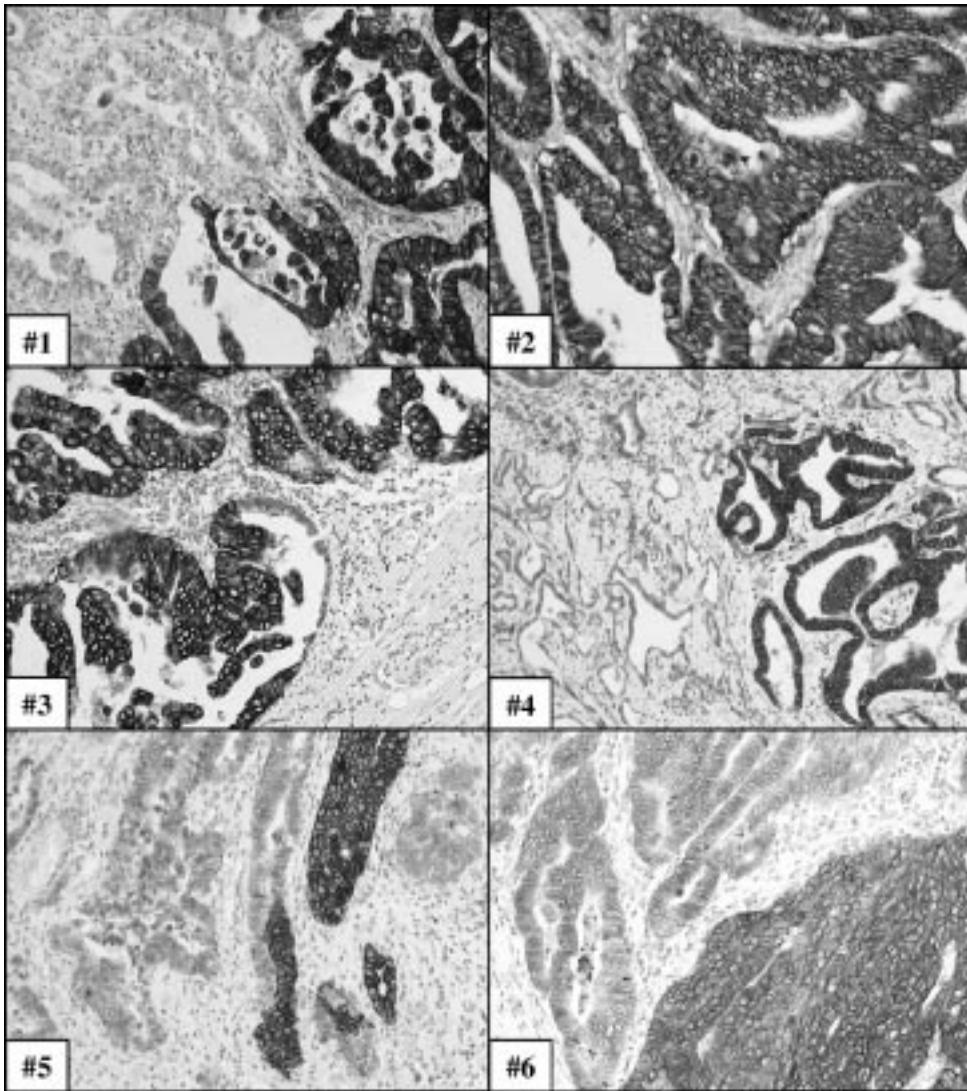


Fig. 2. Heterogeneous pattern of c-erbB-2 immunostaining in six BCA. #1, #3, #4, #5, #6 note the marked intratumoural heterogeneity of c-erbB-2 overexpression; #2, virtually every cell is strongly immunopositive.

the whole tumour areas of the six cases of BCA. Figure 2 illustrates the level of intratumoural heterogeneity of c-erbB-2 overexpression in the six cases of BCA. The mean values of the distribution curves and the results of visual evaluation are summarized in Table 1.

3.1.1. Visual evaluation

According to the used scoring system four of six BCA were scored as “3+”, one as “2+” and one as “1+”. However, five of six BCA showed a marked intratumoural heterogeneous staining pattern ranging from areas in which the tumour cells were negative (score “0”) or faintly positive (score “1+” or “2+”) to tumour areas with a strong staining of the entire

membrane (score “3+”). Only one BCA demonstrated a homogenous staining pattern in which virtually every tumour cell was strongly immunopositive (score 3+). Among the two dysplastic areas also a heterogenous staining pattern was observed. Both dysplastic areas were scored as “1+”.

3.1.2. Evaluation by digital image analysis

Six BCA ranged from 49.2 to 116.0 MOD. All cases except one displayed striking differences in the staining intensities due to different tumour areas analyzed (Fig. 2). The two dysplastic areas showed a MOD of 43.8 and 45.0 (Table 1).

Table 1

Results of IHC and FISH. C-erbB-2 overexpression of six Barrett's adenocarcinomas (CA) and two adjacent dysplasias (DYS). Corresponding FISH analysis of Her-2/neu gene and centromere 17 in two cases of Barrett's adenocarcinoma and two adjacent dysplasia

| IHC | Evaluation by digital image analysis | | | | Visual evaluation |
|--------|--------------------------------------|------|-------|------|--------------------|
| | MOD | STDV | Range | CV | |
| Case | | | | | Score ¹ |
| #1 CA | 85.3 | 22.9 | 108 | 34 | 3+ |
| #2 CA | 90.8 | 9.7 | 51.5 | 10.6 | 3+ |
| #3 CA | 116 | 18.8 | 124 | 16.6 | 3+ |
| #3 Dys | 43.8 | 9.9 | 26.1 | 24.1 | 1+ |
| #4 CA | 49.2 | 8.4 | 60.3 | 23.7 | 1+ |
| #5 CA | 80.9 | 8.4 | 41.2 | 11.2 | 2+ |
| #6 CA | 76 | 24.9 | 89 | 41.5 | 3+ |
| #6 Dys | 45 | 8.9 | 61.0 | 21.7 | 1+ |

| FISH | Evaluation by laser scanning microscopy | | | | Visual evaluation | |
|--------|---|--|-----------------------------------|---------------------------------|-------------------|--------------------------|
| | n ² | Her-2/neu -cluster (%) ³ | Her-2/neu signals ⁴ | Chr. 17 signals ⁵ | | Her-2/neu /chr. 17 |
| Case | | | | | Classification | |
| #2 CA | 144 | 29 | 2.1 | 2.1 | 0.9 | Low level amplification |
| #3 CA | 280 | 75 | 0.5 | 2.7 | 0.2 | High level amplification |
| #3 Dys | 233 | 12 | 1.1 | 2.7 | 0.4 | No amplification |
| #4 CA | 283 | 7.4 | 2.5 | 1.7 | 1.5 | No amplification |
| #6 CA | 264 | 87 | 1.1 | 2.8 | 0.4 | High level amplification |
| #6 Dys | 229 | 0 | 0.5 | 1.8 | 0.3 | No amplification |

MOD, mean optical density; STDV, standard deviation; CV, coefficient of variation; ¹ Score system for the determination of c-erbB-2 protein overexpression, as provided for DAKO Hercept TestTM; ² total number of evaluated neoplastic cells per 15–20 randomly selected high power fields within a histopathologically defined area; ³ number of cells with Her-2/neu signal clusters, precise number of signals in these cells could not be counted due to coalescent signals cluster. The clusters were usually composed of more than 10 signals; ⁴ mean number of Her-2/neu signals in remaining neoplastic cells; ⁵ mean number of chromosome 17 signals per neoplastic cell.

3.1.3. Her-2/neu gene copy number

Table 1 provides a comparison between visual evaluation and evaluation by laser scanning microscopy.

3.1.4. Visual evaluation

Two from four BCA were diagnosed as “high level amplified”, one as “low level amplified” and one as “not amplified”. Striking heterogeneity of intratumoural gene copy number changes was observed in all BCA showing populations with different fractions of cells with polysomy, low level amplification and high level amplification. Figure 3 illustrates intratumoural heterogeneity of Her-2/neu gene amplification in BCA of case #4. The dysplasias adjacent to carcinoma in two cases were classified as “not amplified”. One dysplasia showed a minor population with Her-2/neu signal cluster.

3.1.5. Evaluation by laser scanning microscopy

From the four cases of BCA a total number of 144–283 neoplastic cells were evaluated. In each BCA different fractions of cells with Her-2/neu signal clusters ranging from 7.4–87.0% was present. The remaining cells displayed a varying ratio of Her-2/neu

signals/centromere 17 signals reflecting a continuous spectrum of amplification and polysomy, respectively. From the adjacent dysplastic areas of two cases 233 and 264 cell were counted. One of the two dysplastic areas showed a fraction of 12% with Her-2/neu signal cluster. Detailed results are given in Table 1. An example of an sequence of optical sections for signal enumeration is given in Fig. 4.

4. Discussion

In this study we used quantitative immunohistochemistry and FISH to determine the extent of intratumoural heterogeneity of c-erbB-2 overexpression and Her-2/neu gene amplification in BCA. Striking intratumoural heterogeneity was observed and quantified at both the phenotypic and genotypic levels in most of the tumours. The heterogeneity that was already evident by visual evaluation of the sections could be confirmed by quantification using digital image analysis and laser scanning microscopy. Four of the six tumours had areas which showed strong overexpression of c-erbB-2,

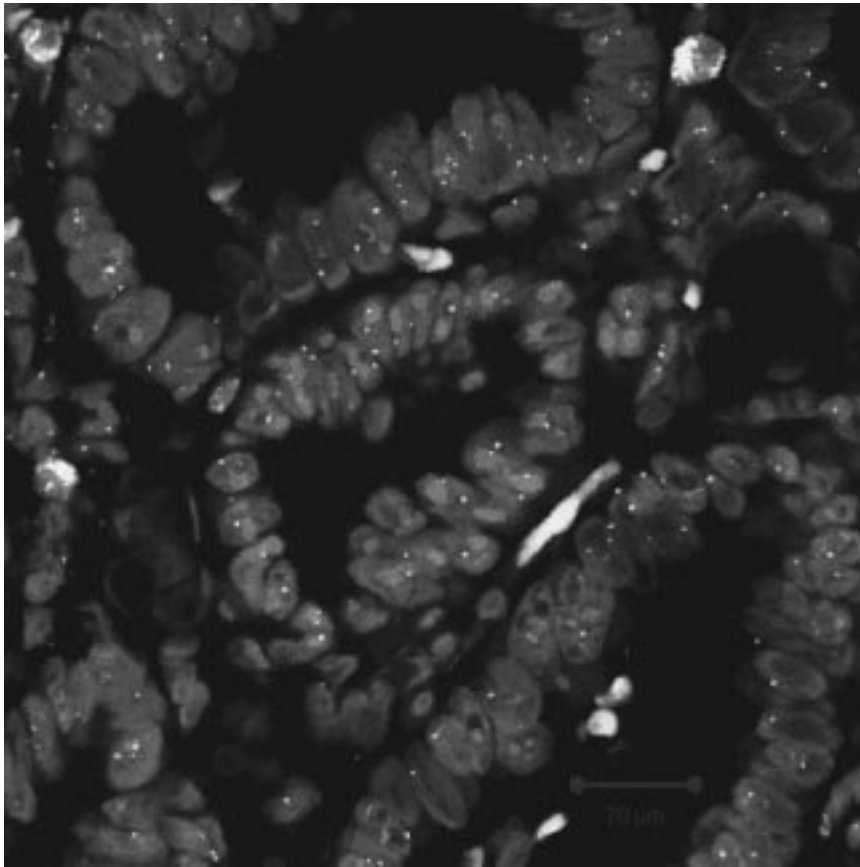


Fig. 3. Heterogeneity of *Her-2/neu* gene amplification in BCA of case #4 shown by dual-colour FISH with *Her-2/neu*-specific probes (red signals) and chromosome 17 centromeric probes (green signals) counterstained with TO-PROTM-3 iodide. Note that the tumour cells in the centre of the BCA area show high-level *Her-2/neu* amplification (clusters), while the remaining tumour cells show no, or only low-level, *Her-2/neu* amplification.

whereas other areas displayed no or only faint cell membrane staining in few tumour cells. Taking the entire tumour area into account, these cases could be still classified as “3+”, the highest score according to the most commonly used scoring system (DAKO HercepTestTM). These results suggest that in small tumour samples of BCA, for example endoscopic biopsies, sampling error could lead to an underestimation of the actual extent of *c-erbB-2* expression.

Primary BCA and its lymph node metastasis are genetically complex tumours characterized by marked genetic heterogeneity, as we previously demonstrated in a comparative genomic hybridization study [5]. This heterogeneity provides a potential source for the selection of subclones with increased malignant and metastatic potential. Therefore, the intra-tumoural heterogeneity of *c-erbB-2* overexpression and *Her-2/neu* gene amplification described in the present study is not surprising. The impact of this intratumoural het-

erogeneity on the biological behavior of BCA is not yet clear. However, the treatment of *c-erbB-2* overexpressing tumours by *c-erbB-2* targeting agents such as Herceptin (Genentech, San Francisco, CA) as already introduced for breast cancer [3] may be less effective in more heterogeneous tumours. In these cases tumour clones without *c-erbB-2* overexpression might be unaffected by the specific therapy and could become the dominant clone after treatment.

The major advantage of the immunohistochemical and FISH techniques used in our study was that the phenotypic and genotypic analyzes could be performed on a cell-by-cell basis with preservation of morphology. Thus, both methods are especially well suited to study intratumoural heterogeneity. Although heterogeneity of *c-erbB-2* overexpression was already evident in our cases by visual evaluation, we used digital imaging analysis to obtain more detailed and objective data. Similarly, FISH signals were evaluated with the

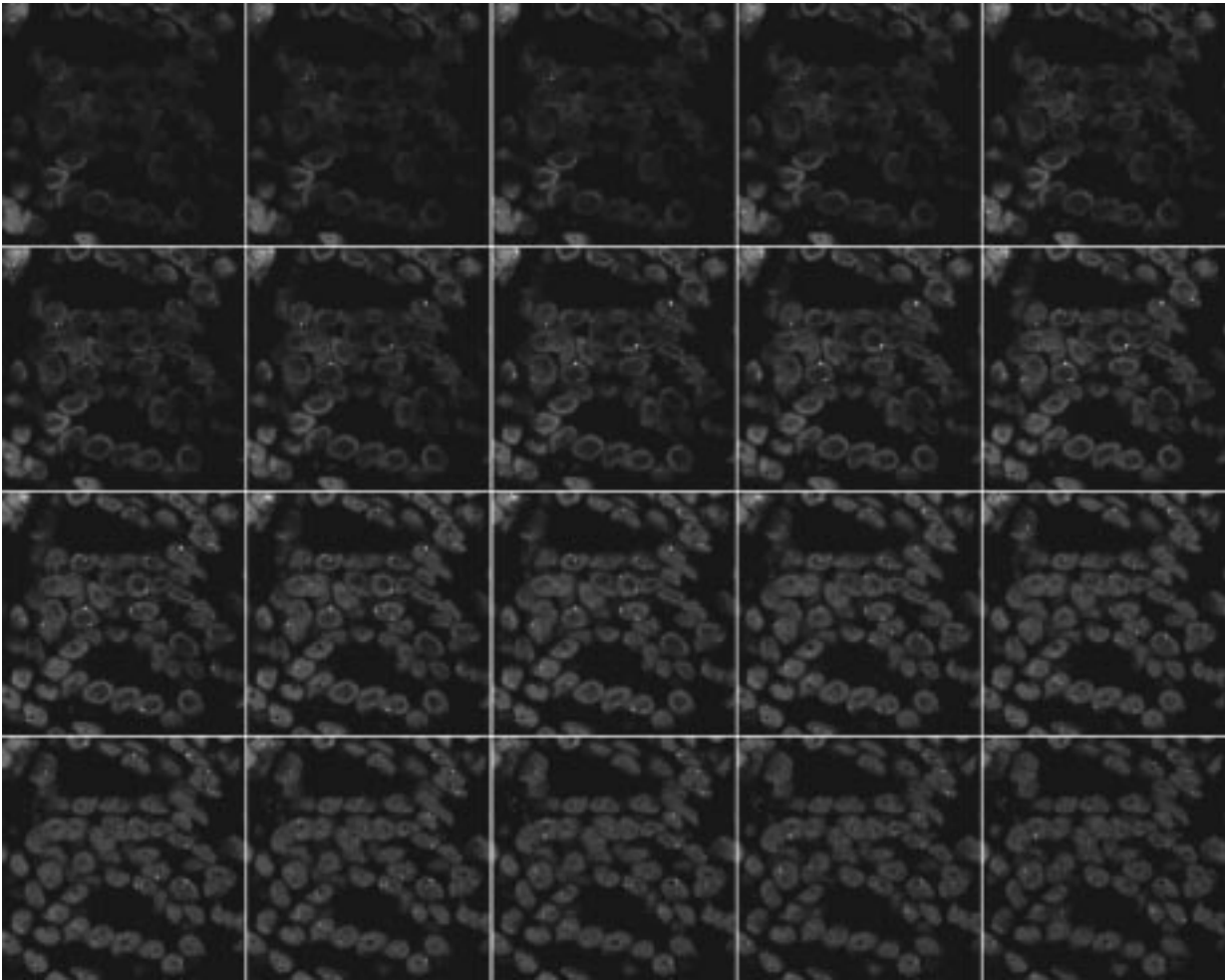


Fig. 4. Evaluation of gene copy number changes for Her-2/neu-specific probes (red signals) and chromosome 17 centromeric probes (green signals) counterstained with TO-PRO™-3 iodide in case #4 using laser scanning microscopy. A sequence of images from an selected areas was scanned in steps of 0.5 μm for signal enumeration.

help of laser scanning microscopy. The automated acquisition of images was more accurate than visual evaluation, especially for the evaluation of double color hybridization marking the Her-2/neu locus and the centromeric region of chromosome 17. The use of laser scanning microscopy allowed a more objective determination of the amplification level within subpopulations and the amplification pattern (clusters of amplified genes versus homogenous distribution).

In conclusion, we observed marked intratumoural heterogeneity of c-erbB-2 protein over-expression and Her-2/neu gene copy number in the majority of the primary BCA that we analyzed. Digital image analysis and laser scanning microscopy were helpful in quantifying the variations in protein expression and DNA copy number in individual tumour cells. Tumor hetero-

geneity should be taken into account when the c-erbB-2 status is determined in small biopsies. Although the biological significance of c-erbB-2 heterogeneity in BCA is not yet clear, it is possible that, in heterogeneous tumours, cells with normal levels of c-erbB-2 protein and Her-2/neu gene copy number could clonally expand during treatment with c-erbB-2 targeting agents.

References

- [1] R.H. Hardwick, N.A. Shepherd, M. Moorghen, P.V. Newcomb and D. Alderson, c-erbB-2 overexpression in the dysplasia/carcinoma sequence of Barrett's oesophagus, *J. Clin. Pathol.* **48** (1995), 129–132.

- [2] A.H. Hopman, F.C. Ramaekers, A.K. Raap, J.L. Beck, P. Devilee, M. van der Ploeg and G.P. Vooijs, In situ hybridization as a tool to study numerical chromosome aberrations in solid bladder tumours, *Histochemistry* **89** (1988), 307–316.
- [3] J.S. Ross and J.A. Fletcher, The HER-2/neu oncogene in breast cancer: prognostic factor, predictive factor, and target for therapy, *Stem Cells* **16**(6) (1998), 413–428.
- [4] E. Tzahar and Y. Yarden, The ErbB-2/HER2 oncogenic receptor of adenocarcinomas: from orphanhood to multiple stromal ligands, *Biochim. Biophys. Acta* **1377**(1) (1998), M25–37.
- [5] Walch, H. Zitzelsberger, J. Bruch, G. Keller, D. Angermeier, M. Aubele, J. Mueller, H. Stein, H. Braselmann, J.R. Siewert, H. Höfler and M. Werner, Chromosomal imbalances in Barrett's adenocarcinoma and in the metaplasia-dysplasia-carcinoma-sequence, *Am. J. Pathol.* (in press).
- [6] M. Werner, A. Mattis, M. Aubele, M. Cummings, H. Zitzelsberger, P. Hutzler and H. Höfler: 20q13.2 amplification in intraductal hyperplasia adjacent to in situ and invasive ductal carcinoma of the breast, *Virchows Arch.* (in press).
- [7] M. Werner, J. Mueller, A. Walch, H. Höfler: The molecular pathology of Barrett's esophagus. Review, *Histol. Histopathol.* **14**(2) (1999), 553–559.