

Empirical treatment without bronchoscopy for *Pneumocystis carinii* pneumonia in the acquired immunodeficiency syndrome

R F MILLER, A B MILLAR, I V D WELLER, S J G SEMPLE

From the Department of Medicine, University College and Middlesex School of Medicine, Middlesex Hospital, London, and the Academic Department of Genitourinary Medicine, Middlesex Hospital, London

ABSTRACT An empirical approach to treating *Pneumocystis carinii* pneumonia was adopted in a prospective study of 73 men with antibodies to human immunodeficiency virus 1 (HIV-1) presenting with respiratory problems. At presentation 49 patients (group 1) were thought to have a history, findings at clinical examination, chest radiograph, and arterial blood gas tensions typical of pneumocystis pneumonia, and empirical treatment was begun immediately. Twenty four patients (group 2) were thought to have features not typical of pneumocystis pneumonia. All patients were subsequently referred for bronchoscopy to determine the diagnosis. In group 1 four patients were excluded from the analysis because bronchoscopy was not possible. Of the remaining 45, 42 had pneumocystis pneumonia, which was diagnosed at bronchoscopy in 40, and on the basis of the clinical response to co-trimoxazole in two who had negative results from investigations. Of the three patients without pneumocystis pneumonia, one patient with lymphoid interstitial pneumonitis and *Branhamella catarrhalis* infection would have failed to respond to empirical treatment. The other two had multiple bacterial pathogens at bronchoscopy; one already had Kaposi's sarcoma and the other would have been misdiagnosed as having AIDS. In group 2 a specific diagnosis was made at bronchoscopy in 21 cases, including pneumocystis pneumonia in seven (all had atypical chest radiographs). In three cases no diagnosis was made and spontaneous recovery occurred. Adopting an empirical approach to treatment for typical pneumocystis pneumonia (group 1) led to the correct treatment in 43 of 45 cases (95%) and would have saved 44 of the 45 of bronchoscopies in this group. Adopting an empirical approach would have caused one patient to be misdiagnosed as having AIDS. Overall, 44 out of 69 bronchoscopies (64%) would have been saved; the specificity for the diagnosis of pneumocystis pneumonia was 85% and the sensitivity was 85%. Adopting an "empirical" treatment policy for typical pneumocystis pneumonia will cause a large reduction in the number of "high risk" bronchoscopies performed.

Introduction

It has been advocated that all patients with suspected *Pneumocystis carinii* pneumonia who have antibodies to human immunodeficiency virus 1 (HIV-1) or who are from a "high risk" group should undergo fibre-optic bronchoscopy and bronchoalveolar lavage, with or without transbronchial biopsy, for a definitive diagnosis before treatment is begun.¹⁻³ Whether this policy is a realistic one is questionable. In logistic

terms, bronchoscopy for every HIV-1 antibody positive patient presenting with respiratory symptoms and signs may soon be impossible. By December 1988 a total of 1982 cases of AIDS had been reported in the United Kingdom.⁴ Published data would suggest that over 60% of all patients with AIDS will have a respiratory illness (and some will have repeated episodes) during progression of the disease.^{5,6} The large and increasing numbers of patients requiring investigation of respiratory problems will place very heavy demands on clinicians, nursing staff, and in particular the laboratory services. The use of induced sputum to make a diagnosis will certainly reduce the numbers needing bronchoscopy but will not completely eliminate the need for this procedure.

Address for reprint requests: Dr R F Miller, University College and Middlesex School of Medicine, Middlesex Hospital, London W1N 8AA.

Accepted 5 April 1989

We have previously reported our experience with 13 patients with a presumed diagnosis of pneumocystis pneumonia who were treated empirically without bronchoscopy.⁷ In that study we proposed: (a) that patients with a history, findings at physical examination, chest radiograph, and arterial blood gas tensions typical of pneumocystis pneumonia did not need bronchoscopy to confirm the diagnosis and could be treated empirically with "high dose" intravenous co-trimoxazole; only those who had failed to respond by day 5 of treatment or who deteriorated *at any stage* should undergo bronchoscopy; (b) that patients with clinical features, chest radiograph, and arterial blood gas tensions that were not typical of pneumocystis pneumonia should also undergo bronchoscopy at or soon after presentation. This management plan is summarised in figure 1. In the present study we have prospectively examined the effects of adopting this empirical approach to treatment in patients presenting with features suggesting pneumocystis pneumonia, checking the validity of the approach from the findings at subsequent bronchoscopy.

Methods

We studied 73 HIV-1 antibody positive patients presenting with respiratory symptoms prospectively. All were male homosexuals with ages ranging from 21 to 62 (mean 41) years. On presentation a clinical

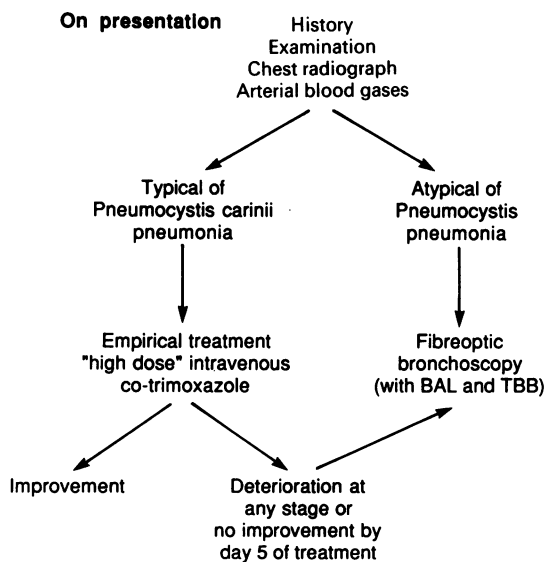


Fig 1 Management plan for patients with suspected *Pneumocystis carinii pneumonia*. BAL—bronchoalveolar lavage; TBB—transbronchial biopsy.

history was taken, the patient was examined, a chest radiograph was obtained, and an arterial blood gas sample was obtained with the patient breathing room air. On the basis of the history, results of examination, chest radiograph, and blood gas analysis the patients were immediately assigned to one of two groups, depending on whether the findings were regarded as typical of pneumocystis pneumonia (group 1) or not (group 2). The criteria used in the allocation of patients to the two groups are listed in table 1. An empirical approach to treatment was adopted in group 1, who were immediately treated with "high dose" intravenous co-trimoxazole. The patients in group 2 had one or more features of their history, findings at physical examination, chest radiograph, or blood gas tensions that were not usually seen in pneumocystis pneumonia and the presentation was considered atypical. These patients underwent bronchoscopy for a definite diagnosis.

Once treatment had been started in patients in group 1, we proceeded to perform bronchoscopies to obtain a laboratory based diagnosis for each patient, so that the validity of the "empirical" treatment policy could be tested.

Bronchoscopy was carried out with the patient sitting semi-upright and the bronchoscope was passed via the nose. Intravenous atropine 0.6 mg and metoclopramide 10 mg were given at the start of the procedure and topical lignocaine was applied to the nose and pyriform fossae (10% solution), to the vocal cords (4%), and below the cords (2%). During the procedure intravenous midazolam (2.5–7.5 mg) with or without alfentanil (0.25–0.5 mg) was used for sedation. Bronchoalveolar lavage was performed, with 180 ml of warmed buffered saline in 60 ml aliquots, and transbronchial biopsy specimens were obtained, without fluoroscopic control, from the

Table 1 Criteria for a clinical diagnosis of *Pneumocystis carinii pneumonia*

| Group 1: Typical of pneumocystis pneumonia | Group 2: Not typical of pneumocystis pneumonia |
|--|---|
| Recent onset of dyspnoea (days/weeks) | |
| Dry cough with or without mucoid sputum | Productive cough, purulent sputum, haemoptysis |
| Inability to take in a deep breath <i>not</i> due to pleuritic pain | Chest pain (with or without pleuritic pain) |
| Examination of chest: fine end inspiratory crackles, especially basally, or normal | Examination of chest: signs of consolidation or effusion |
| Chest radiograph: bilateral alveolar or interstitial shadowing or normal | Chest radiograph: focal abnormalities such as lobar consolidation or pleural effusion(s) or mediastinal lymphadenopathy |
| Blood gas tensions: hypoxaemia | |

lower lobe (usually the lateral segment of the right lower lobe). Lavage fluid was examined cytologically and microbiologically, and the transbronchial biopsy specimens were examined histologically and microbiologically.

Results

GROUP 1 (typical *Pneumocystis carinii* pneumonia)

Of the 49 patients in this group, four were excluded from the analysis because bronchoscopy could not be carried out. One patient refused bronchoscopy but after treatment with intravenous co-trimoxazole was begun *P carinii* was isolated from induced sputum. The other three patients were too ill to undergo bronchoscopy because of refractory hypoxaemia despite supplemental oxygen. All deteriorated rapidly despite intravenous co-trimoxazole and died in respiratory failure. Postmortem examinations were refused.

The bronchoscopic diagnosis in the remaining 45 patients is shown in figure 2. A diagnosis of pneumocystis pneumonia was confirmed in 40 patients, including one patient who also had a heavy growth of *Staphylococcus aureus*. This patient deteriorated with intravenous co-trimoxazole, developing respiratory failure, but recovered when given oxygen by continuous positive airways pressure and flucloxacillin.

GROUP 2 (atypical features)

There were 24 patients in this group. The bronchoscopic diagnoses in these patients is shown in figure 3.

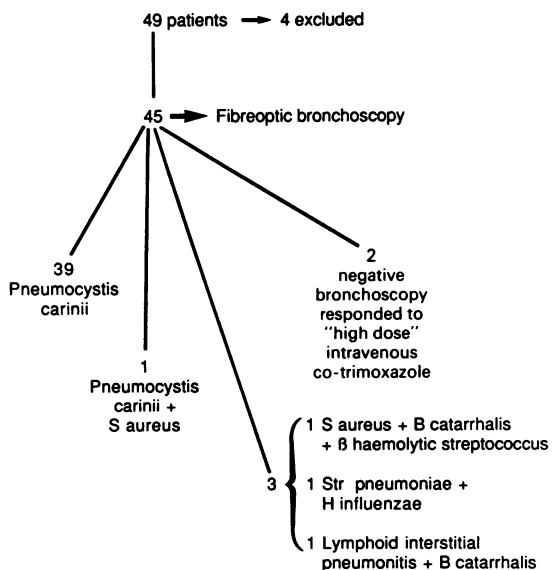


Fig 2 Group 1: Typical *Pneumocystis carinii* pneumonia.

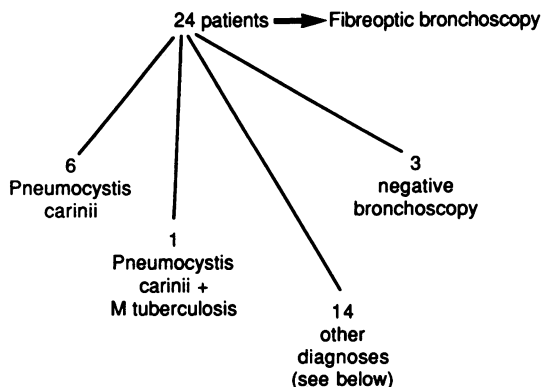


Fig 3 Group 2: Pneumonia not typical of *Pneumocystis carinii*.

Other diagnoses: 2 lymphoid interstitial pneumonitis; 1 non-specific fibrosis; 2 chronic inflammation; 3 Kaposi's sarcoma, endobronchial (one also had *S aureus* and one also had *B catarrhalis*); 6 other infections (1 *Streptococcus pneumoniae* and cytomegalovirus pneumonitis; 1 β haemolytic streptococcus; 1 actinomycosis; 1 *H influenzae*, *S aureus* and acid and alcohol fast bacilli; 1 acid and alcohol fast bacilli; 1 *B catarrhalis*, *S aureus*, β haemolytic streptococcus group G).

Six patients had *P carinii* alone and another had *P carinii* and *M tuberculosis*. The radiological features that made the presentation of these patients atypical for pneumocystis pneumonia are listed in table 2. In 14 patients other diagnoses were made (fig 3). In three patients no specific diagnosis was made. One patient, who was having treatment for cerebral toxoplasmosis with sulphadiazine and pyrimethamine and who also had cutaneous Kaposi's sarcoma, presented with a rapid onset of high fever and cough and right middle lobe consolidation on his chest radiograph (confirmed by computed tomography). At bronchoscopy no endobronchial lesion was seen, biopsy and lavage specimens from the middle lobe were negative, and the consolidation cleared rapidly without treatment. A second patient, with a four week history of fever and

Table 2 Radiographic appearances in seven patients with pneumonia thought not to be typical of *Pneumocystis carinii* in whom the organism was found by bronchoscopy

| Patient No | Radiographic appearances |
|------------|--|
| 1 | Bilateral basal bronchiectasis |
| 2 | Left subpulmonary effusion and interstitial lines |
| 3* | Left upper lobe consolidation and cavitation |
| 4 | Right upper lobe apical segment consolidation and cavitation |
| 5 | Right pleural effusion, left hilum enlarged, mediastinal lymphadenopathy |
| 6 | Bilateral upper lobe consolidation with volume loss |
| 7 | Right apical consolidation |

*Also infected with *Mycobacterium tuberculosis*.

cough without dyspnoea and radiological evidence of a left subpulmonary effusion, also had negative biopsy and lavage specimens and spontaneous resolution of his symptoms and effusion. The third patient, with a three month history of cough and exertional dyspnoea, had a bulky left hilum on the chest radiograph but no endobronchial abnormality was detected at bronchoscopy and laboratory investigations gave negative results. His symptoms improved and a subsequent computed tomogram of the thorax was normal.

The mean (range) arterial oxygen tensions at presentation were 9.5 (5.2–12.2) kPa for group 1 and 10.8 (7.8–14) kPa for group 2. The standard error of the difference between means was 2.819 ($p < 0.01$).

Induced sputum was obtained from 10 of the 40 patients with bronchoscopically confirmed pneumocystis pneumonia. None of these specimens was positive for *P. carinii*; nine showed a mixed growth of upper respiratory tract commensals, and one had no growth. Induced sputum was not obtained in the two patients with clinically suspected (but bronchoscopically negative) pneumocystis pneumonia or in two of the patients with other diagnoses. The induced sputum in the patient with a heavy mixed growth of *S. aureus*, β haemolytic streptococci, and *Branhamella catarrhalis* contained a mixed growth of upper respiratory tract commensals.

Discussion

The first case of AIDS in the United Kingdom was described in 1981⁸ and by December 1988 there had been 1982 cases and 1059 deaths.⁴ The lung is the organ most commonly affected in AIDS^{5,6} and over 60% of patients with AIDS will have a respiratory illness during the course of their disease,⁶ many experiencing repeated respiratory illnesses. Fibreoptic bronchoscopy is generally regarded as the procedure of choice for diagnosing pulmonary opportunistic infections in HIV-1 antibody positive patients with symptoms.⁹ It is recommended that both bronchoalveolar lavage and transbronchial biopsy are performed⁹ as the yield from these two procedures is complementary and extremely high.¹³ The potential impact of this policy in AIDS, with a projected doubling time of the number of cases in the United Kingdom of 11 months, is of great practical importance.

In the general population fibreoptic bronchoscopy is known to be a safe procedure with an extremely low risk of complications,¹⁰ but in patients who are HIV-1 antibody positive the complication rate associated with bronchoscopy is much higher.^{11,12} The complications are largely associated with transbronchial biopsy and occur whether or not fluoroscopic control is

used.¹² The risk of complications, particularly haemorrhage and pneumothorax, is particularly high when transbronchial biopsy is performed in patients whose lungs are infected with *P. carinii*.¹² At the time of this study we routinely carried out both lavage and transbronchial biopsy, but now no longer perform transbronchial biopsy because of the risk of complications and the low yield of additional diagnoses it produces.¹³

The use of induced sputum is a useful initial step in experienced laboratories in the evaluation of HIV-1 antibody positive patients with respiratory symptoms;¹⁴ it should eventually help to reduce the number of bronchoscopic investigations performed, but it will not completely remove the need. Its diagnostic accuracy is up to 79%.¹⁴ Bronchoscopy will still be necessary in those with negative results from induced sputum examination and in those whose clinical diagnosis and response to treatment are at variance with the microbiological or cytological diagnosis obtained from induced sputum. At the time of this study induced sputum examination was not routinely available in our hospital and bronchoscopy was the usual investigation.

Pneumocystis pneumonia is the mode of presentation in over half of all cases of AIDS,^{6,15} and it is responsible for up to 85% of all cases of pneumonia in AIDS.^{5,16} In this study the typical presenting features of pneumocystis pneumonia (group 1, table 1) included a dry cough, which might have been of short or long duration,^{17,18} and often a sensation of difficulty in taking in a deep breath.⁷ Pyrexia was almost invariable but patients rarely complained of fever.¹⁹ On examination the chest may be entirely normal or fine basal crackles may be heard. Signs of consolidation suggest bacterial infection and pleural effusion tuberculosis,¹⁹ and these features would be atypical (group 2, table 1). The chest radiograph in *P. carinii* infection is typically normal initially.²⁰ Subsequently diffuse reticular shadowing, particularly in the perihilar region, is seen and this may progress to give diffuse air space consolidation resembling pulmonary oedema.²¹ In the late stages the lung may be massively consolidated and almost airless.²² Atypically, *P. carinii* may also produce focal changes and cavitation on the chest radiograph, suggesting tuberculosis,²³ or cystic or honeycomb lesions or hilar enlargement.²² Focal abnormalities or localised consolidation are changes more typical of bacterial pneumonia.²⁴ Pleural effusions and mediastinal lymphadenopathy are rarely seen with pneumocystis pneumonia and suggest other diseases, in particular Kaposi's sarcoma, tuberculosis, and fungal infection.²⁵

Arterial blood gas analysis may show normal oxygen tensions in patients with pneumocystis pneumonia but hypoxaemia is more usual. In one

study it was present in almost 80% of patients with pneumocystis pneumonia.²⁶

The policy adopted in this study has been criticised²⁷ because (1) a definite pathogen could not be identified; (2) AIDS related pneumonia may be caused by a wide range of pathogens, frequently with a second pathogen⁵; (3) a therapeutic response to high dose co-trimoxazole does not preclude the possibility of an infection with bacteria sensitive to co-trimoxazole; (4) identification of *P. carinii* (or other opportunist organisms) establishes the diagnosis of AIDS,²⁸ and permits discussion of the disease and prognosis with the patient, which is not possible if the diagnosis is "high dose co-trimoxazole responsive pneumonia."

Since then it has become apparent that second pathogens are not seen as frequently as previously reported (PC Hopewell, personal communication) and in particular the role of cytomegalovirus as a pathogen in AIDS related pneumonia has been questioned.²⁹ Multiple bacterial isolates are often encountered in both induced sputum and lavage fluid but their role as pathogens is doubtful. The technique of protected catheter acquisition of samples at fiberoptic bronchoscopy and their quantitative microbiological analysis gives reliable information where multiple organisms are seen in routine cultures of induced sputum or lavage fluid,^{30,31} but these techniques are not widely used.

An empirical approach raises important ethical issues: in particular, can an HIV-1 antibody positive patient be confidently told that he or she has pneumocystis pneumonia on clinical grounds without bronchoscopy? This and other issues, however, have now largely been resolved with the revision of the case definition criteria for AIDS,³² as a clinical diagnosis of pneumocystis pneumonia with response to anti-pneumocystis treatment in an HIV-1 antibody positive patient is sufficient to make a diagnosis of AIDS and places the patient in CDC category IV c.³² In addition, in recent months it has become apparent that a substantial proportion if not all of the HIV-1 antibody positive patients will ultimately develop AIDS.³³

In our patients who presented with features typical of pneumocystis pneumonia (group 1) two patients had negative results in investigations but responded rapidly to treatment and were thought to have pneumocystis pneumonia. One of the three remaining patients, who had lymphoid interstitial pneumonitis and *B. catarrhalis*, would not have improved by day 5 of treatment and would have had bronchoscopy at that stage. An empirical approach would have been detrimental in the two other cases as they would have received inappropriately high doses of antibiotics with the associated risks of toxicity, and as they responded to high dose intravenous co-trimoxazole would have

been misdiagnosed as having AIDS. One of these two patients already had Kaposi's sarcoma, so the error would not have altered the diagnosis of AIDS; the other developed Kaposi's sarcoma within six months of this respiratory episode. Bronchoscopy was justified in all the patients with atypical presentations (group 2). Adopting an empirical approach would have been the correct decision in 43 of the 45 patients (95%) in group 1 and would have obviated bronchoscopy in 44 of the 69 patients (64%). This empirical approach to treating pneumocystis pneumonia has a specificity of 85% and a sensitivity of 85%.

This is the first study to confirm the validity of an empirical treatment policy for pneumocystis pneumonia. Empirical treatment of patients presenting with clinical and radiological features typical of pneumocystis pneumonia led to the correct management in over 95% of cases. Adopting this policy would potentially be associated with a greater than 63% reduction in the number of bronchoscopies carried out on HIV positive patients with respiratory symptoms. The implications in terms of work load for chest physicians and those caring for HIV positive patients are obvious. An empirical treatment policy carries a small risk of overdiagnosis of AIDS, but it remains to be seen whether this is of major importance in the light of current knowledge of the disease progression of HIV infection.

IVDW is a Wellcome Trust senior lecturer in infectious diseases. We would like to thank Dr Brian Newman, department of statistics, University College London, for statistical advice and Miss Annette Skinner for typing the manuscript.

References

- 1 Broaddus C, Dake MD, Stulberg MS, *et al.* Bronchoalveolar lavage and transbronchial biopsy for the diagnosis of pulmonary infections in the acquired immunodeficiency syndrome. *Ann Intern Med* 1985;102:747-52.
- 2 Hartman B, Koss M, Hill A, *et al.* *Pneumocystis carinii* pneumonia in the acquired immunodeficiency syndrome (AIDS). Diagnosis with bronchial washings, biopsy and broncho-alveolar lavage. *Chest* 1985;87:603-7.
- 3 Stover DE, White DA, Romano PA, Gellene RA. Diagnosis of pulmonary disease in acquired immune deficiency syndrome (AIDS): role of bronchoscopy and broncho-alveolar lavage. *Am Rev Respir Dis* 1984;130:659-62.
- 4 Communicable Diseases Surveillance Centre. Communicable diseases report 1988. *Br Med J* 1989;298:142.
- 5 Murray JF, Felton CP, Garay SM, *et al.* Pulmonary complications of the acquired immunodeficiency

- syndrome. *N Engl J Med* 1984;**310**:1682-8.
- 6 Centres for Disease Control. CDC update: acquired immunodeficiency syndrome—United States. *MMWR* 1986;**35**(2):17-21.
 - 7 Pozniak AL, Tung KT, Swinburn CR, *et al.* Clinical and bronchoscopic diagnosis of suspected pneumonia related to AIDS. *Br Med J* 1986;**293**:797-9.
 - 8 Dubois RM, Branthwaite MA, Mikhalis A, Batten JC. Primary *Pneumocystis carinii* and cytomegalovirus infections [letter]. *Lancet* 1981;ii:1339.
 - 9 Murray JF, Garay SM, Hopewell PC, *et al.* Pulmonary complications of the acquired immunodeficiency syndrome: an update. Report of the second National Heart Lung and Blood Institute Workshop. *Am Rev Respir Dis* 1987;**135**:504-9.
 - 10 Simpson FG, Arnold AG, Purvis A, *et al.* Postal survey of bronchoscopic practice by physicians in the United Kingdom. *Thorax* 1986;**41**:311-7.
 - 11 Milligan SA, Luce JM, Golden J. Transbronchial biopsy without fluoroscopy in patients with diffuse roentgenographic infiltrates and the acquired immunodeficiency syndrome. *Am Rev Respir Dis* 1988;**137**:486-8.
 - 12 Miller RF, Millar AB, Semple SJG. Complications of fiberoptic bronchoscopy in HIV-1 antibody patients undergoing investigations for pulmonary disease [abstract]. *Thorax* 1988;**43**:847P.
 - 13 Griffiths MH, Kocjan G, Miller RF, Godfrey-Faussett P. Diagnosis of pulmonary disease in human immunodeficiency virus infection: the role of transbronchial biopsy and bronchoalveolar lavage. *Thorax* 1989;**44**:554-8.
 - 14 Chaisson RF, Hopewell PC. Empiric diagnosis of pneumocystis pneumonia [letter]. *JAMA* 1987;**258**:3385.
 - 15 Centres for Disease Control. CDC. Update: Acquired immunodeficiency syndrome—Europe. *MMWR* 1986;**35**(2):35-44.
 - 16 Hopewell PC, Luce JM. Pulmonary manifestations of the acquired immunodeficiency syndrome. *Clin Immunol Allergy* 1986;**6**:489-518.
 - 17 Engelberg LA, Lerner CW, Tapper ML. Clinical features of *Pneumocystis pneumonia* in the acquired immune deficiency syndrome. *Am Rev Respir Dis* 1984;**130**:689-94.
 - 18 Swinburn CR, Pozniak AL, Sutherland S, *et al.* Early experience and difficulties with bronchoalveolar lavage and transbronchial biopsy in the diagnosis of AIDS associated pneumonia in Britain. *Thorax* 1985;**40**:166-70.
 - 19 Millar AB. Respiratory manifestations of AIDS. *British Journal of Hospital Medicine* 1988;**3**:204-15.
 - 20 Goodman JL, Tashki DP. *Pneumocystis* when normal chest x-ray film and arterial oxygen tension: early diagnosis in a patient with the acquired immune deficiency syndrome. *Ann Intern Med* 1983;**81**:11-8.
 - 21 Cohen BA, Pomeran ZS, Rabinowirz JG, *et al.* Pulmonary complications of AIDS: radiologic features. *AJR* 1984;**143**:115-22.
 - 22 De Lorenzo LJ, Huang CT, Maguire GP, *et al.* Roentgenographic patterns of pneumocystis carinii pneumonia in 104 patients with AIDS. *Chest* 1987;**91**:323-7.
 - 23 Milligan SA, Stulberg MS, Gamsu G, Golden JA. *Pneumocystis carinii* pneumonia radiographically simulating tuberculosis. *Am Rev Respir Dis* 1985;**132**:1124-6.
 - 24 Polsky B, Gold JWM, Whimbey E, *et al.* Bacterial pneumonia in patients with the acquired immunodeficiency syndrome. *Ann Intern Med* 1986;**104**:38-41.
 - 25 Meduri GU, Stover DE, Lee M, *et al.* Pulmonary Kaposi's sarcoma in the acquired immune deficiency syndrome. Clinical, radiographic and pathologic manifestations. *Am J Med* 1986;**81**:11-8.
 - 26 Rosen MJ, Wytow T, Teirstein AS, *et al.* Diagnosis of pulmonary complications of the acquired immune deficiency syndrome. *Thorax* 1985;**40**:571-5.
 - 27 Shaw RJ, Pinching AJ, Keal FE. Clinical and bronchoscopic diagnosis of suspected pneumonia related to AIDS [letter]. *Br Med J* 1986;**293**:1502.
 - 28 Centres for Disease Control, US Department of Health and Human Services. Classification system for human T-lymphotropic virus type III/lymphadenopathy-associated virus infections. *Ann Intern Med* 1986;**105**:234-7.
 - 29 Millar AB, Miller RF, Patou G, *et al.* Cytomegalovirus; respiratory pathogen or passenger in AIDS? [Abstract]. *Thorax* 1988;**45**:848P.
 - 30 Pollock HM, Hawkins EL, Bonner JR, *et al.* Diagnosis of bacterial pulmonary infections with quantitative protected catheter cultures obtained during bronchoscopy. *J Clin Microbiol* 1983;**17**:255-9.
 - 31 Wimberley NW, Bass JB, Boyd BW, *et al.* Use of a bronchoscopic protected catheter brush for the diagnosis of pulmonary infections. *Chest* 1982;**81**:556-62.
 - 32 Centres for Disease Control. Revision of the CDC surveillance case definition for acquired immunodeficiency syndrome. *MMWR* 1987;**36**(suppl):15.
 - 33 Moss AR, Bacchetti P, Osmond D, *et al.* Seropositivity for HIV and the development of AIDS or AIDS related condition: three year follow-up of the San Francisco General Hospital cohort. *Br Med J* 1988;**296**:745-50.