

# Spontaneous Pneumomediastinum: An Unusual Pulmonary Complication in Anorexia Nervosa

**Kyung-Jin Lee, M.D., Ho-Kee Yum, M.D. and I-Nae Park, M.D.**

Department of Internal Medicine, Inje University Sanggye Paik Hospital, Inje University College of Medicine, Seoul, Korea

Spontaneous pneumomediastinum (PM) is an uncommon condition in which free air enters the mediastinum. This usually occurs either through esophageal tears after vigorous vomiting, or after alveolar rupture subsequent to a rapid increase in intra-alveolar pressure. Spontaneous PM is a rare entity in anorexia nervosa (AN) and self-induced vomiting is often the cause of PM in patients with AN. We experienced a case of spontaneous PM in an anorexic adolescent, in whom vomiting was not the cause of PM.

**Keywords:** Anorexia Nervosa; Mediastinal Emphysema; Subcutaneous Emphysema

## Introduction

Pneumomediastinum (PM) or air in the mediastinum may originate from the esophagus, lungs, or bronchial tree. Spontaneous PM usually results from alveolar wall rupture and must be distinguished from posttraumatic PM resulting from traumatic events. Alveolar rupture results from high intra-alveolar pressures, low peri-vascular pressures, or both. Air escaping from the alveoli tracks into the mediastinum during the breathing cycle as the pressure in the mediastinum decreases relative to the pulmonary parenchymal pressure. From there, air may track into the cervical subcutaneous tissues, epidural space, pericardium, and/or peritoneal cavity<sup>1-3</sup>. This patho-

physiological mechanism was described by Macklin et al. in 1944, and is known as the Macklin effect<sup>1</sup>.

Anorexia nervosa (AN) can be associated with a lot of medical complications. PM is rarely associated with AN. Vomiting, a common symptom in AN, is a known cause of PM<sup>4-6</sup>. But among the cases reported in a small case series, only a few were preceded by vomiting<sup>6,7</sup>. So, there has to be another cause placing patients with AN at risk for spontaneous PM.

We report a case of spontaneous PM in an anorexic adolescent, in whom vomiting was not the cause of PM.

## Case Report

A 14-year-old girl with known AN and extreme malnutrition was referred to us because of subcutaneous air in the neck and thorax on chest X-ray. She complained of unusual crackling sensation in her neck and both axillae since a couple of days. There was no dyspnea or chest pain. There was no history of trauma or injury and vomiting. She was a non-smoker. Before admission to the hospital, she showed loss of appetite and further history taking revealed an anorectic episode for more than 6 months, for which, she had been diagnosed with AN 1 month ago. Physical examination showed a blood pressure of 97/71 mm Hg, heart rate of 54 beats per minute, respiratory rate of 16 breaths per minute, and temperature of 36.5°C. Her height was 165 cm, weight 29 kg, and body mass index 10.7 kg/m<sup>2</sup>. There were signs of subcutaneous emphysema in the

**Address for correspondence:** I-Nae Park, M.D.

Department of Internal Medicine, Inje University Sanggye Paik Hospital, Inje University College of Medicine, 1342 Dongil-ro, Nowon-gu, Seoul 01757, Korea

**Phone:** 82-2-2270-0004, **Fax:** 82-2-2285-2286

**E-mail:** eanee@hanmail.net

**Received:** Feb. 4, 2015

**Revised:** Mar. 20, 2015

**Accepted:** Apr. 9, 2015

©It is identical to the Creative Commons Attribution Non-Commercial License (<http://creativecommons.org/licenses/by-nc/4.0/>).

Copyright © 2015

The Korean Academy of Tuberculosis and Respiratory Diseases.

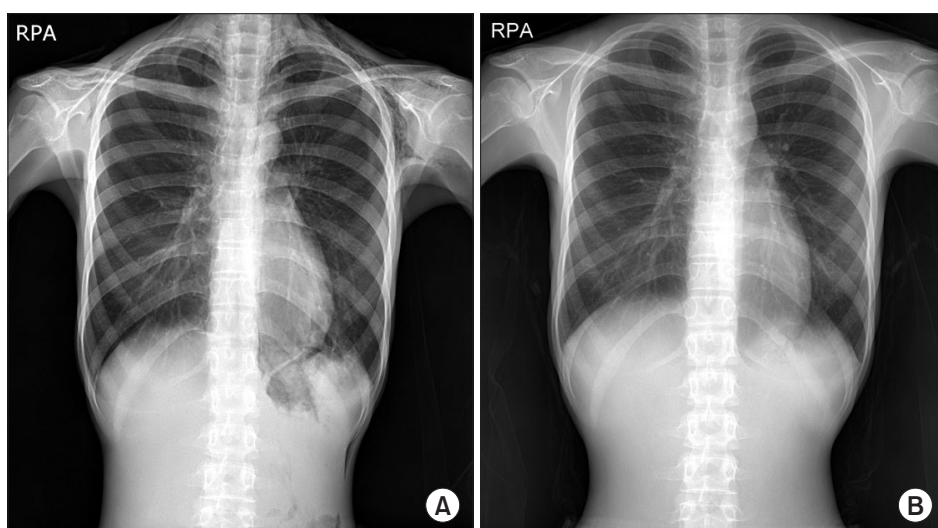
All rights reserved.

neck and in both axillae. She had lanugo on the whole body with no signs of injury or trauma. Cardiac evaluation showed normal heart sounds without a cardiac murmur. On auscultation, there were normal bilateral vesicular breath sounds. Laboratory data on admission revealed a normal leukocyte count (6,130/ $\mu$ L), mild normocytic anemia (hemoglobin, 11.3 mg/dL), elevated levels of alanine aminotransferase (50 IU/L) and lactate dehydrogenase (383 IU/L), and decreased level of protein (6.2 g/dL). Chest X-ray and computed tomography scan showed subcutaneous emphysema in the neck and mediastinal emphysema with extension into the intra-abdominal, retroperitoneal, and epidural regions (Figures 1, 2). There was no pneumothorax. An esophageal gastric passage radiograph showed no abnormalities, and no signs of esophageal perforation were evident. Laryngoscopic findings were also within normal limits, without signs of mucosal lesions or submucosal swelling. Evaluation of the endocrinology laboratory data showed that her follicle-stimulating hormone (0.8 mIU/mL),

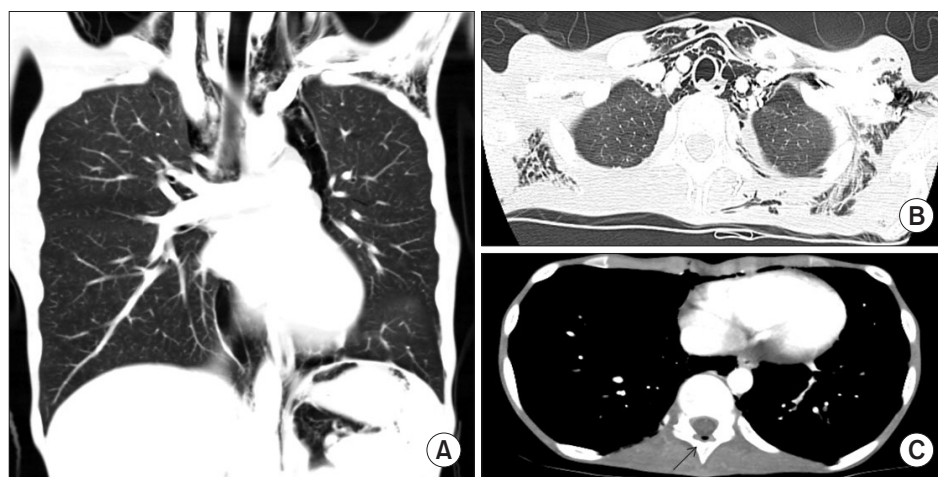
luteinizing hormone (<0.07 mIU/mL), and estradiol (6.4 pg/mL) levels were lowered. Her thyroid-stimulating hormone (4.57  $\mu$ IU/mL) and free T4 (0.83 ng/mL) levels were normal. After refeeding, she was referred to an eating disorders clinic to manage her eating disorder. She was advised to increase her oral intake, especially of high-calorie food. Her leukocyte count and hemoglobin level decreased gradually. Within 2 weeks, her subcutaneous emphysema resolved spontaneously. On the 17th day of hospitalization, her leukocyte count and hemoglobin level reached 2,770/ $\mu$ L and 9.8 g/dL, respectively. At 2 months after discharge, her leukocyte count and hemoglobin level returned to the normal range without any blood transfusion or infection.

## Discussion

Spontaneous PM is an uncommon and generally benign



**Figure 1.** Chest X-ray at the time of admission (A) and on the 10th day of hospitalization (B). Marked improvement in diffuse soft tissue emphysema can be seen.



**Figure 2.** Computed tomography (CT) in the patient with mediastinal emphysema and subcutaneous emphysema in both axillae and lower neck regions. CT scan shows subcutaneous emphysema in the neck and mediastinal emphysema with extension into the intra-abdominal, retroperitoneal (A, B), and epidural regions. Arrow indicates epidural pneumatosis (C).

entity developing in the absence of traumatic or iatrogenic events. Usually, respiratory maneuvers with high intrathoracic pressures (Valsalva maneuver, severe coughing, energetic crying, or vigorous vomiting) have been implicated in its development<sup>2,8</sup>. The increase in intra-alveolar pressure causes alveolar rupture and escape of air into the mediastinal space. Spontaneous PM rarely requires surgical drainage inasmuch as it usually resolves spontaneously. PM is sometimes observed in AN: self-induced vomiting causing an esophageal laceration is frequently the cause of PM in these patients. However, our patient had no history of vomiting, and thorough diagnostic procedures showed no signs of esophageal or upper airway laceration. The pathophysiologic mechanism of PM in our patient can be explained by an alveolar wall rupture, with consequent air leak into the mediastinum.

Of the many body systems adversely affected by severe AN, the pulmonary system may also be affected. Although rare, there are descriptions of spontaneous pneumothorax, spontaneous PM, diffuse soft tissue emphysema, and emphysema-like changes in patients with AN<sup>6,9-13</sup>. Purging behaviour, such as self-induced vomiting, is common among AN patients. Vomiting is a known cause of PM, placing anorexia patients, who frequently vomit, at risk for PM. However, in only a few of the cases described in the literature, vomiting was the preceding event of PM<sup>6</sup>. The pathophysiologic mechanism of air entrance into the mediastinum can be explained by the rupture of an alveolar wall, which is mostly the cause of an air leak into the mediastinum. Based on the literature and our observations, patients with AN are at risk for spontaneous PM, even if they are not vomiting.

Animal studies reveal that calorie restriction results in an important loss of alveoli and a fall in gas-exchange tissue and thinner alveolar walls<sup>14</sup>. Also in human studies, atrophic changes, such as large alveoli and thin alveolar walls, due to starvation were found in Jewish people<sup>15</sup>. With thinner alveolar walls and the loss of alveoli, malnourished individuals are at risk of alveolar wall rupture. Therefore, even with a minimal increase in intra-alveolar pressure, such as that which may occur during usual daily activities, such as a choking incident, can become the cause of air leaks, as observed in our case.

In conclusion, we can suppose that severe malnutrition, causing weakness of the alveolar wall and thinning of the connective tissue, can explain the occurrence of spontaneous PM in our patient.

## Conflicts of interest

No potential conflict of interest relevant to this article was reported.

## References

1. Murayama S, Gibo S. Spontaneous pneumomediastinum and Macklin effect: overview and appearance on computed tomography. *World J Radiol* 2014;6:850-4.
2. Al-Mufarrej F, Badar J, Gharagozloo F, Tempesta B, Strother E, Margolis M. Spontaneous pneumomediastinum: diagnostic and therapeutic interventions. *J Cardiothorac Surg* 2008;3:59.
3. Macia I, Moya J, Ramos R, Morera R, Escobar I, Saumench J, et al. Spontaneous pneumomediastinum: 41 cases. *Eur J Cardiothorac Surg* 2007;31:1110-4.
4. Overby KJ, Litt IF. Mediastinal emphysema in an adolescent with anorexia nervosa and self-induced emesis. *Pediatrics* 1988;81:134-6.
5. Folsom T, Realmuto G. Pneumomediastinum in an adolescent female with anorexia nervosa. *Int J Eat Disord* 1984;3:67-70.
6. van Veelen I, Hogeman PH, van Elburg A, Nielsen-Abbring FW, Heggelman BG, Mahieu HF. Pneumomediastinum: a rare complication of anorexia nervosa in children and adolescents: a case study and review of the literature. *Eur J Pediatr* 2008;167:171-4.
7. Lin LY, Kwok CF, Tang KT, Ho LT, Lin HD. Diffuse soft tissue emphysema in anorexia nervosa: a case report. *Int J Eat Disord* 2005;38:277-80.
8. Filosso PL, Garabello D, Lyberis P, Ruffini E, Oliaro A. Spontaneous pneumomediastinum: a rare complication of anorexia nervosa. *J Thorac Cardiovasc Surg* 2010;139:e79-80.
9. Goldstein MA, Herzog DB, Misra M, Sagar P. Case records of the Massachusetts General Hospital. Case 29-2008. A 19-year-old man with weight loss and abdominal pain. *N Engl J Med* 2008;359:1272-83.
10. Adson DE, Crow SJ, Mitchell JE. Spontaneous pneumothorax in anorexia nervosa. *Psychosomatics* 1998;39:162-4.
11. Corless JA, Delaney JC, Page RD. Simultaneous bilateral spontaneous pneumothoraces in a young woman with anorexia nervosa. *Int J Eat Disord* 2001;30:110-2.
12. Fergusson RJ, Shaw TR, Turnbull CM. Spontaneous pneumomediastinum: a complication of anorexia nervosa? *Postgrad Med J* 1985;61:815-7.
13. Coxson HO, Chan IH, Mayo JR, Hlynsky J, Nakano Y, Birmingham CL. Early emphysema in patients with anorexia nervosa. *Am J Respir Crit Care Med* 2004;170:748-52.
14. Massaro D, Massaro GD, Baras A, Hoffman EP, Clerch LB. Calorie-related rapid onset of alveolar loss, regeneration, and changes in mouse lung gene expression. *Am J Physiol Lung Cell Mol Physiol* 2004;286:L896-906.
15. Winick M. Hunger disease: studies by the Jewish physicians in the Warsaw Ghetto. New York: Wiley; 1979. p. 221-3.