

Symptomatic flexible flatfoot in adults: subtalar arthroereisis

Firat Ozan¹
Fatih Dođar¹
Kürřat Gençer¹
řemmi Koyuncu²
Fatih Vatansever¹
Fuat Duygulu¹
Tařkın Altay³

¹Department of Orthopedics and Traumatology, Kayseri Training and Research Hospital, Kayseri,

²Department of Orthopedics and Traumatology, Bayburt State Hospital, Bayburt, ³Department of Orthopedics and Traumatology, İzmir Bozyaka Training and Research Hospital, İzmir, Turkey

Abstract: Flexible flatfoot is a common deformity in pediatric and adult populations. In this study, we aimed to evaluate the functional and radiographic results of subtalar arthroereisis in adult patients with symptomatic flexible flatfoot. We included 26 feet in 16 patients who underwent subtalar arthroereisis for symptomatic flexible flatfoot. Radiographic examination included calcaneal inclination angle, lateral talocalcaneal angle, Meary's angle, anteroposterior talonavicular angle, and Kite's angle. The clinical assessment was based on the American Orthopaedic Foot and Ankle Society (AOFAS) hindfoot scale and a visual analog scale (VAS). The mean follow-up was 15.1±4.7 months. The mean preoperative AOFAS score was 53±6.6, while the mean AOFAS score at the last follow-up visit was 75±11.2 ($P<0.05$). The mean visual analog scale score was 6.9±0.6 preoperatively and 4.1±1.4 at the last follow-up visit ($P<0.05$). The mean preoperative and postoperative values measured were 13.4°±3.3° and 14.6°±2.7° for calcaneal inclination angles ($P<0.05$); 35.7°±6.9° and 33.2°±5.3° for lateral talocalcaneal angles ($P>0.05$); 8°±5.3° and 3.3±3 for Meary's angles ($P<0.05$); 5.6°±3.5° and 2.6°±1.5° for anteroposterior talonavicular angles ($P<0.05$); and 23.7°±6.1° and 17.7°±5° for Kite's angles, respectively ($P<0.05$). Implants were removed in three feet (11.5%). Subtalar arthroereisis is a minimally invasive procedure that can be used in the surgical treatment of adults with symptomatic flexible flatfoot. This procedure provided radiological and functional recovery in our series of patients.

Keywords: arthroereisis, flatfoot, sinus tarsi implant, pes planus

Introduction

Flexible flatfoot is a common deformity in children and adults.^{1,2} It is characterized by medial rotation and plantar flexion of the talus, eversion of the calcaneus, collapsed medial arch, and abduction of the forefoot.³⁻⁵ In general, infants are born with a flexible flatfoot, with the arch of the foot typically developing during the first decade of life.^{1,6} Most flexible flatfoot cases resolve spontaneously or remain asymptomatic, whereas symptomatic and pathological conditions require treatment.^{1,7}

Various conservative and surgical procedures have been defined in the treatment of symptomatic flexible flatfoot.^{5,8,9} Conservative interventions include shoe modification, brace, physical therapy, and exercise modifications.¹⁰ Surgery is indicated in patients in whom conservative interventions fail,^{11,12} and encompasses both soft-tissue and bone procedures.^{4,13} Surgery mainly includes muscle and tendon lengthening, tendon transfer, osteotomy, arthrodesis, and arthroereisis.^{4,5,10,13} It has been well documented that subtalar arthroereisis is an effective surgical procedure in the treatment of flexible flatfoot in adults, minimizing pain, deformity, and instability.^{2,8,14} Despite controversial opinions on the optimal technique and implant, the principle of reducing overpronation has been widely accepted.^{2,4,15} Subtalar joint implants previously consisted of a bone graft; however, various specifically designed implants are currently used.^{2,8,10,14}

Correspondence: Firat Ozan
Department of Orthopedics and Traumatology, Kayseri Training and Research Hospital, Sanayi Mahallesi, Atatürk Bulvarı Hastane Caddesi, Kocasinan, 38010 Kayseri, Turkey
Email firatozan9@gmail.com

In the present study, clinical and radiographic outcomes as well as related complications of subtalar arthroereisis were assessed in adult patients with symptomatic flexible flatfoot.

Materials and methods

The study included 26 feet (13 left, 13 right) of 16 patients (four females, twelve males) treated with subtalar arthroereisis between 2011 and 2013 for a symptomatic flexible flatfoot deformity (Table 1). Patients with a flatfoot deformity secondary to a neuromuscular condition, congenital condition, or trauma-related injury were excluded. The study included patients with a flexible flatfoot deformity that did not respond to conservative therapies such as stretch exercises, activity modification, and orthosis for at least 6 months, and thus underwent surgery. Patients complained of pain at the midfoot and hindfoot during long walks and while standing, early fatigue, leg pain, and inability to wear some types of shoes.

Pre- and postoperative radiographic examination included calcaneal pitch angle, lateral talocalcaneal (LTC) angle, Meary's angle, anteroposterior talonavicular (APTN) angle, and Kite's angle.^{10,11}

The clinical assessment was based on the American Orthopaedic Foot and Ankle Society (AOFAS) hindfoot scale¹⁶ and a visual analog scale (VAS)¹⁷ (Figures 1 and 2). This study was conducted in accordance with the ethical guidelines of the Declaration of Helsinki, and informed consent was obtained from all patients.

Surgical technique

All patients were operated at the same center and by multiple surgeons. An approximately 2 cm incision was made through the sinus tarsi. Deep fascia and the capsule covering the tarsal sinus were incised using blunt dissection. The tarsal sinus was extended using a probe, and the subtalar joint axis was determined. A guide wire was advanced from lateral to medial through the tarsal tunnel. Tester implants were placed through the guide wire to choose the most suitable implant, and the range of motion of the posterior foot was assessed. A suitable implant (Horizon; BioPro, Port Huron, MI, USA) was then

placed, and the location of the implant was confirmed.^{8,10} The incision site was closed routinely. There was no other procedure performed in the same sitting.

Statistical analysis

Statistical analysis was performed using SPSS v16.0 software (SPSS Inc., Chicago, IL, USA). A paired Student's *t*-test was used to analyze data, and a *P*-value of <0.05 was considered statistically significant.

Results

The mean age was 24.3±5.24 (range, 18–35) years, and the mean follow-up was 15.1±4.7 (range, 7–22) months. The mean preoperative AOFAS score was 53±6.6 (range, 42–66), while the mean AOFAS score at the last follow-up visit was 75±11.2 (range, 58–95) (*P*=0.0001). The mean VAS score decreased from 6.9±0.6 (range, 6–9) preoperatively to 4.1±1.4 (range, 2–6) at the last follow-up visit (*P*=0.0001).

Based on the radiographic results, the mean preoperative and postoperative calcaneal inclination angles were 13.4°±3.3° (range, 6–19) and 14.6°±2.7° (range, 8°–20°), respectively (*P*=0.0377); mean preoperative and postoperative LTC angles, 35.7°±6.9° (range, 20°–46°) and 33.2°±5.3° (range, 24°–41°), respectively (*P*=0.0957); mean preoperative and postoperative Meary's angles, 8°±5.3° (range, 1°–17°) and 3.3°±3° (range, 0°–11°), respectively (*P*=0.0001); mean preoperative and postoperative APTN angles, 5.6°±3.5° (range, 1°–17°) and 2.6°±1.5° (range, 0.3°–6°), respectively (*P*=0.0001); and mean preoperative and postoperative Kite's angles, 23.7°±6.1° (range, 8°–38°) and 17.7°±5° (range, 10°–31°), respectively (*P*=0.0001) (Table 2).

Sinus tarsi pain occurred in three feet (11.5%), and the implant was removed in two (7.6%) of these feet: one at 1 year after surgery, and another in the 8th month after surgery. In one patient, sinus tarsi pain was managed by administering a nonsteroidal anti-inflammatory drug, but implant removal was not performed.

In one patient, the implant was removed in the 7th month after surgery because of loss of fixation (Figure 3). No infection or sensory defect was observed in any patient. In this study, the implant was removed postoperatively from three feet (11.5%).

Discussion

Subtalar arthroereisis involves inserting an implant into the sinus tarsi through a small incision to block excessive subtalar joint pronation and to elevate the talus. Subtalar arthroereisis provides not only satisfactory radiographic

Table 1 Patients' demographic characteristics

Number of patients (feet)	16 (26)
Age, years, mean (range)	24.3±5.24 (18–35)
Sex, n (%)	
Female	4 (25)
Male	12 (75)
Follow-up, months, mean (range)	15.1±4.7 (7–22)
Location, n (%)	
Right	13 (50)
Left	13 (50)

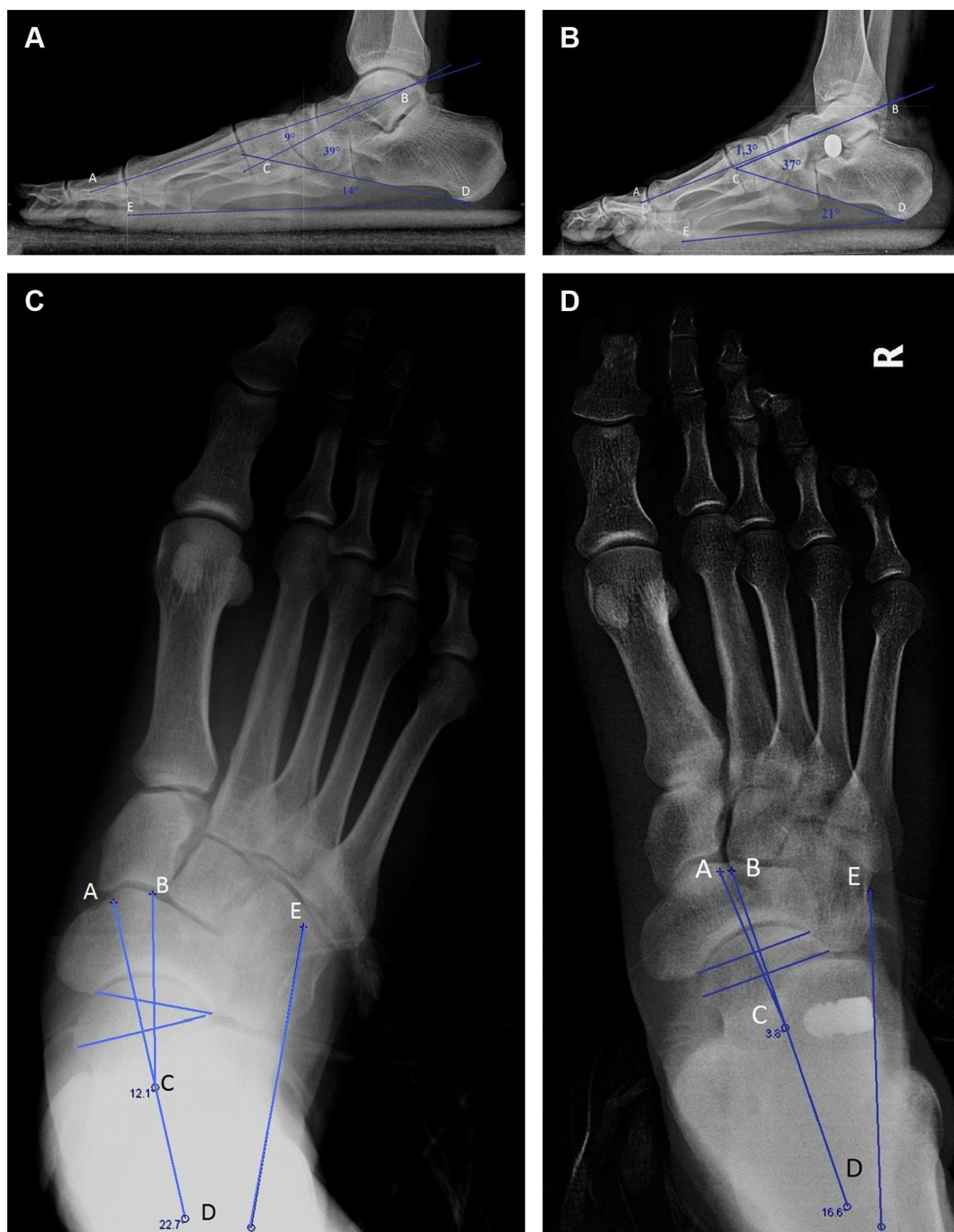


Figure 1 Pre- and postoperative angles.

Notes: Preoperative and postoperative (**A, B**) calcaneal inclination angle (CDE), lateral talocalcaneal angle (BCD), Meary's angle (ABC), (**C, D**) talonavicular angle (ACB), Kite's angle (ADE) (change from baseline).

Abbreviation: R, right foot.

outcomes but also good clinical outcomes. Significant decreases were observed in the VAS pain scores in the postoperative period compared with those in the preoperative period. The mean AOFAS score increased from 53 to 75 at the end of the follow-up.

Although several treatment options are available for the treatment of flexible flatfoot, no consensus on the

best treatment protocol for adequate recovery has been determined.^{9,10} Subtalar arthroereisis allows quick return to daily activities with relatively less pain compared with other surgical interventions.^{4,12} The main advantages of the procedure include the simplicity of the surgical technique without bone or cartilage defects, maintenance of skeletal maturation, low infection risk, and the option for implant

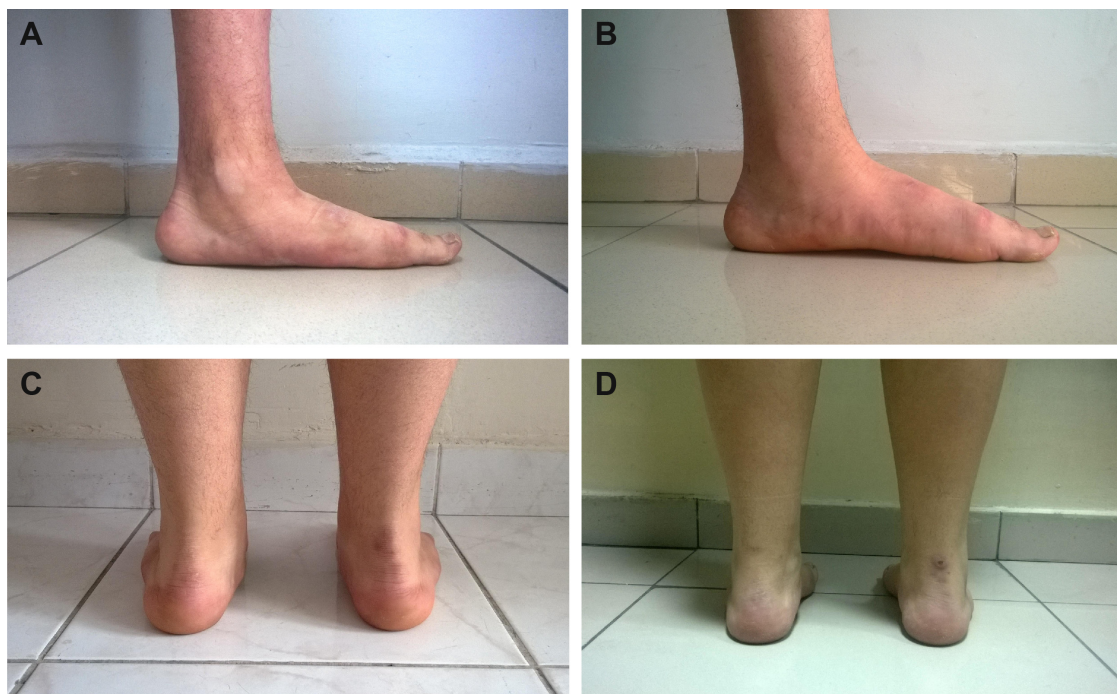

Figure 2 Preoperative and postoperative images of the patients in standing foot posture.
Notes: Change from baseline in (A, B) the foot arch in a patient, and (C, D) heel valgus in another patient.

removal, if required.^{4,15} Complete and painless range of motion of the subtalar joint can also be achieved after implant removal.¹⁵

Table 2 Comparison of preoperative and postoperative clinical and radiographic results

Variables	Preoperative (°)	Postoperative (°)	P-value
Calcaneal inclination			
Mean ± SD	13.4±3.3	14.6±2.7	0.0377
Range	6–19	8–20	
Meary's			
Mean ± SD	8±5.3	3.3±3	0.0001
Range	1–17	0–11	
LTC			
Mean ± SD	35.7±6.9	33.2±5.3	0.0957
Range	20–46	24–41	
APTN			
Mean ± SD	5.6±3.5	2.6±1.5	0.0001
Range	1–17	0.3–6	
Kite's			
Mean ± SD	23.7±6.1	17.7±5	0.0001
Range	8–38	10–31	
AOFAS			
Mean ± SD	53±6.6	75±11.2	0.0001
Range	42–66	58–95	
VAS			
Mean ± SD	6.9±0.6	4.1±1.4	0.0001
Range	6–9	2–6	

Abbreviations: SD, standard deviation; LTC, lateral talocalcaneal angle; APTN, anteroposterior talonavicular coverage angle; AOFAS, American Orthopaedic Foot and Ankle Society; VAS, visual analog scale.

In a study by Arangio et al³ in which subtalar arthroereisis was performed on a three-dimensional multisegment biomechanical model by using 6 mm implants, it was reported that the lateral talo-first metatarsal angle and the LTC angle increased to normal, arch height increased to 2 mm, and the talonavicular coverage angle decreased to normal. However, the authors reported that the force in the tendocalcaneus did not change compared with the normal foot and that the force in the flexor hallucis longus and the flexor digitorum longus remained virtually the same for the normal foot. In addition, the authors found that arthroereisis shifts the load from the joints of the medial column back toward the lateral column, decreases the moments at the talonavicular joint and the medial cuneiform–navicular joint, and decreases the forces in the medial extensions of the long plantar ligament and plantar aponeurosis.

Moreover, in a biomechanical study, Husain and Fallat¹⁸ reported that the movement of subtalar joint was progressively decreased by increasing thickness of implant and that lateral talo-first metatarsal, talar declination, calcaneal inclination, first metatarsal declination, and first intermetatarsal angles were affected.

In addition to favorable reported results, the complication rate of subtalar arthroereisis varies widely from 30% to 40%.^{2,4,9,14} The major complications include persistent sinus tarsi pain, osteonecrosis, subtalar joint arthrosis, overcorrection, loosened or broken implant, implant

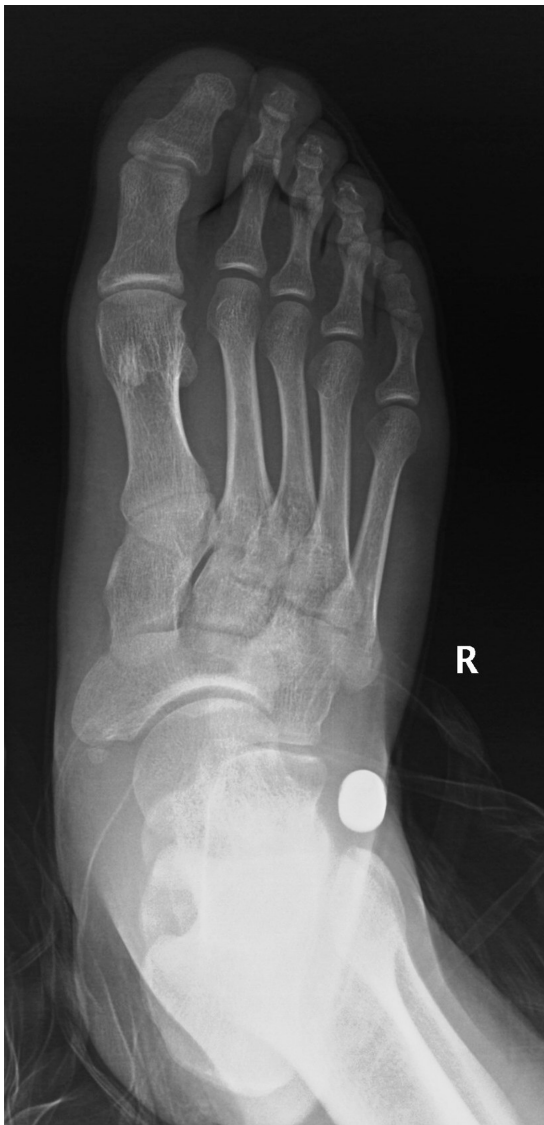

Figure 3 Anteroposterior X-ray showing fixation failure of the subtalar implant at 7 months postoperatively.

Abbreviation: R, right foot.

subluxation, incorrect fixation, and fracture.^{2,4,9,19} Implant removal is the initial intervention in the management of such complications.^{9,14}

The main cause of sinus tarsi pain, a common complication, is mechanical irritation to the soft tissues and bone by the implant.^{4,14,20} An incorrectly fixed implant or incorrectly sized implant may also induce sinus tarsi pain.^{2,4,10,14} In this study, sinus tarsi pain occurred in three feet (11.5%), and the implant was removed in two (7.6%) of these feet. In one patient, sinus tarsi pain was managed by administering a nonsteroidal anti-inflammatory drug, but implant removal was not performed. The implant was removed in one patient because of loss of fixation, and no clinical problem was observed after implant removal. However, the preoperative foot deformity recurred after implant removal. It can be considered an advantage that

no complication other than an incision scar developed after implant removal.

Implant design can be a factor in subtalar arthroereisis. Diverse outcomes can be achieved with implants of different designs. We think that the use of an inappropriately sized and shaped implant can be a factor responsible for loss of fixation. Using inappropriately sized implants can cause implant intolerance and sinus tarsi pain in the postoperative period. We selected an appropriate implant size by assessing hindfoot movements with test implants. However, the surgical criteria are not clear for the selection and insertion of implants of the appropriate size.

Similarly, in their anatomic study, Bali et al²¹ reported that the tarsal canal has a complex structure. Authors reported that implant selection can be made by applying implant to the patient under anesthesia, as there is no method for preoperative selection of an appropriate implant.

In a study including 28 feet in 23 patients, Needleman¹⁴ reported sinus tarsi pain in 46% of feet and implant removal in eleven feet (39%). In another study including 19 patients, Viladot et al¹³ reported that six patients (32%) suffered from sinus tarsi pain postoperatively and that the implant was removed in two patients (11%). Similarly, Giannini et al²⁰ showed that two of 21 patients (9.5%) had sinus tarsi pain that resolved after the degradation of the biomaterial. Consistent with these findings, Scharer et al¹⁰ reported the rate of sinus tarsi pain as 15%, Graham et al²² as 6%, and Nelson et al¹¹ as 5%.

We observed a mean increase of 22 in the AOFAS score postoperatively in our study. Viladot et al¹³ reported that the mean AOFAS score increased from 47 to 82 after surgery, and Needleman¹⁴ reported a 35-point increase in the mean AOFAS score with a significant improvement in the radiographic variables postoperatively. In another study including 34 feet in 20 patients, Jay and Din²³ found that the mean AOFAS score increased from 67.7 to 89 at the end of the follow-up.

According to the radiographic evaluation, we observed a significant improvement in all variables other than the LTC angle postoperatively. Similarly, Nelson et al¹¹ enrolled 67 feet in 37 patients during an 18-month follow-up (mean) and reported significant improvement in the talo-first metatarsal angle, anteroposterior talocalcaneal angle, and lateral talar declination angle. In another study including 60 feet in 35 patients, Brancheau et al¹² showed significantly increased talocalcaneal, calcaneocuboid, and first and second intermetatarsal angles, as well as calcaneal inclination and talar declination angles after surgery. In addition, Scharer et al¹⁰ enrolled 68 feet in 39 patients during a 24-month follow-up (mean). The authors demonstrated a significant improvement in the radiographic variables including APTN

coverage angle and lateral and anteroposterior talocalcaneal angles postoperatively.

Despite recent gains in understanding the mechanics and function of subtalar arthroereisis, the indications and contraindications of the procedure remain to be elucidated.^{2,20} The procedure is preferred mainly for the pediatric population, followed by adults,^{2,12} and can be performed in combination with other surgical techniques for the correction of several pathologies related to the flatfoot deformity.^{10,12,14,20,23} Our study is limited by the small sample size and lack of a control group. The measurements were done by one of us, and, therefore, no inter- or intraobserver reliability assessment was performed. However, further studies are needed to better define the effectiveness of subtalar arthroereisis. We believe that our study has contributed to the further understanding of the subtalar arthroereisis.

Subtalar arthroereisis is a feasible, minimally invasive technique that can be readily performed in adult patients with appropriate indications for surgical treatment of symptomatic flexible flatfoot. Moreover, subtalar arthroereisis can be considered a basic procedure in the treatment of flexible flatfoot.¹⁴ However, one should not anticipate correcting all components of a flexible flatfoot deformity with only subtalar arthroereisis. In addition, sinus tarsi pain and loss of fixation can occur as complications of the technique. It seems that the ability to remove the implant after the presentation of potential complications and the subsequent reversal of symptoms to restore complete and painless motion in the subtalar joint is a major advantage of the technique.

Disclosure

The authors report no conflicts of interest in this work.

References

1. Benedetti MG, Ceccarelli F, Berti L, et al. Diagnosis of flexible flatfoot in children: a systematic clinical approach. *Orthopedics*. 2011;34:94.
2. Van Ooij B, Vos CJ, Saouti R. Arthroereisis of the subtalar joint: an uncommon complication and literature review. *J Foot Ankle Surg*. 2012; 51:114–117.
3. Arangio GA, Reinert KL, Salathe EP. A biomechanical model of the effect of subtalar arthroereisis on the adult flexible flat foot. *Clin Biomech*. 2004;19:847–852.
4. Needleman RL. Current topic review: subtalar arthroereisis for the correction of flexible flatfoot. *Foot Ankle Int*. 2005;26:336–346.

5. Dogan A, Albayrak M, Akman YE, Zorer G. The results of calcaneal lengthening osteotomy for the treatment of flexible pes planovalgus and evaluation of alignment of the foot. *Acta Orthop Traumatol Turc*. 2006;40:356–366.
6. Cappello T, Song KM. Determining treatment of flatfeet in children. *Curr Opin Pediatr*. 1998;10:77–81.
7. Wenger DR, Leach J. Foot deformities in infants and children. *Pediatr Clin North Am*. 1986;33:1411–1427.
8. Baker JR, Klein EE, Weil L, Weil LS, Knight JM. Retrospective analysis of the survivability of absorbable versus nonabsorbable subtalar joint arthroereisis implants. *Foot Ankle Spec*. 2013;6:36–44.
9. Scher DM, Bansal M, Handler-Matasar S, Bohne WH, Green DW. Extensive implant reaction in failed subtalar joint arthroereisis: report of two cases. *HSSJ*. 2007;3:177–181.
10. Scharer BM, Black BE, Sockrider N. Treatment of painful pediatric flatfoot with Maxwell-Brancheau subtalar arthroereisis implant: a retrospective radiographic review. *Foot Ankle Spec*. 2010;3:67–72.
11. Nelson SC, Haycock DM, Little ER. Flexible flatfoot treatment with arthroereisis: radiographic improvement and child health survey analysis. *J Foot Ankle Surg*. 2004;43:144–155.
12. Brancheau SP, Walker KM, Northcutt DR. An analysis of outcomes after use of the Maxwell-Brancheau arthroereisis implant. *J Foot Ankle Surg*. 2012;51:3–8.
13. Viladot R, Pons M, Alvarez F, Omana J. Subtalar arthroereisis for posterior tibial tendon dysfunction: preliminary report. *Foot Ankle Int*. 2003;24:600–606.
14. Needleman RL. A surgical approach for flexible flatfeet in adults including a subtalar arthroereisis with the MBA sinus tarsi implant. *Foot Ankle Int*. 2006;27:9–18.
15. Zatti G, Teli M, Moalli S, Montoli C. Arthroereisis in flexible flatfoot treatment: comparative follow-up of two methods. *Foot Ankle Surg*. 1998;4:219–226.
16. Kitaoka HB, Alexander IJ, Adelaar RS, Nunley JA, Myerson MS, Sanders M. Clinical rating systems for the ankle-hindfoot, midfoot, hallux, and lesser toes. *Foot Ankle Int*. 1994;15:349–353.
17. Katz J, Melzack R. Measurement of pain. *Surg Clin North Am*. 1999;79: 231–252.
18. Husain ZS, Fallat LM. Biomechanical analysis of Maxwell-Brancheau arthroereisis implants. *J Foot Ankle Surg*. 2002;41:352–358.
19. Siff TE, Granberry WM. Avascular necrosis of the talus following subtalar arthroereisis with a polyethylene endoprosthesis: a case report. *Foot Ankle Int*. 2000;21:247–249.
20. Giannini S, Ceccarelli F, Benedetti MG, Catani F, Faldini C. Surgical treatment of flexible flatfoot in children: a four-year follow-up study. *J Bone Joint Surg Am*. 2001;83:73–79.
21. Bali N, Theivendran K, Prem H. Computed tomography review of tarsal canal anatomy with reference to the fitting of sinus tarsi implants in the tarsal canal. *J Foot Ankle Surg*. 2013;52:714–716.
22. Graham ME, Jawrani NT, Chikka A. Extraosseous talotarsal stabilization using HyProCure® in adults: a 5-year retrospective follow-up. *J Foot Ankle Surg*. 2012;51:23–29.
23. Jay RM, Din N. Correcting pediatric flatfoot with subtalar arthroereisis and gastrocnemius recession: a retrospective study. *Foot Ankle Spec*. 2013; 6:101–107.

Therapeutics and Clinical Risk Management

Publish your work in this journal

Therapeutics and Clinical Risk Management is an international, peer-reviewed journal of clinical therapeutics and risk management, focusing on concise rapid reporting of clinical studies in all therapeutic areas, outcomes, safety, and programs for the effective, safe, and sustained use of medicines. This journal is indexed on PubMed Central, CAS,

Submit your manuscript here: <http://www.dovepress.com/therapeutics-and-clinical-risk-management-journal>

Dovepress

EMBASE, Scopus and the Elsevier Bibliographic databases. The manuscript management system is completely online and includes a very quick and fair peer-review system, which is all easy to use. Visit <http://www.dovepress.com/testimonials.php> to read real quotes from published authors.