

Adverse effects of irreversible electroporation of malignant liver tumors under CT fluoroscopic guidance: a single-center experience

Marco Dollinger
Lukas Philipp Beyer
Michael Haimerl
Christoph Niessen
Ernst-Michael Jung
Florian Zeman
Christian Stroszczyński
Philipp Wiggermann

PURPOSE

We aimed to describe the frequency of adverse events after computed tomography (CT) fluoroscopy-guided irreversible electroporation (IRE) of malignant hepatic tumors and their risk factors.

METHODS

We retrospectively analyzed 85 IRE ablation procedures of 114 malignant liver tumors (52 primary and 62 secondary) not suitable for resection or thermal ablation in 56 patients (42 men and 14 women; median age, 61 years) with regard to mortality and treatment-related complications. Complications were evaluated according to the standardized grading system of the Society of Interventional Radiology. Factors influencing the occurrence of major and minor complications were investigated.

RESULTS

No IRE-related death occurred. Major complications occurred in 7.1% of IRE procedures (6/85), while minor complications occurred in 18.8% (16/85). The most frequent major complication was postablative abscess (4.7%, 4/85) which affected patients with bilioenteric anastomosis significantly more often than patients without this condition (43% vs. 1.3%, $P = 0.010$). Bilioenteric anastomosis was additionally identified as a risk factor for major complications in general ($P = 0.002$). Minor complications mainly consisted of hemorrhage and portal vein branch thrombosis.

CONCLUSION

The current study suggests that CT fluoroscopy-guided IRE ablation of malignant liver tumors may be a relatively low-risk procedure. However, patients with bilioenteric anastomosis seem to have an increased risk of postablative abscess formation.

About 70% of hepatic metastases are nonresectable because of their anatomic location, the presence of comorbidities, or limited hepatic functional reserve (1). In these patients and in case of nonresectable primary liver tumors, percutaneous thermal ablation procedures, such as radiofrequency (RF) and microwave ablation, have become effective tools for treating hepatic malignancies (2–4). However, the effectiveness of RF and microwave treatment may be limited, either because of thermal damage to temperature-sensitive structures located in close proximity to the target tissue (5) or because of incomplete ablation of tumors adjacent to major hepatic vessels due to a phenomenon commonly termed “heat-sink effect” (6–10) which describes the loss of the applied thermal energy through the blood flow in those major vessels, whereby the effective energy application remains inadequate to ablate the target lesion.

Irreversible electroporation (IRE) is a theoretically nonthermal ablation technique that delivers a series of high-voltage millisecond electrical pulses to the surrounding tissue, thus leading to irreversible disruption of the integrity of cell membranes and subsequent cell death by apoptosis (11–14). IRE may overcome the problems raised with thermal ablation: previous animal studies reported that bile ducts, blood vessels, nerves, and connective tissues are affected by IRE; however, regeneration is possible to some extent due to preservation of the tissue architecture (12, 13, 15–19). Moreover the feasibility of inducing cell death up to a vessel wall without any perivascular sparing was shown with IRE (12, 13, 18). The safety of IRE in the treatment of humans has been described (20). First reports have described potential complications after IRE, such as hemorrhage requiring blood transfusion (1.2%, two of 167 ablation procedures), portal vein thrombosis (3.2%, one of 31 ablation procedures), injury to bile ducts (1.8%, three of 167 ablation procedures), and infection (3.6%, six of 167 ablation procedures) (21, 22).

From the Department of Radiology (M.D. ✉ marco.dollinger@ukr.de, L.P.B., M.H., C.N., E.M.J., C.S., P.W.), the Center for Clinical Studies (F.Z.), University Medical Center Regensburg, Regensburg, Germany.

Received 29 January 2015; revision requested 3 March 2014; revision received 15 March 2015; accepted 8 April 2015.

Published online 31 August 2015.
DOI 10.5152/dir.2015.14442

However, few data are available for evaluating the potential risk factors associated with the occurrence of post-IRE complications.

The purpose of this study was to review the frequency of mortality and morbidity after computed tomography (CT) fluoroscopy-guided liver IRE conducted at a single center and assess the factors influencing the occurrence of major complications.

Methods

Patients

In this study, 85 IRE procedures in 56 patients with 114 malignant liver tumors (nonresectable and not suitable for thermal ablation) were retrospectively analyzed. The patient group consisted of 42 men (75%) and 14 women (25%) with a median age of 61 years (range, 22–81 years). There were 28 patients with 52 lesions of primary liver tumors and 28 patients with 62 lesions of secondary liver tumors (Table 1). The median follow-up period was 10 months (range, 0–28 months).

The median tumor diameter was 2.2 cm (range, 0.2–6.3 cm). In 61.2% of ablative procedures (52/85), the radiographic margins of index tumors were located within 1 cm to a major hepatic vessel, in 55.3% (47/85) within 1 cm to the liver capsule, and in 4.7% (4/85) within 1 cm of the diaphragm.

The median number of IRE sessions per patient was one (range, 1–4). The median procedure time was 172 min (range, 55–561 min), and a median of four electrodes (range, 2–6) were used. Twenty of 56 patients (35.7%) underwent two or more IRE treatments.

Study design and ablation procedure

The study was approved by the local ethics committee. Patients underwent IRE ablation if both surgical resection and thermal ablation were precluded. Exclusion criteria were presence of a cardiac pacemaker or a defibrillator, coagulation disorder, tumor

resectability, impossibility of general anesthesia, or multifocal hepatic disease not amenable to complete ablation.

All ablation procedures were conducted percutaneously under CT fluoroscopy guidance (CAREVision, SOMATOM Sensation 16, Siemens Healthcare) with the NanoKnife® System (Angiodynamics®). The parameters of IRE ablation were as follows: voltage, 1650 to 3000 V; pulse length, 90 μ s; pulses per cycle, 70. All patients were under general anesthetic and a deep neuromuscular block.

Follow-up after IRE

The first follow-up imaging was routinely conducted on the first working day after the ablation by means of an abdominal CT and/or magnetic resonance imaging (MRI). Routine physical examinations and laboratory tests were continued until the discharge of the patient, which was left to the discretion of the treating physician. Follow-up examinations were conducted on an outpatient basis and included dynamic MRI and/or CT imaging of the abdomen six weeks and 3–4 months after IRE ablation and every 3–4 months after that.

Complications

Complications were documented for each IRE session by evaluating medical records and radiologic images. Complications were defined according to the standardized grading system of the Society of Interventional Radiology (SIR) (23, 24). Major complications were defined as events that, if untreated, threatened the life of the patient, led to substantial morbidity and/or disability, or resulted in a lengthened hospital stay. All other complications were considered minor. Complications were categorized as immediate (within 24 hours after ablation),

periprocedural (1–30 days after ablation), and delayed (more than 30 days after ablation) according to the time point of diagnosis (23). According to the SIR grading system, common procedural side effects such as periprocedural pain, fever, and transient elevation of liver enzyme levels were excluded from the evaluation.

Statistical analysis

Risk factors influencing the occurrence of major complications were assessed by means of logistic regression models. Variables included previous liver therapy (status post liver resection or chemotherapy), the number of tumors treated, the number of IRE needles, tumor location (subcapsular or subphrenic), distance to major vessels (≤ 1 cm vs. > 1 cm), duration of the ablation procedure, liver cirrhosis, hemoglobin levels (< 12.0 g/dL vs. ≥ 12.0 g/dL), platelet count (< 150 /nL vs. ≥ 150 /nL), creatinine level (< 1.2 mg/dL vs. ≥ 1.2 mg/dL), partial thromboplastin time (≤ 40 s vs. > 40 s), anti-coagulation, and bilioenteric anastomosis. Odds ratios and corresponding 95% confidence intervals (CI) are reported as effect estimates. An exact unconditional test based on the Pearson's chi-squared statistic was used for a group-to-group comparison regarding the occurrence of postablative abscess formation between patients with bilioenteric anastomosis and patients without this condition. Statistical significance was set at $P \leq 0.05$. Data entry and calculations were made with the software package SPSS 22.0 (IBM Corp.) and R 3.0.3.

Results

The results of major complications are presented in Table 2. In six of 85 IRE sessions

Main points

- Irreversible electroporation of malignant hepatic tumors appears to be a procedure with an acceptable safety profile.
- Caution has to be exercised in patients with bilioenteric anastomosis, as this condition is associated with increased risk of postablative abscesses.
- Portal vein branch thrombosis may occur; thus care has to be taken in patients with pre-interventionally impaired liver function.

Table 1. Tumor types in 56 patients treated with irreversible electroporation of malignant liver tumors

Diagnosis	No. of patients	No. of treated lesions
Primary liver tumors		
Hepatocellular carcinoma	24	45
Cholangiocellular carcinoma	4	7
Metastases		
Colorectal tumor	18	44
Breast carcinoma	2	6
Neuroendocrine tumor	2	3
Pancreatic tumor	2	3
Other	4	6

(7.1%) seven major complications occurred, with two major complications developing within a single IRE session. No patient died due to IRE ablation. The most frequent major complication was hepatic abscess (4.7%), which occurred in four patients. The abscesses detected during the periprocedural postablative period were located within the ablation zone and required intravenous antimicrobial and drainage therapy. A group-to-group comparison showed that postablative abscess developed significantly more often in patients with bilioenteric anastomosis (three of seven ablation procedures in three of four patients) than in patients without this condition (one of 78 ablation procedures in one of 52 patients) ($P = 0.010$). Logistic regression models showed that only bilioenteric anastomosis presented a significant risk factor for the occurrence of a major complication ($P = 0.002$; odds ratio, 18.75; 95% CI, 2.76–137.28). One of the patients with postablative hepatic abscess formation additionally developed renal failure after IRE and thus required transient hemodialysis during the periprocedural postablative period (preinterventional glomerular filtration rate, 77 mL/min/1.73 m²).

Two patients developed bleeding (2.4%). One patient sustained injury to the right mammary artery during the intervention, and the resulting acute hemorrhage was treated by arterial embolization during angiography (Fig.); no blood transfusion was required. Another patient required blood transfusion because of diffuse intraperitoneal bleeding with decreasing hemoglobin levels; bleeding stopped spontaneously, so that no surgical or interventional therapy was necessary.

Minor complications according to the SIR grading system occurred in 18.8% of procedures (16/85). In three cases, two minor complications were found within a single IRE session. The most frequent minor complications were hemorrhage without requirement of any further therapy (5.9%, 5/85) and portal vein branch thrombosis (5.9%, 5/85). Further complications were pneumothorax without requirement of a chest drain (3.5%, 3/85), hepatic arteriovenous shunt (3.5%, 3/85), and neurologic deficits of the right upper limb due to peri-interventional positioning (2.3%, 2/85), which completely resolved at discharge from hospital. One patient developed partial liver infarction associated with the above-mentioned portal venous thrombotic changes (1.2%, 1/85).

Table 2. Major complications after 85 irreversible electroporation procedures

Complication	Period after IRE			Overall
	Immediate	Periprocedural	Delayed	
Hepatic abscess	0	4	0	4
Hemorrhage				
requiring blood transfusion	0	1	0	1
requiring arterial embolization	1	0	0	1
Renal failure	0	1	0	1
Total	1	6	0	7

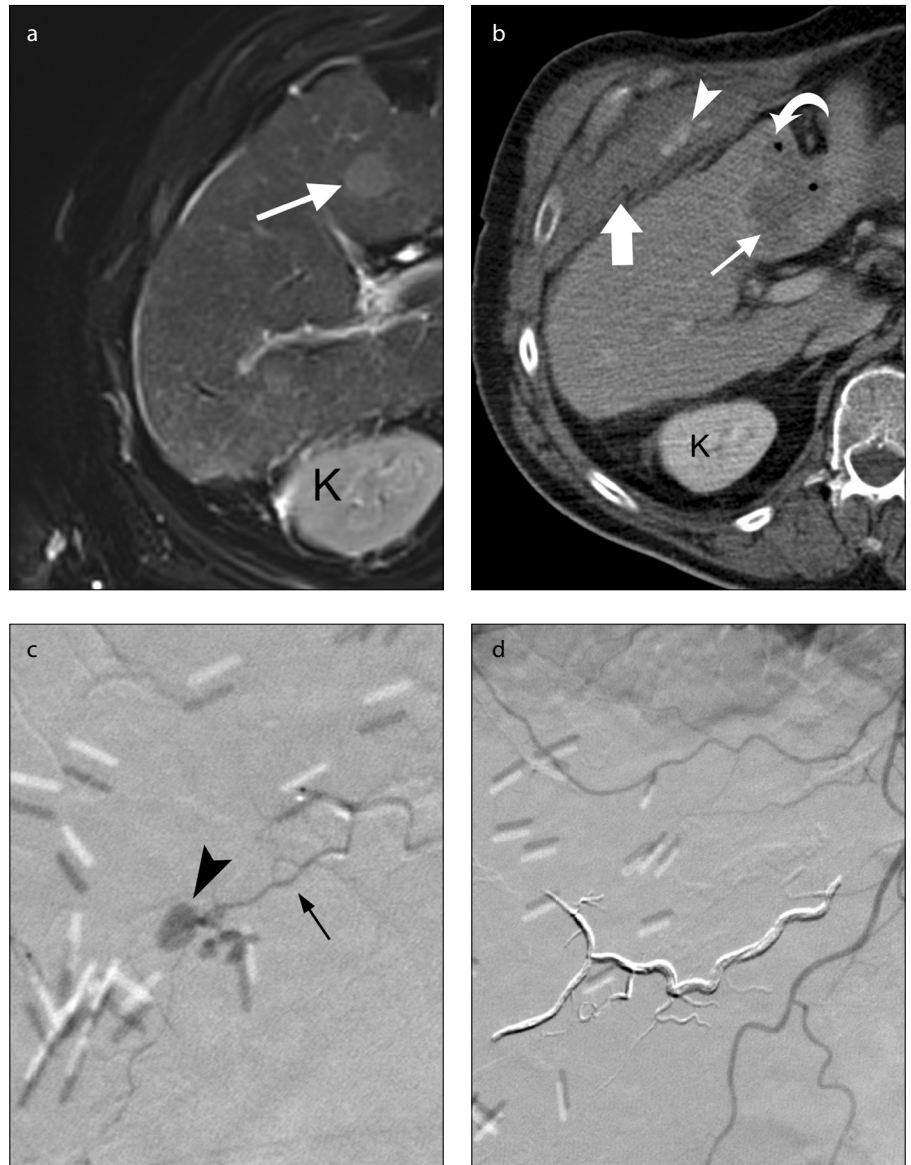


Figure. a–d. A 66-year-old male patient with hepatocellular carcinoma. T2-weighted MRI image six days before intervention shows a hyperintense HCC lesion (a, arrow) in segment V of the liver located within a perimeter of 1 cm of a segmental portal vein branch (not shown on the figure). A peri-interventional contrast-enhanced CT scan shows extrahepatic hematoma (b, thick arrow) with active extravasation of contrast medium (b, arrowhead) due to active bleeding. The ablation zone (b, thin arrow) contains intralésional gas bubbles (b, curved arrow). Immediate digital subtraction angiography with selective angiography of the right internal thoracic artery (c) shows extravasation of contrast medium (arrowhead) from one of its branches (thin arrow). Consecutively, the vessel was successfully embolized with an ethylene vinyl alcohol copolymer (Onyx, ev3 Inc.) (d). K, kidney.

In three patients, complete thrombosis of a portal vein branch or segmental portal vein branch was detected during the periprocedural follow-up by means of CT imaging. In the first patient, preinterventional imaging showed the left portal vein branch to be 0.5 cm distant to the target lesion, and the follow-up image after 13 months showed persistent branch thrombosis and a reduced volume of the left liver lobe. In another patient, preinterventional imaging showed radiographic margins of the ablated tumor located within 0.5 cm to a segmental branch of the left portal vein. This patient developed segmental portal vein branch thrombosis leading to infarction of parts of the left liver lobe and received low-intensity anticoagulation therapy. The preinterventional images of a third patient showed a segmental branch of the left portal vein located 0.9 cm from the target lesion that was completely occluded on the first follow-up images. The patient received anticoagulation therapy, and thrombosis resolved after seven days without any evidence of liver infarction.

In two patients, partial thrombosis of portal vein branch was detected in periprocedural follow-up imaging. In both patients, the left portal venous system was affected. The preinterventional images of the first patient showed the left portal vein branch abutting the target lesion. At three-month follow-up, thrombosis persisted with consecutive volume reduction of the left liver lobe. In the other patient, the affected part of the left portal vein was 0.8 cm distant to the ablation zone on the first postablative day; at six-month follow-up thrombosis resolved, and no liver infarction occurred. Since thrombosis within the portal venous system and liver infarction were detected by means of imaging and were clinically unapparent, they were considered to be minor complications. Logistic regression models did not show any risk factors for the occurrence of minor complication.

Discussion

Although percutaneous tumor ablation procedures are generally considered to be minimally invasive, published data suggest that such techniques carry some degree of risk. Since IRE ablation represents a rather new ablation technique, possible risks factors in IRE have yet to be evaluated. The current results show that IRE of hepatic tumors using CT fluoroscopy has a major compli-

cation rate of 7.1% (6/85) without any mortality, which is an acceptable safety profile comparable to other ablative treatments.

Livraghi et al. (5) reported six deaths (0.3%) and 50 additional major complications (2.2%) in a multicenter study in which more than 3,500 hepatic tumors in 2,320 patients were ablated by internally cooled RF ablation. Additional major complications predominantly consisted of peritoneal hemorrhage, neoplastic seeding, intrahepatic abscesses, and intestinal perforation (5). In the current study, the major complication rate after IRE ablation was higher than that after RF ablation. However, the selection bias of patients should be taken into consideration because patients were only treated with IRE ablation if they were unable to undergo thermal ablation or surgery.

The most frequent major complication in the current study was hepatic abscess which occurred during the periprocedural postablative period. This is in line with previous studies reporting a time range from eight days to five months between hepatic RF ablation and abscess formation (25–27). Those percutaneous RF ablation studies reported rates of abscess formation of 0.4% to 3.1% (6/1500 to 7/226) (25, 28). Thus, the rate of 4.7% found in the current study is higher compared to the above-mentioned results after RF ablation. However, the development of postablative abscesses was significantly associated with the presence of bilioenteric anastomosis compared to patients without this condition. In the current study, three of four patients with postablative abscess had bilioenteric anastomosis, and this condition has been reported to be a risk factor for infectious complications after loco-regional hepatic tumor treatment such as RF ablation (5, 25), microwave ablation (29), and embolization (30–33). In case of chemoembolization in patients with bilioenteric anastomosis, prophylactic therapies have already been proven to be successful (34).

Hemorrhage requiring therapy has been described as one of the common major complications after hepatic RF ablation with a frequency of 0.5% to 1.1% (5, 28). In the current study, the rate of this complication was slightly higher (3%). Since two to six electrodes are used in IRE ablation compared to one electrode in thermal ablation techniques, hemorrhage may occur markedly more often after IRE ablation than after RF or microwave ablation. The nonthermal effect of IRE does not allow cauterization of

the needle tracts, which represents another theoretical risk factor. On the other hand, the relative small size of IRE electrodes of just 18G compared to that of RF probes of up to 15G would imply a decreased risk of hemorrhage.

Thrombotic changes within the portal venous system, especially of small vessels, are known complications after thermal ablation (10). However, according to de Baère et al. (25) thrombosis of larger hepatic vessels is mainly associated with vascular occlusion (Pringle maneuver) in cirrhotic livers, which is used as supplement to RF ablation to avoid heat sink phenomena. The narrowing of hepatic vessels immediately after IRE ablation due to edematous and inflammatory changes has already been described previously (39.1%, 9/23 hepatic veins) (18), and even postablative portal vein thrombosis is a well-known complication after IRE ablation (3.2%, 1/31 ablation procedures) (22). The thrombotic alterations within the portal venous system in the current study may have been due to portal vein narrowing with reduced blood flow.

The current study has several limitations such as the low number of patients and IRE interventions and its retrospective nature. Consequently, other types of complications may be described in future studies. The current patient series was also too small to find risk factors for each respective complication. Another limitation is the heterogeneity of the study population consisting of patients with and without liver cirrhosis.

In conclusion, the current study suggests that IRE ablation of liver tumors may be a well-tolerated and rather safe ablative technique with a 7.1% rate of major complications and no deaths. Intratumoral abscess was the most frequent postablative complication, and it was significantly associated with the presence of bilioenteric anastomosis.

Acknowledgement

The authors thank Dietlinde Ulsperger for editing the figures.

Conflict of interest disclosure

All authors have read the journal's policies, and the following conflicts have emerged: Philipp Wiggemann received travelling assistance from Angiodynamics®. In response to this conflict, the authors state that this assistance does not alter adherence to any of the policies of the Diagnostic and Interventional Radiology on sharing data and materials. Angiodynamics® was neither involved in the study design, data collection and analysis, nor in the decision to publish or the preparation of the manuscript.

References

1. Fortner JG, Silva JS, Golbey RB, Cox EB, Maclean BJ. Multivariate analysis of a personal series of 247 consecutive patients with liver metastases from colorectal cancer. I. Treatment by hepatic resection. *Ann Surg* 1984; 3:306–316. [\[CrossRef\]](#)
2. Dromain C, Baere T de, Elias D, et al. Hepatic tumors treated with percutaneous radio-frequency ablation: CT and MR imaging follow-up. *Radiology* 2002; 1:255–262. [\[CrossRef\]](#)
3. Murakami R, Yoshimatsu S, Yamashita Y, Matsukawa T, Takahashi M, Sagara K. Treatment of hepatocellular carcinoma: value of percutaneous microwave coagulation. *AJR Am J Roentgenol* 1995; 5:1159–1164. [\[CrossRef\]](#)
4. Lencioni R, Crocetti L. Local-regional treatment of hepatocellular carcinoma. *Radiology* 2012; 1:43–58. [\[CrossRef\]](#)
5. Livraghi T, Solbiati L, Meloni MF, Gazelle GS, Halpern EF, Goldberg SN. Treatment of focal liver tumors with percutaneous radio-frequency ablation: complications encountered in a multicenter study. *Radiology* 2003; 2:441–451. [\[CrossRef\]](#)
6. Patterson EJ, Scudamore CH, Owen DA, Nagy AG, Buczkowski AK. Radiofrequency ablation of porcine liver in vivo: effects of blood flow and treatment time on lesion size. *Ann Surg* 1998; 4:559–565. [\[CrossRef\]](#)
7. Rossi S, Garbagnati F, Francesco I de, et al. Relationship between the shape and size of radiofrequency induced thermal lesions and hepatic vascularization. *Tumori* 1999; 2:128–132.
8. Goldberg SN, Hahn PF, Tanabe KK, et al. Percutaneous radiofrequency tissue ablation: does perfusion-mediated tissue cooling limit coagulation necrosis? *J Vasc Interv Radiol* 1998; 1 Pt 1:101–111. [\[CrossRef\]](#)
9. Goldberg SN, Hahn PF, Halpern EF, Fogle RM, Gazelle GS. Radio-frequency tissue ablation: effect of pharmacologic modulation of blood flow on coagulation diameter. *Radiology* 1998; 3:761–767. [\[CrossRef\]](#)
10. Lu DSK, Raman SS, Vodopich DJ, Wang M, Sayre J, Lassman C. Effect of vessel size on creation of hepatic radiofrequency lesions in pigs: assessment of the “heat sink” effect. *AJR Am J Roentgenol* 2002; 1:47–51. [\[CrossRef\]](#)
11. Lee RC. Cell injury by electric forces. *Ann N Y Acad Sci* 2005; 1066:85–91. [\[CrossRef\]](#)
12. Rubinsky B, Onik G, Mikus P. Irreversible electroporation: a new ablation modality—clinical implications. *Technol Cancer Res Treat* 2007; 1:37–48. [\[CrossRef\]](#)
13. Lee EW, Chen C, Prieto VE, Dry SM, Loh CT, Kee ST. Advanced hepatic ablation technique for creating complete cell death: irreversible electroporation. *Radiology* 2010; 2:426–433. [\[CrossRef\]](#)
14. Miller L, Leor J, Rubinsky B. Cancer cells ablation with irreversible electroporation. *Technol Cancer Res Treat* 2005; 6:699–705. [\[CrossRef\]](#)
15. Deodhar A, Monette S, Single GW, JR, et al. Renal tissue ablation with irreversible electroporation: preliminary results in a porcine model. *Urology* 2011; 3:754–760. [\[CrossRef\]](#)
16. Schoellnast H, Monette S, Zell PC, et al. Acute and subacute effects of irreversible electroporation on nerves: experimental study in a pig model. *Radiology* 2011; 2:421–427. [\[CrossRef\]](#)
17. Li W, Fan Q, Ji Z, Qiu X, Li Z. The effects of irreversible electroporation (IRE) on nerves. *PLoS One* 2011; 4:e18831. [\[CrossRef\]](#)
18. Lee YJ, Lu DSK, Osuagwu F, Lassman C. Irreversible electroporation in porcine liver: short- and long-term effect on the hepatic veins and adjacent tissue by CT with pathological correlation. *Invest Radiol* 2012; 11:671–675. [\[CrossRef\]](#)
19. Lee YJ, Lu DSK, Osuagwu F, Lassman C. Irreversible electroporation in porcine liver: acute computed tomography appearance of ablation zone with histopathologic correlation. *J Comput Assist Tomogr* 2013; 2:154–158. [\[CrossRef\]](#)
20. Thomson KR, Cheung W, Ellis SJ, et al. Investigation of the safety of irreversible electroporation in humans. *J Vasc Interv Radiol* 2011; 5:611–621. [\[CrossRef\]](#)
21. Philips P, Hays D, Martin RCG. Irreversible electroporation ablation (IRE) of unresectable soft tissue tumors: learning curve evaluation in the first 150 patients treated. *PLoS One* 2013; 11:e76260. [\[CrossRef\]](#)
22. Kingham TP, Karkar AM, D’Angelica MI, et al. Ablation of perivascular hepatic malignant tumors with irreversible electroporation. *J Am Coll Surg* 2012; 3:379–387. [\[CrossRef\]](#)
23. Goldberg SN, Grassi CJ, Cardella JF, et al. Image-guided tumor ablation: standardization of terminology and reporting criteria. *J Vasc Interv Radiol* 2009; 7 Suppl:S377–390. [\[CrossRef\]](#)
24. Burke DR, Lewis CA, Cardella JF, et al. Quality improvement guidelines for percutaneous transhepatic cholangiography and biliary drainage. Society of Cardiovascular and Interventional Radiology. *J Vasc Interv Radiol* 1997; 4:677–681. [\[CrossRef\]](#)
25. Baere T de, Risse O, Kuoch V, et al. Adverse events during radiofrequency treatment of 582 hepatic tumors. *AJR Am J Roentgenol* 2003; 3:695–700. [\[CrossRef\]](#)
26. Wood TF, Rose DM, Chung M, Allegra DP, Foshag LJ, Bilchik AJ. Radiofrequency ablation of 231 unresectable hepatic tumors: indications, limitations, and complications. *Ann Surg Oncol* 2000; 8:593–600. [\[CrossRef\]](#)
27. Zagoria RJ, Chen MYM, Shen P, Levine EA. Complications from radiofrequency ablation of liver metastases. *Ann Surg* 2002; 2:204–209.
28. Takaki H, Yamakado K, Nakatsuka A, et al. Frequency of and risk factors for complications after liver radiofrequency ablation under CT fluoroscopic guidance in 1500 sessions: single-center experience. *AJR Am J Roentgenol* 2013; 3:658–664. [\[CrossRef\]](#)
29. Shibata T, Yamamoto N, Ikai I, et al. Cholechojejunostomy: possible risk factor for septic complications after percutaneous hepatic tumor ablation. *AJR Am J Roentgenol* 2000; 4:985–986. [\[CrossRef\]](#)
30. Baere T de, Roche A, Amenabar JM, et al. Liver abscess formation after local treatment of liver tumors. *Hepatology* 1996; 6:1436–1440. [\[CrossRef\]](#)
31. Okajima K, Kohno S, Tamaki M, et al. Bilio-enteric anastomosis as a risk factor for perieMBOLIC hepatic abscesses. *Cardiovasc Intervent Radiol* 1989; 3:128–130. [\[CrossRef\]](#)
32. Song SY, Chung JW, Han JK, et al. Liver abscess after transcatheter oily chemoembolization for hepatic tumors: incidence, predisposing factors, and clinical outcome. *J Vasc Interv Radiol* 2001; 3:313–320. [\[CrossRef\]](#)
33. Kim W, Clark TW, Baum RA, Soulen MC. Risk factors for liver abscess formation after hepatic chemoembolization. *J Vasc Interv Radiol* 2001; 8:965–968. [\[CrossRef\]](#)
34. Geschwind JH, Kaushik S, Ramsey DE, Choti MA, Fishman EK, Kobeiter H. Influence of a new prophylactic antibiotic therapy on the incidence of liver abscesses after chemoembolization treatment of liver tumors. *J Vasc Interv Radiol* 2002; 11:1163–1166. [\[CrossRef\]](#)