

Non-cardiogenic pulmonary oedema due to the intravenous administration of clove oil

Carl M Kirsch, Gordon G Yenokida, William A Jensen, Robert Wendland, Hyun Suh, Michelle Bourgault

Abstract
Intravenous injection of clove oil induced non-cardiogenic pulmonary oedema, which was managed successfully with a conservative diagnostic and therapeutic approach.

Since the original description of the adult respiratory distress syndrome,¹ numerous causes of non-cardiogenic pulmonary oedema have been identified.² Obtaining the diagnosis by a thorough history may reduce unnecessary and hazardous investigations.

Case report

A 32 year old woman was admitted with hypoxaemia and acute dyspnoea, which had developed over one hour. There was no history of exposure to known toxic agents, loss of consciousness, recent seizure activity, abdominal pain, fever, leg swelling, or pain. She had not smoked cigarettes for 14 years, but had used intravenous drugs in the distant past.

At examination she appeared as an alert,

cooperative woman in acute respiratory distress. Her blood pressure was 110/60 mm Hg, pulse 128/min, and respiratory rate 26/min. The cardiovascular system was normal. There were prominent inspiratory crackles over the lower three quarters of both posterior lung fields. There was no clubbing or peripheral oedema.

A chest radiograph showed pronounced bilateral interstitial and alveolar infiltrates without cardiomegaly, lymphadenopathy, or pleural effusions (figure). An electrocardiogram was normal except for sinus tachycardia. Arterial blood gas measurements showed that pH was 7.30, carbon dioxide tension (Paco₂) 3.9 kPa, and oxygen tension (Pao₂) 4.4 kPa while the patient was breathing room air. While she breathed 100% oxygen from a face mask pH was 7.42, Paco₂ 3.7 kPa and Pao₂ 8.1 kPa. An echocardiogram (M mode and 2 D) showed normal anatomy and function of both right and left ventricles. Although a cardiogenic aetiology for pulmonary oedema seemed unlikely, insertion of a pulmonary arterial catheter to measure pulmonary capillary wedge pressure was seriously considered. After repeated and focused questioning the patient admitted that one hour before the onset of her acute dyspnoea she had injected an unknown amount of clove oil intravenously. The patient was then managed conservatively with supplemental oxygen and recovered over the next seven days. Arterial blood gas measurements were repeated seven days after admission, when pH was 7.44, Paco₂ 4.5 kPa, and Pao₂ 12.4 kPa while the patient was breathing air.

Discussion

Diagnostic criteria for non-cardiogenic pulmonary oedema have been established.² The combination of severe arterial hypoxaemia, bilateral diffuse alveolar and interstitial densities on the chest film, normal cardiac function, and a clear predisposing preceding event satisfies the definition of non-cardiogenic pulmonary oedema in this patient. Almost all patients who develop non-cardiogenic pulmonary oedema have an underlying predisposing disease process, which is usually recognised early in the clinical course. The lack of such an obvious predisposition in our patient, coupled with her history of intravenous drug abuse, led us to question her closely about illicit activities.

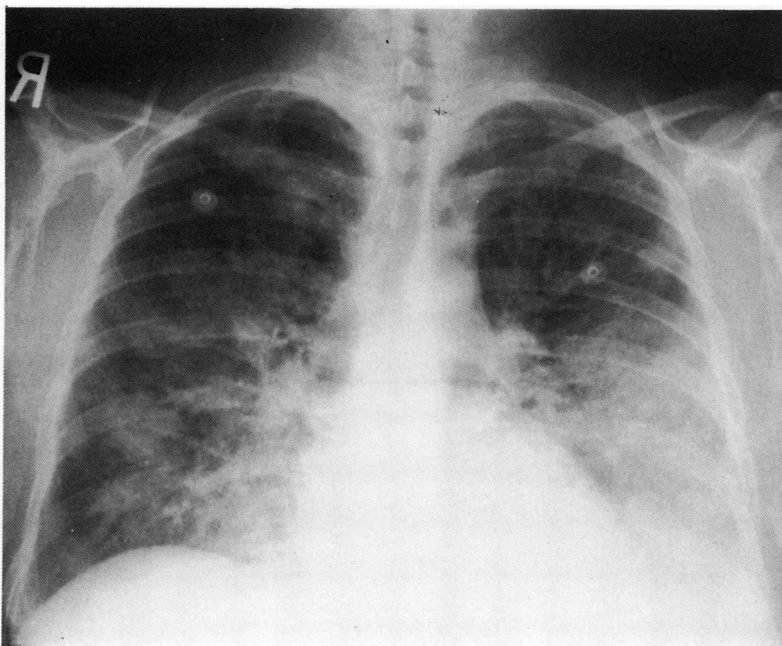
Oil of cloves and its major component, eugenol (4-allyl-2-methoxyphenol),³ have been used for decades in dentistry because of its local anaesthetic and antiseptic properties.⁴⁻⁹ Eugenol is often combined with zinc oxide in a paste used as temporary packing for dental wounds.⁴ Our patient had been given oil of cloves by her dentist for topical application to painful gums. Eugenol uncouples oxidative phosphorylation in rat liver mitochondria⁴ and is a potent inhibitor of platelet aggregation and thromboxane synthesis.⁵ In low concentrations eugenol inhibits cyclo-oxygenase and enhances lipoxygenase metabolism, possibly by redirecting arachidonic acid precursors.⁵ Its applica-

Division of
 Respiratory Medicine,
 Santa Clara Valley
 Medical Center, San
 Jose, California, USA

Carl M Kirsch
 Gordon G Yenokida
 William A Jensen
 Robert Wendland
 Hyun Suh
 Michelle Bourgault

Address for reprint requests:
 Dr Carl M Kirsch, Division
 of Respiratory Medicine,
 Santa Clara Valley Medical
 Center, 751 South Bascom
 Avenue, San Jose, California
 95128, USA.

Accepted 26 October 1989



Chest radiograph showing bilateral interstitial and alveolar infiltrates.

tion to oral mucosa causes inflammation and cellular necrosis⁶ and its application to isolated nerves produces a dose dependent neurotoxic effect.⁷ Intratracheal instillation of eugenol into rats and hamsters causes interstitial pulmonary haemorrhage and oedema.⁸ When injected into the aorta or a peripheral artery in dogs eugenol produces vasodilation, hypotension, increased local blood flow, neurotoxicity, and haemorrhagic pulmonary oedema.⁹ The lethal dose of eugenol in 75% of dogs is 0.2 ml/kg of a 1:20 solution and its detrimental effects are magnified with rapid administration.⁹ In man clove cigarettes expose the smoker to the effects of eugenol. Clove cigarettes (60–70% tobacco and 30–40% cloves) have been imported into the United States from Indonesia since 1968.¹⁰ Twelve cases of toxicity related to the smoking of clove cigarettes have been reported to the Communicable Diseases Center. Adverse effects include bronchospasm, haemoptysis, and pulmonary oedema.¹⁰

Illicit intravenous drug use is a common phenomenon and is associated with the parenteral administration of unusual substances.

The recognition of clove oil injection as the cause of non-cardiogenic pulmonary oedema in our patient obviated the need for invasive investigations and led to successful conservative treatment.

- 1 Ashbaugh DG, Bigelow DB, Petty TL, Levine BE. Acute respiratory distress in adults. *Lancet* 1967;ii:319–23.
- 2 Petty TL. Adult respiratory distress syndrome: definition and historical perspective. *Clin Chest Med* 1982;3:3–7.
- 3 Wagner H, Bladt S, Zgainski EM. *Plant drug analysis*. Berlin: Springer, 1984:320.
- 4 Cotmore JM, Burke A, Lee NH, Shapiro IM. Respiratory inhibition of isolated rat liver mitochondria by eugenol. *Arch Oral Biol* 1979;24:565–8.
- 5 Srivastava KC, Justesen U. Inhibition of platelet aggregation and reduced formation of thromboxane and lipooxygenase products in platelets by oil of cloves. *Prostaglandins Leukotrienes Med* 1987;29:11–8.
- 6 Kozam G, Mantell GM. The effect of eugenol on oral mucous membranes. *J Dent Res* 1978;57:954–7.
- 7 Kozam G. The effect of eugenol on nerve transmission. *Oral Surg* 1977;44:799–805.
- 8 LaVoie EJ, Adams JD, Reinhardt J, Rivenson A, Hoffmann D. Toxicity studies on clove cigarette smoke and constituents of clove: determination of the LD₅₀ of eugenol by intratracheal instillation in rats and hamsters. *Arch Toxicol* 1986;59:78–81.
- 9 Sticht FD, Smith RM. Eugenol: some pharmacologic observations. *J Dent Res* 1971;50:1531–5.
- 10 Centers for Disease Control. Illnesses possibly associated with smoking clove cigarettes. *Morbidity and Mortality Weekly Report* 1985;34:297–9.