

Antioxidant and antiapoptotic effects of darbepoetin- α against traumatic brain injury in rats

Hayri Kertmen¹, Bora Güner¹, Erdal Resit Yilmaz¹, Mehmet Ali Kanat², Ata Türker Arikok³, Berrin Imge Ergüder⁴, Askin Esen Hasturk⁵, Julide Ergil⁶, Zeki Sekerci¹

¹Ministry of Health, Diskapi Yildirim Beyazit Education and Research Hospital, Neurosurgery Clinic, Ankara, Turkey

²Ministry of Health, Refik Saydam National Public Health Agency, Ankara, Turkey

³Department of Pathology, Ministry of Health, Diskapi Yildirim Beyazit Education and Research Hospital, Ankara, Turkey

⁴Department of Biochemistry, Ankara University, Ankara, Turkey

⁵Department of Neurosurgery, Ministry of Health, Oncology Training and Research Hospital, Ankara, Turkey

⁶Department of Anesthesiology, Ministry of Health, Diskapi Yildirim Beyazit Education and Research Hospital, Ankara, Turkey

Submitted: 22 July 2013

Accepted: 4 October 2013

Arch Med Sci 2015; 11, 5: 1119–1128

DOI: 10.5114/aoms.2015.54869

Copyright © 2015 Termedia & Banach

Corresponding author:

Bora Güner MD
Ministry of Health Diskapi
Yildirim Beyazit Education
and Research Hospital
İrfan Bastug cad. S.B.
Diskapi Yildirim Beyazit
Eğitim ve Arastirma
Hastanesi 1
Beyin Cerrahi Servi
06110 Ankara, Turkey
Phone: +90 5063164201
Fax: +90 3123186690
E-mail: boragurer@gmail.com

Abstract

Introduction: In this study, we tried to determine whether darbepoetin- α would protect the brain from oxidative stress and apoptosis in a rat traumatic brain injury model.

Material and methods: The animals were randomized into four groups; group 1 (sham), group 2 (trauma), group 3 (darbepoetin α), group 4 (methylprednisolone). In the sham group only the skin incision was performed. In all the other groups, a moderate traumatic brain injury model was applied.

Results: Following trauma both glutathione peroxidase, superoxide dismutase levels decreased ($p < 0.001$ for both); darbepoetin- α increased the activity of both antioxidant enzymes ($p = 0.001$ and $p < 0.001$ respectively). Trauma caused significant elevation in the nitric oxide synthetase and xanthine oxidase levels ($p < 0.001$ for both). Administration of darbepoetin- α significantly decreased the levels of nitric oxide synthetase and xanthine oxidase ($p < 0.001$ for both). Also, trauma caused significant elevation in the nitric oxide levels ($p < 0.001$); darbepoetin- α administration caused statistically significant reduction in the nitric oxide levels ($p < 0.001$). On the other hand, malondialdehyde levels were increased following trauma ($p < 0.001$), and darbepoetin α significantly reduced the malondialdehyde levels ($p < 0.001$). Due to the elevated apoptotic activity following the injury, caspase-3 activity increased significantly. Darbepoetin- α treatment significantly inhibited apoptosis by lowering the caspase-3 activity ($p < 0.001$). In the darbepoetin group, histopathological score was lower than the trauma group ($p = 0.016$).

Conclusions: In this study, darbepoetin- α was shown to be at least as effective as methylprednisolone in protecting brain from oxidative stress, lipid peroxidation and apoptosis.

Key words: antiapoptosis, antioxidation, darbepoetin- α , methylprednisolone, neuroprotection, rat, traumatic brain injury.

Introduction

Traumatic brain injury (TBI) is one of the most disabling injuries in all age groups. Brain trauma causes tissue damage by primary and sec-

ondary injury to neural tissues. The primary injury is caused by an initial mechanical trauma resulting in physical disruption of vessels, neurons and their axons [1, 2]. Immediately following the primary injury several different pathways activate the secondary injury, causing the death of additional tissues at the peripheral zone of the initial damage [3]. Currently little can be done to prevent the primary brain damage caused by the initial impact. Thus far one of the major factors determining outcome in TBI is the extent of the secondary injury processes.

Reactive oxygen species (ROS) play an important role in the pathogenesis of secondary injury after TBI [4, 5]. Trauma-induced production of ROS causes injury via lipid peroxidation, as well as oxidative damage of proteins and DNA. Oxidative stress begins immediately after TBI, and initiates the events resulting in neuronal dysfunction and death [6]. To prevent this oxidative damage, organisms have an endogenous enzymatic antioxidant defense system with constituents such as superoxide dismutase (SOD), glutathione peroxidase (GPx) and catalase. On the other hand, secondary insults often involve apoptotic cell death, which causes complex cascading pathways resulting in the activation of proteases such as caspase-3 [7, 8].

Erythropoietin (EPO) is a glycoprotein hormone, which is the primary regulator of erythropoiesis [9]. Recombinant human EPO has been used to treat anemia associated with chronic renal failure, chemotherapy for cancer patients, and HIV infections [10]. Erythropoietin is a neuroprotective agent used in a variety of animal models of spinal cord injury [11–13], subarachnoid hemorrhage [14–16] and TBI [17, 18]. Also, EPO has been shown to be effective as a direct antioxidant by scavenging ROS by sialic acid-containing oligosaccharide chains [19].

Darbepoetin- α (DA) is a novel erythropoiesis-stimulating agent with additional sialic acid-containing oligosaccharide compared with EPO, and an extended circulatory half-life and increased *in vivo* biological activity [20]. Darbepoetin- α is a hypersialylated analog of EPO and activates EPO receptors. Here, we evaluated whether DA treatment could protect brain tissues from oxidative stress and apoptosis in rats after experimental TBI. We also compared DA with methylprednisolone (MP), which has been researched widely in traumatic brain and spinal cord injury [21–24].

Material and methods

Experimental groups

Animal care and all experiments were in concordance with the European Communities Council Directive of November 24, 1986 (86/609/EEC) on the protection of animals for experimental use. All

experimental procedures used in this investigation were reviewed and approved by the ethical committee of the Ministry of Health Refik Saydam Hifzissiha Institution. Thirty-two adult male Wistar albino rats weighing 250–350 g were used. The rats were randomly assigned to four groups with eight rats per group.

The groups were as follows: group 1 – Sham ($n = 8$); skin incision only. Rats underwent skin incision and non-traumatic brain samples were obtained 24 h after surgery. Group 2 – Trauma ($n = 8$); rats underwent TBI as described below. After craniectomy, brain samples were removed 24 h after injury. Group 3 – DA ($n = 8$); as for group 2, but rats received a single intraperitoneal dose of 30 $\mu\text{g}/\text{kg}$ DA (Aranesp, Amgen Europe, Netherlands) immediately following TBI. The dosage of the DA used in this study was obtained from past studies [21]. Group 4 – Methylprednisolone (MP) ($n = 8$); as for group 2, but rats received a single intraperitoneal dose of 30 mg/kg MP (Prednol, Mustafa Nevzat, Turkey) immediately following TBI.

Anesthesia and trauma procedure

All rats were kept under environmentally controlled conditions at 22–25°C, with appropriate humidity and a 12 h light cycle, and granted free access to food and water.

The animals were anesthetized by an intraperitoneal injection of 10 mg/kg xylazine (Rompun, Bayer, Turkey) and 50 mg/kg ketamine (Ketalar, Parke Davis, Turkey), and allowed to breathe spontaneously. A rectal probe was inserted and the animals were positioned on a heating pad maintaining the body temperature at 37°C. A moderate brain-injury model, described by Marmarou *et al.* [25], and modified by Ucar *et al.* [26], was applied for head trauma. The rats were placed in a prone position on the table. A midline incision was made on the head, and the coronal and lambdoid sutures were identified. A metallic disc of 10 mm diameter and 3 mm thickness was fixed to the cranium using bone wax between the two sutures in the midline. Trauma was applied at the point where the disc was placed in the midline. A lead object weighing 450 g was allowed to fall freely from a height of 70 cm through a copper tube on to the metal disc over the skulls of the rats. The animals were supported on a 10 cm foam bed that provided the deceleration after impact. After injury, the metallic disc was removed and the skin sutured before termination of anesthesia.

All the animals were anesthetized with the above-mentioned agents at the 24th hour after trauma and their brains were extracted immediately without causing any damage. Samples of neural tissues were obtained by excising the left

frontoparietal lobes from the boundary of the interhemispheric fissure and were subjected to biochemical analyses. The remaining parts of the brains were maintained in formaldehyde solution for histopathological analysis.

Biochemical procedures

Tissues were homogenized in physiological saline (1 g in 5 ml) and centrifuged at 4000 g for 20 min. The upper layer of clear supernatant was removed and used in the analyses. Before the analysis, the supernatant samples were adjusted so that they contained equal protein concentrations. The protein concentrations of the supernatant samples were measured using the Lowry method. The Lowry method depends on the reactivity of the nitrogen in peptides with copper ions under alkaline conditions and the subsequent reduction of Folin-Ciocalteu phosphomolybdic-phosphotungstic acid to heteropolymolybdenum blue by the copper catalyzed oxidation of aromatic amino acids. Absorbance measurements were made at 700 nm using a spectrophotometer. The protein concentration of the sample was determined by using a protein calibrator.

Tissue glutathione peroxidase (GPx) analysis

Glutathione peroxidase activity was measured by following changes in NADPH absorbance at 340 nm [27]. The oxidation of NADPH to NADP⁺ is accompanied by a decrease in absorbance at 340 nm providing a spectrophotometric means for monitoring. In the activity calculations (international unit – IU), extinction coefficients NADPH were used for GPx. The molar extinction coefficient for NADPH is 6220 M⁻¹cm⁻¹ at 340 nm. The results were expressed as IU/mg-protein.

Tissue superoxide dismutase (SOD) analysis

Total (Cu–Zn and Mn) SOD (EC 1.15.1.1) activity was determined according to the method of Sun *et al.* [28]. The principle of the method is based on the inhibition of nitroblue-tetrazolium (NBT) reduction by the xanthine–xanthine oxidase system as a superoxide generator. Activity was assessed in the ethanol phase of the supernatant after 1.0 ml ethanol/chloroform mixture (5/3, v/v) was added to the same volume of sample and centrifuged. One unit of SOD was defined as the enzyme amount causing 50% inhibition in the NBT reduction rate. Superoxide dismutase activity was expressed as U/mg protein.

Tissue nitric oxide (NO) and nitric oxide synthetase (NOS) analysis

The level of NO was estimated by the method based on the diazotization of sulfanilic acid

by NO at acidic pH and subsequent coupling to N-1-naphthyl-ethylene diamine (Griess reaction) as described before [29]. Since the nitrate anion does not give a diazotization reaction with sulfanilic acid, the samples were treated with cadmium (a reducing agent) to reduce nitrate anions to nitrite anions before the NO estimation. The total NOS activity method is based on the Griess reaction. The results were expressed as $\mu\text{mol}/\text{mg}$ protein and IU/mg protein, respectively.

Tissue xanthine oxidase (XO) analysis

Serum XO activity was measured by the method of Prajda and Weber [30], where activity is measured by determination of uric acid from xanthine. Serum samples were incubated for 30 min at 37°C in 3 ml of the phosphate buffer (pH 7.5, 50 nM) containing xanthine (4 mM). The reaction was stopped by addition of 0.1 ml 100% (w/v) trichloroacetic acid and the mixture was then centrifuged at 4000 g for 20 min. Urate was determined in the supernatant by measuring absorbance at 292 nm against blank and expressed as mIU/mg protein. The calibration curve was constructed by using 10–50 mU/ml concentrations of standard XO solutions (Sigma X-1875). One unit of activity was defined as 1 μmol of uric acid formed per minute at 37°C, pH 7.5.

Tissue malondialdehyde (MDA) analysis

Malondialdehyde is formed from the breakdown of polyunsaturated fatty acids, and serves as an important and reliable index for determining the extent of peroxidation reactions [31]. Tissue MDA levels were determined by a method based on the reaction with thiobarbituric acid (TBA). Malondialdehyde concentrations were expressed as nmoles per milligram tissue wet weight.

Tissue caspase-3 analysis

The caspase-3 activity of the tissue samples was measured using the Caspase-3 Colorimetric Detection Kit (907-013; Assay Designs, Ann Arbor, MI, USA). The kit involves the conversion of a specific chromogenic substrate for caspase-3 (acetyl-Asp-Glu-Val-Asp-p-nitroanilide), followed by colorimetric detection of the product (*p*-nitroaniline) at 405 nm. The absolute value for caspase-3 activity can be determined by comparison with a signal given by the *p*-nitroaniline calibrator. Activity measurements were quantified by comparing the optical densities obtained with standards with the *p*-nitroaniline calibrator. One unit of caspase-3 activity was defined as the amount of enzyme needed to convert 1 pmol of substrate per min at 30°C. The results were expressed as U/mg protein.

Histopathological procedures

The brain parenchymal tissues of all rats in all the groups were embedded in paraffin and fixed with 10% buffered formalin for 24 h. Using a microtome, 5 µm-thick serial sections were taken from the paraffin blocks, and stained with hematoxylin-eosin (H + E) for routine histopathological observations. Sections of all tissue samples were observed under a light microscope by a neuropathologist who was blinded to the study design.

A semiquantitative scoring system, ranging between zero and three, was used for grading both histopathological changes (vascular congestion, intraparenchymal hemorrhage, inflammation, neuronal loss and gliosis) and the neuronal degenerative signs (nuclear pyknosis, nuclear hyperchromasia, cytoplasmic eosinophilia and axonal edema) in all of the brain tissue samples. Nine different parameters assessed histopathologically were scored as follows: 0 – absent, 1 – mild, 2 – moderate, 3 – common. The pathological score for each brain was calculated by averaging the scores of these nine different parameters.

Statistical analysis

Data analysis was performed by using SPSS for Windows, version 11.5 (SPSS Inc., Chicago, IL, United States). Normality of distributions of continuous variables was evaluated by the Shapiro Wilk test. The Levene test was used for the evaluation of homogeneity of variances. Data are shown as mean ± standard deviation or median (IQR), where applicable. The mean differences among groups were analyzed by one-way ANOVA; otherwise, the Kruskal-Wallis test was applied for comparisons of the median values. When the *p* value from one-way ANOVA or Kruskal-Wallis test statistics was statistically significant, *post hoc* Tukey HSD or Conover's non-parametric multiple comparison tests were used to determine which groups differ from others. A *p* value less than 0.05 was considered statistically significant.

Results

Tissue glutathione peroxidase (GPx) analysis

When mean tissue GPx levels were compared between the sham and the trauma groups, a statistically significant difference was observed ($p < 0.001$); so we concluded that after TBI, due to highly elevated oxidative stress, tissue GPx levels decreased. When we compared the DA group with the trauma group, a statistically significant difference was observed ($p = 0.001$). As in the DA group, the comparison between the MP and the

trauma groups showed a statistically significant difference ($p < 0.001$) (Figure 1 A). These data showed that both DA and MP protected the brain from oxidative stress by activating antioxidant GPx activity.

Tissue superoxide dismutase (SOD) analysis

As for GPx levels, SOD levels were significantly decreased when comparing the sham group with the trauma group ($p < 0.001$). When the trauma group was compared with both the DA and MP groups, the differences were statistically significant ($p < 0.001$ and $p = 0.003$ respectively) (Figure 1 B). Both DA and MP caused elevated SOD activity and protected the brain from oxidative stress.

Tissue nitric oxide (NO) and total nitric oxide synthetase (NOS) analysis

Trauma caused significant elevation of the NO levels when compared with the control group ($p < 0.001$). Both DA and MP treatment showed a statistically significant reduction in the NO levels ($p < 0.001$ for both) (Figure 1 C).

After trauma, total NOS levels were increased significantly when compared to the control group ($p < 0.001$). Both DA and MP inhibited total NOS activity significantly when compared to the trauma group ($p < 0.001$ for both) (Figure 1 D).

Tissue xanthine oxidase (XO) analysis

Xanthine oxidase activity was found to be higher in the trauma group when compared to the control group ($p < 0.001$). Both DA and MP decreased the XO activity following TBI ($p < 0.001$ for both) (Figure 1 E).

Tissue malondialdehyde (MDA) analysis

When mean tissue MDA levels were compared between the sham and the trauma groups, a statistically significant difference was observed ($p < 0.001$); as a result we concluded that after TBI, due to elevated lipid peroxidation, tissue MDA levels increased. When we compared the DA and the MP groups with the trauma group, a statistically significant difference was observed ($p < 0.001$ for both). These data showed that both DA and MP protected the brain from an increase in MDA levels (Figure 1 F).

Tissue caspase-3 analysis

There was a statistically significant difference between the sham and the trauma groups regarding the mean caspase-3 activity ($p < 0.001$). However, the data showed that TBI clearly elevated caspase-3 activity in the damaged tissue. When both the DA and MP groups were com-

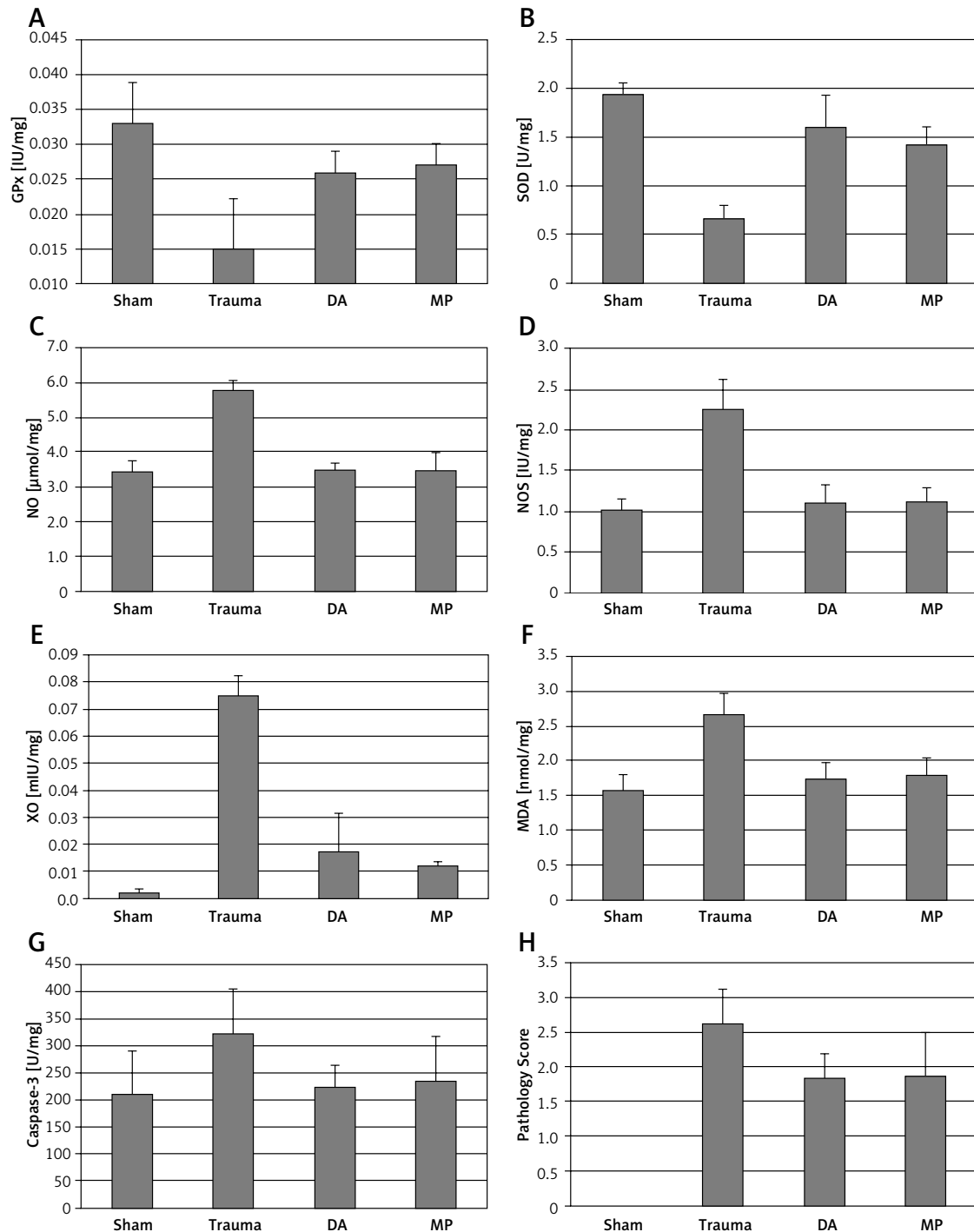


Figure 1. Bar graphs showing the biochemical results of tissue glutathione peroxidase (A), superoxide dismutase (B), nitric oxide (C), nitric oxide synthetase (D), xanthine oxidase (E), malondialdehyde (F), caspase-3 (G) levels. Bar graph showing the pathological scores (H) is also shown

Values are expressed as mean \pm SD. DA – darbepoetin- α , MP – methylprednisolone, GPx – glutathione peroxidase, SOD – superoxide dismutase, NO – nitric oxide, NOS – nitric oxide synthetase, XO – xanthine oxidase, MDA – malondialdehyde.

pared with the trauma group, a statistically significant difference was found ($p < 0.001$ for both) (Figure 1 G). These data show that both DA and MP prevented an increase in caspase-3 activity and effectively inhibited apoptotic cell death caused by TBI.

Histopathological assessment

The parenchymal features of the white and grey matter, the neuronal morphology and the vascular structures were assessed to be normal in the control group (Figure 2 A). Following the trauma, marked edema in the white and grey matter

in addition to vascular congestion was observed with neuronal injury findings including hyperchromasia in neuronal nuclei, nuclear pyknosis, cytoplasmic eosinophilic degeneration, and axonal edema. Also, focal neuronal loss and gliotic zones were seen in the trauma group (Figure 2 B).

When pathological scores were compared, the trauma group had statistically higher scores than the sham group ($p < 0.001$). In the DA group, the pathological score is lower (1.83 ± 0.36) than the trauma group (2.62 ± 0.51); this difference was statistically significant ($p = 0.016$). In the MP group, the pathology score was 1.87 ± 0.64 ; this score is statistically significantly lower than the trauma group ($p = 0.017$) (Figure 1 H). Histopathologically, both DA and MP protected the brain from TBI (Figures 2 C, D).

The biochemical results and pathology scores are summarized in Table I.

Discussion

Head trauma causes brain injury by leading to primary and secondary damage in the neural

tissues. The most important secondary factors, which lead to further neuronal death, are the development of ROS [5, 32], lipid peroxidation [6, 33–35], and apoptosis [7, 36].

The TBI model, used in our study, was described by Marmarou *et al.* [25], and modified by Ucar *et al.* [26]. In the model of Marmarou *et al.* [25], an object of 450 g falls freely from an altitude of two meters, causing 44% mortality. To lower the mortality rate, we used the moderate head trauma model described by Ucar *et al.* [26], in which an object of 450 g falls freely from an altitude of 70 cm. In our trauma and treatment groups, the total number of rats was scheduled as 24; among these, 3 rats died of trauma and another 3 additional rats were exposed to trauma and included in the study. Hence a total of 27 rats were subjected to trauma and 3 (11.1%) died.

Recombinant human EPO has been shown to be an exceedingly safe drug, which has been used for more than 15 years for treatment of anemia. About a decade ago, it was generally believed that EPO acts only on erythroid precursor cells, but since then EPO receptors have been found in

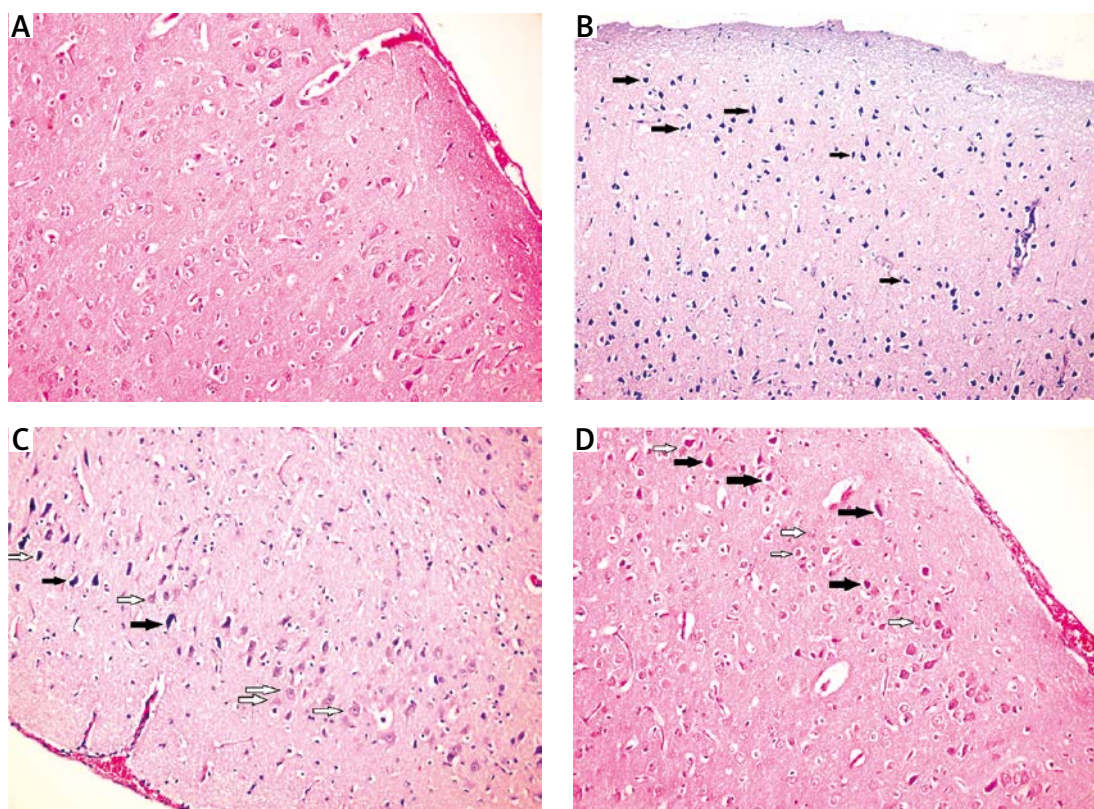


Figure 2. A – Photomicrograph of sham group, showing regular brain parenchyma (hematoxylin-eosin, 20× objective). B – Photomicrograph of trauma group, showing marked edema, vascular congestion and neuronal injury findings (hematoxylin-eosin, 20× objective). The filled arrows show the injured neurons. Note only the few normal appearing neurons (hollow arrows). C – Photomicrograph of darbepoetin alpha group, showing less edema and degenerated neuron (filled arrow). Note the normal appearing neurons (hollow arrow) (hematoxylin-eosin, 20× objective). The brain tissues were well protected from injury. D – Photomicrograph of MP group, showing less degenerated neurons (filled arrow), and more normal appearing neurons (hollow arrow) (hematoxylin-eosin, 20× objective)

Table I. Biochemical and histopathological differences among the groups

Variables	Sham	Trauma	DA	MP	Value of <i>p</i>
GPx [IU/mg]	0.033 \pm 0.006 ^a	0.015 \pm 0.007 ^{a,b,c}	0.026 \pm 0.003 ^b	0.027 \pm 0.003 ^c	< 0.001 [†]
SOD [U/mg]	1.94 \pm 0.12 ^{a,d,e}	0.66 \pm 0.14 ^{a,b,c}	1.61 \pm 0.33 ^{b,d,f}	1.42 \pm 0.19 ^{c,e,f}	< 0.001 [‡]
NO [μ mol/mg]	3.44 \pm 0.31 ^a	5.8 \pm 0.26 ^{a,b,c}	3.49 \pm 0.21 ^b	3.51 \pm 0.48 ^c	< 0.001 [‡]
NOS [IU/mg]	1.01 \pm 0.15 ^a	2.26 \pm 0.37 ^{a,b,c}	1.11 \pm 0.22 ^b	1.12 \pm 0.17 ^c	< 0.001 [‡]
XO [mIU/mg]	0.002 \pm 0.001 ^{a,d,e}	0.075 \pm 0.007 ^{a,b,c}	0.017 \pm 0.014 ^{b,d}	0.012 \pm 0.001 ^{c,e}	< 0.001 [‡]
MDA [nmol/mg]	1.57 \pm 0.23 ^{a,d,e}	2.66 \pm 0.32 ^{a,b,c}	1.74 \pm 0.25 ^{b,d}	1.79 \pm 0.25 ^{c,e}	< 0.001 [‡]
Caspase-3 [U/mg]	210.4 \pm 80.02 ^a	321.8 \pm 83.67 ^{a,b,c}	222.5 \pm 42.23 ^b	233.4 \pm 85.4 ^c	< 0.001 [†]
Pathology	0.0 \pm 0.00 ^{a,d,e}	2.62 \pm 0.51 ^{a,b,c}	1.83 \pm 0.36 ^{b,d}	1.87 \pm 0.64 ^{c,e}	< 0.001 [‡]

Values are expressed as mean \pm SD. DA – darbepoetin α , MP – methylprednisolone, GPx – glutathione peroxidase, SOD – superoxide dismutase, NO – nitric oxide, NOS – nitric oxide synthetase, XO – xanthine oxidase, MDA – malondialdehyde. [†]One-way ANOVA, [‡]Kruskal-Wallis test, ^a – sham vs. trauma (*p* < 0.001), ^b – DA vs. trauma (*p* < 0.05), ^c – MP vs. trauma (*p* < 0.05), ^d – DA vs. sham (*p* < 0.05), ^e – MP vs. sham (*p* < 0.05), ^f – DA vs. MP (*p* < 0.001).

many other tissues including brain, spinal cord, heart and testis; there is an emerging consensus that EPO may help nonerythroid cells to survive and proliferate [37, 38]. Erythropoietin has been shown to have antiapoptotic, antioxidant, anti-inflammatory and angiogenic effects, which provide tissue protector effects [39]. The neuroprotective effect of EPO has been demonstrated in numerous experimental studies [40–44]. The EPO analogue DA is an erythropoiesis-stimulating agent that exerts similar physiological responses by affecting EPO receptors [20]. Convincing evidence is available that DA as well as EPO acts as a neurotrophic factor and neuroprotector in the brain. Banks *et al.* [45] reported that DA crosses the blood-brain barrier by way of the extracellular pathways in amounts that could account for the neuroprotective effect. In animal studies both agents have been reported to be beneficial in treating global and focal ischemia, reducing nervous system inflammation and improving neurological outcome [11, 43, 44, 46]. As an EPO-derivate agent, we hypothesized that DA may have neuroprotective effects on TBI.

Erythropoietin has shown to manifest antioxidant effects [47]. The exact mechanisms are not completely understood, but several possibilities have been suggested. Erythropoietin has been shown to act as a direct antioxidant by scavenging ROS [19]. It is a single-chain, 165 amino acid glycosylated protein with three N-linked and O-linked sialic acid-containing oligosaccharide chains [48]. Sialic acids are known to scavenge ROS *in vivo* [49]. In addition, EPO has been shown to induce antioxidant enzymes [50, 51]. Darbepoetin α is a hypersialylated analog of EPO that was engineered to prolong serum half-life and increase *in vivo* activity [52]. A recent study showed that sialic acid residues in DA were essential for its

antioxidant effect [47]. Antioxidant effects of DA have also been shown in the ischemia/reperfusion injury of the kidney [53] and testicular torsion/detorsion injury [54]. Due to these past studies, we hypothesized that this antioxidant effect of DA may attenuate neuroprotection in TBI.

Reactive oxygen species play a key role in mediating secondary injury induced by trauma [55, 56]. The brain is particularly vulnerable to oxidative injury because of its high rate of oxygen consumption, intense production of reactive radicals and high levels of transition metals, such as iron, which can catalyze the production of reactive radicals [57, 58]. When tissues are exposed to oxidative stress, they increase the activity and expression of antioxidant enzymes as a compensatory mechanism against free radical-mediated damage. Nevertheless, the increased activity of the antioxidant enzymes may be inadequate to counteract the potential damage in many conditions of oxidative stress [59, 60]. Moreover, antioxidant enzyme activities have been found to be diminished under highly elevated oxidative stress conditions as a result of molecular damage. In adult animals, brain tissue GPx and SOD levels have been demonstrated to be decreased at 1 h after head trauma [61, 62]. Fan *et al.* [63] found that GPx activity increased within 24 h after TBI. Contrary to that, Ozdemir *et al.* [57] demonstrated no increase in either GPx or SOD levels 24 h after TBI. In our moderate head trauma model, we demonstrated that both GPx and SOD levels decreased significantly after TBI. Therefore, we hypothesized that this decrease is due to highly elevated oxidative stress. After the administration of both DA and MP, these antioxidant enzymes increased significantly, promising antioxidant activity of both drugs.

The role of NO in the pathophysiology of TBI has not been fully elucidated [64]. Endogenous

NO is generated from L-arginine by a family of three distinct isoforms of NOS, including endothelial NOS (eNOS), neuronal NOS (nNOS) and inducible NOS (iNOS) [65]. TBI-induced activation of eNOS and nNOS has been shown to be beneficial and detrimental, respectively, and the role of iNOS is controversial [66, 67]. Deletion of the iNOS gene has been shown to be either beneficial by reducing the post-TBI lesion volume and improving the neurological recovery [68], or on the contrary may have detrimental effects by increasing the neuronal cell loss and worsening the neurological deficit [69]. Our study demonstrated that, 24 h after TBI, NO and total NOS levels increased significantly. Treatment with both DA and MP resulted in significant reduction of NO and total NOS levels. This is also further evidence for the antioxidant activity of both drugs.

Reactive oxygen species can be generated by a variety of sources at the cellular level. Xanthine oxidase is an important source for ROS. Xanthine oxidase is shown to be elevated in pathological conditions [70]. After TBI, secondary processes may also promote the generation of ROS and lipid peroxidation via the XO pathway [33]. Inhibition of XO activity prevents generation of uric acid [71] and reduces cerebral edema formation in the rat after cerebral ischemia [72]. We demonstrated that, after TBI, XO levels increased significantly. As expected, due to antioxidant activity both the DA and the MP reduced XO levels significantly.

In summary, after TBI, administration of DA increased the antioxidant enzyme levels of GPx and SOD, and also decreased the oxidant levels of NO, NOS, and XO, indicating that DA had potent antioxidant activity.

It is known that lipid peroxidation products increase soon after injury [33]. However, lipid peroxidation is recognized as one of the main pathophysiological mechanisms involved in secondary damage [73]. Malondialdehyde, a well-known secondary product of lipid peroxidation in myelin, glial and neural membranes, which is formed from the breakdown of polyunsaturated fatty acids, serves as a convenient index for determining the extent of lipid peroxidation [74]. Our study showed that, after TBI, levels of MDA dramatically increased in the trauma group compared with the sham group; after the administration of DA and MP, this increase in the MDA levels decreased significantly. These results showed that both DA and MP prevented lipid peroxidation in the traumatic brain.

Following TBI, secondary insults often involve apoptotic cell death in regions caudal to the impact site [75]. Caspase-3 is an interleukin-converting enzyme, and has been suggested to be the principal effector in the mammalian apoptotic

and inflammatory pathways [76]. Caspase-3 is a reliable marker in reflecting the apoptotic activity [75]. Sakurai *et al.* [77] observed an increase in caspase-3 immunoreactivity after 15 min of ischemia. Also, it has been found that apoptosis occurred at 24 h after injury [21, 22, 77, 78]. Anti-apoptotic effects of DA have been observed in the previous studies [21]. In this study, after trauma caspase-3 activity increased significantly, as an indicator of increased apoptosis following TBI. Both DA and MP protected the brain from apoptosis by lowering caspase-3 activity.

Histopathological evaluation includes vascular congestion, intraparenchymal hemorrhage, inflammation, neuronal loss, gliosis, and neuronal degeneration. The sham group had normal brain morphology. In the trauma group marked edema, vascular congestion, and intraparenchymal hemorrhage were observed. Gliosis and neuronal degeneration were also significant in the trauma group. Both DA and MP groups showed better morphological results compared with the trauma group. These results suggest that, after moderate TBI, both DA and MP have beneficial effects on preserving normal brain morphology both by antioxidant effects, reducing lipid peroxidation and antiapoptotic effects.

However, this study has some limitations. The number of rats in each group may be increased and the dose-dependent results may be investigated. Delayed biochemical and histopathological assessment may promise better results for further studies. Also, another limitation of this study is the lack of functional outcome measures.

In conclusion, biochemical and histopathological analysis revealed that DA exhibits meaningful neuroprotective effects against TBI by antioxidant effects, reducing lipid peroxidation and antiapoptotic effects. The results of our study provided the first experimental evidence of antioxidant effects of DA after TBI. DA is shown to be at least as effective as MP, in protecting brain tissue against TBI. So, we propose that DA treatment could be useful in TBI.

Conflict of interest

The authors declare no conflict of interest.

References

1. Siesjö BK. Basic mechanisms of traumatic brain damage. *Ann Emerg Med* 1993; 22: 959-69.
2. Marshall LF. Head injury: recent past, present, and future. *Neurosurgery* 2000; 47: 546-61.
3. Yurdakoc A, Gunday I, Memiş D. Effects of halothane, isoflurane, and sevoflurane on lipid peroxidation following experimental closed head trauma in rats. *Acta Anaesthesiol Scand* 2008; 52: 658-63.
4. Hall ED, Braughler JM. Central nervous system trauma and stroke. II. Physiological and pharmacological evi-

- dence for involvement of oxygen radicals and lipid peroxidation. *Free Radic Biol Med* 1989; 6: 303-13.
5. Ikeda Y, Long DM. The molecular basis of brain injury and brain edema: the role of oxygen free radicals. *Neurosurgery* 1990; 27: 1-11.
 6. Awasthi D, Church DF, Torbati D, Carey ME, Pryor WA. Oxidative stress following traumatic brain injury in rats. *Surg Neurol* 1997; 47: 575-81.
 7. Lotocki G, Alonso OF, Frydel B, Dietrich WD, Keane RW. Monoubiquitination and cellular distribution of XIAP in neurons after traumatic brain injury. *J Cereb Blood Flow Metab* 2003; 23: 1129-36.
 8. Wennersten A, Holmin S, Mathiesen T. Characterization of Bax and Bcl-2 in apoptosis after experimental traumatic brain injury in the rat. *Acta Neuropathol* 2003; 105: 281-8.
 9. Krantz SB. Erythropoietin. *Blood* 1991; 77: 419-34.
 10. Markham A, Bryson HM. Epoetin alfa. A review of its pharmacodynamic and pharmacokinetic properties and therapeutic use in nonrenal applications. *Drugs* 1995; 49: 232-54.
 11. Celik M, Gökmen N, Erbayraktar S, et al. Erythropoietin prevents motor neuron apoptosis and neurologic disability in experimental spinal cord ischemic injury. *Proc Natl Acad Sci U S A* 2002; 99: 2258-63.
 12. Gorio A, Gokmen N, Erbayraktar S, et al. Recombinant human erythropoietin counteracts secondary injury and markedly enhances neurological recovery from experimental spinal cord trauma. *Proc Natl Acad Sci USA* 2002; 99: 9450-5.
 13. Grasso G, Sfacteria A, Erbayraktar S, et al. Amelioration of spinal cord compressive injury by pharmacological preconditioning with erythropoietin and a nonerythropoietic erythropoietin derivative. *J Neurosurg Spine* 2006; 4: 310-8.
 14. Grasso G, Graziano F, Sfacteria A, et al. Neuroprotective effect of erythropoietin and darbepoetin alfa after experimental intracerebral hemorrhage. *Neurosurgery* 2009; 65: 763-9.
 15. Grasso G. Neuroprotective effect of recombinant human erythropoietin in experimental subarachnoid hemorrhage. *J Neurosurg Sci* 2001; 45: 7-14.
 16. Springborg JB, Ma X, Rochat P, et al. A single subcutaneous bolus of erythropoietin normalizes cerebral blood flow autoregulation after subarachnoid haemorrhage in rats. *Br J Pharmacol* 2002; 135: 823-9.
 17. Cherian L, Goodman JC, Robertson C. Neuroprotection with erythropoietin administration following controlled cortical impact injury in rats. *J Pharmacol Exp Ther* 2007; 322: 789-94.
 18. Brines M, Grasso G, Fiordaliso F, et al. Erythropoietin mediates tissue protection through an erythropoietin and common beta-subunit heteroreceptor. *Proc Natl Acad Sci USA* 2004; 101: 14907-12.
 19. Chattopadhyay A, Choudhury TD, Bandyopadhyay D, Datta AG. Protective effect of erythropoietin on the oxidative damage of erythrocyte membrane by hydroxyl radical. *Biochem Pharmacol* 2000; 59: 419-25.
 20. Egrie JC, Browne JK. Development and characterization of darbepoetin alfa. *Oncology (Williston Park)* 2002; 16: 13-22.
 21. Yilmaz ER, Kertmen H, Dolgun H, et al. Effects of darbepoetin-alpha in spinal cord ischemia-reperfusion injury in the rabbit. *Acta Neurochir (Wien)* 2012; 154: 1037-44.
 22. Yilmaz ER, Kertmen H, Güner B, et al. The protective effect of 2-mercaptoethane sulfonate (MESNA) against traumatic brain injury in rats. *Acta Neurochir (Wien)* 2013; 155: 141-9.
 23. Liu D, Shan Y, Valluru L, Bao F. Mn (III) tetrakis (4-benzoic acid) porphyrin scavenges reactive species, reduces oxidative stress, and improves functional recovery after experimental spinal cord injury in rats: comparison with methylprednisolone. *BMC Neurosci* 2013; 14: 23.
 24. Chang CM, Lee MH, Wang TC, Weng HH, Chung CY, Yang JT. Brain protection by methylprednisolone in rats with spinal cord injury. *Neuroreport* 2009; 20: 968-72.
 25. Marmarou A, Foda MA, van den Brink W, Campbell J, Kita H, Demetriadou K. A new model of diffuse brain injury in rats. Part I: Pathophysiology and biomechanics. *J Neurosurg* 1994; 80: 291-300.
 26. Ucar T, Tanriover G, Gurer I, Onal MZ, Kazan S. Modified experimental mild traumatic brain injury model. *J Trauma* 2006; 60: 558-65.
 27. Paglia DE, Valentine WN. Studies on the quantitative and qualitative characterization of erythrocyte glutathione peroxidase. *J Lab Clin Med* 1967; 70: 158-69.
 28. Sun Y, Oberley LW, Li Y. A simple method for clinical assay of superoxide dismutase. *Clin Chem* 1988; 34: 497-500.
 29. Durak I, Kavutcu M, Kaçmaz M, et al. Effects of isoflurane on nitric oxide metabolism and oxidant status of rat myocardium. *Acta Anaesthesiol Scand* 2001; 45: 119-22.
 30. Prajda N, Weber G. Malignant transformation-linked imbalance: decreased XO activity in hepatomas. *FEBS Lett* 1975; 59: 245-9.
 31. Lukacova N, Halat G, Chavko M, Marsala J. Ischemia-reperfusion injury in the spinal cord of rabbits strongly enhances lipid peroxidation and modifies phospholipid profiles. *Neurochem Res* 1996; 21: 869-73.
 32. Southorn PA, Powis G. Free radicals in medicine. II. Involvement in human disease. *Mayo Clin Proc* 1988; 63: 390-408.
 33. Ates O, Cayli S, Altinoz E, et al. Neuroprotection by resveratrol against traumatic brain injury in rats. *Mol Cell Biochem* 2007; 294: 137-44.
 34. Kontos HA, Povlishock JT. Oxygen radicals in brain injury. *Cent Nerv Syst Trauma* 1986; 3: 257-63.
 35. Nishio S, Yunoki M, Noguchi Y, Kawauchi M, Asari S, Ohmoto T. Detection of lipid peroxidation and hydroxyl radicals in brain contusion of rats. *Acta Neurochir Suppl* 1997; 70: 84-6.
 36. Pineda JA, Wang KK, Hayes RL. Biomarkers of proteolytic damage following traumatic brain injury. *Brain Pathol* 2000; 14: 202-9.
 37. Lappin T. The cellular biology of erythropoietin receptors. *Oncologist* 2003; 8: 15-8.
 38. Wright GL, Hanlon P, Amin K, Steenberger C, Murphy E, Arcasoy MO. Erythropoietin receptor expression in adult rat cardiomyocytes is associated with an acute cardioprotective effect for recombinant erythropoietin during ischemia-reperfusion injury. *FASEB J* 2004; 18: 1031-3.
 39. Ates E, Yalcin AU, Yilmaz S, Koken T, Tokyol C. Protective effect of erythropoietin on renal ischemia and reperfusion injury. *ANZ J Surg* 2005; 75: 1100-5.
 40. Kaptanoglu E, Solaroglu I, Okutan O, Surucu HS, Akbiyik F, Beskonakli E. Erythropoietin exerts neuroprotection after acute spinal cord injury in rats: effect on lipid peroxidation and early ultrastructural findings. *Neurosurg Rev* 2004; 27: 113-20.
 41. Marti HH, Bernaudin M, Petit E, Bauer C. Neuroprotection and angiogenesis: dual role of erythropoietin in brain ischemia. *News Physiol Sci* 2000; 15: 225-9.
 42. Sadamoto Y, Igase K, Sakanaka M, et al. Erythropoietin prevents place navigation disability and cortical infarction

- in rats with permanent occlusion of the middle cerebral artery. *Biochem Biophys Res Commun* 1998; 253: 26-32.
43. Sakanaka M, Wen TC, Matsuda S, et al. In vivo evidence that erythropoietin protects neurons from ischemic damage. *Proc Natl Acad Sci USA* 1998; 95: 4635-40.
44. Sirén AL, Fratelli M, Brines M, et al. Erythropoietin prevents neuronal apoptosis after cerebral ischemia and metabolic stress. *Proc Natl Acad Sci USA* 2001; 98: 4044-9.
45. Banks WA, Jumbe NL, Farrell CL, Niehoff ML, Heatherington AC. Passage of erythropoietic agents across the blood-brain barrier: a comparison of human and murine erythropoietin and the analog darbepoetin alfa. *Eur J Pharmacol* 2004; 505: 93-101.
46. Belayev L, Khoutorova L, Zhao W, et al. Neuroprotective effect of darbepoetin alfa, a novel recombinant erythropoietic protein, in focal cerebral ischemia in rats. *Stroke* 2005; 36: 1071-6.
47. Yang WS, Chang JW, Han NJ, Park SK. Darbepoetin alfa suppresses tumor necrosis factor- α -induced endothelin-1 production through antioxidant action in human aortic endothelial cells: role of sialic acid residues. *Free Radic Biol Med* 2011; 50: 1242-51.
48. Egrie JC, Browne JK. Development and characterization of novel erythropoiesis stimulating protein (NESP). *Nephrol Dial Transplant* 2001; 16: 3-13.
49. Iijima R, Takahashi H, Namme R, Ikegami S, Yamazaki M. Novel biological function of sialic acid (N-acetylneuraminic acid) as a hydrogen peroxide scavenger. *FEBS Lett* 2004; 561: 163-6.
50. d'Uscio LV, Smith LA, Katusic ZS. Erythropoietin increases expression and function of vascular copper- and zinc-containing superoxide dismutase. *Hypertension* 2010; 55: 998-1004.
51. Katavetin P, Inagi R, Miyata T, et al. Erythropoietin induces heme oxygenase-1 expression and attenuates oxidative stress. *Biochem Biophys Res Commun* 2007; 359: 928-34.
52. Elliott S, Pham E, Macdougall IC. Erythropoietins: a common mechanism of action. *Exp Hematol* 2008; 36: 1573-84.
53. Cassis P, Azzollini N, Solini S, et al. Both darbepoetin alfa and carbamylated erythropoietin prevent kidney graft dysfunction due to ischemia/reperfusion in rats. *Transplantation* 2011; 92: 271-9.
54. Akcora B, Altug ME, Kontas T, Atik E. The protective effect of darbepoetin alfa on experimental testicular torsion and detorsion injury. *Int J Urol* 2007; 14: 846-50.
55. Shohami E, Beit-Yannai E, Horowitz M, Kohen R. Oxidative stress in closed-head injury: brain antioxidant capacity as an indicator of functional outcome. *J Cereb Blood Flow Metab* 1997; 17: 1007-19.
56. Tyurin VA, Tyurina YY, Borisenko GG, et al. Oxidative stress following traumatic brain injury in rats: quantitation of biomarkers and detection of free radical intermediates. *J Neurochem* 2000; 75: 2178-89.
57. Ozdemir D, Uysal N, Gonenc S, et al. Effect of melatonin on brain oxidative damage induced by traumatic brain injury in immature rats. *Physiol Res* 2005; 54: 631-7.
58. Evans PH. Free radicals in brain metabolism and pathology. *Br Med Bull* 1993; 49: 577-87.
59. Rodriguez C, Mayo JC, Sainz RM, et al. Regulation of antioxidant enzymes: a significant role for melatonin. *J Pineal Res* 2004; 36: 1-9.
60. Schaller BJ. The role of endothelin in stroke: experimental data and underlying pathophysiology. *Arch Med Sci* 2006; 2: 146-58.
61. Erkan Ustün M, Md AD, Oztin Oğün C, Sümer F, Gürbilek M. Effects of deferoxamine on tissue superoxide dismutase and glutathione peroxidase levels in experimental head trauma. *J Trauma* 2001; 51: 22-5.
62. Ustün ME, Duman A, Oğün CO, Vatansev H, Ak A. Effects of nimodipine and magnesium sulfate on endogenous antioxidant levels in brain tissue after experimental head trauma. *J Neurosurg Anesthesiol* 2001; 13: 227-32.
63. Fan P, Yamauchi T, Noble LJ, Ferriero DM. Age-dependent differences in glutathione peroxidase activity after traumatic brain injury. *J Neurotrauma* 2003; 20: 437-45.
64. Bramlett HM, Dietrich WD. Pathophysiology of cerebral ischemia and brain trauma: similarities and differences. *J Cereb Blood Flow Metab* 2004; 24: 133-50.
65. Alderton WK, Cooper CE, Knowles RG. Nitric oxide synthases: structure, function and inhibition. *Biochem J* 2001; 357: 593-615.
66. Mesenge C, Verrecchia C, Allix M, Boulu RR, Plotkine M. Reduction of the neurological deficit in mice with traumatic brain injury by nitric oxide synthase inhibitors. *J Neurotrauma* 1996; 13: 209-14.
67. Wada K, Chatzipanteli K, Busto R, Dietrich WD. Role of nitric oxide in traumatic brain injury in the rat. *J Neurosurg* 1998; 89: 807-18.
68. Sinz EH, Kochanek PM, Dixon CE, et al. Inducible nitric oxide synthase is an endogenous neuroprotectant after traumatic brain injury in rats and mice. *J Clin Invest* 1999; 104: 647-56.
69. Jones NC, Constantin D, Gibson CL, et al. A detrimental role for nitric oxide synthase-2 in the pathology resulting from acute cerebral injury. *J Neuropathol Exp Neurol* 2004; 63: 708-20.
70. Hille R, Nishino T. Flavoprotein structure and mechanism. 4. Xanthine oxidase and xanthine dehydrogenase. *FASEB J* 1995; 9: 995-1003.
71. Kanemitsu H, Tamura A, Kirino T, et al. Allopurinol inhibits uric acid accumulation in the rat brain following focal cerebral ischemia. *Brain Res* 1989; 499: 367-70.
72. Itoh T, Kawakami M, Yamauchi Y, Shimizu S, Nakamura M. Effect of allopurinol on ischemia and reperfusion-induced cerebral injury in spontaneously hypertensive rats. *Stroke* 1986; 17: 1284-7.
73. Diaz-Ruiz A, Rios C, Duarte I, et al. Lipid peroxidation inhibition in spinal cord injury: cyclosporin-A vs methylprednisolone. *Neuroreport* 2000; 11: 1765-7.
74. Qian H, Liu D. The time course of malondialdehyde production following impact injury to rat spinal cord as measured by microdialysis and high pressure liquid chromatography. *Neurochem Res* 1997; 22: 1231-6.
75. Kobeissy FH, Ottens AK, Zhang Z, et al. Novel differential neuroproteomics analysis of traumatic brain injury in rats. *Mol Cell Proteomics* 2006; 5: 1887-98.
76. Keane RW, Kraydieh S, Lotocki G, et al. Apoptotic and anti-apoptotic mechanisms following spinal cord injury. *J Neuropathol Exp Neurol* 2001; 60: 422-9.
77. Sakurai M, Nagata T, Abe K, Horinouchi T, Itoyama Y, Tabayashi K. Survival and death-promoting events after transient spinal cord ischemia in rabbits: induction of Akt and caspase 3 in motor neurons. *J Thorac Cardiovasc Surg* 2003; 125: 370-7.
78. Dolgun H, Sekerci Z, Turkoglu E, et al. Neuroprotective effect of mesna (2-mercaptoethane sulfonate) against spinal cord ischemia/reperfusion injury in rabbits. *J Clin Neurosci* 2010; 17: 486-9.