

Unsuspected myasthenia gravis presenting as respiratory failure

Anne Mier, Clare Laroche, Malcolm Green

Abstract

A patient developed respiratory failure after surgical removal of a recurrent thymoma, which necessitated removal of part of the diaphragm. The respiratory failure was due to previously undiagnosed myasthenia gravis, which had selectively affected the respiratory muscles.

It is well known that patients with myasthenia gravis may have respiratory muscle weakness. Myasthenia may, however, affect the respiratory muscles very selectively. We describe a patient who presented with respiratory failure due to severe respiratory muscle weakness, in whom the diagnosis of myasthenia gravis was not obvious initially.

Case report

A 45 year old man, a smoker, underwent uneventful excision of a thymic tumour that had been detected on a routine chest radiograph. A test with edrophonium hydrochloride (Tensilon) at this time gave a negative result. Seven years later the tumour was found to have recurred and at operation a part of the right hemidiaphragm was resected during excision of the mass. Postoperatively he required a prolonged period of intermittent ventilation, which was thought to be a result of mechanical difficulties caused by damage to the hemidiaphragm. He was finally weaned off the ventilator and discharged, but was readmitted several days later with severe breathlessness at rest and confusion, and was found to be in gross respiratory failure. When questioned at this time he denied dysphagia, dysarthria, or any other muscle weakness. On examination he was using his accessory muscles of respiration and had paradoxical inward motion of the abdomen on inspiration when supine. There was mild bilateral ptosis and facial weakness but no limb muscle weakness. He was reintubated and ventilated for several days. On being weaned off the ventilator he was able to maintain normal arterial blood gases during the day, but continued to require external ventilatory support in an iron lung at night. Forced expiratory volume in one second was 1.1 l (68% predicted) and vital capacity 2.1 l (45% predicted) when he was

sitting, falling to 1.5 l when he was supine, a postural fall of 29% (normal <25%).¹

Chest radiography showed a raised right hemidiaphragm. Diaphragm screening showed paradoxical motion of the right hemidiaphragm with diminished movement of the left hemidiaphragm (2.5 cm; normal >3 cm). Diaphragm muscle action potentials during phrenic nerve stimulation by surface electrodes were low (250 μ v). Conduction time of both right and left phrenic nerves was normal (4.5 ms; normal <9.5 ms). Maximal static inspiratory and expiratory mouth pressures were low (inspiratory (P_{imax}) 20 (normal >44²) cm H₂O; expiratory (P_{emax}) was 48 (normal >80²) cm H₂O). Transdiaphragmatic pressures (P_{di}) during a maximal static inspiratory effort (P_{di}P_{imax}) against an obstructed valve with a specially designed mouth-piece³ at residual volume was 5 (normal >18) cm H₂O. P_{di} recorded during a maximal inspiration to total lung capacity⁴ (P_{di}TLC) was 15 (normal >25) cm H₂O. Transdiaphragmatic pressure (fig 1) recorded during a series of 10 reproducible maximal sniffs (sniff P_{di})⁵ was greatly reduced at 15 cm H₂O (normal >98) cm H₂O; after intravenous edrophonium hydrochloride this increased to 35 cm H₂O, suggesting the diagnosis of myasthenia gravis. There was no response to a placebo injection of saline. Repetitive stimulation of the right ulnar, median, and accessory nerves at 3 Hz produced no decrement in response. Single fibre electromyography of the extensor digitorum communis muscle gave inconclusive results. Antiacetylcholine receptor antibodies were present at a titre of 1/124. Myasthenia gravis was diagnosed and treatment started with oral azathioprine, 150 mg daily, and prednisolone, 80 mg on alternate days.

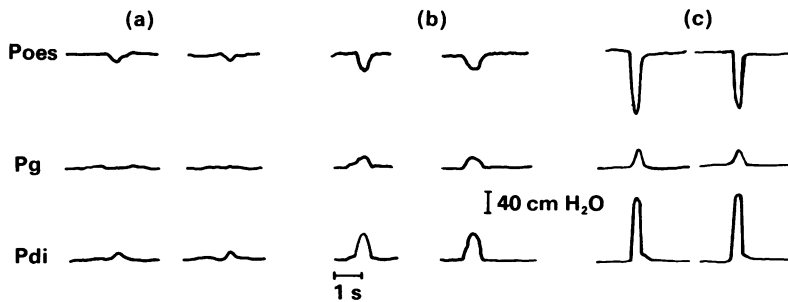
Three months later the patient's breathlessness had improved and his exercise tolerance was 200 m, but he still had orthopnoea. P_{imax} was 36 cm H₂O, P_{emax} 90 cm H₂O, P_{di}P_{imax} 12.5 cm H₂O, and P_{di}TLC 22.5 cm H₂O, and sniff P_{di} had increased to 45 cm H₂O. Seven months later, while he was still having immunosuppressive treatment, his exercise tolerance had increased to 1.6 km and he had no orthopnoea. P_{imax} was 74 cm H₂O, P_{emax} 124 cm H₂O, P_{di}max 85 cm H₂O, and P_{di}TLC 55 cm H₂O, and sniff P_{di} had increased to 100 cm H₂O. Only after his strength had improved with treatment did the patient and his relatives realise that he had gradually been developing ptosis, breathlessness, and difficulty in chewing and swallowing over several years.

Discussion

This patient had myasthenia gravis presenting with respiratory failure due to respiratory muscle weakness. Several studies have reported respiratory muscle weakness in patients with generalised myasthenia gravis.⁶⁻⁸ This case is unusual in that the respiratory muscles were affected predominantly and we were able to quantify an improvement in diaphragm

Department of
Respiratory Muscle
Physiology, Brompton
Hospital, London
A Mier
C Laroche
M Green

Address for reprint requests:
Dr Anne Mier,
Department of Medicine,
Charing Cross Hospital,
London W6 8RF.



Oesophageal (Poes), gastric (Pg), and transdiaphragmatic (Pdi) pressures during maximal sniffs (a) at presentation, and after treatment with prednisolone and azathioprine for (b) three months and (c) for seven months.

strength during treatment. The underlying diagnosis was in doubt until careful evaluation of diaphragm and respiratory muscle strength was carried out and before it was confirmed by finding antiacetylcholine receptor antibodies.

Global respiratory muscle strength may be assessed by recording maximal static respiratory mouth pressures; and sequential measurements have been used to monitor improvement in muscle strength after treatment in conditions such as thyrotoxicosis.⁹ The strength of the diaphragm may be assessed by recording transdiaphragmatic pressures, most reliably during maximal sniffs.^{5,10}

Although this man had thoracic surgery, it is unlikely that either of his phrenic nerves were damaged as conduction times were normal. Small action potentials may be found in the presence of severe diaphragmatic weakness, as in our patient, although they are absent in complete paralysis of the diaphragm. The action potentials were of normal M wave pattern and were present consistently on several occasions. If this patient's diaphragm weakness had been caused by damage to the diaphragm during surgery, his symptoms and respiratory pressures would not be expected to have improved with immunosuppressive treatment. His expiratory muscle strength should not have been affected by diaphragm resection, and would not have improved with therapy, as it did, if damage to the diaphragm had been the only cause of his weakness. Thus this patient's respiratory muscle weakness appears to have been related principally to his myasthenia gravis. Myasthenia gravis of the diaphragm was diagnosed on the basis of clinical signs, low transdiaphragmatic pressures, and an increase in strength over seven months after he started immunosuppressive treatment. Recovery may take a long time in patients with myasthenia gravis; in this case improvement of respiratory symptoms mirrored the improvement in maximal respiratory and diaphragmatic pressures.

Although our patient had a minor degree of ptosis, he claimed that this was longstanding

and denied other symptoms of muscle weakness or fatiguability. Only when his strength improved with treatment did he realise that he had been having difficulty with chewing and swallowing. Myasthenic symptoms are usually less insidious in onset but difficulty in obtaining a precise history may contribute to delay in diagnosis. Peripheral muscle electromyograms may fail to show characteristic fatiguability, as in this case. Single fibre electromyography of peripheral muscles is the most sensitive electrophysiological test for detecting abnormal neuromuscular transmission, but is not specific.^{11,12} The peripheral muscles studied in this patient were not affected and a positive response was not obtained. Muscle power does not always improve after intravenous injection of edrophonium hydrochloride, and antibodies to acetylcholine receptors may be absent, particularly in patients with ocular myasthenia.¹³ When antibodies are found, they are highly specific for the diagnosis of myasthenia gravis.

This case illustrates the importance of considering myasthenia gravis as a cause of respiratory failure, even when other skeletal muscles are not obviously affected.

We are grateful to Dr Charles Hind and Dr Margaret Branthwaite for permission to report this patient, who was also under their clinical care.

- 1 Allen SM, Hunt B, Green M. Fall in vital capacity with posture. *Br J Dis Chest* 1985;79:267-71.
- 2 Wilson SH, Cooke NT, Edwards RHT, Spiro SG. Predicted normal values for maximum respiratory pressures in caucasian adults and children. *Thorax* 1984;39:535-8.
- 3 DeTroyer A, Estenne M. Limitation of measurement of transdiaphragmatic pressures in detecting diaphragm weakness. *Thorax* 1981;36:169-74.
- 4 Newsom Davis J, Goldman M, Loh L, Casson M. Diaphragm function and alveolar hypoventilation. *Q J Med* 1976;45:87-100.
- 5 Miller J, Moxham J, Green M. The maximal sniff in the assessment of diaphragm function in man. *Clin Sci* 1985;69:91-6.
- 6 Ringqvist I, Ringqvist T. Respiratory Mechanics in untreated myasthenia gravis with special reference to the respiratory forces. *Acta Med Scand* 1971;190:499-508.
- 7 Ringqvist I, Ringqvist T. Changes in respiratory mechanics in myasthenia gravis with therapy. *Acta Med Scand* 1971;190:509-18.
- 8 Mier A, Harvard CW. Diaphragmatic myasthenia in mother and child. *Postgrad Med J* 1985;61:725-7.
- 9 Mier A, Brophy C, Wass J, Besser G, Green M. Reversible respiratory muscle weakness in hyperthyroidism. *Am Rev Respir Dis* 1989;139:529-33.
- 10 Mier-Jedrzejowicz A, Brophy C, Moxham J, Green M. Assessment of diaphragm weakness. *Am Rev Respir Dis* 1988;137:877-83.
- 11 Stalberg E, Trontel J. Single fibre electromyography. Old Woking, Surrey: Mirvalle, 1979.
- 12 Ozdemir C, Young R. The results to be expected from electrical testing in the diagnosis of myasthenia gravis. *Am N Y Acad Sci* 1976;174:203-22.
- 13 Lindstrom JM, Seybold ME, Lennon VA, Whittingham S, Duane DD. Antibody to acetylcholine receptor in myasthenia gravis: prevalence, clinical correlates and diagnostic value. *Neurology* 1976;26:1054-9.