

Ectopic Paratubal Adrenal Cell Rest Associated with Mucinous Cystadenoma of Ovary

BINNY KHANDAKAR¹, SOUMIT DEY², PRASENJIT SEN RAY³, RANU SARKAR⁴, PALAS BHATTACHARYYA⁵

ABSTRACT

Ectopic adrenal cortex is a rare entity. Usually found in male children; commonly located around kidney, retroperitoneum, spermatic cord and para-testicular region. Rarely, adults with heterotopic adrenal glands are described. Incidence in females is very less; though sometimes detected accidentally in hysterectomy specimens. We describe a case of ectopic adrenal cortical cell in paratubal region in a patient with mucinous cyst adenoma of ovary. A 26-year-old female presented with complains of menstrual irregularities and abdominal discomfort for 6 months. Investigations suggested a right ovarian cyst. Right ovarian cystectomy with partial salpingectomy was performed; histopathology revealed mucinous cyst adenoma. Sections from tube showed presence of ectopic adrenal cortical rest in the paratubal region, incidentally discovered on microscopy. We present this case because of its rarity in females, interesting presentation with another unrelated gynaecological pathology, its potentiality for malignant transformation and possible complications.

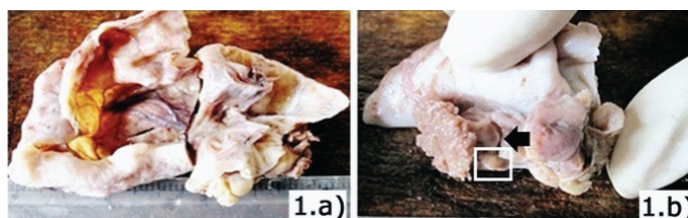
Keywords: Menstrual abnormalities, Ovarian cystectomy

CASE REPORT

A 26-year-old female presented to the gynaecology outpatient department of our institute with complaints of menstrual abnormalities and vague abdominal discomfort for 6 months. Patient's menstrual history revealed menarche at 11 years and a regular 29 day cycle with 4-5 days menstruation with moderate bleeding earlier to the onset of symptoms. She was G1P1; baby was delivered by lower (uterine) segment caesarean section four years back. Per-abdominal examination revealed a vague lump in right lower abdomen. An initial imaging (ultrasound) work up revealed a predominantly cystic lesion of right ovary, measuring 8X5 cm, without any other obvious abnormality or fluid collection in peritoneum. Other laboratory investigations including a complete blood picture, routine urine analysis, blood biochemistry, serum antigen (CA-125), all were within normal limits, except for mild anaemia. An ultrasound guided aspirate was tried, which yielded mostly clear fluid; microscopy did not reveal any definite malignant cells. The patient was subsequently scheduled for laparotomy and she underwent right ovarian cystectomy with oophorectomy and partial salpingectomy. The excised specimen was sent for histopathological examination.

Gross and Microscopy

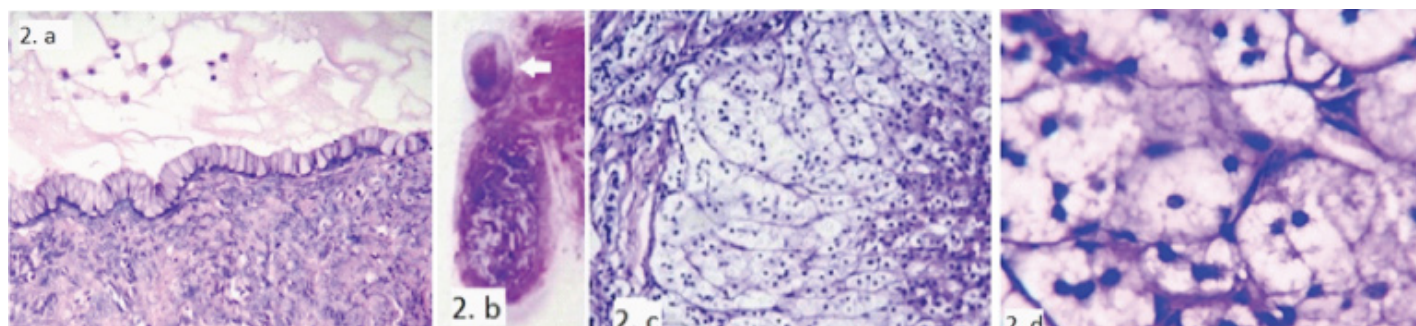
The specimen sent was partially cut opened and labelled as 'right ovarian cystectomy', measured 8X5X2.5 cm; comprised of multiloculated cyst with smooth inner wall, containing clear to mucoid



[Table/Fig-1a]: Gross Photograph: Cut opened specimen of 'right ovarian cystectomy' showing smooth cyst wall

[Table/Fig-1b]: Gross Photograph: attached tube. Area from where section was taken (Black arrow). Yellowish-white nodule adjacent to tube (white square)

fluid [Table/Fig-1a]. No definite solid area was identified. Attached tube measured 4 cm in length, 1.5 cm in diameter [Table/Fig-1b]. Multiple sections examined from the ovarian cyst on microscopy showed a cyst wall lined by single layer of tall columnar cells, without any nuclear atypia/stratifications [Table/Fig-2a]. Unexpectedly, one of the whole mount view of cyst with fallopian tube revealed presence of a well-defined tiny nodule (0.6X0.4 cm) just adjacent to the tube [Table/Fig-2b], which on microscopy showed a well encapsulated adrenal cortex without medulla [Table/Fig-2c]. The cells of ectopic adrenal cortex were arranged in cords and trabeculae, perpendicular to the capsule [Table/Fig-2c]. The cells of zona fasciculata were most abundant, followed by reticularis. Cells of glomerulosa were sparse, 1-2 layer thick, located just beneath the capsule. Cells of zona fasciculata were large polygonal with abundant foamy cytoplasm and bland small pyknotic nuclei [Table/



[Table/Fig-2a]: Ovarian cyst wall lined by single layer of tall columnar cells, without any nuclear atypia/stratifications (H&E stain, 100X)

[Table/Fig-2b]: Whole mount view of fallopian tube showing a well-defined tiny nodule just adjacent to the tube (white arrow)

[Table/Fig-2c]: Well encapsulated adrenal cortex without medulla, predominate cells being cells of zona fasciculata and reticularis (H&E stain, 100X)

[Table/Fig-2d]: Large polygonal cells with abundant foamy cytoplasm and bland small pyknotic nuclei, morphologically consistent with cells of zona fasciculata (H&E stain, 400X)

Fig-2d]. The cells of reticularis contained bright eosinophilic granular cytoplasm and round vesicular nuclei, situated next to fasciculata. After finding ectopic adrenal rest we took another look into the specimen from where section of the tube was taken [Table/Fig-1b]; a tiny whitish-yellowish area was noted, which was initially thought as Walthard cell rest. A final histopathological diagnosis of mucinous cyst adenoma of right ovary with ectopic adrenal cell rest adjacent to fallopian tube was offered.

Following the incidental discovery of ectopic adrenal cell rest a thorough history and examination was done to look for any signs/symptoms of any abnormal hormone production from the ectopic adrenal rest. Our patient did not have any signs/symptoms of hormone production from the ectopic adrenal tissue at any point of time. Her sole complain was related to the right ovarian cyst she had. The patient was discharged one week after surgery and at two month follow up she is doing well without any complaints.

DISCUSSION

Ectopic adrenal cell rest can be found anywhere in the genitourinary tract. It was first described by Morgagni, detected as yellowish nodules resembling adrenal gland. Most of the ectopic adrenal rests are reported in relation to kidney; rarely these have been described in other sites including retroperitoneum, male genital tract [1]. It has seldom been described in other organs including ovary, broad ligament, testis, spermatic cord and stomach [2,3]. The clinical significance of ectopic adrenal tissue is usually minimal. It is commonly detected in autopsies or as an incidental finding in patients with some other pathology. Most of these rests are non-functional and rarely cause any problem; however, rarely, functional adenomas at the ectopic sites can occur [2]. Ectopic adrenal cell rest is very rare in females; broad ligament or mesosalpinx is the usual location [3]. Here we describe a case of incidentally detected ectopic adrenal rest in the paratubal region on right side, in a 26-year-old female with mucinous cyst adenoma of ovary of the same side. Common differentials of small paratubal mass include Walthard cell nests, adenomatoid tumours. Walthard cell nests are composed of a benign cluster of epithelial cells; adenomatoid tumour is mesothelial in origin; shows presence of numerous cords, tubules, composed of cuboidal to columnar cells having vacuolated cytoplasm and fibrous stroma [4].

Ectopic adrenal gland is typically detected incidentally in male child and sporadically in adults. Their exact origin is yet not evident, though some believe role of pluripotent stem cells for this heterotopias [5]. These heterotopic adrenal cell rests are usually detected in children, median age in reported literature being 5.8 years and is five times commoner in children than adults [6].

Grossly these can vary in size; in our case it was 0.6 cm. These nodules can sometimes undergo hyperplastic/adenomatous/

malignant change and become large [2,7]. Occasionally a hyperplastic adrenal cell rest can be detected in broad ligament of females, who have lost a functional adrenal due to some disease process hampering proper functioning of the primary gland, like tuberculosis. Rarely patients with Nelson syndrome have been found to have hyperplastic adrenal rests [8,9].

Microscopically, adrenal rests are characteristically composed solely of adrenocortical-type cells. These cells are large polygonal with abundant vacuolated to eosinophilic granular cytoplasm, with small bland vesicular to pyknotic nuclei, depending on the type of cortical cells. In some reports, well-formed zona reticularis has not been detected [1,5]; however in our case zona glomerulosa was less; the reason for such case to case variability is difficult to commit.

Generally these rests do not produce any clinical symptoms, like the current case; however they may become symptomatic with change in biological behaviour, such transformation can pose substantial morbidity and mortality to patients [2,3].

CONCLUSION

Ectopic adrenal cortical cell rest is rare and uncommonly found in pelvis of adult females. It is commonly indolent in most cases as in the present case, rarely can show alterations in biological behaviour, such as hyperplasia or neoplasia resulting in potential complications. A careful search for any such change should be made on detection of ectopic adrenal rest and histopathologists need to be aware of this rare entity. We reported this case for its rarity and interesting incidental discovery in a patient being treated for a different pathology.

REFERENCES

- [1] Schechter DC. Aberrant adrenal tissue. *Ann Surg*. 1968;167(3):421-26.
- [2] Surrey LF, Thaker AA, Zhang PJ, Karakousis G, Feldman MD. Ectopic functioning adrenocortical oncocytic adenoma (oncocytoma) with myelolipoma causing virilization. *Case Rep Pathol*. 2012;2012:326418.
- [3] Kasajima A, Nakamura Y, Adachi Y, Takahashi Y, Fujishima F, Chiba Y, et al. Oncocytic adrenocortical neoplasm arising from adrenal rest in the broad ligament of the uterus. *Pathol Int*. 2014;64(4):183-88.
- [4] Sheng B, Zhang YP, Wei HH, Ma M, Nan X. Primary adenomatoid tumour of the testis: report of a case and review of literature. *Int J Clin Exp Pathol*. 2015;8(5):5914-18.
- [5] Anderson JR, Ross AH. Ectopic adrenal tissue in adults. *Postgrad Med J*. 1980;56(661):806-08.
- [6] Mendez R, Tellado MG, Somoza I, Liras J, Sanchez-Abuin A, Pais E, et al. Ectopic adrenal tissue in the spermatic cord in pediatric patients: surgical implications. *Int Braz J Urol*. 2006;32(2):202-07.
- [7] Ren PT, Fu H, He XW. Ectopic adrenal cortical adenoma in the gastric wall: case report. *World J Gastroenterol*. 2013;19(5):778-80.
- [8] Wild RA, Albert RD, Zaino RJ. Virilizing paraovarian tumours: a consequence of Nelson's syndrome? *Obstet Gynecol*. 1988;71(6 Pt 2):1053-56.
- [9] Verdonk C, Guerin C, Lufkin E. Activation of virilising adrenal rest tissues by excessive ACTH production: an unusual presentation of Nelson's syndrome. *Am J Med*. 1982;73(3):455-59.

PARTICULARS OF CONTRIBUTORS:

1. Demonstrator, Department of Pathology, Nil Ratan Sircar Medical College & Hospital, Kolkata, India.
2. Demonstrator, Department of Pathology, Nil Ratan Sircar Medical College & Hospital, Kolkata, India.
3. Demonstrator, Department of Pathology, Nil Ratan Sircar Medical College & Hospital, Kolkata, India.
4. Professor, Department of Pathology, Nil Ratan Sircar Medical College & Hospital, Kolkata, India.
5. Associate Professor, Department of Pathology, Nil Ratan Sircar Medical College & Hospital, Kolkata, India.

NAME, ADDRESS, E-MAIL ID OF THE CORRESPONDING AUTHOR:

Dr. Binny Khandakar,
Flat No 6 18 Deedar Bux Lane, Kolkata-700016, West Bengal, India.
E-mail : binnikhandakar@gmail.com

FINANCIAL OR OTHER COMPETING INTERESTS: None.

Date of Submission: **Jun 28, 2015**
Date of Peer Review: **Aug 10, 2015**
Date of Acceptance: **Aug 24, 2015**
Date of Publishing: **Oct 01, 2015**