

fungal disease, on the basis of Greenberger's criteria for allergic bronchopulmonary aspergillosis.¹ The strongly positive precipitin bands and skin test responses to *P boydii* and the heavy growth of the fungus confirm its likely pathogenicity in this patient. Additionally, the growth of *Aspergillus terreus*, with a positive skin test response and precipitins, is consistent with mixed allergic bronchopulmonary fungal disease.

Our patient also had positive skin test reactions and precipitins in response to other fungi, a finding common in asthmatic patients, individuals who do not have allergic bronchopulmonary fungal disease. The clinical significance of these reactions is not clear and their presence may in part be due to cross reactivity between common fungi. Cross reactivity between *Aspergillus* species exists, though in this patient cross reactivity of *P boydii* with *Aspergillus* seems unlikely, as shown by immunodiffusion tests using rabbit antisera.

This patient's condition supports the concept of "allergic bronchopulmonary fungal disease" as opposed to "allergic bronchopulmonary aspergillosis", as an increasingly wide range of fungi are being shown to cause a syndrome identical to that commonly

associated with *Aspergillus* species. In suspected allergic bronchopulmonary fungal disease where all tests for *Aspergillus* give negative results the possibility of other fungi, such as *P boydii*, as causative agents should be investigated.

- Greenberger PA. Allergic bronchopulmonary aspergillosis. *J Allergy Clin Immunol* 1984;74:645-52.
- McAleer R, Kroenert DB, Elder JL, Froudast JH. Allergic bronchopulmonary fungal disease caused by *Curvularia lunata* and *Drechslera hawaiiensis*. *Thorax* 1981;36:338-44.
- Adam RD, Paquin ML, Petersen EA, et al. Phaeohyphomycosis caused by the fungal genera *Bipolaris* and *Exserohilum*. A report of 9 cases and a review of the literature. *Medicine (Baltimore)* 1986;65:203-17.
- Rippon JW, Carmichael JW. Petriellidiosis (allescheriosis): four unusual cases and review of literature. *Mycopathologia* 1976;58:117-24.
- MacKenzie DWA, Proctor AGJ, Philpot CM. Basic serodiagnostic methods for disease caused by fungi and actinomycetes. London: Public Health Laboratory Services, 1980:13,40-2. (UK monograph series, vol 12.)
- Winston DJ, Jordan MC, Rhodes J. *Allescheria boydii* infections in the immunosuppressed host. *Am J Med* 1977;63:830-5.
- Chaudhary BA, McAlexander D, El Gommel T, Spier WA. Multiple mycetomas due to *Pseudallescheria boydii*. *South Med J* 1987;80:653-4.
- Seale JP, Hudson JA. Successful medical treatment of pulmonary petriellidiosis. *South Med J* 1985;78:473-6.
- Arnett JC, Hatch HB. Pulmonary allescheriosis. Report of a case and review of the literature. *Arch Intern Med* 1975;135:1250-3.
- Severo LC, Londero AT, Picon D, Rizzon CFC, Tarasconi JC. *Petriellidium boydii* fungus ball in a patient with active tuberculosis. *Mycopathologia* 1982;77:13-7.

Mediastinitis and bilateral thoracic empyemas complicating adult epiglottitis

W H Chong, M A Woodhead,
F J C Millard

Abstract

A 32 year old woman developed life threatening mediastinitis and bilateral empyemas as a complication of adult epiglottitis. She recovered completely.

Mediastinitis following deep neck infections was well recognised in the preantibiotic era. In Pearses's series of 110 cases the main cause was perforation of the oesophagus.¹ Twenty three cases resulted from abscesses in the oropharynx. Mediastinitis complicating oropharyngeal infections is now uncommon.

Acute epiglottitis in adults is an uncommon but important condition.²⁻⁴ This is the first reported case of acute epiglottitis complicated by mediastinitis and thoracic empyema.

Case history

A previously fit 32 year old woman presented with a few hours' history of sore throat and dysphagia followed by progressive dyspnoea. On examination she had a temperature of 37.6°C, inspiratory stridor, a muffled voice, drooling saliva, and a tender neck. A lateral

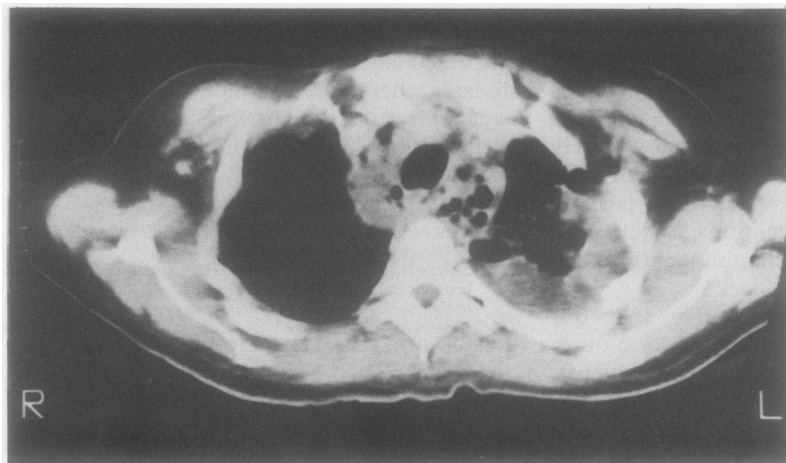
neck radiograph showed a swollen epiglottitis, but the chest radiograph was normal. Flexible laryngoscopy showed swelling of supraglottic structures. The leucocyte count was $22.4 \times 10^9/l$ with neutrophilia. Blood cultures were sterile. Serological examination of paired specimens showed no appreciable rise in the titre of antibodies to viruses or atypical bacteria. She was treated with intravenous chloramphenicol and hydrocortisone followed by dexamethasone. She gradually improved and was afebrile by the fifth day.

On the sixth day she developed a constant left anterior chest pain, increasing breathlessness, and haemoptysis. A pleural rub was present at the left base. The chest radiograph showed a small left pleural effusion. She was given intravenous heparin for a presumed pulmonary embolus but her condition deteriorated. Subsequent radiographs showed widening of the mediastinum, an increasing left pleural effusion, and a small left sided pneumothorax. On the eighth day one litre of foul smelling pus was aspirated from the left hemithorax. This grew mixed anaerobes and *Streptococcus milleri*. Anticoagulation was discontinued and she was treated with benzylpenicillin, gentamicin, and metronidazole. Computed tomography showed fluid and gas in the anterior and posterior mediastinum and confirmed the presence of bilateral pleural effusions. No oesophageal leak was detected from a gastrografin swallow. Intercostal chest drains were introduced into both pleural cavities. Transcervical exploration and drainage of the mediastinum was performed. After these procedures mechanical ventilation was required for three days and was complicated by paroxysmal fast atrial fibrillation.

Chest Clinic,
St George's Hospital,
London
W H Chong
M A Woodhead
F J C Millard

Address for correspondence:
Dr M A Woodhead,
Brompton Hospital,
London SW3

Accepted 12 February 1990



Computed tomogram of the upper thorax showing fluid in the left pleural space and multiple gas filled cavities in the mediastinum.

The patient made a gradual recovery and all drainage tubes were removed by the 11th postoperative day. On the 28th postoperative day a further small amount of pus was aspirated from a loculated collection in the left hemithorax. There was no growth on the culture. She was discharged a week later and continued to improve over the next three months.

Discussion

This patient developed severe thoracic complications of an oropharyngeal infection. In epiglottitis there is oedema and inflammatory cell infiltration of the supraglottic structures. An abscess may form^{3,4} but this is rare; it occurred in only one of 56 adult cases.² No abscess in the oropharynx could be found in our case. In the absence of evidence of oesophageal perforation the mediastinitis was probably due to direct spread of infection from the supraglottic area.

In our patient inflammation is likely to have spread initially into the parapharyngeal space. From there it can enter the retropharyngeal space, which is continuous with the retrovisceral space below the sixth cervical vertebra (this is the space around the pharynx, oesophagus and trachea that is enclosed by the alar fasciae). Below the level of the third thoracic vertebra pus can rupture into a space filled by the loose connective tissue that lies between the alar fasciae anteriorly and the prevertebral fascia posteriorly and reaches inferiorly to the diaphragm. Infection reaching here can potentially affect a large portion of the posterior mediastinum. Empyema results, with rupture of pus through the

parietal pleura into the pleural space. This is believed to be the main route of spread from the oropharynx into the mediastinum.⁵⁻⁹ A less common route is via the space within the carotid sheath.

Blood cultures are not uncommonly negative in adult epiglottitis. The positive cultures mostly grow *Haemophilus influenzae*.^{2,4} Viridans streptococci have been known to cause epiglottitis.⁴ A viridans streptococcus, *S milleri*, was grown from pus from the pleural cavity of our patient but we cannot be certain that this was the initial infecting organism. The bacteriology of mediastinitis is varied and often both aerobes and anaerobes are present.¹⁰ The symbiotic relationship between these groups of microorganisms contributes to the fulminant nature of the infection.⁵

The use of corticosteroids in acute epiglottitis is controversial.^{3,4} Steroids are claimed to decrease the oedema and inflammation of the supraglottic structures, but there is insufficient evidence that their use is beneficial. Steroids may have contributed to the spread of infection in our patient.

Mediastinitis is an unusual complication of oropharyngeal infection but should be suspected in any patient developing thoracic symptoms. Prompt recognition is vital if appropriate treatment is to be given and is aided by the use of computed tomography, which can show the changes in the mediastinum. In the preantibiotic era the mortality rate was about 50%.¹ With antibiotics the rate is still as high as 40%.^{5,7} For those patients who survive the course is often a stormy one,^{7,8} as in our patient.

- 1 Pearse HH. Mediastinitis following cervical suppuration. *Ann Surg* 1938;108:588-611.
- 2 MayoSmith MF, Hirsch PJ, Wodzinski SF, Schiffman FJ. Acute epiglottitis in adults. An eight-year experience in the state of Rhode Island. *N Engl J Med* 1986;314:1133-9.
- 3 Tvetaras K, Kristensen S. Acute epiglottitis in adults. Bacteriology and therapeutic principles. *Clin Otolaryngol* 1987;12:337-43.
- 4 Baxter FJ, Dunn GL. Acute epiglottitis in adults. *Can J Anaesth* 1988;35:428-35.
- 5 Estrera AS, Landay MJ, Grisham JM, et al. Descending necrotising mediastinitis. *Surg Gynecol Obstet* 1983;157:545-52.
- 6 Bounds GA. Subphrenic and mediastinal abscess formation: a complication of Ludwig's angina. *Br J Oral Maxillofac Surg* 1985;23:313-21.
- 7 Levine TM, Wurster CF, Krespi YP. Mediastinitis occurring as a complication of odontogenic infections. *Laryngoscope* 1986;96:747-50.
- 8 Zachariades N, Mezitis M, Stavrinidis P, Konsolaki-Agouridaki E. Mediastinitis, thoracic empyema and pericarditis as complications of a dental abscess: report of a case. *J Oral Maxillofac Surg* 1986;46:493-5.
- 9 Grodinsky M, Holyoke EA. Fasciae and fascial spaces of the head, neck and adjacent regions. *Am J Anat* 1938;63:367-407.
- 10 Murray PM, Finegold SM. Anaerobic Mediastinitis. *Rev Infect Dis* 1984;6(S1):S123-7.