

Elective resection of tumours of the trachea and main carina after endoscopic laser therapy

S Shankar, P J M George, M R Hetzel, P Goldstraw

Abstract

In our patients with tumour affecting the trachea or carina elective surgery was carried out after endoscopic laser treatment. Laser treatment was performed as an emergency procedure in three of the patients, who presented with impending asphyxia; the improvement provided time in which to assess the disease, withdraw corticosteroids, and treat infection. The fourth patient was treated with the laser for life threatening haemoptysis, but further bleeding made it necessary to tamponade the tumour with a cuffed endotracheal tube for 24 hours. Elective resections of the trachea (three cases) and carina (one case) were performed successfully four to eight weeks after laser treatment. Frozen sections of the resection margins were clear in all cases and paraffin sections subsequently confirmed the localised nature of the lesions. All patients are alive and well with no evidence of tumour recurrence after 18 months to 4 years. Laser therapy appears to be an ideal preoperative treatment for patients with impending asphyxia but it may be of limited value in controlling very brisk haemorrhage.

Tumours of the trachea and carina are frequently not diagnosed correctly until a relatively late stage when there is advanced obstruction of the airway.^{1,2} Surgical resection of the tumour may be an appropriate treatment in some patients but must carry an appreciable risk when performed as an emergency procedure. Restoration of an adequate airway by endoscopic laser therapy may be of particular value in these circumstances as it provides time in which to assess the disease and allows subsequent treatment to be given electively.³

We have previously reported a patient with a primary tracheal tumour who had successful tracheal resection as an elective operation after emergency laser treatment.⁴ We have since treated a further three patients in this way and now report our experience. These four cases illustrate both the advantages and the limitations of this method of management.

Patients, methods, and outcome

PATIENTS

During 1985-8 four patients underwent elective tracheal or carinal resection after endoscopic laser treatment. Three were referred with severe upper airway obstruction and were judged to be at risk of asphyxia (cases 1-3), and the fourth was at risk of torrential haemoptysis (case 4). There were two men and two women, mean age 65 (range 64-66) years. Their presentations and subsequent management are described below. One of the cases (No 1) has been reported before.⁴

ENDOSCOPIC LASER THERAPY

All patients were treated with a neodymium YAG laser (Fiberlase 100, Pilkington Medical Systems) under general anaesthesia, a rigid ventilating bronchoscope being used. The output beam of the laser was transmitted via a flexible optical fibre and directed at the tumour by means of a fibreoptic bronchoscope passed inside the rigid bronchoscope. The thermal effects of the beam were used to vaporise the most superficial layers of tissue and coagulate the deeper layers. Rigid biopsy forceps were then used to remove tumour debris and coagulated tissue. The method has been described in detail.³

SURGERY

Tracheal resection was performed in three patients and carinal resection in one (case 2). The procedure was determined by the site of the lesion. One patient with a tumour in the upper trachea (case 3) underwent a trans-cervical tracheal resection with a primary anastomosis facilitated by suprahyoid release. The remaining three patients underwent transthoracic resections with primary anastomoses. A minitracheostomy and chinsternum stitch, to maintain cervical flexion, were used in each case. Frozen sections at the time of surgery confirmed that the resection margins were clear of tumour.

CASE REPORTS

Patient 1 A 66 year old man with a four month history of breathlessness developed extreme respiratory distress and inspiratory stridor. Tracheal tomography showed a tumour of the lower trachea. Infection had developed beyond the tumour. He was started on oral prednisolone and referred for urgent laser treatment. The intraluminal component of the tumour was resected by laser and an excellent airway established. Stridor was abolished and his peak expiratory flow (PEF) had risen from 80 to 240 l min⁻¹ 12 hours after he recovered from the anaesthetic. Corticosteroids were discontinued and his infection was treated with antibiotics. Biopsy specimens of the tumour showed a malignant mixed tumour arising from tracheal glands. After full assessment he was considered suitable for tracheal resection after six weeks, to allow time for withdrawal of steroids and resolution of infection. The patient has since remained well with no evidence of tumour recurrence for four years.

Department of
Thoracic Surgery,
Middlesex Hospital,
London

S Shankar
P Goldstraw

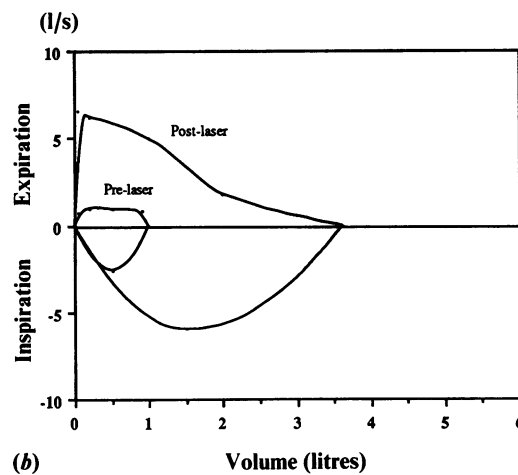
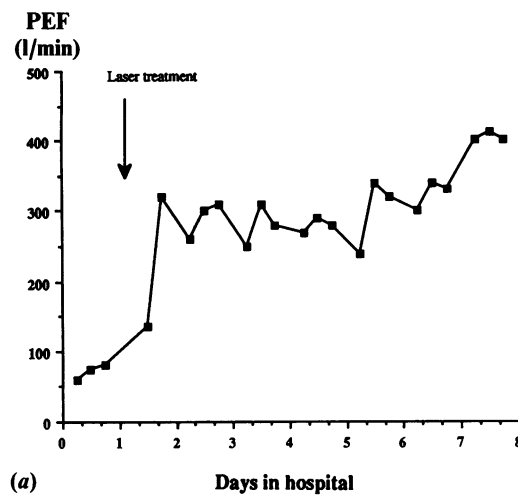
Department of
Thoracic Medicine,
University College
Hospital, London

P J M George
M R Hetzel

Address for correspondence:
Mr P Goldstraw,
Department of Thoracic
Surgery,
Middlesex Hospital,
London W1N 8AA

Accepted 16 January 1990

Figure 1 Changes in respiratory function after laser treatment in a patient with tumour of the main carina (case 2). (a) Increase in peak expiratory flow (PEF) from 60 to 400 l/min. (b) Maximum expiratory and inspiratory flow-volume curves obtained immediately before and four days after laser treatment, showing increased flow at all lung volumes.



Patient 2 A 66 year old man gave a six month history of progressive exertional dyspnoea, diagnosed and treated initially as late onset asthma. After three weeks he developed severe respiratory distress with obvious stridor and fiberoptic bronchoscopy showed a polypoid tumour at the main carina causing severe obstruction to both main bronchi. As he was thought to be at risk of asphyxiation he was referred for urgent laser treatment. This restored good patency to both main bronchi and, despite a chest infection that required antibiotics, his breathing immediately improved and his stridor was abolished. There was substantial improvement in PEF (from 60 to 400 l min⁻¹; fig 1a) and in flow at all lung volumes (fig 1b).

Histological examination showed invasive squamous cell carcinoma. Isotope bone scanning and computed tomography of the chest, upper abdomen and brain showed no evidence of metastatic disease. He was accepted for surgery, though this was deferred for two months while corticosteroids (given for asthma) were withdrawn and infection and inflammation at the site of treatment allowed to resolve. A right thoracotomy was performed and the main carina was resected, giving complete macroscopic clearance of the tumour. The margins of the trachea and main bronchi were clear of tumour in the frozen sections and the carina was reconstructed. Postoperative recovery was uneventful and the patient was discharged from hospital 10

days later. He has remained well for three years with no evidence of recurrent disease.

Patient 3 A 64 year old woman gave a four month history of cough and progressive exertional dyspnoea, attributed initially to chronic obstructive pulmonary disease. Her breathlessness abruptly grew worse, however, and she developed loud inspiratory stridor. Fiberoptic bronchoscopy showed polypoid tumour in the upper trachea. Although there was only a 60% obstruction of the tracheal lumen, infected secretions had accumulated beyond the tumour. Laser treatment was therefore expedited and restored an excellent airway. Her stridor was abolished and the infection resolved rapidly. Her PEF rose immediately from 120 to 200 l min⁻¹. Pretreatment and post-treatment flow-volume loops are shown in figure 2. Biopsy specimens were reported as showing squamous cell carcinoma. Computed tomography showed no evidence of metastatic disease and the tumour was considered resectable. Tracheal resection was deferred for six weeks to allow time for the resolution of inflammation and infection at the site of laser treatment. Immediately after surgery she developed hoarseness of her voice, due to damage to the left superior laryngeal nerve, and incoordinated swallowing. This latter complication was attributed to the suprahyoid release and settled after two months. She has remained well for two years with no evidence of recurrent disease.

Patient 4 A 66 year old woman gave a six week history of repeated and severe haemoptyses. She had previously undergone resections of haemangiopericytomas from the left aryepiglottic fold and the left false vocal cord. Fiberoptic bronchoscopy showed a further haemangiopericytoma in the lower trachea, which was thought to be the likely source of bleeding. Although the airway was not compromised, it was considered that laser photocoagulation should be performed to prevent further haemorrhages. Profuse bleeding, however, occurred during her treatment, which could not be controlled with the laser. A cuffed endotracheal tube was used to tam-

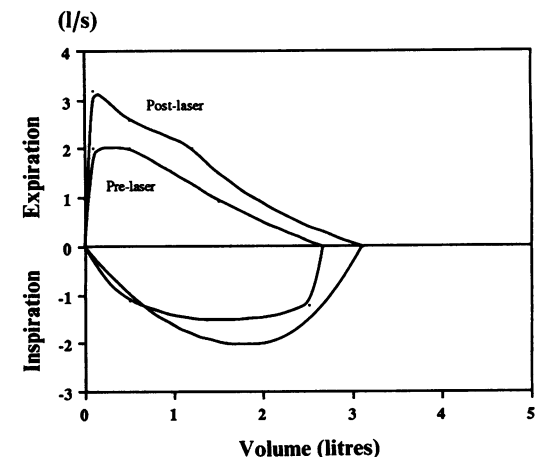


Figure 2 Maximum expiratory and inspiratory flow-volume curves obtained immediately before and four days after laser treatment in a patient with a tumour obstructing the upper trachea (case 3).

ponade the bleeding for 24 hours. The tube was then removed and elective tracheal resection was performed eight weeks later, when inflammation had resolved at the site of laser treatment. During the interval between laser treatment and resection she had no further haemoptyses. In the 18 months since tracheal surgery she has remained in excellent health with no further haemoptyses.

Discussion

Emergency laser treatment provides a safe and effective method of relieving respiratory distress in patients with tumours obstructing the trachea³ and carina. Although treatment is given for palliation, our experience has identified a group of patients who are candidates for curative surgery. The risk of impending asphyxia in three of the patients reported here (cases 1–3) precluded careful investigation and tumour staging and so they were not considered for early surgery at the time of presentation. Prompt restoration of an adequate airway with the laser, however, provided time in which to assess their disease and plan elective surgery.

An important advantage of elective surgery is the provision of frozen section analysis. The risks of surgery are known to rise as the extent of the resection increases. Tumour clearance may therefore be compromised in the interests of keeping the resection margins to a minimum. In the present series frozen sections showed that the resection margins were free from tumour and thereby enabled the operator to obtain optimal clearance. This was subsequently confirmed by paraffin sections in each of the four cases.

Although tracheal resection is a widely performed procedure, it carries a mortality ranging from 7.4% to 15%.^{5,6} Carinal resection has a higher mortality, in the region of 13–31%.^{7,8} The mortality in patients who undergo emergency resections is not documented but is likely to be even higher. Preoperative laser treatment should reduce some of the risks of surgery as it provides time to withdraw corticosteroids (which might jeopardise healing) and facilitates the resolution of infection beyond the tumour.

Laser treatment inevitably causes some thermal damage to the airway adjacent to the tumour and there is a theoretical risk of impaired healing at the site of the anastomosis. Surgery was therefore deferred for up to eight

weeks to allow inflammation and infection at the site of treatment to resolve. This precaution appears to have been adequate as anastomotic complications were not seen in any of our patients.

Although the thermal action of the neodymium YAG laser normally permits adequate haemostasis, bleeding could not be controlled in the patient with a haemangiopericytoma (case 4). Nevertheless, further haemoptyses did not occur in the interval between laser treatment and tracheal resection. Experimental work on canine gastric mucosa suggests that the neodymium YAG laser may seal vessels of up to 1.5 mm in diameter.⁹ Bleeding from larger vessels, however, may not be adequately controlled and this may be the explanation for failure in case 4. Whether the neodymium YAG laser provides the best available method for controlling brisk bleeding awaits further evaluation.

In our experience, patients with tumours of the trachea and main carina are frequently misdiagnosed in the early stages of their disease. The consequent delays undoubtedly contribute to the severity of their respiratory distress at the time of referral. Emergency endoscopic laser treatment, however, provides a safe and effective method of restoring an adequate airway. This provides time for identifying patients with operable tumours and has the advantage of allowing subsequent surgery to be performed electively. The value of laser treatment in controlling life threatening haemorrhage, however, is questionable and requires further assessment.

- 1 Houston HE, Harrison EG, Olsen AM. Primary cancers of the trachea. *Arch Surg* 1969;99:132–40.
- 2 Hajdu SI, Huvos AG, Goodner JT, Foote FW, Beattie JR. Carcinoma of the trachea: clinicopathologic study of 41 cases. *Cancer* 1970;25:1448–56.
- 3 George PJM, Garrett CPO, Hetzel MR. Role of the neodymium YAG laser in the management of tracheal tumours. *Thorax* 1987;42:440–4.
- 4 George PJM, Garrett CPO, Goldstraw P, Hetzel MR, Ramsay AD. Resuscitative laser photoresection of a tracheal tumour before elective surgery. *Thorax* 1986;41:812–3.
- 5 Grillo HC. Management of tracheal tumours. *Am J Surg* 1982;143:697–700.
- 6 Perleman M, Koroleva N. Surgery of the trachea. *World J Surg* 1980;4:583–93.
- 7 Grillo HC. Tracheal tumours: surgical management. *Ann Thorac Surg* 1978;26:112–25.
- 8 Pearson FG, Todd TRJ, Cooper JD. Experience with primary neoplasms of the trachea and carina. *J Thorac Cardiovasc Surg* 1984;88:511–8.
- 9 Kelly DF, Bown SG, Calder BM, et al. Histological changes following Nd YAG laser photocoagulation of canine gastric mucosa. *Gut* 1983;24:914–20.